

# Unusual Cause of Acute Back Pain Mimicking Aortic Dissection: A Case Report

Markus Czesla<sup>1</sup> Olga Karnari<sup>1</sup> Julia Götte<sup>1</sup> Bernhard Schulte<sup>2</sup> Ulrich Pfeilsticker<sup>3</sup> Anita Narr<sup>1</sup>  
Nicolas Doll<sup>1</sup>

<sup>1</sup>Sana Herzchirurgie Stuttgart, Stuttgart, Germany

<sup>2</sup>Robert Bosch Krankenhaus Stuttgart, Stuttgart, Germany

<sup>3</sup>Klinikum Sindelfingen-Böblingen, Sindelfingen, Germany

**Address for correspondence** Dr. Markus Czesla, M.D., Sana Herzchirurgie Stuttgart GmbH, Herdweg 2, Stuttgart 70174, Germany (e-mail: m.czesla@sana-herzchirurgie.de).

Thorac Cardiovasc Surg 2012;60(S2):e28–e30.

## Abstract

### Keywords

- ▶ aortic dissection
- ▶ embolism
- ▶ foreign body
- ▶ pulmonary embolism

We report the case of a 62-year-old woman who initially presented with symptoms suggesting acute type A aortic dissection. Imaging studies revealed hemorrhagic pericardial fluid without the evidence of dissection. Foreign body material was noted floating in the inferior vena cava (IVC) and also piercing the right ventricular wall. Upon surgical exploration, the extracted material could be identified to be acrylic bone cement (palacos). The patient had reported a history of kyphoplasty in 2008.

Hemopericard in combination with acute back pain typically raises the concern for acute type A aortic dissection. It is important to recognize that according to the recent case reports, a wide variety of rare conditions can mimic aortic dissections. Our case illustrates that prompt assessment and appropriate surgical care are fundamental in the management of these patients.

## Case Presentation

A 62-year-old woman admitted to the hospital complaining of acute chest pain. She described sudden onset of stabbing pain between her shoulder blades. Her medical history was unremarkable, except for spine surgery in 2008. The clinical symptoms appeared to be consistent with the diagnosis of acute aortic dissection. Transthoracic echocardiography and a CT scan of the chest revealed a 7 to 16 mm pericardial effusion without the evidence of a dissection flap in the ascending aorta, dilation of the aortic root, or aortic valve insufficiency. Coronary angiography did not show any signs of coronary artery disease. Three irregular shaped, 8 to 15 cm long and thin pieces of foreign body material appeared to be located in the IVC (▶ **Figs. 1,2**), the right atrium, and the right ventricular wall. Another piece was found in a branch of the right pulmonary artery. These structures could clearly be identified on CT images. The patient was taken to the

operating room. Intraoperative findings included a small amount of hemorrhagic pericardial effusion as well as foreign body material perforating the inferior wall of the right ventricle close to the posterior descending coronary artery. The 2 to 3 mm thick foreign body could be extracted completely from the right ventricle. The two pieces in the IVC could not be entirely removed from the inferior vena cava because they appeared adherent to the vessel wall distally. The extracted material was sent to the pathology for further examination. During her postoperative course, no relevant complications occurred. The patient was discharged within 3 weeks.

## Discussion

Although acute type A aortic dissection should lead to rapid surgical treatment, a thorough history, clinical exam, and work-up are of major importance to identify the correct diagnosis and provide appropriate care. Eagle et al analyzed 55 patients who admitted to the emergency department complaining of symptoms initially suggesting acute aortic dissection.<sup>1</sup> Negative aortograms prompted further testing and revealed a wide variety of entities including myocardial infarction, aneurysms, mediastinal tumors, as well as rare findings such as cholecystitis. Several case reports describe rare conditions like ingested fish bones, and dislodged

received

June 18, 2011

accepted

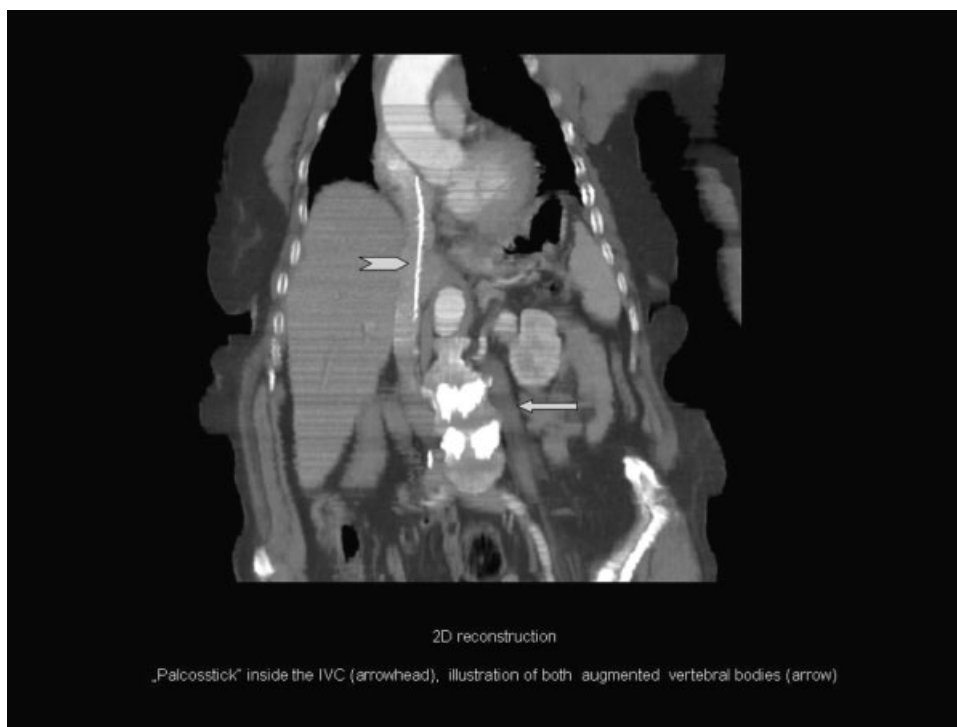June 20, 2011

published online

December 29, 2011

© 2012 Georg Thieme Verlag KG  
Stuttgart · New York

DOI <http://dx.doi.org/10.1055/s-0031-1295580>.  
ISSN 2194-7635.

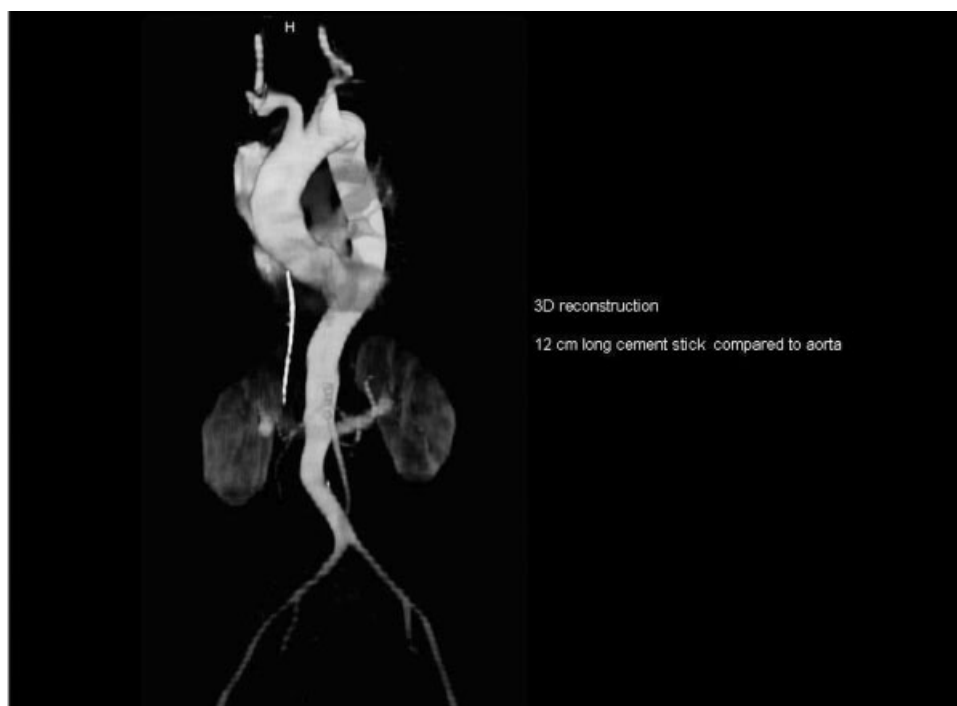


**Figure 1** 2D reconstruction: palacosstick inside the IVC, illustration of both augmented vertebral bodies.

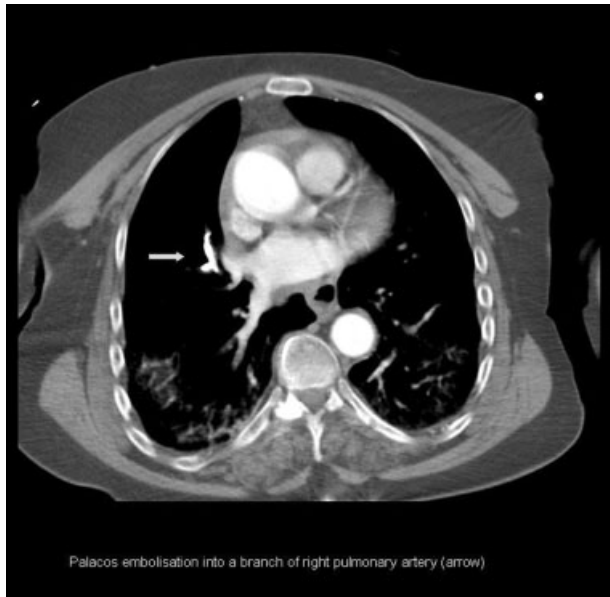
transcatheter closure devices causing symptoms masquerading acute dissections.<sup>2,3</sup>

More than 8 cm long, thin and almost entirely straight cement sticks in the IVC and right ventricular wall is a very seldom finding. Our question was: how did it get there? The patient had undergone kyphoplasty 2 years prior to the

presentation, the only possible reason for the cement finding in her body. The procedure is used for pain relief of osteoporotic vertebral body compression fractures. After percutaneous injections of palacos the material solidifies. This process generates temperatures as high as 70°C with the potential of causing tissue damage allowing leakage of bone cement into



**Figure 2** 3D reconstruction: palacosstick compared with aorta.



**Figure 3** Palacos embolus into a branch of right pulmonary artery.

surrounding structures. In her case, we must assume that the cement application was difficult. Besides the palacos pieces in the IVC and right heart, a relatively large pulmonary embolus can be identified on CT images, suggesting palacos embolization into a branch of the right pulmonary artery (►**Fig. 3**). Similar observations have been reported in the recent publications.<sup>4-9</sup> We assume that over time one of the spiky cement sticks has worked itself through the right ventricular wall eventually causing a perforation with hemopericard and acute onset of symptoms resembling an aortic dissection.

Our case report illustrates a rare condition initially suggesting a wrong diagnosis. The described scenario emphasizes the importance of a thorough history and unbiased review of imaging tests. Missing out on the correct diagnosis in our patient could have resulted in a life-threatening condition or death.

## References

- 1 Eagle KA, Quertermous T, Kritzer GA, et al. Spectrum of conditions initially suggesting acute aortic dissection but with negative aortograms. *Am J Cardiol* 1986;57(4):322-326
- 2 Girdauskas E, Diab M, Secknus MA, Borger MA, Kuntze T. Late cardiac perforation after transcatheter closure of patent foramen ovale mimicking acute type a aortic dissection. *Ann Thorac Surg* 2010;89(5):1649-1651
- 3 Kitzing B, Li YX. Fish bone ingestion mimicking aortic dissection: a case report. *Cases J* 2008;1(1):233
- 4 Agko M, Nazzal M, Jamil T, Castillo-Sang M, Clark P, Kasper G. Prevention of cardiopulmonary embolization of polymethylmethacrylate cement fragment after kyphoplasty with insertion of inferior vena cava filter. *J Vasc Surg* 2010;51(1):210-213
- 5 Cohen J, Lane T. Right intra-atrial and ventricular polymethylmethacrylate embolus after balloon kyphoplasty. *Am J Med* 2010;123(10):e5-e6
- 6 Farahvar A, Dubensky D, Bakos R. Perforation of the right cardiac ventricular wall by polymethylmethacrylate after lumbar kyphoplasty. *J Neurosurg Spine* 2009;11(4):487-491
- 7 Lee IJ, Choi AL, Yie MY, et al. CT evaluation of local leakage of bone cement after percutaneous kyphoplasty and vertebroplasty. *Acta Radiol* 2010;51(6):649-654
- 8 Park JH, Choo SJ, Park SW. Images in cardiovascular medicine. Acute pericarditis caused by acrylic bone cement after percutaneous vertebroplasty. *Circulation* 2005;111(6):e98
- 9 Schoenes B, Bremerich DH, Risteski PS, Thalhammer A, Meininger D. [Cardiac perforation after vertebroplasty]. *Anaesthesist* 2008;57(2):147-150