Hyaluronic acid injection for sustained control of bleeding from a sclerotic ulcer base

A 55-year-old man with recurrent duodenal ulcers presented to our institution with massive hematemesis. Emergent endoscopy revealed a duodenal ulcer scar and pulsatile bleeding at the base of the ulcer (**Fig. 1**).

Endoscopic hemoclipping was attempted three times, but this failed due to the sclerotic ulcer base. Thermocoagulation was tried but this also failed. Intense electrical coagulation of a duodenal lesion can cause perforation, so we carried out hot biopsy forceps coagulation three times. Injection of an epinephrine mixture around the bleeding focus only had a transient effect. However, prior to considering emergent surgery or radiological intervention, we decided to inject a total of 20 mL of a 0.2% 3000 kDa Line 16 hyaluronic acid solution made from 4 mL Hyruan Plus (LG, Seoul, Korea) and 16 mL normal saline; 5 mL of the hyaluronic acid solution was injected at each of four points around the bleeding focus (**Fig. 2**). This intervention successfully stopped the bleeding (**Fig. 3**), and a follow-up endoscopy 12 hours later revealed no evidence of hemorrhage from the previously bleeding site (**Fig. 4**). Endoscopic ultrasonography after 3 days showed a round but ill-defined, homogeneously hypoechoic lesion within the wall of the duodenum (**Fig. 5**), which may have represented residual hyaluronic acid under the ulcer.

The disadvantages of injection therapy include a short-lived effect due to gradual dissipation of the injected fluid [1]. However, injection of hyaluronic acid solution increases the tamponading pressure and prolongs the tamponading time even under a sclerotic ulcer base. Hyaluronic acid is a naturally occurring polysaccharide with distinct physicochemical properties that underpin its application as a viscoelastic tool [2]. It is thought to be the best material for injection for endoscopic submucosal dissection because of its ability to create a persistent submucosal cushion [3]. Control of bleeding by sustained tamponading pressure allows sufficient time for inducing natural healing of the bleeding focus. Based on our experience, we suggest using, in carefully selected cases, hyaluronic acid injection for uncontrolled

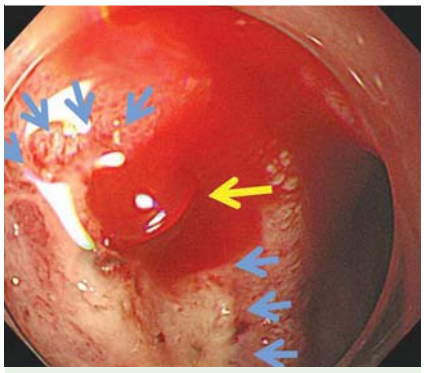

Fig. 1 Pulsatile bleeding (yellow arrow) from a sclerotic ulcer base (blue arrows) in a 55-year-old man with recurrent duodenal ulcers and massive hematemesis.

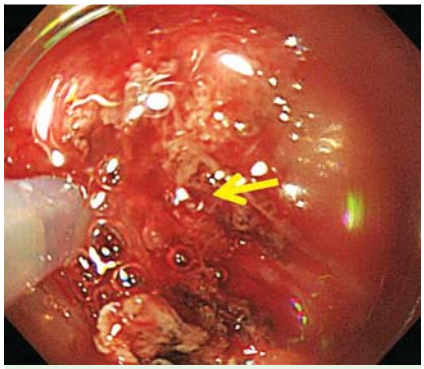

Fig. 2 Injection of 5 mL of 0.2% hyaluronic acid solution at the 9 o'clock side of the bleeding focus (arrow).

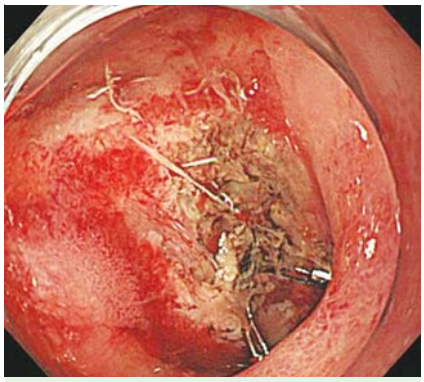

Fig. 3 Bleeding from the ulcer successfully controlled after hyaluronic acid injection.

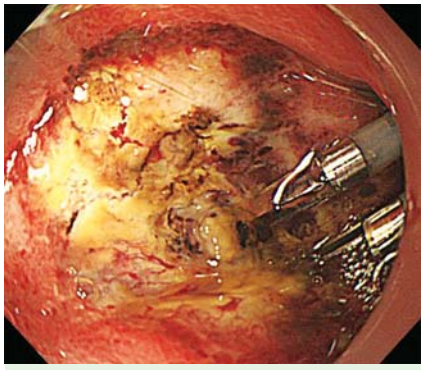

Fig. 4 Bleeding from the ulcer is still controlled after 12 hours following the hyaluronic acid injection.

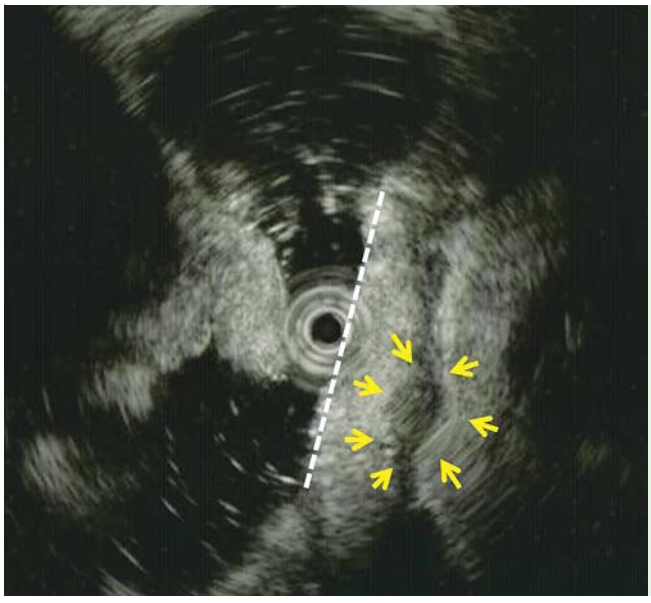

Fig. 5 Endoscopic ultrasonography (20 MHz, mini-probe) showing a relatively round but ill-defined, homogeneously hypoechoic lesion, suggesting residual hyaluronic acid (yellow arrows) under the ulcer base (white dotted line).

This document was downloaded for personal use only. Unauthorized distribution is strictly prohibited.

bleeding from a sclerotic ulcer base, especially at the duodenum.

Endoscopy_UCTN_Code_TTT_1AO_2AD

Competing interests: None

H. H. Kim, S. J. Park, M. I. Park, W. Moon

Department of Internal Medicine, Kosin University College of Medicine, Busan, Korea

References

1 *Park WG, Yeh RW, Triadafilopoulos G.* Injection therapies for nonvariceal bleeding disorders of the GI tract. Gastrointest Endosc 2007; 66: 343 – 354
2 *Goa KL, Benfield P.* Hyaluronic acid. A review of its pharmacology and use as a surgical aid in ophthalmology, and its therapeutic potential in joint disease and wound healing. Drugs 1994; 47: 536 – 566
3 *Hyun JJ, Chun HR, Chun HJ* et al. Comparison of the characteristics of submucosal injection solutions used in endoscopic mucosal resection. Scand J Gastroenterol 2006; 41: 488 – 492

Bibliography
DOI http://dx.doi.org/10.1055/s-0031-1291756
Endoscopy 2012; 44: E169–E170
© Georg Thieme Verlag KG Stuttgart · New York
ISSN 0013-726X

Corresponding author
H. H. Kim
Department of Internal Medicine
Kosin University College of Medicine
34 Amnam-dong, Seo-gu
Busan 602-702
Korea
Fax: +82-51-990-5055
drhhkim@gmail.com

This document was downloaded for personal use only. Unauthorized distribution is strictly prohibited.