A rare case of double primary cancer of the colon with parotid gland metastasis

The major modes of spread for colon cancer are local invasion and lymphatic and hematogenous metastasis, with the liver being the most common site of metastasis, followed by the peritoneum, omentum, lung, and mesentery. Parotid gland involvement by adenocarcinoma of the colon is extremely rare. We report here a patient who developed a mass in the right neck due to a metastasis from a double primary adenocarcinoma of the colon.

A 78-year-old woman attended our hospital after an episode of hematochezia that had occurred 3 days previously. At her visit, she also complained of a lump in her neck that she had noticed a month before. A colonoscopy performed to evaluate the hematochezia showed a coin-shaped, elevated lesion in the area adjacent to the ileocecal valve (**Fig. 1 a**) and an ulcerated, fungating mass surrounding the lumen of the sigmoid colon (**Fig. 1 b**).

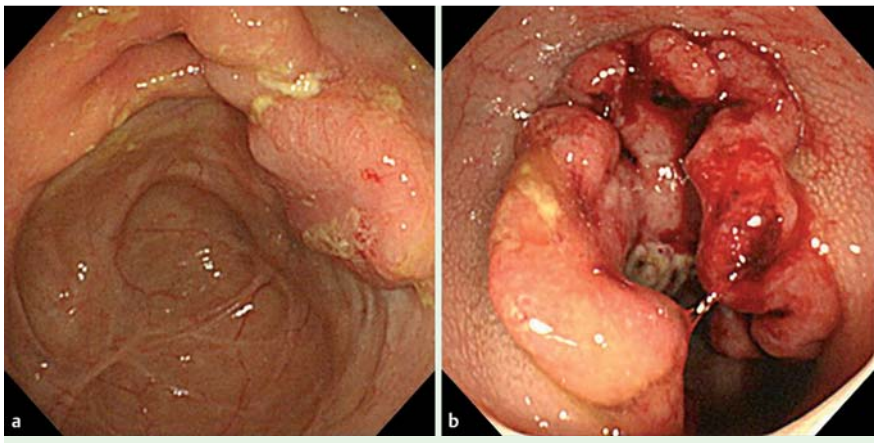

Fig. 1 Views from a colonoscopy performed in a 78-year-old woman with hematochezia showing: **a** a coin-shaped, elevated lesion in the area of the ileocecal valve; **b** an ulcerated, fungating mass surrounding the lumen of the sigmoid colon.

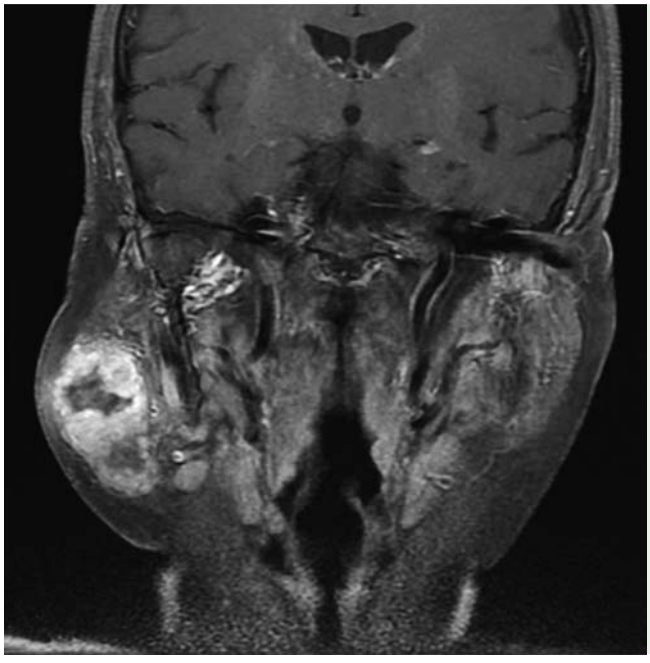

Fig. 3 Contrast-enhanced, T1-weighted magnetic resonance imaging (MRI) scan showing a heterogeneously enhancing mass with a non-enhancing cystic or necrotic center in the right parotid gland.

Biopsies of each lesion were taken for histology, and both revealed a diagnosis of moderately differentiated colon adenocarcinoma.

Combined positron emission tomography and computed tomography (PET/CT) was performed for the staging and evaluation of the colon cancer. This showed a hypermetabolic lesion accompanied by diffuse wall thickening in the sigmoid colon and a hypermetabolic mass in the right parotid gland (**Fig. 2**). Subsequent magnetic resonance imaging (MRI) showed a 5.6-cm mass with low intensity T1-weighted signal and heterogeneous high intensity T2-weighted signal in the right parotid gland (**Fig. 3**).

To further evaluate the right neck mass, a fine needle aspiration (FNA) was performed, which was consistent with a diagnosis of metastatic carcinoma. A decision was made to perform a right hemicolectomy and anterior resection followed by a parotidectomy (**Fig. 4 a**). Histopathology of the resected parotid gland revealed tumor cell infiltration and accompanying necrosis of the capsule. Columnar cells, which are not observed in normal parotid tissue, were present (**Fig. 4 b**), and staining for carcinoembryonic antigen (CEA), performed to verify the colonic origin of the metastasis, showed focal positivity (**Fig. 4 c**). Based on the above results, the patient was diagnosed as having double primary cancer of the colon

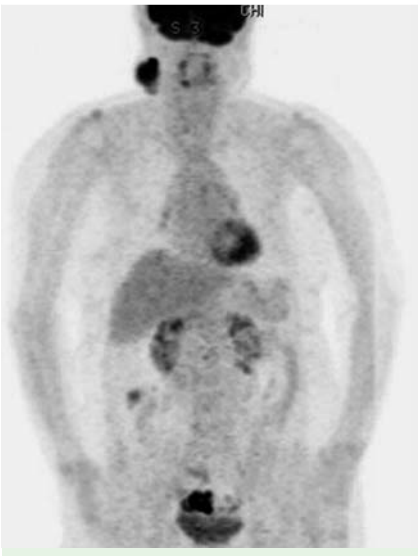

Fig. 2 Combined positron emission tomography and computed tomography (PET/CT) scan showing a hypermetabolic lesion accompanied by diffuse wall thickening in the sigmoid colon and a hypermetabolic mass in the right parotid gland.

This document was downloaded for personal use only. Unauthorized distribution is strictly prohibited.

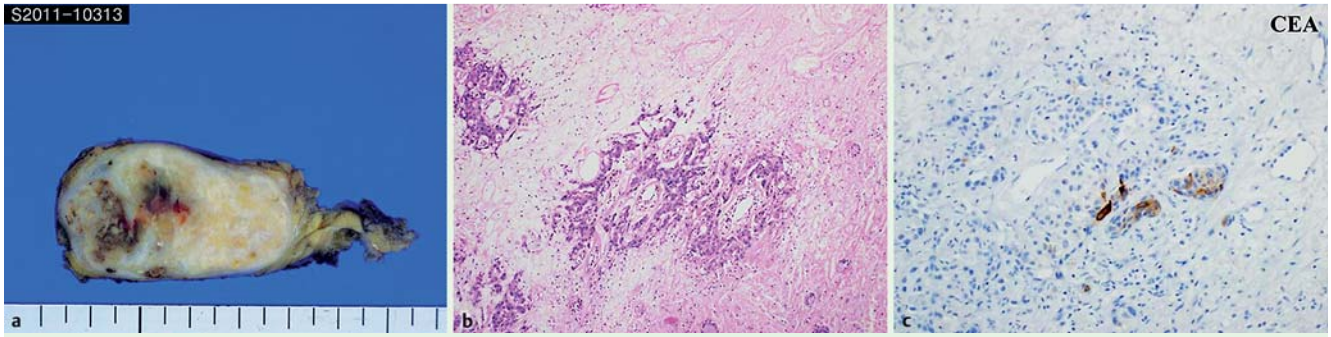

Fig. 4 Pathological examination of the resected parotid gland revealed: **a** a 4.5 × 2.5-cm parotid mass macroscopically; **b** tumor cell infiltration of the salivary gland with accompanying necrosis of the capsule microscopically; **c** focal positivity when stained for carcinoembryonic antigen (CEA; magnification × 200).

with parotid gland metastasis. The progression of her condition remains under observation.

Metastatic involvement of the parotid gland may arise from lymphatic spread, hematogenous dissemination, or contiguous involvement. Contiguous extension is common with malignancies of the supporting tissues in the parotid region, whereas the parotid gland is unusual as the focus of a distant primary tumor [1]. Most metastases to the parotid gland arise from primary tumors in the head and neck region, usually being either melanomas or squamous cell carcinomas. The frequency of metastasis to the parotid gland is low for many types of cancers, including for primary cancers of the lung, breast, and colon.

Colorectal carcinoma has the potential to metastasize to almost any organ of the body, as has been shown from autopsy reports. However, to date there have been only six reported cases of colon cancer metastasizing to the parotid gland [2,3]. To our knowledge, a solitary distant metastasis from a double primary colon cancer without other tumor spread has not been previously described. Although rare, metastatic adenocarcinoma from the colon should be included in the differential diagnosis of lesions of the parotid gland.

Endoscopy_UCTN_Code_CCL_1AD_2AB

Competing interests: None

S. Y. Kim[1], J. K. Seong[1], H. Y. Jeong[1], K. S. Kim[1], I. S. Jeong[1], K. H. Ko[1], H. S. Moon[1], D. Y. Kang[2]

[1] Department of Internal Medicine, Chungnam University College of Medicine, Daejeon, South Korea

[2] Department of Pathology, Chungnam University College of Medicine, Daejeon, South Korea

References

1 *Yarington CT*. Metastatic malignant disease to the parotid gland. Laryngoscope 1981; 91: 517 – 519

2 *Velez A*, *Petrelli N*, *Herrera L* et al. Metastasis to the parotid gland from colorectal adenocarcinoma. Dis Colon Rectum 1985; 28: 190 – 192

3 *Kucan JO*, *Frank DH*, *Robson MC*. Tumors metastatic to the parotid gland. Br J Plast Surg 1981; 34: 299 – 301

Bibliography

DOI http://dx.doi.org/10.1055/s-0031-1291694
Endoscopy 2012; 44: E123–E124
© Georg Thieme Verlag KG
Stuttgart · New York
ISSN 0013-726X

Corresponding author
H. S. Moon, MD
Chung Nam National University Hospital – Internal medicine
Daejeon 301-721
South Korea
Fax: +82-042-2575753
mhs1357@cnuh.co.kr

This document was downloaded for personal use only. Unauthorized distribution is strictly prohibited.