Osseous metaplasia of the colon in an ulcerative proctosigmoiditis

A 77-year-old woman presented with acute abdominal pain and hematochezia. The patient reported a normal routine colonoscopy 2 years ago. Her long-term medication consisted of statins, allopurinol, and triazolam. Additionally she had a short-term analgesic medication (naproxen). At colonoscopy, a marginal macroscopic inflammation of the sigmoid colon and a 4-mm rectal polypoid lesion were visible (**Fig. 1**).

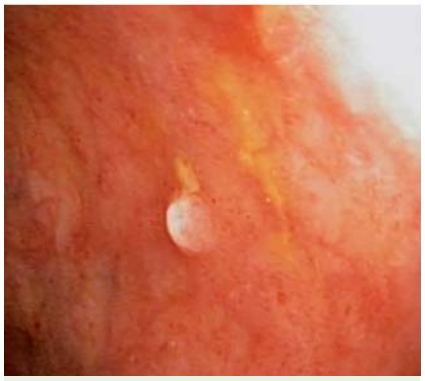

Fig. 1 Endoscopic view of the lesion.

During histological examination, a mixed inflammatory infiltrate was visible in the lamina propria, with multiple crypt abscesses (**Fig. 2**). The polypoid lesion showed hyperplastic crypts and foci of heterotopic bone formation (**Fig. 3**). Small regions with surface ulceration could be seen. Thus the histopathological diagnosis was ulcerative proctosigmoiditis with metaplastic bone formation. It seems that the bone formation had persisted for a long time and that the finding of ulcerative colitis was overlaid by an infectious component. Due to a normal number of leukocytes in the blood sample, and unremarkable stool samples, a parasitic infection was excluded.

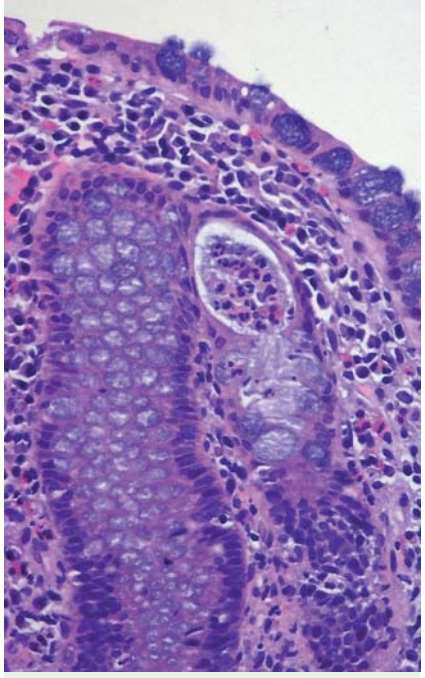

Fig. 2 Microscopic image showing colitis with crypt abscess (hematoxylin and eosin stain, ×400).

Heterotopic ossification in the gastrointestinal tract is described predominantly in mucin-producing carcinomas of the colon [1]. Descriptions of ossification within inflammatory gastrointestinal lesions are extremely rare, and the pathological mechanisms remain unclear. Sperling et al. assumed that bone-forming osteoblasts differentiate from immature fibroblasts [2]. Rifas et al. demonstrated that T-cell cytokines regulate the differentiation process of human mesenchymal stromal cells into osteoblasts by inducing bone morphogenetic protein-2 (BMP-2) [3]. Yu et al. reported that an active actin receptor-like kinase-2 (ALK2), activated by BMP receptor 1, leads to ectopic bone formation [4]. Finally, Shafritz et al. showed that overexpression of BMP-4 in lymphocytes is associated with ectopic osteogenesis in fibrodysplasia ossificans progressiva [5]. Overall, chronic inflammatory processes seem to play an important role in ectopic bone formation.

Endoscopy_UCTN_Code_CCL_1AD_2AJ

Competing interests: None

L. Veits[1,2], A. Perathoner[3], C. Profanter[3], C. Falkeis[1,2], G. Mikuz[1], C. Ensinger[1]

[1] Institute of Pathology, Medical University of Innsbruck, Innsbruck, Austria
[2] Institute of Pathology, Klinikum Bayreuth, Bayreuth, Germany
[3] Department of Visceral, Transplant and Thoracic Surgery, Medical University of Innsbruck, Innsbruck, Austria

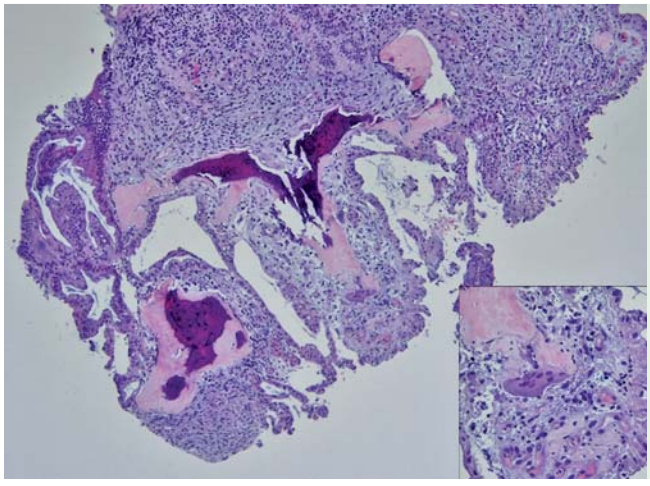

Fig. 3 Microscopic image showing colitis with heterotopic ossification, ulceration, and an osteoclastic giant cell (shown also in enlarged inset) (hematoxylin and eosin stain, ×40).

References

1 *Haque S*, *Eisen RN*, *West AB*. Heterotopic bone formation in the gastrointestinal tract. Arch Pathol Lab Med 1996; 120: 666 – 670

2 *Sperling MH*, *Friedman CJ*. Osseuous metaplasia in a benign colon polyp. Gastrointest Endosc 1981; 27: 198 – 199

3 *Rifas L*. T-Cell Cytokine Induction of BMP-2 Regulates Human Mesenchymal Stromal Cell Differentiation and Mineralization. J Cell Biochem 2006; 98: 704 – 714

4 *Yu PB*, *Deng DY*, *Lai CS* et al. BMP type I receptor inhibition reduces heterotopic ossification. Nat Med 2008; 14: 1363 – 1369

5 *Shafritz AB*, *Shore EM*, *Gannon FH* et al. Overexpression of an osteogenic morphogen in fibrodysplasia ossificans progressiva. N Engl J Med 1996; 335: 555 – 561

Bibliography

DOI http://dx.doi.org/10.1055/s-0031-1291602
Endoscopy 2012; 44: E76–E77

ISSN 0013-726X

Corresponding author

L. Veits, MD
Institute of Pathology
Klinikum Bayreuth
Preuschwitzerstraße 101
95445 Bayreuth
Germany
Fax: +49-921-4005609
lothar.veits@klinikum-bayreuth.de