

Complete esophageal occlusion after band ligation

Esophageal variceal ligation (EVL) is commonly used to treat esophageal varices given its safety profile [1]. We report an unusual complication of EVL, complete esophageal obstruction, managed with the use of a clear cap attached to the gastroscope using a “can opener” maneuver. An 84-year-old white woman with primary biliary cirrhosis intolerant to β -blockers underwent prophylactic EVL using the seven-shooter multiband ligator (Boston Scientific Inc., Natick, Massachusetts, USA) (● Fig. 1). On arriving home, she reported inability to tolerate even water. Repeat upper endoscopy demonstrated complete esophageal obstruction with a single band (● Fig. 2). Multiple attempts to remove the band using the endoscope, snare, and biopsy forceps were unsuccessful. A clear-cap (D-201–11304, Olympus Inc., Tokyo, Japan) fitted gastroscope was then used to secure one side of the band and, just like the movement to remove a cap from a bottle, dislodge the band (● Fig. 3). The patient returned 6 days later with similar complaints. An esophagogram showed a distal esophageal obstruction (● Fig. 4). Repeat endoscopy demonstrated necrotic tissue occluding the esophagus, which was managed by dilation with a through the scope balloon and insertion of a nasoenteral feeding tube. After 2 weeks the nasoenteral feeding tube was removed and the esophageal stricture dilated to 15 mm (● Fig. 5). The patient is now eating without restrictions and has remained asymptomatic for 6 months.

Complete esophageal occlusion is a rare complication of EVL, however, removal of the occluding band may be challenging [3–5]. We report the novel use of a clear cap to successfully dislodge the band and relieve the obstruction.

Endoscopy_UCTN_Code_CPL_1AH_2AC

Competing interests: None

S. W. de Melo

University of South Alabama, Mobile, Alabama, USA

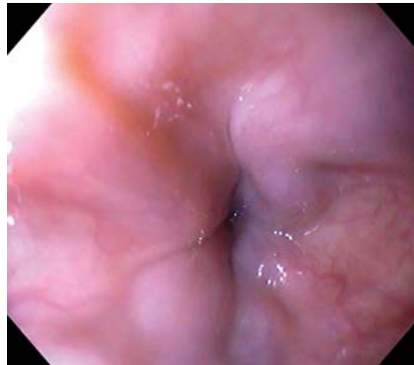


Fig. 1 Small esophageal varices seen on endoscopy.

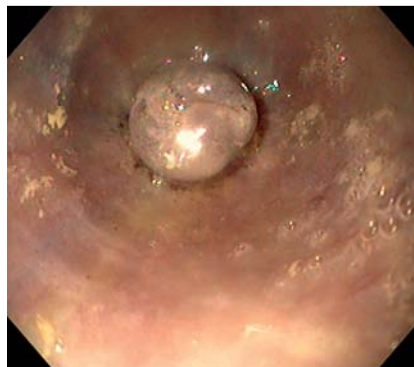


Fig. 2 Complete esophageal ligation.

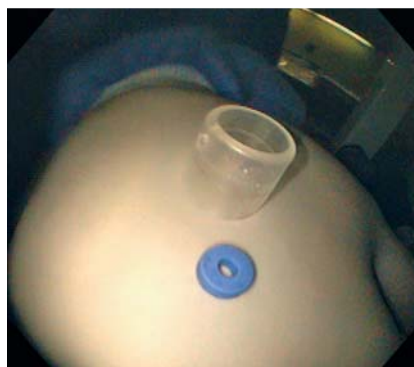

Fig. 3 Clear cap and the removed band.

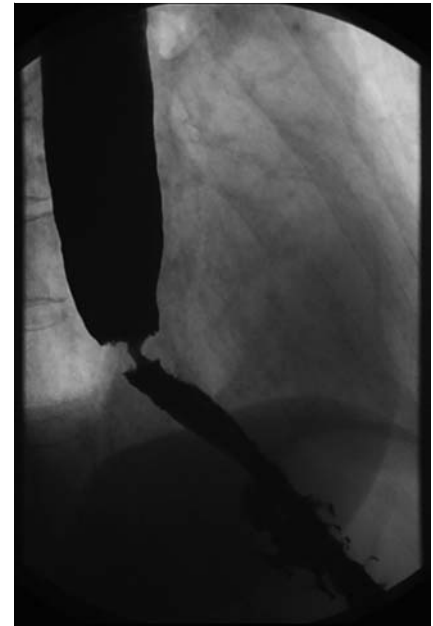


Fig. 4 Gastrografin esophagogram with distal esophageal “ring.”

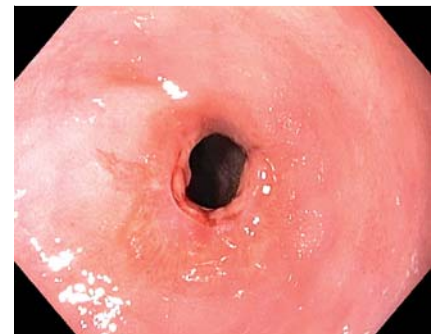

Fig. 5 Esophageal stricture after dilation.

References

- 1 Garcia-Tsao G, Sanyal AJ, Grace ND, Carey W. Prevention and management of gastroesophageal varices and variceal hemorrhage in cirrhosis. *Hepatology* 2007; 46: 922–938
- 2 Garcia-Tsao G, Bosch J. Management of varices and variceal hemorrhage in cirrhosis. *N Engl J Med* 2010; 362: 823–832
- 3 Nawaz A, Sarwar S, Batul A. Complete esophageal occlusion following esophageal variceal band ligation: an unusual complication; a case report. *Visible Human Journal of Endoscopy* 2010; 9: 1–4

Bibliography

DOI 10.1055/s-0030-1256522

Endoscopy 2011; 43: E259

© Georg Thieme Verlag KG Stuttgart · New York · ISSN 0013-726X

Corresponding author

S. W. de Melo Jr, MD

University of South Alabama
5600 Girby Road
Mobile
AL 36693
USA
demelo@usouthal.edu

4 Verma D, Pham C, Madan A. Complete esophageal obstruction: an unusual complication of esophageal variceal ligation. *Endoscopy* 2009; 41 Suppl 2: E200–201

5 Rai RR, Nijhawan S, Singh G. Post-ligation stricture: a rare complication. *Endoscopy* 1996; 28: 406