Cyanoacrylate glue in the management of blue rubber bleb nevus syndrome

Fig. 1 Case 1. Hemangiomas of the foot.

Fig. 2 Case 1. Capsule endoscopy picture of a bluish, nipple-like rubbery vascular lesion of the jejunum, compatible with a blue rubber bleb nevus.

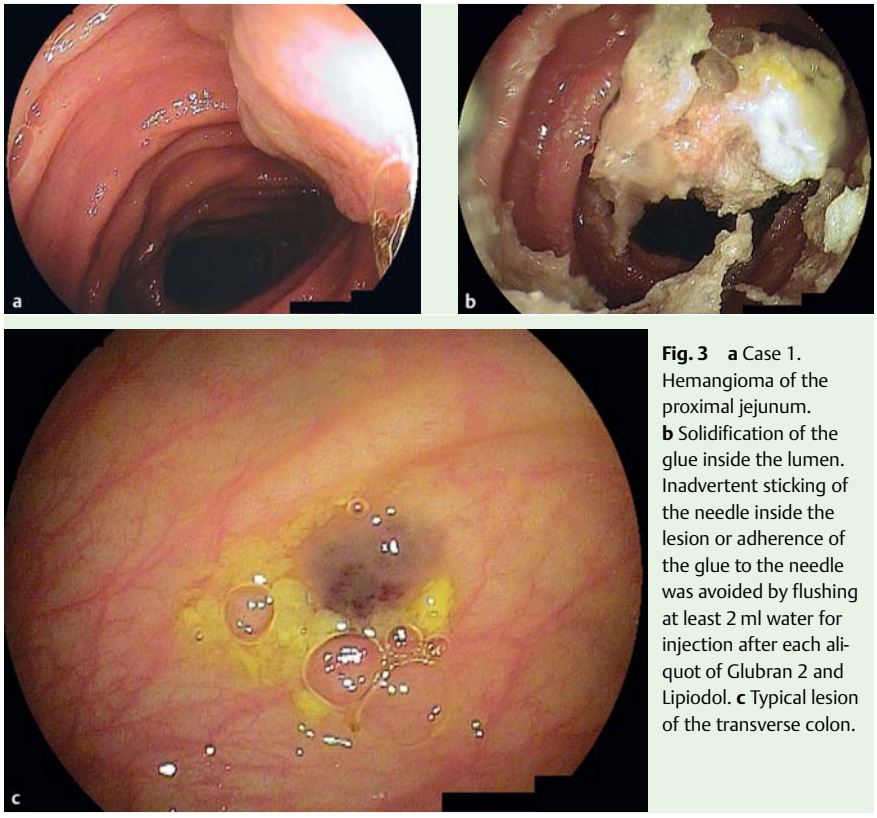

Fig. 3 **a** Case 1. Hemangioma of the proximal jejunum. **b** Solidification of the glue inside the lumen. Inadvertent sticking of the needle inside the lesion or adherence of the glue to the needle was avoided by flushing at least 2 ml water for injection after each aliquot of Glubran 2 and Lipiodol. **c** Typical lesion of the transverse colon.

Case 1. A 16-year-old boy with blue rubber bleb nevus syndrome (BRBNS) was admitted for occult bleeding. He had a history of gastric and colonic hemangiomas treated 2 years earlier by argon plasma coagulation and alcohol injection respectively. Clinical examination showed a few hemangiomas on his back and feet (▶ **Fig. 1**).

Capsule endoscopy (Pillcam SB2; Given Imaging, Yoqneam, Israel) disclosed three blebs of the small bowel (▶ **Fig. 2**), and the patient underwent double-balloon enteroscopy (Fujinon, Saitama, Japan).

A 2-cm bleb was found at the jejunum, two smaller lesions at the ileum, and one at the transverse colon. N-butyl-2-cyanoacrylate and methacryloxysulfolane (Glubran 2), 1 ml, diluted with Lipiodol, 1 ml, was injected in aliquots of 1 ml per injection and up to 4 ml at each lesion (▶ **Fig. 3**). No complications occurred. At 6-month follow-up the patient had no anemia.

Case 2. An 11-year-old girl with BRBNS was addressed for hematochezia due to colonic blebs. Colonoscopy revealed a bleeding lesion at the cecum (▶ **Fig. 4**).

After initial failure to stop the bleeding with a hemostatic grasper (Coagrasper, Olympus), Glubran 2 was injected successfully. Two more blebs of the right colon were treated similarly. After 2 years the patient remained asymptomatic.

This document was downloaded for personal use only. Unauthorized distribution is strictly prohibited.

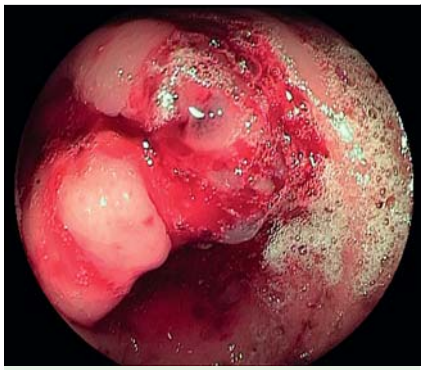

Fig. 4 Case 2. Bleeding hemangioma of the cecum near the ileocecal valve.

BRBNS is a rare condition characterized by multiorgan cavernous hemangiomas. Gastrointestinal bleeding is the major problem, and several endoscopic therapeutic approaches have been proposed: Nd:YAG laser, bipolar or argon plasma coagulation, band ligation, snare resection, and sclerotherapy [1–4]. Our patients were treated successfully by Glubran 2 injection, commonly used in the management of gastric varices. Endoscopic obliteration of cavernous hemangiomas with n-butyl-2-cyanoacrylate (Histoacryl) has been previously described, in the rectum [5]. However, these appear to be the first cases of cyanoacrylate glue injection to control bleeding in the small bowel and colon in the setting of BRBNS.

Endoscopy_UCTN_Code_TTT_1AO_2AD

Competing interests: None

G. Mavrogenis[1], D. Coumaros[1], D. Tzilves[1], E. Rapti[1], G. Stefanidis[2], J. Leroy[3], F. Becmeur[4]

[1] Department of Gastroenterology, University Hospital, Strasbourg, France
[2] Department of Gastroenterology, Athens Naval Hospital, Athens, Greece
[3] Department of Digestive Surgery, University Hospital, Strasbourg, France.
[4] Department of Pediatric Surgery, University Hospital, Strasbourg, France

References

1 *Shahed M, Hagenmüller F, Rösch T et al.* A 19-year-old female with blue rubber bleb nevus syndrome. Endoscopic laser photocoagulation and surgical resection of gastrointestinal angiomata. Endoscopy 1990; 22: 54–56
2 *Maunoury V, Turck D, Brunetaud JM et al.* Blue rubber bleb nevus syndrome. 3 cases treated with a Nd:YAG laser and bipolar electrocoagulation [in French with English abstract]. Gastroenterol Clin Biol 1990; 14: 593–595
3 *Bak YT, Oh CH, Kim JH.* Blue rubber bleb naevus syndrome: endoscopic removal of the gastrointestinal hemangiomas. Gastrointest Endosc 1997; 45: 90–92
4 *Arguedas MR, Wilcox CM.* At the focal point. Blue rubber bleb nevus syndrome. Gastrointest Endosc 1999; 50: 544
5 *Zurakowski J, Swiercz P, Wróblewski T et al.* Diffuse cavernous hemangioma of rectosigmoid colon treated with n-butyl-2-cyanoacrylate injections. Endoscopy 2008; 40: E120–121

Bibliography

DOI 10.1055/s-0030-1256425
Endoscopy 2011; 43: E291–E292
© Georg Thieme Verlag KG Stuttgart · New York ·
ISSN 0013-726X

Corresponding author

D. Coumaros, MD
IRCAD/EITS
University Hospital
1 Place de l'Hôpital
67091 Strasbourg
France
Fax: +33-3-88751521
coumarosd@wanadoo.fr

This document was downloaded for personal use only. Unauthorized distribution is strictly prohibited.