

Endoscopic ultrasound-guided transgastric pancreatic duct drainage after Whipple surgery in a patient with chronic pancreatitis

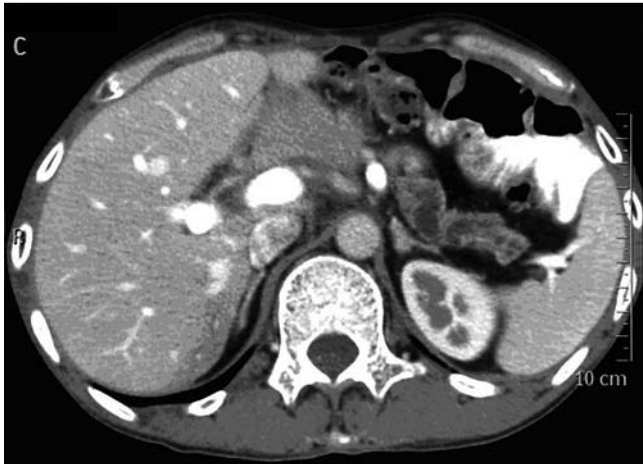

Fig. 1 Computed tomography (CT) image showing the severely dilated pancreatic duct before the endoscopic ultrasound (EUS)-guided pancreatic duct drainage.

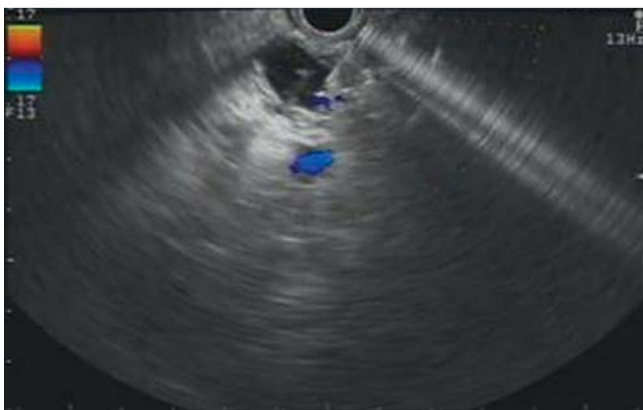


Fig. 3 Endoscopic ultrasound (EUS) image of the main pancreatic duct punctured by the 19-gauge needle.

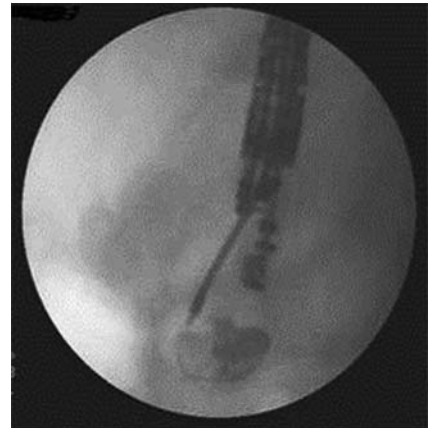

Fig. 2 Radiographic image showing the main pancreatic duct punctured by the 19-gauge needle.

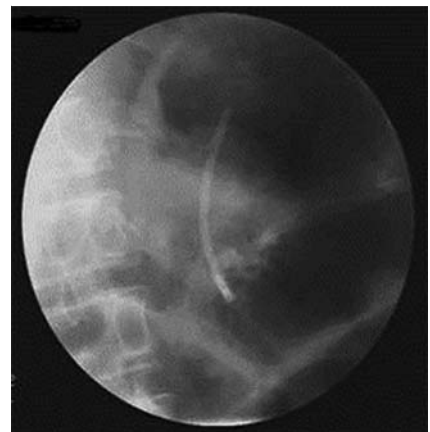


Fig. 4 Radiographic image of the stent inserted in the main pancreatic duct.

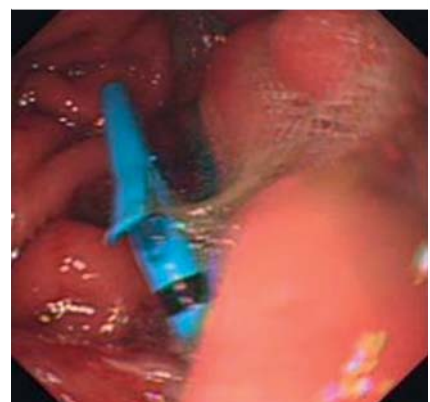


Fig. 5 Endoscopic image showing the stent visible in the posterior gastric wall.

A 34-year-old Chinese man was admitted for repeated episodes of diarrhea and abdominal pain following a Whipple procedure for a duodenal stromal tumor. Computed tomography (CT; [● Fig. 1](#)) and magnetic resonance cholangiopancreatography (MRCP) were performed and revealed a severely dilated pancreatic duct after the procedure.

It was possible that endoscopic retrograde cholangiopancreatography (ERCP) would be unsuccessful because of postoperative anomalies, and the patient rejected surgery. Endoscopic ultrasound (EUS)-guided transgastric drainage of the main pancreatic duct was therefore performed. An echo endoscope was introduced into the stomach and EUS demonstrated that the main pancreatic duct was severely dilated. The duct was punctured with a 19-gauge needle through the posterior gastric wall ([● Figs. 2 and 3](#)); pancreatic juice

was aspirated; and a 0.035-inch guide wire was inserted.

The gastric wall was incised by the wire-guided needle-knife, and a 7-Fr Soehendra dilator was used to dilate the gastropancreatic fistula. Finally, a 5-cm long plastic 7-Fr double-pigtail stent was inserted into the main pancreatic duct under fluoroscopic guidance ([● Figs. 4 and 5](#)).

There were no complications and the dilation of the pancreatic duct resolved, with gradual disappearance of the abdominal pain. During follow-up at 14 weeks, CT scan showed no recurrence of the pancreatic duct dilatation ([● Fig. 6](#)).

Although a year later gastroscopy has revealed that the stent is no longer in place, fortunately the fistula cannot be found; the patient has gained weight and is free of abdominal pain.

It has been proposed that EUS-guided drainage of the main pancreatic duct

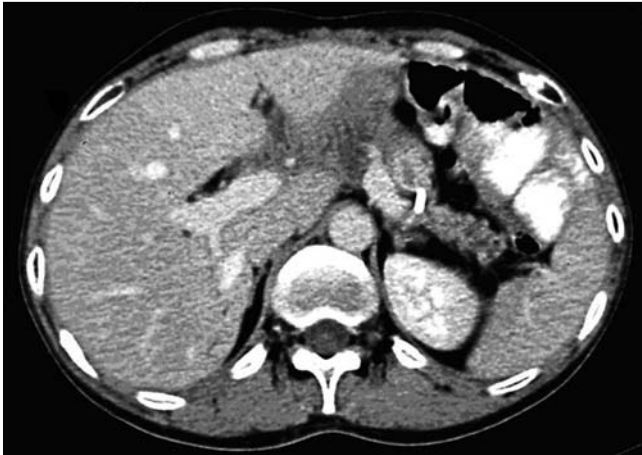

Fig. 6 Computed tomography (CT) image showing no recurrence of the pancreatic duct dilatation after the EUS-guided pancreatic duct drainage.

could be an effective treatment option for those patients who were high risk surgical candidates and in whom ERCP had been technically unsuccessful [1,2]. On the basis of this report, treatment of chronic pancreatitis after Whipple procedure with dilated pancreatic duct by EUS-guided transgastric direct drainage of the main pancreatic duct is technically feasi-

ble and may be effective. However long-term assessment is required as to whether the patient will need a further drainage procedure if the pancreatic duct again becomes dilated.

Endoscopy_UCTN_Code_TTT_1AR_2AI

Competing interests: None

C. Sun*, Z.-D. Jin*, X. Pan, D. Wang, Z.-S. Li

Department of Gastroenterology, Changhai Hospital, Second Military Medical University, Shanghai, China

References

- 1 Kahaleh M, Yoshida C, Yeaton P. EUS ante-grade pancreatography with gastropancreatic duct stent placement: review of two cases. *Gastrointest Endosc* 2003; 58: 919–923
- 2 Varadarajulu S, Trevino JM. Review of EUS-guided pancreatic duct drainage. *Gastrointest Endosc* 2009; 69: 200–202

Bibliography

DOI 10.1055/s-0030-1256298

Endoscopy 2011; 43: E182–E183

© Georg Thieme Verlag KG Stuttgart · New York · ISSN 0013-726X

Corresponding author

Z.-S. Li, MD

Department of Gastroenterology
Changhai Hospital
Second Military Medical University
168 Chang Hai Road, Shanghai
China

Fax: +86-21-55620081

zhсли@81890.net

* C. Sun and Z.-D. Jin are the co-first authors.