

Bleeding hepaticojejunostomy anastomotic varices successfully treated with Histoacryl injection, using single-balloon enteroscopy

A 29-year-old, 31-week pregnant woman presented to our department with recurrent lower gastrointestinal bleeding. Her past history was remarkable for a choledochal cyst excision with hepaticojejunostomy 2 years ago. Intermittent massive bleeding started 6 months after the surgery for which the patient received blood transfusions as the source of the bleeding was not identified. On examination the stools were maroon colored stool but there was no hematemesis. The blood tests were negative for hypercoagulable factors. Esophagogastroduodenoscopy revealed few small esophageal varices and one small gastric varix, without bleeding stigmata, while a colonoscopy was normal. The patient's pregnancy was terminated at 34 weeks because of the recurrent lower gastrointestinal bleeding. Anastomotic varices were suspected to be the source of the bleeding, and thus, single-balloon enteroscopy was carried out. The enteroscopy revealed multiple varices with white and red nipple signs around the hepaticojejunostomy anastomotic site (▶ Fig. 1).

A total of 3 mL of glue mixture (0.5 mL of *N*-butyl-2-cyanoacrylate [Histoacryl] and 0.8 mL of Lipiodol) was injected at the varices under fluoroscopic guidance (▶ Figs. 2, 3). The patient underwent computed tomography (CT) for portal vein evaluation, which showed embolic glue material in liver parenchyma, small portal vein branches, and multiple filling defects in branches of the superior mesenteric vein (SMV) that were hyperdense in the contrast phase, suggestive of acute SMV branch thrombosis. The patient developed moderate abdominal discomfort without elevation of liver enzymes, but the pain disappeared within few days of conservative management. The patient continues to be free from abdominal pain and bleeding, and a 3-month follow-up single-balloon enteroscopy revealed no residual anastomotic varices (▶ Fig. 4).

Anastomotic varix is an uncommon form of ectopic bleeding varices [1]. In our case, endoscopic treatment with glue injection was the preferred treatment for this type of varices [2,3]. There have been no prior reports of Histoacryl injection using a single-balloon enteroscope. This

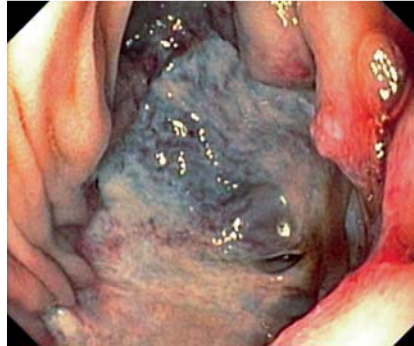


Fig. 1 White and red nipple signs of bleeding anastomotic varices.

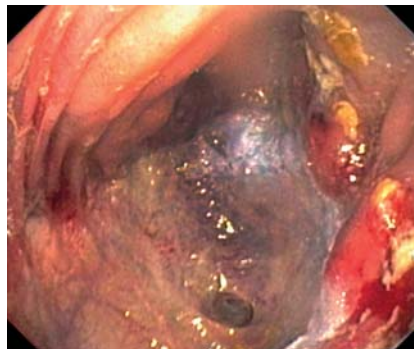


Fig. 2 Image taken after Histoacryl injection at the varices.

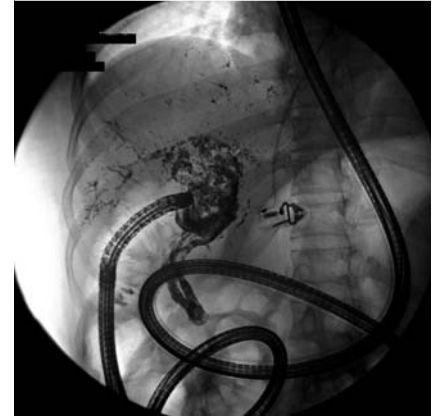


Fig. 3 Computed tomography (CT) scan showed multiple foci of glue material in the portal vein branches.

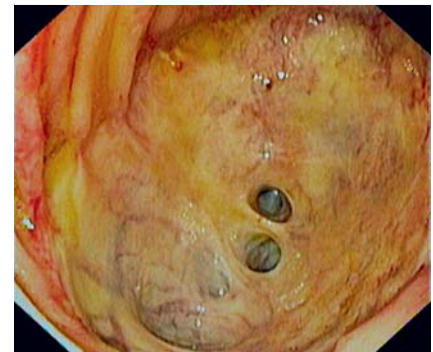


Fig. 4 The latest enteroscopy, showing no residual varices after treatment.

technique makes it relatively easy to diagnose and treat deep small-bowel lesions with minimal complications.

Endoscopy_UCTN_Code_TTT_1AP_2AD

Competing interests: None

V. Prachayakul, P. Aswakul, U. Kachintorn

Department of Internal Medicine, Siriraj Hospital, Bangkoknoi, Bangkok, Thailand

References

- 1 Watanabe N, Toyonaga A, Kojima S *et al*. Current status of ectopic varices in Japan: Results of a survey by the Japan Society for Portal Hypertension. *Hepatol Res* 2010; 40: 763–776
- 2 Ahmed H, Khalid A, Mohamed A. Updates in the pathogenesis, diagnosis and management of ectopic varices. *Hepatol Int* 2008; 2: 322–334
- 3 Deepak K, Sharma B, Sriram P. Endoscopic management of bleeding ectopic varices with histoacryl. *HBP Surg* 1999; 11: 171–173

Bibliography

DOI 10.1055/s-0030-1256233

Endoscopy 2011; 43: E153

© Georg Thieme Verlag KG Stuttgart · New York · ISSN 0013-726X

Corresponding author

P. Aswakul

Siriraj Endoscopy Center – Internal Medicine

Siriraj Hospital

Bangkoknoi

Bangkok

Thailand 10700

Fax: +66-24-299672

asawakul@gmail.com