A new traction device for facilitating endoscopic submucosal dissection (ESD) for early gastric cancer: the "medical ring"



Fig. 1 The "medical ring" has a diameter of 6 mm, a width of 2 mm, and a thickness of 200 µm. It is white in color to ensure the highest level of visibility.



Fig. 2 For mounting, the ring is attached to a hemoclip with 3-0 silk.

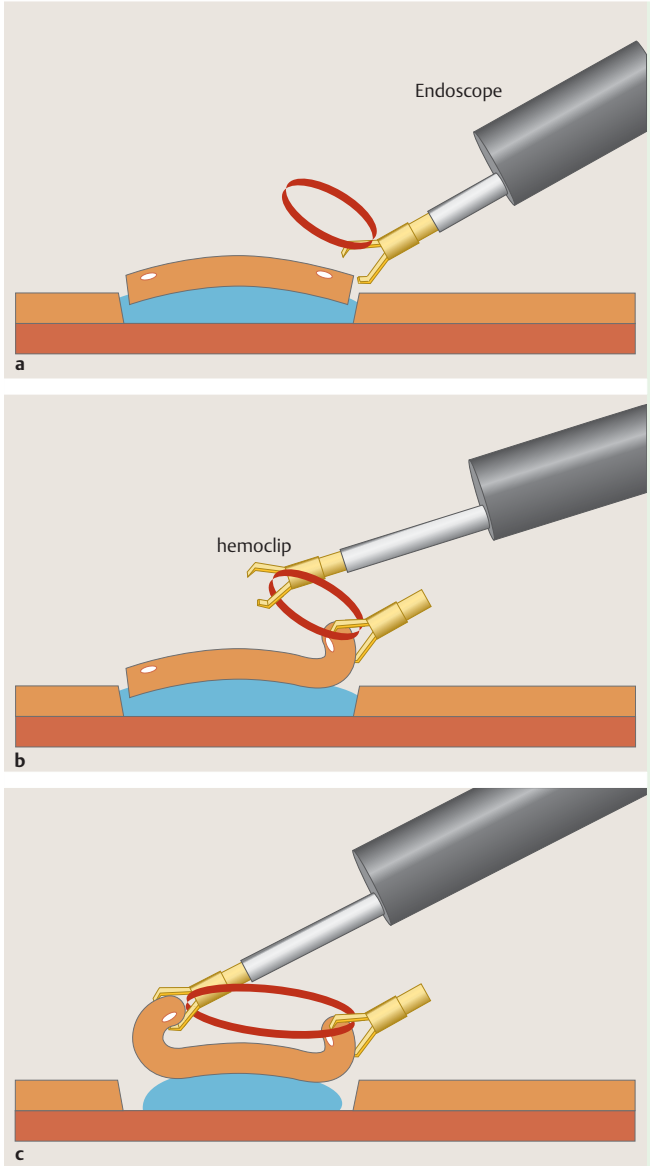

Fig. 3 **a** The circumference of the target tumor is marked with dots, thereby clearly outlining the margin of the lesion. After injection of a saline solution into the submucosa, the tumor margin is separated from the surrounding normal mucosa by making a complete incision within the mucosa around the lesion using the IT knife. **b, c** The device is clipped to the freed mucosal edge at two opposite sides of the lesion, which pulls up the lesion and opens up the resection margin.

The main factor that make endoscopic submucosal dissection (ESD) a difficult procedure is the risk associated with cutting along the line of the submucosal layer blind: the cut edge of the lesion curls inwards and obscures the endoscopist's view. Several methods have been devised to facilitate visibility [1–3], however, no devices have yet been developed that meet the demands of convenience, cost, sterility, and safety. Furthermore, most devices lift up only one part of a lesion, which means that resection can only be carried out from one side; their use is also limited depending on the tumor's location [4]. We have designed a new traction device which employs a bilateral approach ("medical ring"; Okamoto Co. Ltd, Tokyo, Japan) (▶ **Fig. 1**). The device comprises an inert elastic band, which is made of the same material as used in several medical devices including the endoscopic variceal ligation O-ring. The device is mounted by connecting it with 3-0 silk to a hemoclip (HX 610-090; Olympus Optical Co. Ltd, Tokyo, Japan) (▶ **Fig. 2**). It is stored in a sheath, which opens and elongates when wet. The device can be passed through the instrument channel of a standard endoscope. The ESD procedure using the device is illustrated in ▶ **Fig. 3**

Video 1

Medical ring-assisted endoscopic submucosal dissection of an early gastric cancer lesion.

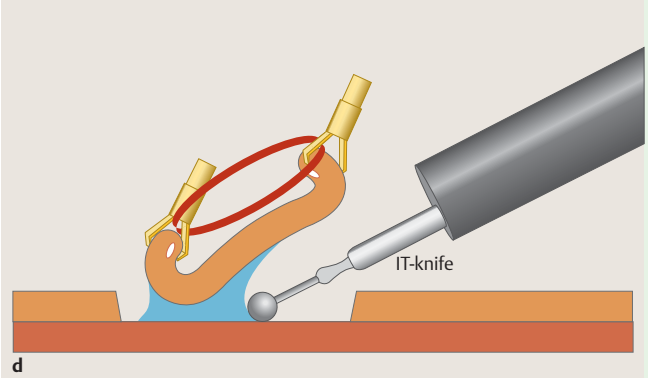

d The dissection can now be carried out speedily due to the tension in the elastic material, which maintains the upward reflection of the resection margins.

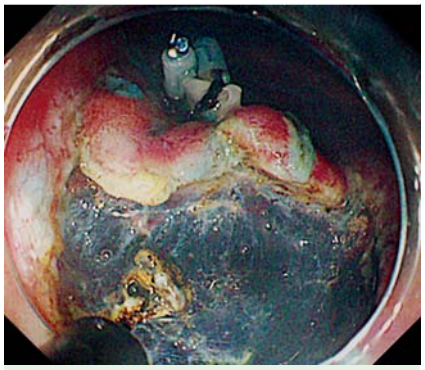

Fig. 4 Early gastric carcinoma (0-IIc). The tension in the medical ring allows full visualization of the submucosal layer and speedy dissection.

and ▶ **Video 1**. The lesion is pulled up, opening the resection margin, and dissection can then be carried out quickly as the tension in the elastic material helps maintain visibility of the margin throughout the procedure (▶ **Fig. 4**). In the illustrated case, the size of the resected lesion was 40 mm and the dissection time was 12 min. The device is recoverable with the resected lesion, and can be easily removed with forceps. With this medical ring, the ESD method can be safely and easily carried out while maintaining direct vision of the resected site. This method is also potentially applicable in the resection of esophageal and colorectal lesions.

Endoscopy_UCTN_Code_TTT_1AO_2AG

Competing interests: None

K. Matsumoto, A. Nagahara, N. Sakamoto, M. Suyama, H. Konuma, T. Morimoto, E. Sagawa, H. Ueyama, T. Takahashi, K. Beppu, T. Shibuya, T. Osada, T. Yoshizawa, T. Ogihara, S. Watanabe
Department of Gastroenterology,
Juntendo University School of Medicine,
Tokyo, Japan

References

1 *Tokumo H, Komatsu H, Ishida K et al.* Transgastrostomal endoscopic mucosal resection for the treatment of gastric mucosal lesions [in Japanese]. Gastroenterol Endosc 1997; 39: 1775 – 1780
2 *Gotoda T, Oda I, Tamakawa K et al.* Prospective clinical trial of magnetic-anchor-guided endoscopic submucosal dissection for large early gastric cancer. Gastrointestinal Endosc 2009; 69: 10 – 15
3 *Kume K, Yamasaki M, Yamasaki T et al.* Endoscopic hemostatic treatment under irrigation for upper GI hemorrhage: a comparison of one third and total circumference transparent end hoods. Gastrointest Endosc 2004; 59: 712 – 716
4 *Jeon WJ, You IY, Chae HB et al.* A new technique for gastric endoscopic submucosal dissection: peroral traction-assisted endoscopic submucosal dissection. Gastrointestinal Endosc 2009; 69: 29 – 33

Bibliography

DOI 10.1055/s-0030-1255923
Endoscopy 2011; 43: E67 – E68

ISSN 0013-726X

Corresponding author

K. Matsumoto
Department of Gastroenterology
Juntendo University School of Medicine
2-1-1 Hongo
Bunkyo-ku
Tokyo 113-8421
Japan
Fax: +81-3-3813-8862
kmatumo@juntendo.ac.jp