

Small-bowel perforation in a patient with Roux-en-Y anatomy for Peutz–Jeghers polyps after spiral enteroscopic investigation

Spiral enteroscopy is a new technique for diagnosis and treatment of small-bowel disease. In July 2009, a 19-year-old woman with Peutz–Jeghers syndrome was sent to our hospital for screening and treatment. The patient had undergone segmental resection of the distal jejunum, 4 years previously, for acute intestinal obstruction due to large Peutz–Jeghers polyps.

After informed consent had been obtained, we chose antegrade spiral enteroscopy for small-bowel investigation. The procedure was performed under monitored anesthesia. A standard Fujinon EN-450P5 enteroscope with an Endo-Ease Discovery SB overtube was used. The insertion depth of the enteroscope was about 220 cm beyond the ligament of Treitz. The duration of the procedure was 44 min.

During the investigation, a normal Roux-en-Y anastomotic stoma was found at about 200 cm beyond the ligament of Treitz (● Fig. 1), and eight IIa-type hyperplastic polyps of size 3–8 mm were found nearby. Argon plasma coagulation (APC) was used for treatment of these polyps. The procedure of investigation and treatment was successful, and no bleeding occurred. However, the patient experienced severe abdominal pain after 2 h. The abdominal computed tomography (CT) scan showed pneumoperitoneum. During emergent surgery, a perforation of 15 mm was seen at the anastomotic stoma, and intraperitoneal adhesion was severe. The patient was clinically stable after repair of the perforation, and was discharged 5 days later.

Diagnostic double-balloon enteroscopy (DBE) has an overall complication rate of 1.7% (perforation 0.3%, pancreatitis 0.3%, bleeding 0.8%). Therapeutic DBE has a relatively high complication rate of 4.3%

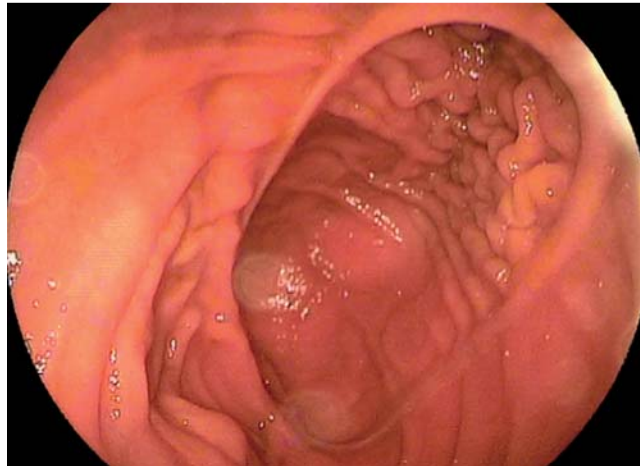


Fig. 1 Endoscopic view, showing the anastomotic stoma in the distal jejunum.

(APC perforation 1.2%, dilation perforation 2.9%) [1]. In patients with small-bowel anastomoses, perforations occur easily during diagnostic DBE procedures [2]. The rate of perforation after spiral enteroscopy is reported to be 0.34% [3]. Spiral enteroscopy has been successfully performed in patients with surgically altered anatomies [4], with no reports of perforation until now. In this case, perforation was found to have occurred because of prior surgery not therapeutic procedures. Avoiding excessive tension may help to limit complications including perforation.

Endoscopy_UCTN_Code_CPL_1AI_2AD

Competing interests: None

X.-B. Li^{1,2}, L.-Y. Gu¹, Y. Song¹, Y.-J. Gao¹, Z.-Z. Ge^{1,2}

¹ Department of Gastroenterology, Shanghai Renji Hospital, Shanghai Jiaotong University School of Medicine, Shanghai, China

² Shanghai Institute of Digestive Disease, Shanghai, China

References

- 1 Mensink PB, Haringsma J, Kucharzik T *et al*. Complications of double balloon enteroscopy: a multicenter survey. *Endoscopy* 2007; 39: 613–615
- 2 Semrad CE. Small-bowel enteroscopy: territory conquered, future horizons. *Curr Opin Gastroenterol* 2009; 25: 110–115
- 3 Akerman PA, Cantero D. Severe complications of spiral enteroscopy in the first 1750 patients. *Gastrointest Endosc* 2009; 69: AB127
- 4 Akerman PA, Agrawal D, Chen W *et al*. Spiral enteroscopy: a novel method of enteroscopy by using the Endo-Ease Discovery SB overtube and a pediatric colonoscope. *Gastrointest Endosc* 2009; 69: 327–332

Bibliography

DOI 10.1055/s-0030-1255897

Endoscopy 2011; 43: E85

© Georg Thieme Verlag KG Stuttgart · New York · ISSN 0013-726X

Corresponding author

Z.-Z. Ge, MD

Department of Gastroenterology
Shanghai Renji Hospital
Shanghai Jiaotong University School of Medicine
Shanghai Institute of Digestive Disease
145 Shan-dong zhong Rd
Shanghai 200001
China
Fax: +86-21-68383015
zhizhengge@yahoo.com.cn