

Duodenum-penetrating toothpick with liver abscess: removal with single-balloon enteroscopy

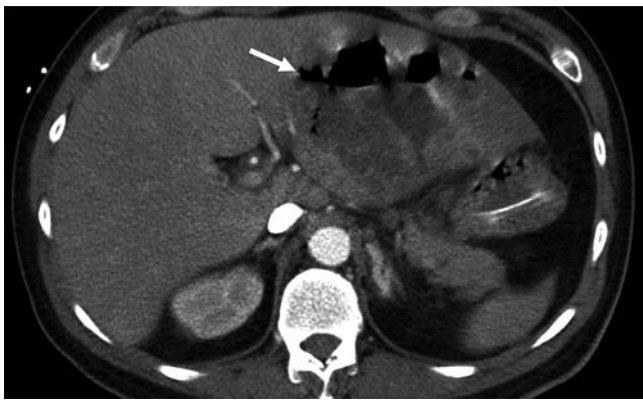

Fig. 1 Contrast-enhanced abdominal CT showed a large (11.2 cm diameter) liver abscess (arrow) in the left lateral segment of the liver with an internal air-fluid level.

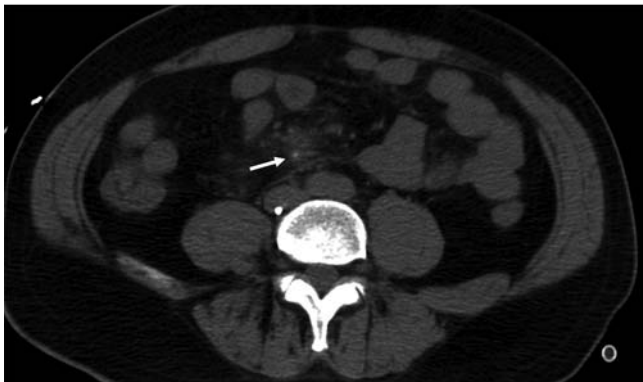

Fig. 2 Unenhanced abdominal CT demonstrated a hyperdense dot (arrow) with surrounding "dirty" fat.

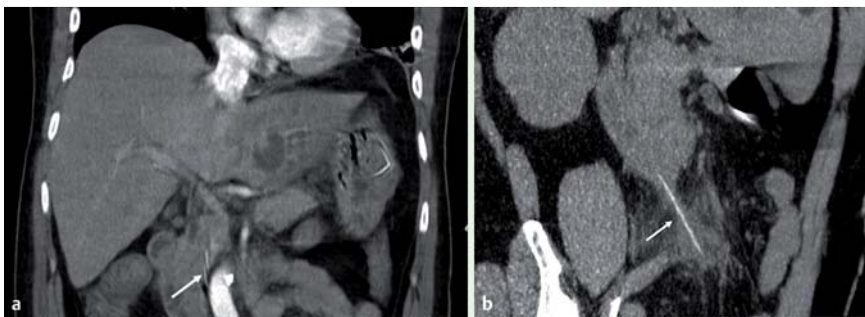


Fig. 3 **a** Coronal view of reformatted CT revealed a sharp object penetrating the wall of the third part of the duodenum. **b** Reformatted CT image delineated the contour of the toothpick.

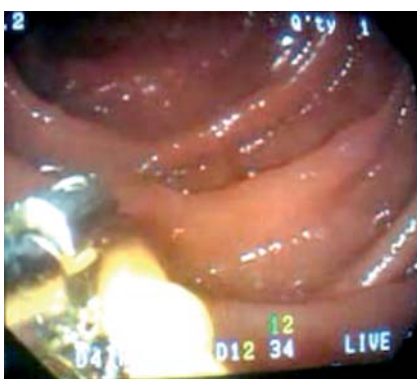

Fig. 4 The toothpick was removed by a grasping snare via single-balloon enteroscopy.

A 43-year-old man with a 1-month history of intermittent cramping upper abdominal pain visited our emergency department because of sudden onset of fever and chills. He had not previously had any underlying disease. On his arrival, physical examination revealed shortness of breath with hypotension and tachycardia. Laboratory data demonstrated leukocytosis with left shifting. Arterial blood gas measurement revealed metabolic acidosis. Elevated transaminases were noted. Contrast-enhanced axial computed tomography (CT) disclosed a huge liver abscess and a spotty hyperdensity (Fig. 1, 2).

Reformatted CT imaging revealed a 7-cm-long toothpick penetrating the wall of the third part of the duodenum (Fig. 3).

Our patient could not specifically recall having swallowed a toothpick. However, his wife told us that he had a habit of biting on a toothpick and falling asleep in his chair after eating dinner and watching TV. We speculated that the toothpick might have slipped into the gastrointestinal tract one day after he fell asleep and caused intermittent upper abdominal pain for 1 month followed by liver abscess. He was admitted to the intensive care unit immediately. Later, blood cultures yielded *Streptococcus anginosus* and *Eikenella corrodens*.

A CT-guided pig-tail catheter drained out much purulent pus from the liver abscess. The culprit behind the pyogenic liver abscess was believed to be ascending infection via portal venous blood from contaminated duodenal penetration by the inadvertently swallowed toothpick. After the patient's hemodynamics became stable, we performed single-balloon enteroscopy (SBE) via the oral route and successfully removed the toothpick using a grasping snare (Fig. 4, 5) in the third part of the duodenum, where ordinary esophagogastroduodenoscopy failed to reach.

The uniqueness of SBE is that the enteroscope can be smoothly withdrawn and detached from the outer overtube sheath. Therefore, the overtube was able to prevent the sharp toothpick from injuring the aerodigestive tract, or dropping into it, during removal. In addition, our case has implications for the expanded use of bedside balloon-assisted enteroscopy in the intensive care unit without the restraints imposed by the requirement for fluoroscopic facilities.

After appropriate antibiotic treatment, the patient was discharged uneventfully 1 month later.

Ingested foreign bodies in the intestines account for about 1% of intestinal perforations [1–3]. The case presented here might have been overlooked on ordinary axial CT, as the toothpick appeared just as a spotty hyperdensity (Fig. 2). Meanwhile, mixed-flora bacteremia showing the presence of *Streptococcus anginosus* and *Eikenella corrodens* should alert clinicians to the possibility of a culprit relating

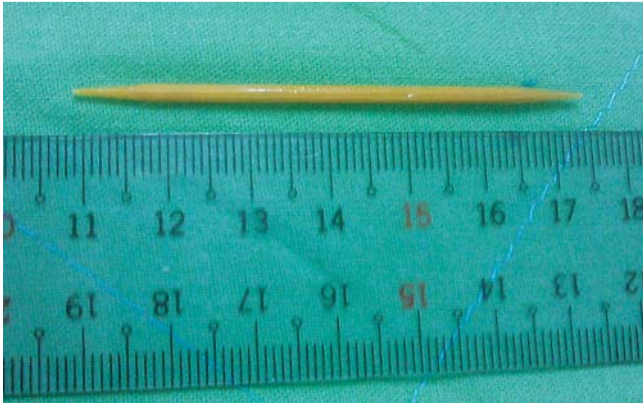


Fig. 5 The foreign body removed: a 7-cm-long wooden toothpick with two sharp ends.

to ingested foreign bodies [4]. Nearly all foreign bodies penetrating the duodenum and inducing liver abscess have been removed via laparotomy or autopsy [4]. However, balloon-assisted enteroscopy may offer a nonsurgical treatment to remove small intestinal foreign bodies, as exemplified by this case.

Endoscopy_UCTN_Code_TTT_1AO_2AL

Competing interests: None

M.-J. Hsieh¹, T.-C. Lee², C.-H. Tseng³, T.-H. Lin⁴, K.-L. Liu⁵, S.-Y. Chen¹, H.-P. Wang^{2,6}

¹ Department of Emergency Medicine, National Taiwan University Hospital and College of Medicine, National Taiwan University, Taipei, Taiwan

² Department of Internal Medicine, National Taiwan University Hospital and College of Medicine, National Taiwan University, Taipei, Taiwan

³ Division of Gastroenterology and Hepatology, Department of Internal Medicine, E-DA Hospital, Kaohsiung, Taiwan

⁴ Department of Traumatology, National Taiwan University Hospital and College of Medicine, National Taiwan University, Taipei, Taiwan

⁵ Department of Medical Imaging, National Taiwan University Hospital and

College of Medicine, National Taiwan University, Taipei, Taiwan

⁶ Division of Gastroenterology, Department of Internal Medicine, National Taiwan University Hospital Yun-Lin Branch, Yun-Lin, Taiwan

References

- 1 Velitchkov NG, Grigorov GI, Losanoff JE, Kjossev KT. Ingested foreign bodies of the gastrointestinal tract: retrospective analysis of 542 cases. *World J Surg* 1996; 20: 1001 – 1005
- 2 Shaw PJ, Feeman JG. The antemortem diagnosis of pyogenic liver abscess due to perforation of the gut by a foreign body. *Postgrad Med J* 1983; 59: 455 – 456
- 3 Maleki M, Evans WE. Foreign-body perforation of the intestinal tract. Report of 12 cases and review of the literature. *Arch Surg* 1970; 101: 474 – 477
- 4 Santos SA, Alberto SCF, Cruz E et al. Hepatic abscess induced by foreign body: case report and literature review. *World J Gastroenterol* 2007; 13: 1466 – 1470

Bibliography

DOI 10.1055/s-0030-1255804

Endoscopy 2011; 43: E11 – E12

© Georg Thieme Verlag KG Stuttgart · New York · ISSN 0013-726X

Corresponding author

H.-P. Wang, MD

Department of Internal Medicine
National Taiwan University Hospital
No. 7, Chung Shan S. Road
Taipei 100

Taiwan

Fax: +886-2-23947899

wanghp@ntu.edu.tw