

In vivo identification by confocal laser endoscopy of foamy macrophages associated with Whipple's disease

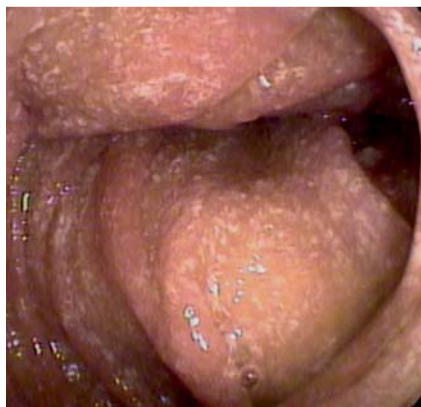

Fig. 1 Macroscopic appearance, showing whitish patterned duodenal mucosa.

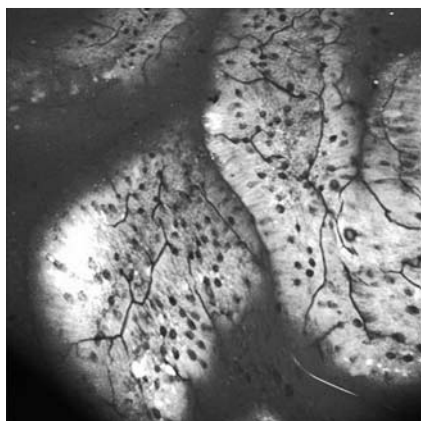


Fig. 2 Superficial endomicroscopy showing capillary leak in the duodenal mucosa.

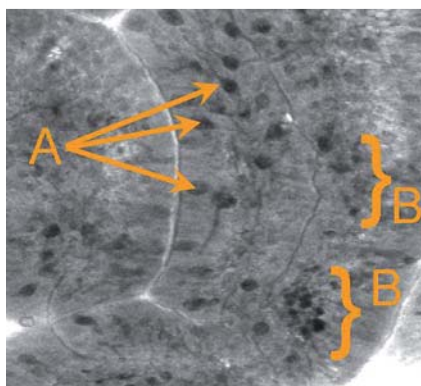


Fig. 3 Deep endomicroscopic image of the duodenal mucosa. A Goblet cells, B foamy macrophages within the lamina propria.

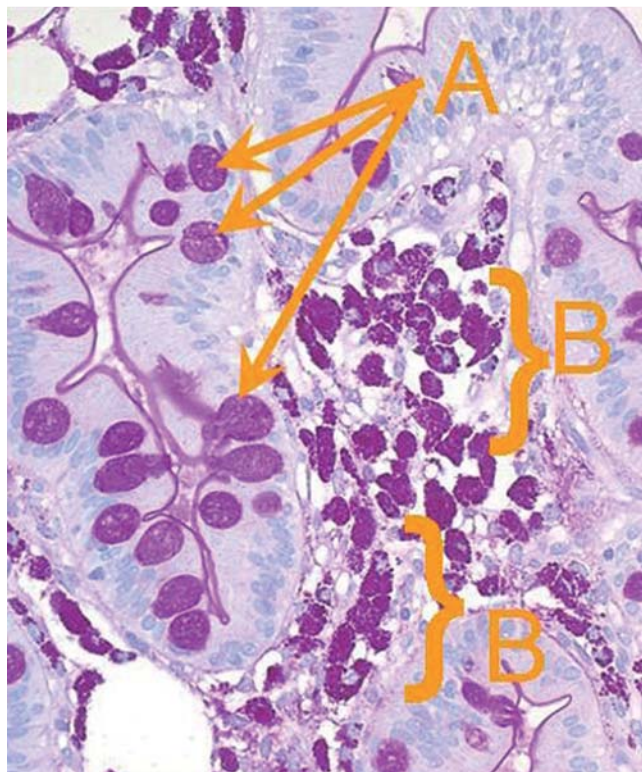


Fig. 4 Periodic acid-Schiff staining of a histological section of the duodenum. A Goblet cells, B foamy macrophages within the lamina propria.

Whipple's disease is a very rare illness caused by the actinobacterium *Tropheryma whippelii*. The diagnosis is confirmed by demonstration of macrophages staining positive in the periodic acid-Schiff (PAS) reaction in histological biopsy sections, but cannot be made on the basis of the macroscopic appearance during endoscopy [1,2]. We report the in vivo findings typical of Whipple's disease at the single cell level, captured by confocal laser endomicroscopy (CLE) in the duodenal mucosa of a 69-year-old woman with confirmed Whipple's disease.

Macroscopically, edematous duodenal villi were seen, diffusely patterned with small whitish dots (Fig. 1). Endomicroscopy showed massive capillary leak and a thickened epithelial layer, both unspecific signs of inflammation (Fig. 2).

Going into depth, several grouped cells (B in Fig. 3) appeared within the lamina propria, clearly distinguishable from single goblet cells (A in Fig. 3) in the surroundings.

Biopsies were taken from the locations observed by CLE. Directly linking in vivo findings to histological sections, we were able to identify the grouped cells as foamy macrophages which showed PAS-positive staining properties (Fig. 4), characteristic of Whipple's disease.

Zambelli et al. already reported CLE findings in Whipple's disease in 2008 [3]. While their case report mainly focused on tissue patterns, we were able to obtain CLE images at the single cell level, which may be partly attributed to improvements that have taken place in the meantime in the visual properties of the CLE technique. The identification of foamy macrophages within the lamina propria in vivo underlines the uniqueness of CLE, which depicts directly gastrointestinal pathologies that could formerly be evaluated only on the basis of biopsy results.

Competing interests: None

Endoscopy_UCTN_Code_CCL_1AB_2AZ_3AZ

W. Dolak¹, J. Leitner², J. Maresch³,
F. Wrba³, C. Mueller¹

¹ Department of Medicine III, Clinical
Division of Gastroenterology and Hepa-
tology, Medical University of Vienna,
Vienna, Austria

² Department of Medicine I, Clinical
Division of Infectious Diseases, Medical
University of Vienna, Vienna, Austria

³ Clinical Institute of Pathology, Medical
University of Vienna, Vienna, Austria

References

- 1 Fenollar F, Puéchal X, Raoult D. Whipple's disease. *N Engl J Med* 2007; 356: 55–66
- 2 Schöniger-Hekele M, Petermann D, Weber B, Müller C. *Tropheryma whipplei* in the environment: survey of sewage plant influxes and sewage plant workers. *Appl Environ Microbiol* 2007; 73: 2033–2035
- 3 Zambelli A, Villanacci V, Buscarini E et al. Confocal endomicroscopic aspects in Whipple's disease. *Gastrointest Endosc* 2008; 68: 373–374

Bibliography

DOI 10.1055/s-0030-1255809

Endoscopy 2010; 42: E310–E311

© Georg Thieme Verlag KG Stuttgart · New York ·
ISSN 0013-726X

Corresponding author

W. Dolak, MD

Medical University of Vienna
Department of Internal Medicine III
Clinical Division of Gastroenterology
and Hepatology
Währinger Gürtel 18–20
1090 Vienna
Austria
Fax: +43-1-404004735
werner.dolak@meduniwien.ac.at