Endoscopic removal of the Padlock-G clip

In recent years various new endoscopic closure techniques and devices have been developed [1]. Research has mainly been driven by the need for a secure and reliable closure for natural orifice transluminal endoscopic surgery (NOTES) [2]. At present, the clinical applicability of NOTES remains unclear, but research in this area has already immeasurably enriched our endoscopic armamentarium with regards to endoscopic closure of perforations [1,3,4].

Recently, two novel clipping devices have been developed, which are conceptually similar to endoscopic band ligation [3–5]. One of these devices is the Padlock-G clip (**Fig. 1**; Aponos Medical, Kingston, New Hampshire, USA), the feasibility of which has been demonstrated recently [5].

The closure mechanism consists of a 16.5-mm nitinol clip delivered via an over-the-scope delivery pod. Herein we report a technique that we have developed for the safe removal of this clip after it has been deployed.

In a 34-kg female domestic pig under general anesthesia, an 18-mm gastric wall opening was created using a needle knife and a dilation balloon. The Padlock-G clip was deployed after approximating the gastrotomy borders with a specialized tissue approximation grasper (Ovesco Endoscopy AG, Tübingen, Germany), thus creating a full-thickness closure of the defect (**Fig. 2a**, **Video 1**). Time to achieve endoscopic closure was 3 minutes.

For removal, a soft oval endoscopic snare (SD-210U-25, Olympus, Center Valley, Pennsylvania, USA) was used. By grasping two of the side bars, each anchoring pin of the clip can be pulled out of the tissue in a serial fashion and the clip can be removed with minimal tissue trauma (**Fig. 2b–d**, **Video 2**). Removal was facilitated within 1 minute and without complications.

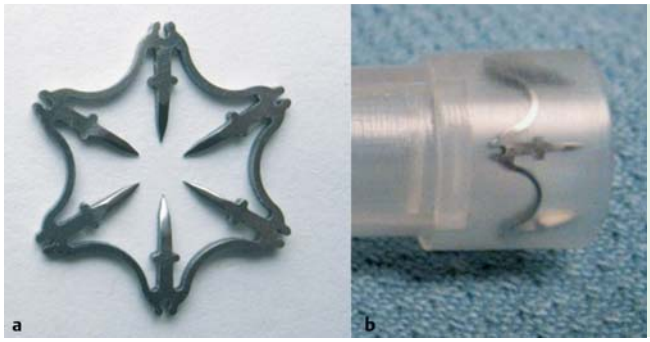

Fig. 1 Padlock-G clip closure device. **a** The clip; **b** the loaded clip on the applicator cap.

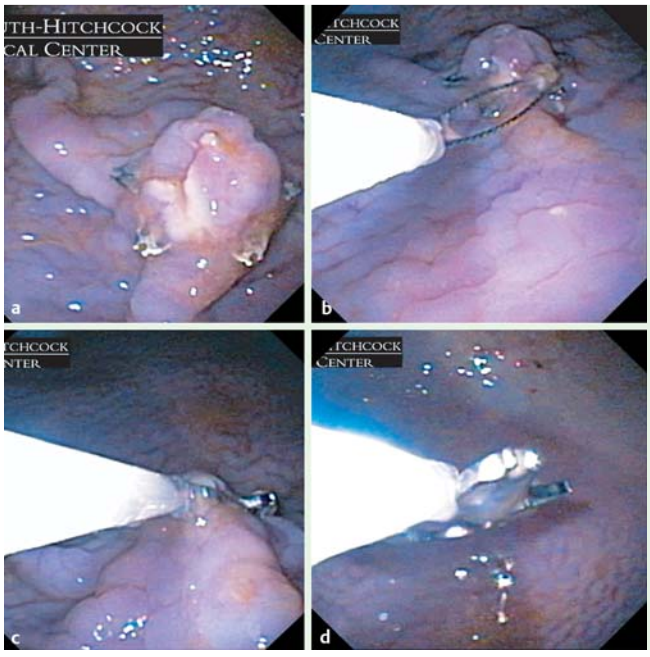

Fig. 2 Removal of the Padlock-G clip. **a** The Padlock-G clip closure of an 18-mm full-thickness gastric wall defect. **b–d** Padlock-G clip removal using a standard endoscopic snare. By grasping two of the side bars (**b**), each anchoring pin of the clip can be pulled out of the tissue (**c**) in a serial fashion and the clip is removed (**d**).

In conclusion, the novel Padlock-G clip seems to be a promising new device for endoscopic organ wall closure with the additional benefit of easy and swift endoscopic removal in cases of unsatisfactory or incomplete closure attempts.

Competing interests: None

Endoscopy_UCTN_Code_TTT_1AO_2AI

Video 1

Padlock closure of an 18-mm gastric wall defect.

Video 2

Technique of endoscopic Padlock removal.

D. von Renteln[1], M. C. Vassiliou[2], R. I. Rothstein[3]

[1] Department of Interdisciplinary Endoscopy, University Hospital Hamburg-Eppendorf, Hamburg, Germany

[2] Department of Surgery, McGill University Health Centre, Montreal, Quebec, Canada

[3] Section of Gastroenterology and Hepatology, Dartmouth-Hitchcock Medical Center, Lebanon, New Hampshire, USA

References

1 *Voermans RP, Worm AM, van Berge Henegouwen MI et al.* In vitro comparison and evaluation of seven gastric closure modalities for natural orifice transluminal endoscopic surgery (NOTES). Endoscopy 2008; 40: 595–601

2 ASGE/SAGES Working Group on Natural Orifice Translumenal Endoscopic Surgery. White Paper October 2005. Gastrointest Endosc 2006; 63: 199–203

3 *Renteln D von, Schmidt A, Vassiliou MC et al.* Endoscopic closure of large colonic perforations using an over-the-scope clip: a randomized controlled porcine study. Endoscopy 2009; 41: 481–486

4 *Renteln D von, Rudolph HU, Schmidt A et al.* Endoscopic closure of duodenal perforations by using an over-the-scope clip: a randomized, controlled porcine study. Gastrointest Endosc 2010; 71: 131–138

5 *Romanelli JR, Desilets DJ, Earle DB.* Natural orifice transluminal endoscopic surgery gastrotomy closure in porcine explants with the Padlock-G clip using the Lock-It system. Endoscopy 2010; 42: 306–310

Bibliography

DOI 10.1055/s-0030-1255620
Endoscopy 2010; 42: E241–E242

ISSN 0013-726X

Corresponding author

D. von Renteln, MD
Department of Interdisciplinary Endoscopy
University Hospital Hamburg-Eppendorf
Martinistr. 52
20251 Hamburg
Germany
Fax: +49-7141-997463
renteln@gmx.net