All that is red is not blood!

A 62-year-old woman presented for screening colonoscopy after a 24-hour clear-liquid diet and Colyte preparation. Frank blood was noted from the point of colonoscope insertion up to the terminal ileum (**Fig. 1 a**). Aspirate tested negative with the hemoccult card. Using narrow-band imaging (NBI) the "red liquid" appeared cyan blue (**Fig. 1 b**). Upon further questioning during recovery, the patient reported eating red jello.

NBI is an alternative light-wavelength capture system that filters light in the visible spectrum, except for narrow bands in the blue and green wavelengths (415 nm and 540 nm, respectively) [1] (**Fig. 3**). The peak absorption spectrum of red dye is 502–518 nm and appears as a cyan color whereas oxyhemoglobin is absorbed at 415 nm and appears as dark maroon. As shown in **Figs. 1 a** and **2 a**, red jello and post-polypectomy bleeding appeared indistinguishable under white light. Even the most sophisticated of tools, NBI, has demonstrated here a simple clinical use in differentiating between blood and other

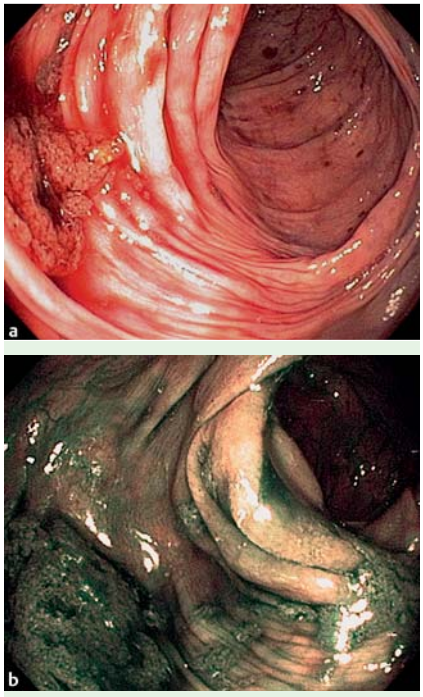

Fig. 1 Screening colonoscopy following ingestion of red jello. **a** Red liquid in colon lumen seen under white light. **b** Under the blue light of narrow-band imaging, the red dye in the jello (dye No. 40) appears blue–green.

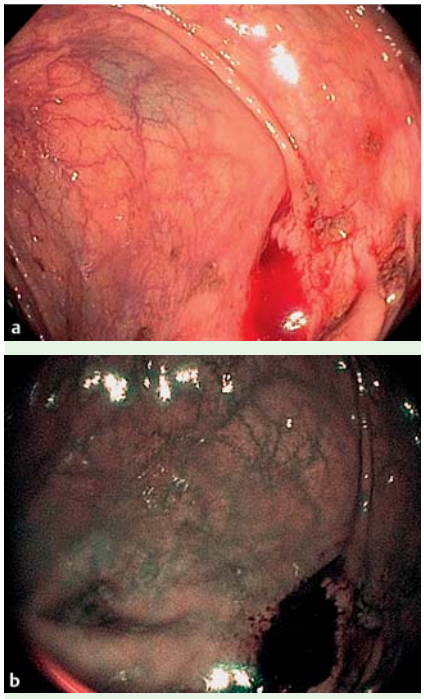

Fig. 2 Bleeding from recent polypectomy site. **a** Seen under white light. **b** Seen under blue light; note the dark maroon color of the blood.

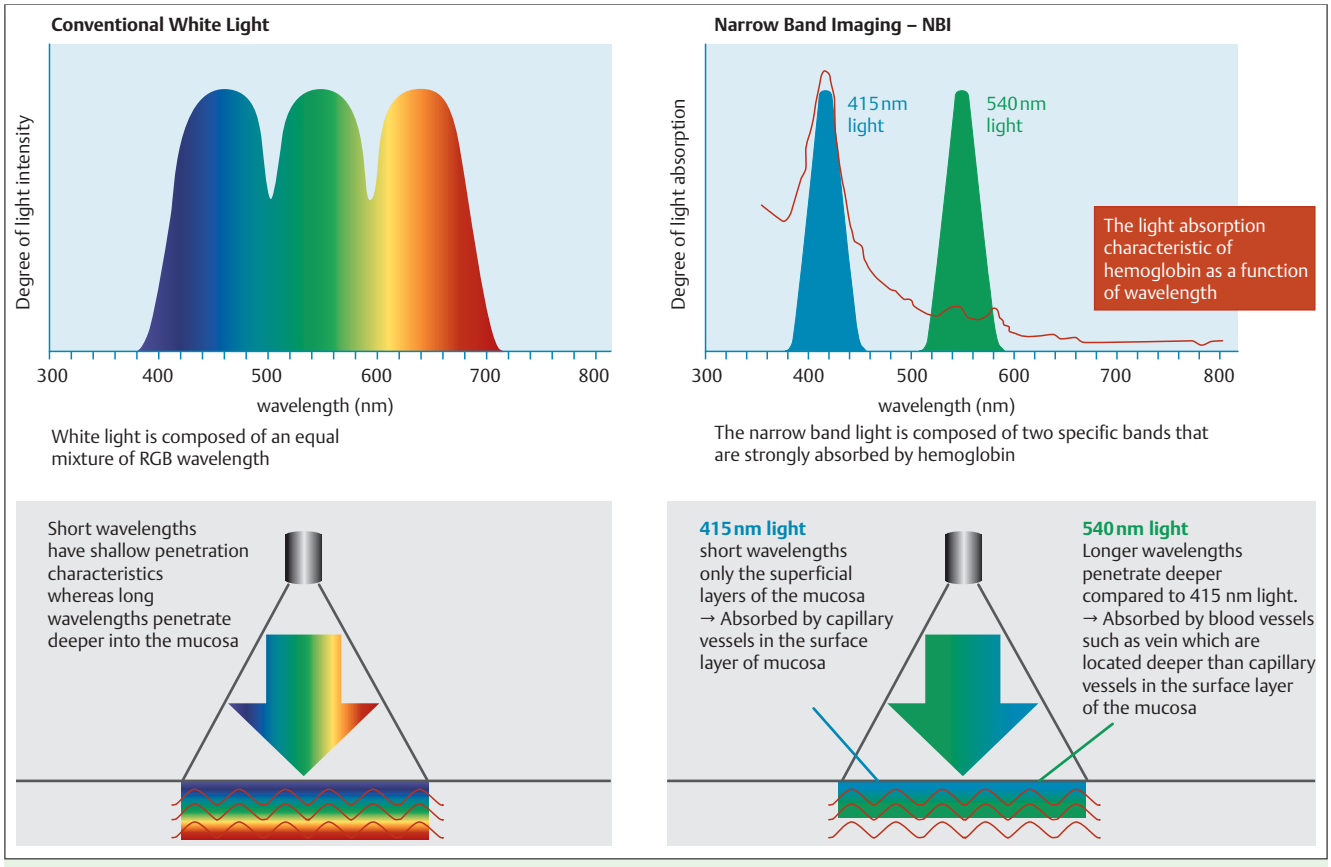

Fig. 3 Maximum absorptive capacity of hemoglobin at a wavelength of 415 nm. Adapted with permission from Olympus Europe (www.olympus-europa.com).

red substances. We suspect that this is not the first or the last case of "red jello stool" [2].

Competing interests: None

Endoscopy_UCTN_Code_CPL_1AJ_2AI

A. Soloman, M. Merheb, D. R. Ferguson
Division of Gastroenterology, MetroHealth Medical Center, Case Western University, Cleveland, Ohio, USA

References

1 *Kuznetsov K.* Narrow-band imaging: potential and limitations. Endoscopy 2006; 38: 76 – 81
2 *Sullivan SN.* Red jello stool and red dye-arrhea. J Clin Gastroenterology 1993; 16: 178

Bibliography
DOI 10.1055/s-0029-1244119
Endoscopy 2010; 42: E229 – E230

ISSN 0013-726X

Corresponding author
A. Soloman, DO
Division of Gastroenterology,
MetroHealth Medical Center,
Case Western University
2500 MetroHealth Dr.
Cleveland
OH 44109
USA
Fax: +1-216-778-4873
asoloman@metrohealth.org