Modified rendezvous technique with successful reconnection of completely transected common bile duct using combined endoscopic and radiologic approach

Fig. 1 Scout radiograph from initial endoscopic retrograde cholangiographic pancreatography (ERCP) showing disruption of the common bile duct into a subhepatic cavity.

Fig. 2 Scout radiograph from initial percutaneous transhepatic cholangiography (PTC) showing complete transection of the proximal common bile duct.

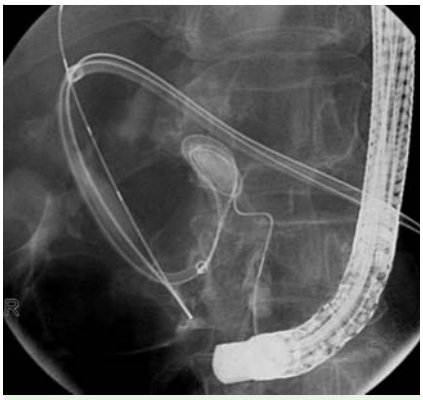

Fig. 3 Scout radiograph from combined ERCP and PTC. A sheath has been passed through the percutaneous tract into the biloma. A snare is open and adjacent to the endoscopic guide wire.

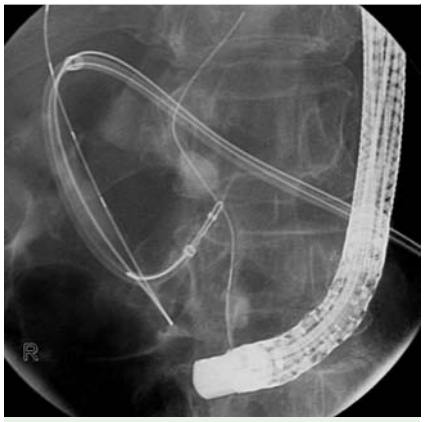

Fig. 4 Radiograph showing successful grasping of the biliary wire within the biloma.

Fig. 5 A catheter has been passed percutaneously over the guide wire; note the guide wire is still within the endoscope.

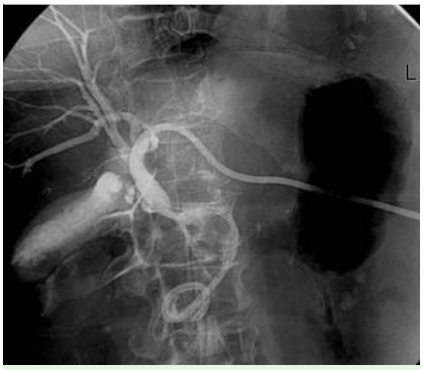

Fig. 6 Final image after removal of the endoscope. The internal/external locking loop catheter is in good position.

A 75-year-old woman underwent emergent Billroth I gastrectomy for perforated peptic ulcer. Postoperatively, she developed progressive jaundice (total bilirubin 13 mg/dL). Abdominal CT scan showed moderate bile duct dilatation and abrupt transition of the proximal common bile duct to a normal caliber, with a small subhepatic fluid collection. ERCP showed extravasation of contrast from the common bile duct into the subhepatic space with no connection to the proximal biliary system (▶ **Fig. 1**). Percutaneous transhepatic cholangiography (PTC) showed complete obstruction of the proximal common bile duct (▶ **Fig. 2**). A biliary drainage catheter was advanced across the obstruction into the subhepatic space.

The next day a combined procedure was performed in the radiology suite with the patient supine and under general anesthesia. An ERCP was performed and the bile duct was cannulated. An angled 0.035-inch hydrophilic wire (Glidewire; Boston Scientific Corporation, Natick, Massachusetts, USA) was passed into the subhepatic space. From the percutaneous approach, a snare (Angiotech Medical Technologies, Gainesville, Florida, USA) was inserted through a sheath and used to grasp the endoscopic wire (▶ **Figs. 3** and **4**), which was then withdrawn externally. A 12-French catheter was inserted percutaneously (▶ **Figs. 5** and **6**) and internal biliary drainage was established. Six weeks later an elective open hepaticojejunostomy was performed.

Nonoperative management of complete bile duct transection is difficult but has been described. Although combined endoscopic and percutaneous methods are well known, the use of a common pathway outside the biliary tree to allow reconnection has been infrequently reported [1,2]. This modified rendezvous technique was performed with simultaneous endoscopic and percutaneous approaches and is useful for the nonoperative man-

agement of bile duct transection. In this case it allowed an elective, delayed reconstructive operation in a healed surgical bed, and also established physiologic internal biliary drainage, avoiding the nutritional and metabolic complications of external biliary diversion.

Competing interests: None

Endoscopy_UCTN_Code_TTT_1AR_2AI
Endoscopy_UCTN_Code_TTT_1AR_2AJ

A. Saleem[1], A. J. LeRoy[2], T. H. Baron[1]

[1] Division of Gastroenterology and Hepatology, Mayo Clinic, Rochester, Minnesota, USA

[2] Division of Vascular and Interventional Radiology, Mayo Clinic, Rochester, Minnesota, USA

References

1 *Wai CT, Ngoi SS, Goh PY et al.* Modified rendezvous technique in management of biliary leak in right lobe live donor liver transplant recipients. Surg Laparosc Endosc Percutan Tech 2009; 19: 143 – 145

2 *Aytekin C, Boyvat F, Yimaz U et al.* Use of the rendezvous technique in the treatment of biliary anastomotic disruption in a liver transplant recipient. Liver Transpl 2006; 12: 1423 – 1426

Bibliography

DOI 10.1055/s-0029-1244061
Endoscopy 2010; 42: E178 – E179

ISSN 0013-726X

Corresponding author

T. H. Baron, MD
Division of Gastroenterology and Hepatology
Mayo Clinic
200 First Street, SW
Charlton 8A
Rochester, MN 55905
USA
Fax: +1-507-266-3939
baron.todd@mayo.edu