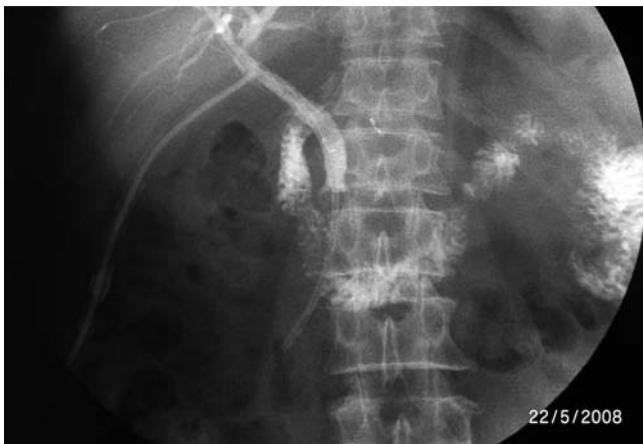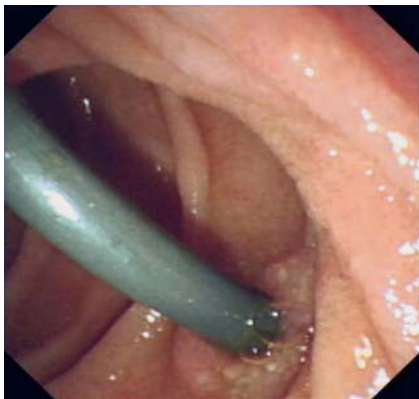


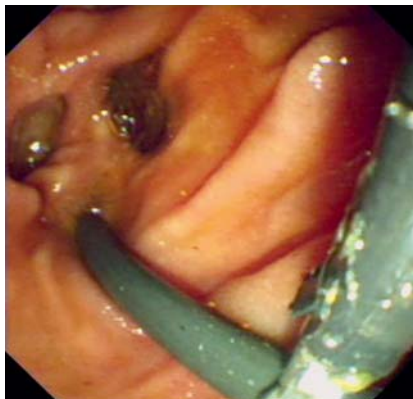
## Asymptomatic duodenal perforation from obstructed and migrated biliary stent



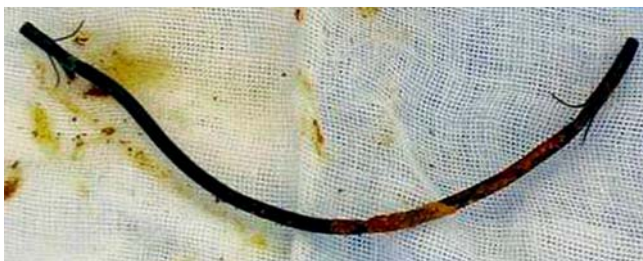**Fig. 1** T-tube tract cholangiography revealed the distal end of the biliary stent located 10 mm into the duodenal lumen.



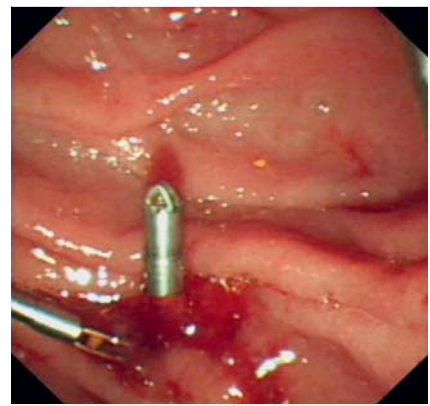
**Fig. 2** The distal part of the stent was found to protrude through the contralateral bowel wall of the duodenal papilla.



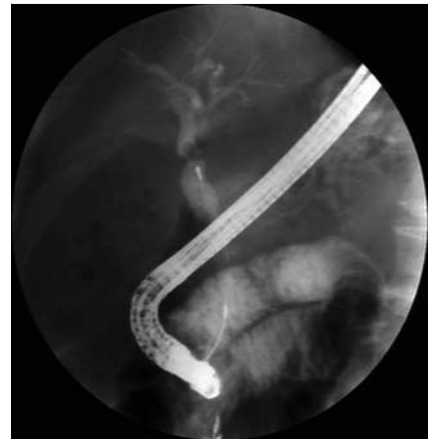**Fig. 3** The stent was retrieved using a rat tooth grasping forceps.



**Fig. 4** The plastic stent was found to be obstructed.



**Fig. 5** The perforation wound was clamped with a hemostatic clip.



**Fig. 6** Cholangiography disclosed severe filling defects in the common bile duct.

Endoscopic biliary stenting has become a principal management option in the treatment of pancreaticobiliary disease. Long-term complications include occlusion, migration, and dislocation [1–3]. Duodenal perforations caused during stent migration are rare but life-threatening [4], with complications including peritonitis, sepsis, retroperitoneal abscess, and duodenal fistulization [4–5]. This report describes an asymptomatic case of duodenal perforation caused by distal stent migra-

tion and successful retrieval of the migrated stent using an endoscope.

A 70-year-old man with a short history of jaundice underwent placement of an 8.5-Fr biliary stent for drainage at a local hospital. Meanwhile cholangiography disclosed evidence of hepatic portal filling defects. Several days later he underwent laparotomy, during which the biliary stent was neither found nor extracted. Frozen section detection did not show malignant tumor cell. Cholecystectomy was then per-

formed, and a T-tube was placed in the common bile duct (CBD). The patient made a good recovery. Twenty days later, T-tube tract cholangiography and computed tomography (CT) scan revealed the distal end of the biliary stent located 10 mm into the duodenal lumen (● Fig. 1).

This patient presented without any symptoms of stent perforation or gallstones during a 2-year period. More recently, he was admitted to our department to determine whether or not the stent had migrated. Under endoscopy, the distal part of the stent was found to penetrate the contralateral bowel wall of the duodenal papilla (● Fig. 2).

The proximal stent was in the CBD. The stent was retrieved using a rat tooth grasping forceps and found to be obstructed. The perforation wound was clamped with a hemostatic clip (● Figs. 3–5). Cholangiography disclosed severe filling defects in the CBD (● Fig. 6).

The stones were retrieved with a wire-guided basket.

In this case, the stent was obstructed before migration, so the bile could not evac-

uate to the abdominal cavity. This might explain why the patient was without symptoms after stent migration resulted in perforation. This novel consequence suggests that regular follow-up and CT scans are needed for asymptomatic patients with biliary stenting.

Endoscopy\_UCTN\_Code\_CPL\_1AK\_2AD

**Competing interests:** None

**H. Lin, Z. S. Li, X. B. Zhan**

Department of Gastroenterology,  
Changhai Hospital, Second Military  
Medical University, Shanghai, China

## References

- 1 *Libby ED, Leung JW.* Prevention of biliary stent clogging: a clinical review. *Am J Gastroenterol* 1996; 91: 1301–1308
- 2 *Arhan M, Odemiş B, Parlak E et al.* Migration of biliary plastic stents: experience of a tertiary center. *Surg Endosc* 2009; 23: 769–775
- 3 *Storkson RH, Edwin B, Reiertsen O et al.* Gut perforation caused by biliary endoprosthesis. *Endoscopy* 2000; 32: 87–89
- 4 *Saranga BR, Rao P, Ghosh K.* Iatrogenic duodenal perforations caused by endoscopic biliary stenting and stent migration: an update. *Endoscopy* 2006; 38: 1271–1274
- 5 *Basile A, Macri A, Lamberto S et al.* Duodenoscrotal fistula secondary to retroperitoneal migration of an endoscopically placed plastic biliary stent. *Gastrointest Endosc* 2003; 57: 136–138

## Bibliography

**DOI** 10.1055/s-0029-1215373  
*Endoscopy* 2011; 43: E40–E41  
© Georg Thieme Verlag KG Stuttgart · New York ·  
ISSN 0013-726X

## Corresponding author

**Z. S. Li, MD**

Department of Gastroenterology  
Changhai Hospital  
Second Military Medical University  
Shanghai 200433  
China  
Fax: +86-21-81873824  
zhsl@81890.net