

Splenic infarction after cyanoacrylate injection for fundal varices

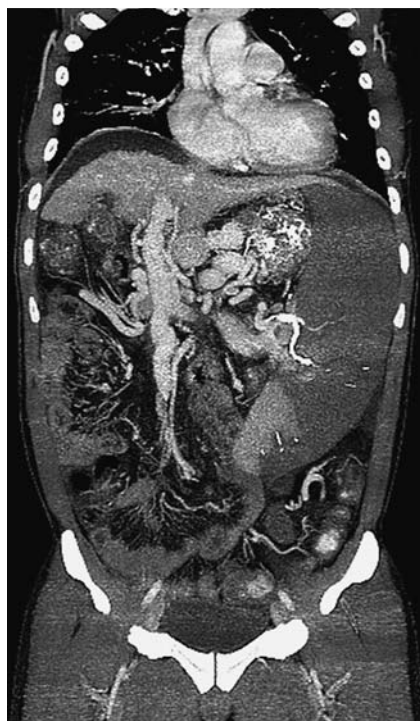

Fig. 1 Abdominal computed tomographic angiography showing multiple cyanoacrylate deposits along the splenic vein, and an enlarged spleen and unenhanced splenic parenchyma compatible with cyanoacrylate-induced splenic infarction.

A 43-year-old man with liver cirrhosis due to hepatitis B infection, who had undergone regular endoscopic variceal therapy for fundal varices, was admitted for secondary prophylaxis. The laboratory findings were unremarkable apart from a low platelet count ($34 \times 10^3/\mu\text{L}$) and prolonged prothrombin time (17.7 s, international normalized ratio [INR] 1.46, 59%). Endoscopic examination revealed small esophageal varices and large fundal varices with the red color sign. Two injections of 2 mL of *N*-butyl-2-cyanoacrylate (Histoacryl; B. Braun, Tuttlingen, Germany) diluted with Lipiodol (Guerbet, Aulnay Sous Bois, France) were administered into the fundal varices. The patient had undergone multiple sessions of endoscopic injection therapy in the past with no occurrence of complications. However, 2 days after the last endoscopic cyanoacrylate therapy, he developed abdominal pain and fever, and his white blood cell (WBC) count rose to

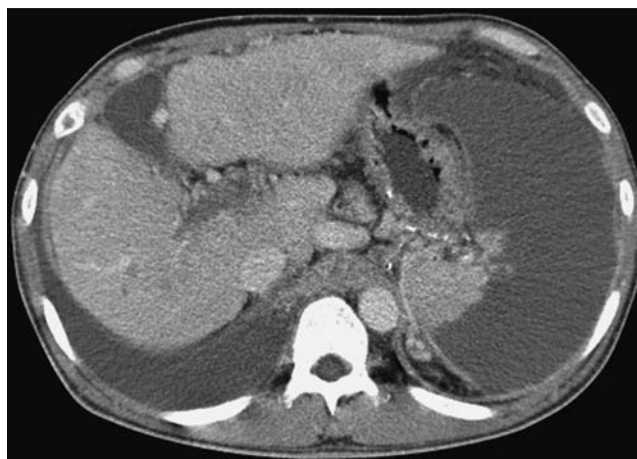


Fig. 2 Follow-up computed tomography scan showing remnants of cyanoacrylate within the splenic vein and persistent, large hypoattenuated lesions in the spleen.

$14 \times 10^3/\mu\text{L}$. Abdominal computed tomographic (CT) angiography revealed remnants of cyanoacrylate in the splenic vein with nonenhancing splenic parenchyma, suggestive of cyanoacrylate-induced splenic infarction (● Fig. 1).

Intravenous antibiotics were immediately initiated along with supportive management. Both the abdominal pain and fever gradually subsided and the WBC count normalized. The patient was discharged on day 20 in the hospital without any further complications or symptoms. A follow-up CT showed persistent, large, hypoattenuated lesions in the spleen, but the patient remained asymptomatic during the 9 months' follow-up in the outpatient department (● Fig. 2).

Endoscopic injection of cyanoacrylate is generally considered to be the usual treatment for gastric varices, but complications such as fever, deep ulceration, chest pain, and vascular occlusion can occur. Although splenic infarction after administration of cyanoacrylate is rare, it has been reported to occur when large volumes of cyanoacrylate are injected rapidly. This is because of the consequent splenic venous occlusion [1]. With adequate supportive management the splenic infarct can be left in situ. Its clinical course may be self-limiting and the patient may not require surgical treatment, such as splenectomy [2].

Competing interests: None

Endoscopy_UCTN_Code_CPL_1AH_2AC

J. Kim, H. J. Chun, J. J. Hyun, B. Keum, Y. S. Seo, Y. S. Kim, Y. T. Jeon, H. S. Lee, S. H. Um, C. D. Kim, H. S. Ryu

Department of Internal Medicine, Korea University College of Medicine, Institute of Digestive Disease and Nutrition, Seoul, Republic of Korea

Reference

- 1 Cheng PN, Sheu BS, Chen CY et al. Splenic infarction after Histoacryl injection for bleeding gastric varices. *Gastrointest Endosc* 1998; 48: 426–427
- 2 Jaroch MT, Broughan TA, Hermann RE. The natural history of splenic infarction. *Surgery* 1986; 100: 743–750

Bibliography

DOI 10.1055/s-0029-1243984

Endoscopy 2010; 42: E118

© Georg Thieme Verlag KG Stuttgart · New York · ISSN 0013-726X

Corresponding author

J. Kim

Korea University College of Medicine – Internal Medicine
Institute of Digestive Disease and Nutrition
126-1 Anam-dong 5-ga Seongbuk-gu
Seoul 136-705
Republic of Korea
Fax: +82-2-953-1943
moldkim@nate.com