

Pneumoscrotum associated with nontherapeutic lower gastrointestinal endoscopy

A 66-year-old man underwent flexible rectosigmoidoscopy due to anemia and rectal bleeding. The rectosigmoidoscopy showed blood oozing from third-degree hemorrhoids (● Fig. 1a). During the procedure the patient noticed swelling of his scrotum (● Fig. 1b); he then developed abdominal pain. A computed axial tomography scan confirmed subcutaneous emphysema and the presence of pneumoperitoneum, with air in the scrotum (● Fig. 2a), around the rectum (● Fig. 2b), in the retroperitoneum, and the perinephric (● Fig. 2c) as well as the paraesophageal (● Fig. 2d) spaces. Physical examination under general anesthesia revealed perforation of the rectum into the subcutaneous tissue adjacent to the hemorrhoids. After consultation with the surgeons, the patient was kept nil per os overnight. Antibiotics were administered (ciprofloxacin 200 mg i.v. bid, metronidazole 500 mg i.v. tid), and the pneumoscrotum resolved within 3 days. The patient's white blood cell count remained stable. After 3 days, the patient was started on a full liquid diet and then advanced to a regular diet. He was discharged uneventfully after 4 days in hospital.

Subcutaneous or retroperitoneal air that dissects into the dartos lining of the scrotal wall or movement of air from the intraperitoneal space into the scrotum may result in pneumoscrotum. Local gas production is another mechanism that suggests anaerobic infection, requiring urgent surgical interventions [1]. In the literature there are only seven cases of pneumoscrotum following lower gastrointestinal endoscopy [2–8]. Four of these patients had undergone polypectomy [2–5], one had undergone endoscopic mucosal resection for a tumor [6], and one with ulcerative colitis had undergone biopsy [7]. To the best of our knowledge, our case is only the second one reported in the literature involv-

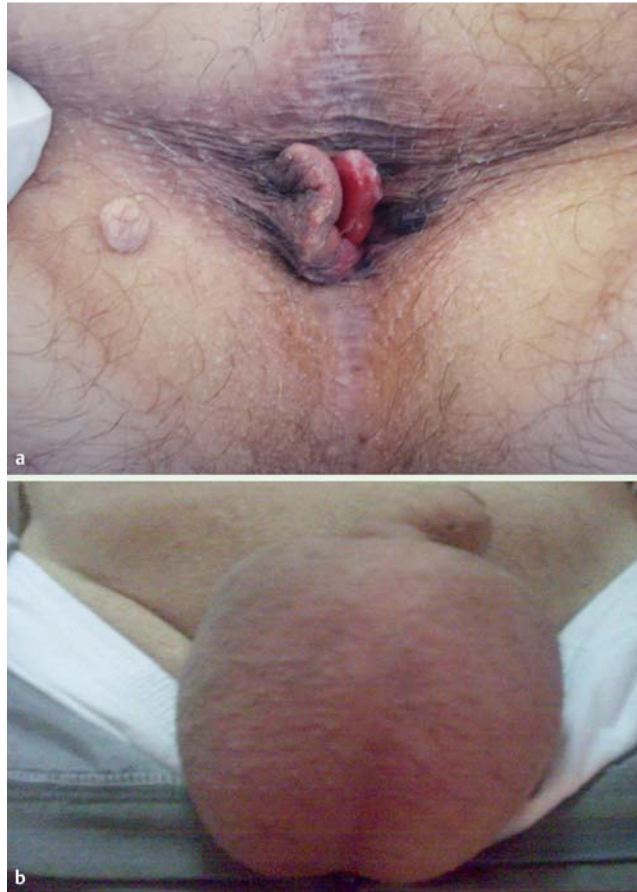

Fig. 1 Physical examination following rectosigmoidoscopy.
a External hemorrhoids were visible on perianal inspection in the knee-elbow position.
b Edematous scrotum.

ing the development of pneumoscrotum following a pure diagnostic lower gastrointestinal endoscopy [8]. None of the patients with this complication required a surgical repair procedure, and complete resolution was observed after close clinical observation, with judicious use of antibiotics and serial monitoring of the patients. Our case serves as an important reminder to gastroenterologists that pneumoscrotum could present as a sign of colonic perforation even in patients with diagnostic lower gastrointestinal endoscopy.

Endoscopy_UCTN_Code_CPL_1AJ_2AB

M. Akdogan¹, I. K. Onal¹, M. Kurt¹, Z. M. Yalinkilic¹, A. Sayilir¹, K. Karaman², B. Celep², R. S. Okten³

¹ Department of Gastroenterology, Türkiye Yüksek İhtisas Teaching and Research Hospital, Ankara, Turkey

² Department of Gastrointestinal Surgery, Türkiye Yüksek İhtisas Teaching and Research Hospital, Ankara, Turkey

³ Department of Radiology, Türkiye Yüksek İhtisas Teaching and Research Hospital, Ankara, Turkey

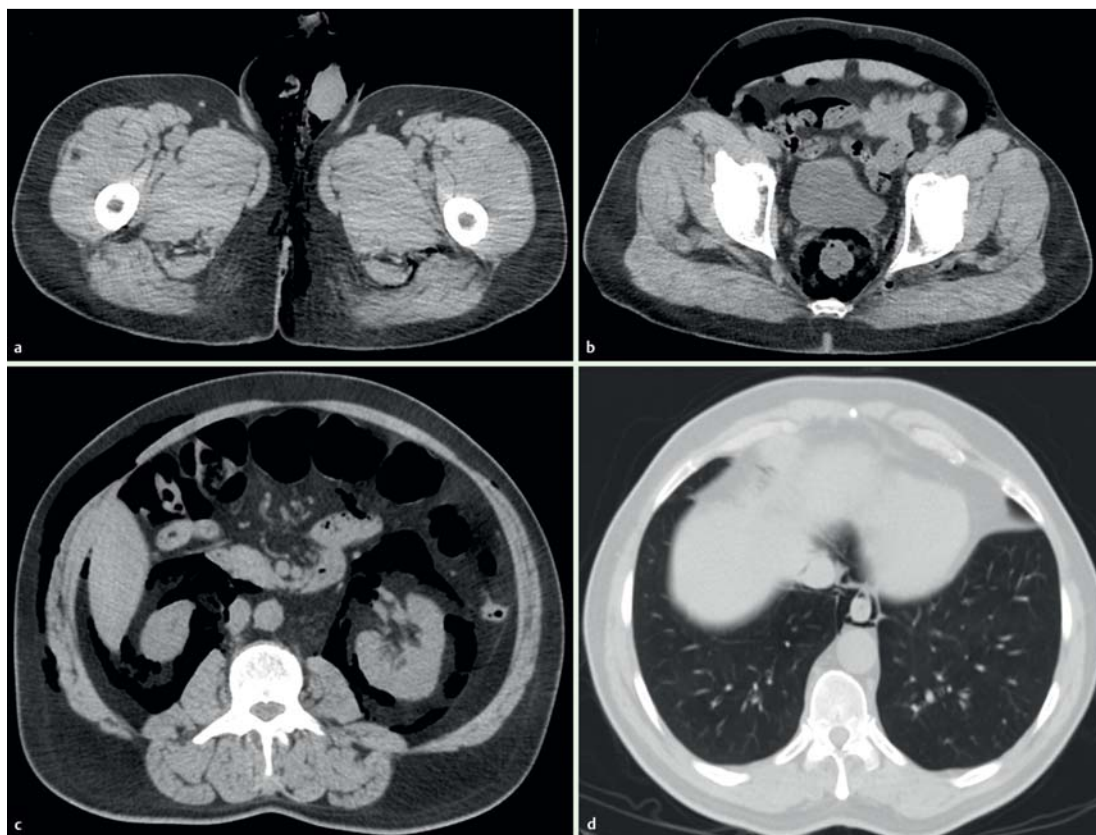


Fig. 2 Computed tomography scans of the thorax and abdomen demonstrated: **a** pneumoscotum; **b** free air surrounding the rectal wall, **c** in the perinephric area on both sides, **d** and in the paraesophageal space.

References

- 1 Watson HS, Klugo RG, Coffield KS. Pneumoscotum: report of two cases and review of mechanisms of its development. *Urology* 1992; 40: 517–521
- 2 Singh S, Thakur M. Pneumoscotum after colonoscopy. *Can J Gastroenterol* 2008; 22: 411–413
- 3 Humphreys F, Hewetson KA, Dellipiani AW. Massive subcutaneous emphysema following colonoscopy. *Endoscopy* 1984; 16: 160–161
- 4 Carlsen CU, Andreassen KH. Benign pneumoperitoneum and scrotal emphysema after colonoscopy. *Ugeskr Laeger* 1992; 154: 1785–1786
- 5 Graepler R, Lauer UM, Horger MS et al. Pneumoscotum after colonoscopic polypectomy. *Endoscopy* 2007; 39: E90
- 6 Fu KI, Sano Y, Kato S et al. Pneumoscotum: a rare manifestation of perforation associated with therapeutic colonoscopy. *World J Gastroenterol* 2005; 11: 5061–5063
- 7 Goerg KJ, Duber C. Retroperitoneal, mediastinal and subcutaneous emphysema with pneumothorax after colonoscopy. *Dtsch Med Wochenschr* 1996; 121: 693–696
- 8 Fishman EK, Goldman SM. Pneumoscotum after colonoscopy. *Urology* 1981; 18: 171–172

Bibliography

DOI 10.1055/s-0029-1215410

Endoscopy 2010; 42: E7–E8

© Georg Thieme Verlag KG Stuttgart · New York · ISSN 0013-726X

Corresponding author

M. Kurt, MD

Department of Gastroenterology
Türkiye Yüksek İhtisas Teaching
and Research Hospital
Kızılay Sk. No:2, 06100
Sıhhiye
Ankara
Turkey
Fax: +90-312-3124120
dr.mevlutkurt@gmail.com