Strongyloides stercoralis ileitis detected by double-balloon endoscopy

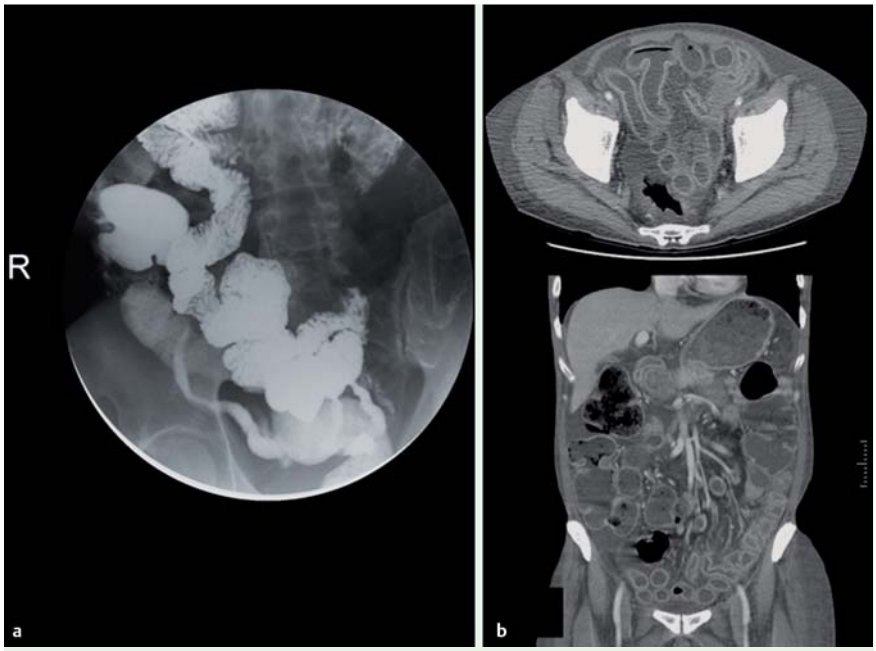

Fig. 1 Small-intestine series and abdominal computed tomography demonstrating diffuse wall thickening of the terminal ileum.

Fig. 2 **a** Double-balloon enteroscopy showing disappearance of villi in the terminal ileum under water. **b** Air inflation revealed widespread swollen and erosive mucosa with petechiae.

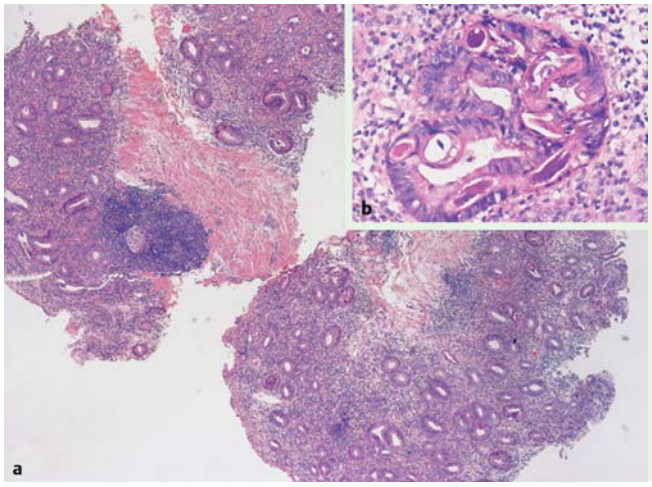

Fig. 3 **a** Eosinophils infiltrating the lamina propria. **b** Parasitic ova and larvae resembling the filariform larvae of *S. stercoralis* within the intestinal crypts.

A 52-year-old man was admitted for chronic diarrhea since more than a year, and progressive low-leg edema over the past three months. His history revealed that he made several short-term trips to southern China for business. He was passing loose stool seven to eight times every day. Laboratory tests revealed a total leukocyte count of 10.5×10^9/L with 59.7% neutrophils, 1.5% eosinophils, and 30% lymphocytes. His serum albumin level was 11.5 g/L and serum IgE level was 739 IU/mL (normal range < 78 IU/mL). The serum human immunodeficiency virus (HIV) antibody status was negative. Small-intestine follow-through study showed long-segment narrowing of the lumen of the terminal ileum (**Fig. 1 a**), whereas abdominal computed tomography demonstrated diffuse wall thickening of the terminal ileum (**Fig. 1 b**). Double-balloon enteroscopy was carried out via the anal route to further explore the long-segment narrowing in the ileum. There was loss of the normal villous structure of the terminal ileum on washing with water (**Fig. 2 a**), and widespread swelling and erosions with petechiae were noted in the mucosa after air inflation (**Fig. 2 b**; **Video 1**). Histopathological examination of biopsy specimens of this area revealed marked leukocytic infiltration, with eosinophils in the lamina propria (**Fig. 3 a**). Parasitic ova and larvae, morphologically resembling the filariform larvae of *Strongyloides stercoralis*, were found within the intestinal crypts (**Fig. 3 b**). The patient subsequently received treatment with ivermectin (12 mg/day) for 3 days. The diarrhea gradually resolved and the serum albumin level rose to 31.2 g/L 4 months after drug treatment.

Endoscopy_UCTN_Code_CCL_1AC_2AG

Video 1

Washing of the terminal ileum with water revealing loss of the normal villous structure.

W. H. Hsu[1,2], S. F. Yang[3], Y. C. Su[1,4]

[1] Division of Gastroenterology, Department of Internal Medicine, Kaohsiung Medical University Hospital, Kaohsiung, Taiwan

[2] Division of Internal Medicine, Kaohsiung Municipal Hsiao-Kang Hospital, Kaohsiung Medical University, Kaohsiung, Taiwan

[3] Department of Pathology, Kaohsiung Medical University Hospital, Kaohsiung, Taiwan

[4] Department of Medicine, Faculty of Medicine, College of Medicine, Kaohsiung Medical University, Kaohsiung, Taiwan

Bibliography

DOI 10.1055/s-0029-1215073
Endoscopy 2009; 41: E292 – E293

ISSN 0013-726X

Corresponding author

Y. C. Su MD
Division of Gastroenterology
Department of Internal Medicine
Kaohsiung Medical University Hospital
No. 100 Tz-You 1st Road
Kaohsiung 807
Taiwan
Fax: +886-7-3135612
ycsu@kmu.edu.tw