Infolding of Ultraflex self-expanding metal stent on insertion

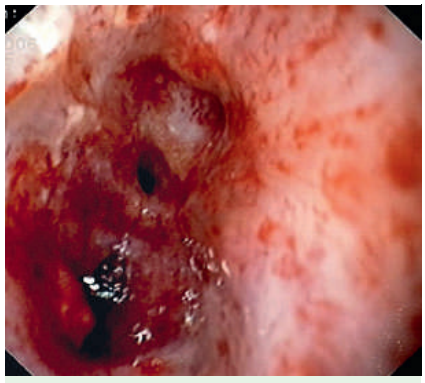

Fig. 1 Esophagorespiratory fistula.

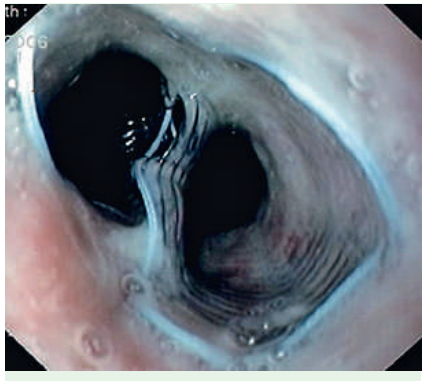

Fig. 2 Endoscopic view of infolded stent.

Fig. 3 Radiographic view of infolded stent.

Esophageal cancer is often diagnosed at an advanced stage, without curative options in 50%–60% of cases. Of the major complications, the principal ones are luminal obstruction and esophagorespiratory fistulas [1].

Among palliative measures, self-expanding metal stents (SEMS) have provided good quality of life for patients and are cost-effective [2]. Despite these advantages, the use of SEMS is not free of complications, namely incomplete expansion, migration, perforation, hemorrhage, tracheal compression, or food impaction [1]. Recently some authors have demonstrated accurate and safe stenting using only endoscopic guidance, without fluoroscopic support [3,4].

The Ultraflex stent has been associated with more occurrences of incomplete expansion and migration as well as infolding after deployment, as its construction favors a smaller radial force; thus, whilst preventing the risk of major trauma, it occasionally requires balloon dilation [5].

We report an unusual event after insertion of a covered 12-cm Ultraflex SEMS under sedation and without fluoroscopic control. The patient was a 52-year-old man with inoperable lower third esophageal cancer, who had previously undergone chemotherapy and radiotherapy and currently had grade 3 dysphagia (▶ **Fig. 1**).

After deployment the stent adopted a bizarre "B type" infolded conformation with maintenance of double lumen patency (▶ **Fig. 2** and **3**), whilst successfully covering the fistula holes. After 24 hours, repeat endoscopy revealed the same findings. Balloon dilation was done unsuccessfully. Biopsy rat-tooth forceps were used to displace the stent, which allowed it to unfold but uncovered the fistula opening (▶ **Fig. 4**). A second attempt, using the same instrument, correctly positioned the prosthesis (▶ **Fig. 5** and **6**).

The patient remained asymptomatic for the following 6 months and required no further endoscopic examinations.

This report highlights a possible and previously unconsidered adverse event, and is a reminder of the importance of improvisation and of the necessity for improvements in stent design.

Endoscopy_UCTN_Code_CPL_1AH_2AD

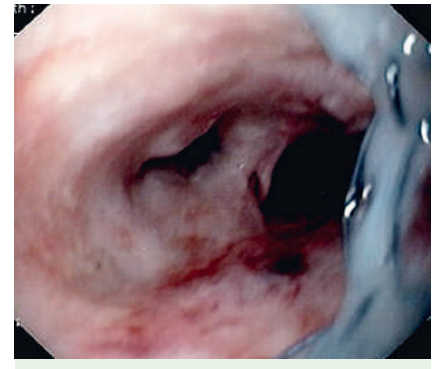

Fig. 4 The uncovered opening of the fistula.



Fig. 5 Endoscopic confirmation of correct opening of the stent.

Fig. 6 Esophagographic confirmation of correct opening of the stent.

B. Arroja, C. Gonçalves, F. Silva, I. Cotrim, H. Vasconcelos
Department of Gastroenterology, Hospital de Santo André EPE, Leiria, Portugal

References

1 *Wang MQ, Sze DY, Wang ZP et al.* Delayed complications after esophageal stent placement for treatment of malignant esophageal obstructions and esophagorespiratory fistulas. J Vasc Interv Radiol 2001; 12: 465 – 474
2 *Knyrim K, Wagner HJ, Bethge N et al.* A controlled trial of an expansile metal stent for palliation of esophageal obstruction due to inoperable cancer. N Engl J Med 1993; 329: 1302 – 1307
3 *Singhavi R, Abbasakor F, Manson JMcK.* Insertion of self-expanding metal stents for malignant dysphagia: assessment of a simple endoscopic method. Ann R Coll Surg Engl 2000; 82: 243 – 248
4 *White RE, Mungatana C, Topazian M.* Esophageal stent placement without fluoroscopy. Gastrointest Endosc 2001; 53: 348 – 351
5 *Nevitt AW, Kozarek RA, Kidd R.* Expandable esophageal prostheses: recognition, insertion techniques, and positioning. AJR Am J Roentgenol 1996; 167: 1009 – 1013

Bibliography
DOI 10.1055/s-0029-1214434
Endoscopy 2009; 41: E80 – E81

ISSN 0013-726X

Corresponding author
B. Arroja, MD
Hospital de Santo André EPE, Serviço de Gastroenterologia
Rua das Olhalvas, Pousos
2410 197 Leiria
Portugal
Fax: +351-244-817080
brunoarroja@gmail.com