A pseudotumoral angiodysplasia

Fig. 1 A computed tomography of the abdomen showing a thickening of the cecal wall.

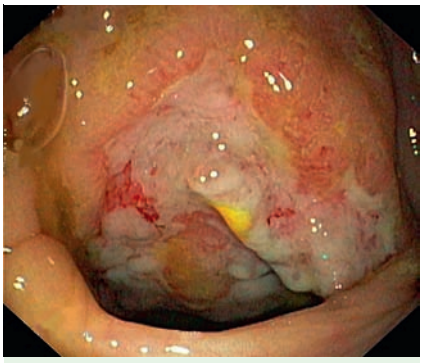

Fig. 2 Endoscopic view of the ulceronecrotic lesion facing the ileocecal valve.

A 76-year-old woman presented with recurrent right lower quadrant pain associated with decreased appetite and weight loss. An abdominal computed tomography (CT) scan without contrast injection (iodine allergy) showed a thickening of the cecal wall with infracentimetric regional lymph nodes (**Fig. 1**).

Colonoscopy depicted a 4 × 2-cm indurated and ulcerated lesion with necrotic features facing the ileocecal valve (**Fig. 2**).

Laboratory tests were normal except for a slightly elevated carcinoembryonic antigen at 9.6 ng/mL (normal value: < 4.5 ng/mL). The pathologic analyses from the biopsies showed necrotic tissue without signs of malignancy. Despite negative histology, given the clinical presentation, and endoscopic and imaging studies, the patient underwent a right hemicolectomy. Macroscopic study of the resected specimen found an ulcerative lesion of size 3.5 cm near the ileocecal valve. Microscopic examination revealed richly vascularized granulation tissue (**Fig. 3**) containing arterialized veins (arrows).

The mucosa and the submucosa exhibited increased numbers of dilated and deformed vessels (**Fig. 4**).

In the absence of nonsteroidal anti-inflammatory drug use and ischemic findings, all these pathologic features are consistent with the diagnosis of ulcerated angiodysplasia of the cecum.

Typical lesions of angiodysplasia are red and small (diameter 4 – 8 mm) [1]. Colonoscopy is the gold standard for detecting symptomatic or asymptomatic lesions. It has a sensitivity of 68 % with a predictive positive value of 90 % [2]. Two cases of angiodysplasia have been described with a radiologic aspect typical of adenocarcinoma [3, 4]. In both cases, it presented as a sessile mass, with adjacent ulceration in one case, and surgery was performed. The originality of this case comes first from the clinical presentation – a 76-year-old woman with no presenting blood loss but with abdominal pain, lack of appetite and weight loss – features that are very unusual in the setting of angiodysplasia, and second from its atypical endoscopic presentation mimicking adenocarcinoma.

Endoscopy_UCTN_Code_CCL_1AD_2AF

This document was downloaded for personal use only. Unauthorized distribution is strictly prohibited.

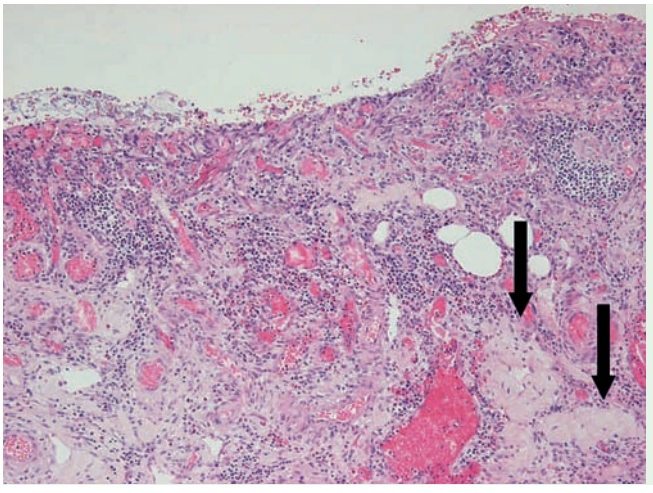

Fig. 3 Microscopic examination of the surgical specimen revealed richly vascularized tissue containing arterialized veins (arrows).

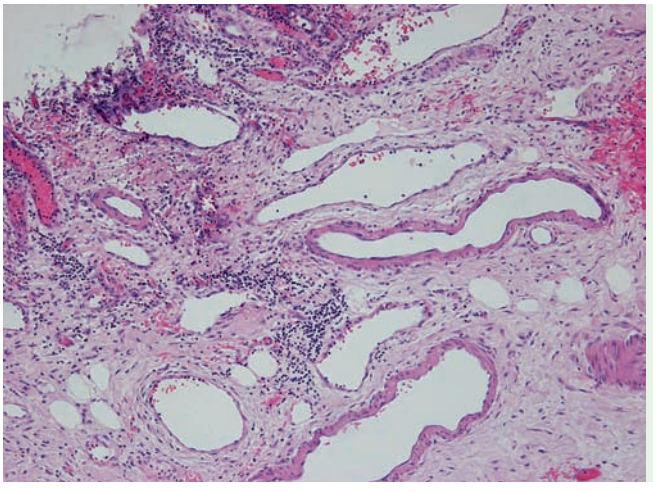

Fig. 4 Microscopic examination of the surgical specimen showing increased numbers of dilated and deformed vessels within the mucosa and the submucosa.

N. Dauby[1], F. Mboti[1], P. Demetter[2], J. Deviere[1], J. Van de Stadt[1], D. Blero[1]

[1] Medico-Surgical Department of Gastroenterology, Hôpital Erasme, Université Libre de Bruxelles, Brussels, Belgium

[2] Pathology Department, Hôpital Erasme, Université Libre de Bruxelles, Brussels, Belgium

References

1 *Sharma R, Gorbien MJ.* Angiodysplasia and lower gastrointestinal tract bleeding in elderly patients. Arch Intern Med 1995; 155: 807 – 812

2 *Richter JM, Hedberg SE, Athanasoulis CA et al.* Angiodysplasia. Clinical presentation and colonoscopic diagnosis. Dig Dis Sci 1984; 29: 481 – 485

3 *Lu C, Fukuya T, Landas S et al.* Angiodysplasia of the colon mimicking adenocarcinoma. AJR Am J Roentgenol 1993; 160: 898

4 *Chiu ML, Liu GC, Liu CS, Chen CY.* Angiodysplasia mimicking colon cancer: colonoscopy, double contrast barium enema, and CT findings. AJR Am J Roentgenol 2007; 188: W456 – W458

Bibliography

DOI 10.1055/s-0028-1119726
Endoscopy 2009; 41: E140 – E141
© Georg Thieme Verlag KG Stuttgart · New York ·
ISSN 0013-726X

Corresponding author

D. Blero, MD
Department of Gastroenterology
Hôpital Erasme
808 route de Lennik
1070 Bruxelles
Belgium
Fax: +32-2-5554697
dblero@ulb.ac.be

This document was downloaded for personal use only. Unauthorized distribution is strictly prohibited.