A case of syndrome of inappropriate secretion of antidiuretic hormone following endoscopic treatment

Syndrome of inappropriate secretion of antidiuretic hormone (SIADH) after endoscopic treatment has never been described. We report the first case of this complication after a relatively minor endoscopic procedure.

A 71-year-old woman with a sigmoid colon polyp was admitted to our hospital for endoscopic mucosal resection. Her medical history included right hemicolectomy for transverse colon cancer, hypertension, and acute myocardial infarction, and her current medications included isosorbide dinitrate, candesartan cilexetil, and indapamide. Physical examination and routine preprocedure laboratory tests on admission were normal. We performed a safe and painless endoscopic mucosal resection for a 5-mm sigmoid colon polyp (**Fig. 1**). The day after treatment, she complained of anorexia, nausea, and lethargy. Her physical and neurologic examinations, and magnetic resonance imaging of the brain were normal. Biochemical evaluation revealed a serum sodium concentration of 119 mmol/L, a potassium level of 2.8 mmol/L, and normal levels of urea and creatinine. Measured serum osmolality was 252 mmol/kg, urinary sodium concentration was 72 mmol/L, and urine osmolality was 181 mmol/kg. On the basis of these findings, she fulfilled the criteria for SIADH [1], and was treated accordingly with a water-restricted regimen and with 1 L of normal saline infused over 24 hours. Within 5 days of the onset of SIADH, her serum sodium concentration increased gradually to 141 mmol/L. Her symptoms resolved in accordance with her serum sodium concentration.

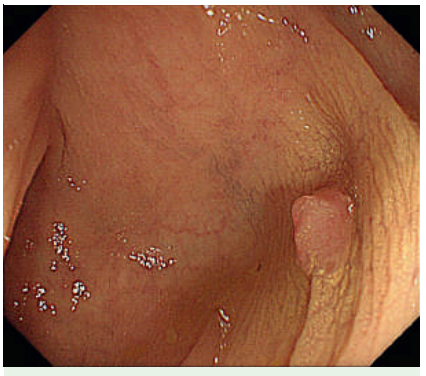

Fig. 1 Conventional colonoscopic view of a sessile polyp in the sigmoid colon.

Recently there have been reports of symptomatic hyponatremia and SIADH in patients undergoing not only major but also minor surgeries such as laparoscopic cholecystectomy and appendectomy [2–4]. Endoscopists should be aware that SIADH is a potential complication after endoscopic procedures, and they should check the serum sodium levels in patients who complain of unexplained nausea, disorientation, or lethargy after endoscopic treatments.

Endoscopy_UCTN_Code_CPL_1AH_2AK
Endoscopy_UCTN_Code_CPL_1AJ_2AI

M. Tajika[1], T. Nakamura[1], J. Tsuboi[2], V. Bhatia[3], H. Kawai[1], A. Sawaki[2], N. Mizuno[2], T. Takagi[2], K. Hara[2], Y. Sawai[2], Y. Kobayashi[2], K. Matsumoto[2], S. Sugimori[2], K. Yamakita[2], K. Yamao[2]

[1] Department of Endoscopy, Aichi Cancer Center Hospital, Nagoya, Japan
[2] Department of Gastroenterology, Aichi Cancer Center Hospital, Nagoya, Japan
[3] Institute of Liver and Biliary Sciences, New Delhi, India

References

1 *Bartter FC, Schwartz WB.* The syndrome of inappropriate secretion of antidiuretic hormone. Am J Med 1967; 42: 790–806
2 *Policastro AM.* Syndrome of inappropriate secretion of antidiuretic hormone following appendectomy: case report. Mil Med 1983; 148: 271–272
3 *Fuhrman TM, Runyan T, Reilley T.* SIADH following minor surgery. Can J Anaesth 1992; 39: 97–98
4 *Han SR, Wu CC, Mok M et al.* Postoperative coma induced by hyponatremia after laparoscopy. Acta Anaesthesiol Sin 2000; 38: 41–46
5 *Cooper BC, Murray AM.* Syndrome of inappropriate antidiuretic hormone in a healthy woman after diagnostic laparoscopy. J Reprod Med 2006; 51: 199–201

Bibliography
DOI 10.1055/s-0028-1119621
Endoscopy 2009; 41: E101
© Georg Thieme Verlag KG Stuttgart · New York ·
ISSN 0013-726X

Corresponding author
M. Tajika, MD, PhD
Department of Endoscopy
Aichi Cancer Center Hospital
1-1 Kanokoden
Chikusa-ku
Nagoya City
464-8681
Japan
Fax: +81-52-763-5233
mtajika@aichi-cc.jp

This document was downloaded for personal use only. Unauthorized distribution is strictly prohibited.