

Additional over-the-scope-clip closure can shorten endoscopic vacuum therapy for postoperative upper gastrointestinal leakage



Authors

Lars Kollmann¹, Alexander Weich², Maximilian Gruber¹, Sven Flemming¹, Alexander Meining², Christoph-Thomas Germer¹, Johann Friso Lock¹, Florian Seyfried¹, Markus Brand^{1,2}, Stanislaus Reimer^{1,2}

Institutions

- 1 Department of General, Visceral, Transplantation, Vascular, and Pediatric Surgery, University Hospital Würzburg, Würzburg, Germany
- 2 Department of Gastroenterology, University Hospital Würzburg, Würzburg, Germany

Key words

Quality and logistical aspects, Quality management, Performance and complications, GI surgery

received 14.5.2024

accepted after revision 7.8.2024

Bibliography

Endosc Int Open 2024; 12: E1023–E1028

DOI 10.1055/a-2387-2054

ISSN 2364-3722

© 2024. The Author(s).

This is an open access article published by Thieme under the terms of the Creative Commons Attribution-NonDerivative-NonCommercial License, permitting copying and reproduction so long as the original work is given appropriate credit. Contents may not be used for commercial purposes, or adapted, remixed, transformed or built upon. (<https://creativecommons.org/licenses/by-nc-nd/4.0/>)

Georg Thieme Verlag KG, Rüdigerstraße 14,
70469 Stuttgart, Germany

Corresponding author

Lars Kollmann, M.D., University Hospital Würzburg,
Department of General, Visceral, Transplantation, Vascular,
and Pediatric Surgery, Würzburg, Germany
kollmann_l@ukw.de

Supplementary Material is available at
<https://doi.org/10.1055/a-2387-2054>

ABSTRACT

Background and study aims Endoscopic vacuum therapy (EVT) has become the most effective therapeutic option for upper gastrointestinal leakage. Despite its efficiency, this treatment can necessitate a long hospitalization. The aim of this study was to evaluate whether additional use of an over-the-scope-clips (OTSC) closure after successful EVT can shorten leakage therapy.

Patients and methods All patients treated with EVT for leakages in the upper gastrointestinal tract at our center from 2012 to 2022 were divided into two propensity matched cohorts (EVT + OTSC vs. EVT only). The EVT + OTSC patients received OTSC application at the end of successful EVT directly after removal of the last sponge. The primary endpoint was the time interval from leakage diagnosis until discharge. Secondary endpoints included EVT efficacy, complications, and nutritional status at discharge.

Results A total of 84 matched patients were analyzed. EVT efficacy was 100% in both groups. The time interval from leakage until discharge was significantly shorter in the EVT + OTSC vs. EVT group (33 [19–48] vs. 46 days [29–77] $P = 0.004$). No patient in the EVT + OTSC group required additional procedures for leakage management, whereas five (12%) in the EVT group needed additional stent placement ($P = 0.021$). More patients could be discharged on sufficient oral nutrition in the EVT + OTSC group (98% vs. 60%; $P < 0.001$).

Conclusions The addition of OTSCs after successful EVT is safe and has the potential to shorten leakage therapy, enabling earlier discharge along with better functional outcomes.

‡ These authors contributed equally.

Introduction

Endoscopic vacuum therapy (EVT) has become the preferred standard for postoperative leakage management during the last decade [1, 2, 3], while technical aspects have been further

optimized [4]. Especially for postoperative leakages after upper gastrointestinal tract surgery (UGI), EVT has proven its high clinical efficacy even in complex situations [5,6]. We recently reported the effectiveness and the infrastructural and technical challenges during EVT implementation at our center, demonstrating significant improvement concerning morbidity as well as mortality [4].

Although procedure-related complications such as strictures or bleeding have been shown to be rare [4,6,7], important drawbacks of EVT include the relatively long therapeutic sequence with recurrent endoscopies every 3 to 5 days, patient inability to take oral nutrition, and compromising nasogastric tubes. As a promising option to shorten the EVT time, EVT-conditioned defect closure with an over-the-scope-clip (OTSC; Ovesco Endoscopy AG, Tuebingen, Germany) has been identified [8]. This technique has been used for gastric or colonic defect closure by grasping a rather large amount of tissue and closing it by clamping it with an application device from outside the endoscope [9].

We hypothesized that additional OTSC application after initial leakage consolidation by EVT could have the potential to shorten leakage therapy. Therefore, OTSC application after initial EVT was used in our department in selected individuals based on clinical decision. The aim of this retrospective propensity-matched analysis was to compare leakage management and clinical outcomes for EVT alone vs. EVT + OTSC.

Patients and methods

This propensity score matched study covered an 11-year-period (2012–2022) and was retrospectively conducted in a 1,500-bed tertiary center. The manuscript was prepared according to the Standards for Quality Improvement Reporting Excellence (SQUIRE) [10].

Study design and ethics

Beginning in 2015, information about all patients who received EVT was prospectively collected in a standardized database. Data analysis was approved by the local ethics review board in 2015. Since the first application of EVT at our center, local clinical management of UGI leakage has undergone several changes including additional OTSC closure in individual cases. The first OTSC clip was applied in 2017 but the frequency of use has increased since 2021. We identified a total of 42 patients that received OTSC after successful EVT in our patient cohort. OTSC application was performed directly after sponge removal during the same endoscopy. The indication for performing OTSC instead of continuing EVT was chosen on an individual basis by the endoscopist, as described below.

To evaluate the impact of additional OTSC clip placement, the 42 patients were selected for a 1:1 matched propensity score analysis. Because of the heterogeneity of EVT indications and clinical situations, we chose to reduce the dataset to achieve two homogenous patient cohorts. Based on the available literature and expert knowledge, we chose the following covariates that could influence the progression and outcome of leakage therapy: gender, age, Charlson comorbidity index,

underlying disease, surgical procedure, and localization and size of leakage. Because all EVT + OTSC patients recovered and none died, only patients in whom EVT was effective were selected for matching.

The analysis focused on clinically important outcome variables, such as total duration of leakage therapy, time from leakage till discharge, and nutritional status at discharge.

Endoscopic vacuum therapy

All endoscopic procedures were performed by experienced gastroenterologists with at least 10 years of experience in endoscopy, who had completed their learning curve for EVT treatment and who also had multiple years of experience in use OTSCs.

The processes and endoscopic techniques for using both EVT and OTSCs have been described in detail [6,9]. The leak was consolidated using EVT, leading to normalization of systemic infection parameters and allowing antibiotic therapy to be discontinued. Prerequisites for additional OTSC closure to end EVT were: 1) absence of systemic inflammation with successful discontinuation of anti-infective therapy; 2) sufficiently refreshed, vital and epithelialized wound edges of leakage; 3) no more secretion from the defect during endoluminal aspiration with an endoscope; and 4) residual leakage defect < 10 mm enabling technical application of OTSC.

OTSC application was performed using a single mini-OTSC (mini OTSC Clip 6 t, OVESCO) without an anchor. The clip was applied with the suction method.

All patients received an endoscopic control 3 to 5 days after OTSC placement and after ending EVT treatment for residual leakage. Radiography was performed only in cases for which the endoscopist could not define success by endoscopy only.

Statistical analysis

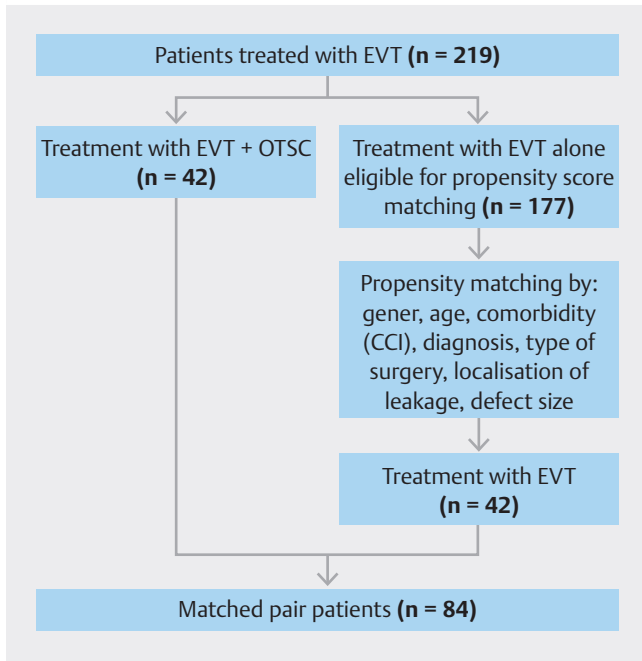
All statistical analyses were performed using IBM SPSS Statistics 29 (International Business Machines Corporation, Armonk, New York, United States). Descriptive data are reported as means with standard deviations, unless otherwise stated. The propensity variable for 1:1 matching was calculated by logistic regression analysis incorporating the selected covariates. A matching tolerance of < 0.2 of the standard deviation (SD) of the logit of the propensity was accepted.

Comparisons between the analyzed cohorts were performed using chi-square, Fisher's exact, Mann-Whitney U tests or one-way analysis of variance, in accordance with data scale and distribution. Time intervals were compared by Kaplan-Meier analysis with log rank test. The level of statistical significance was 0.05 (two-sided).

Results

Study population and indications for EVT

From the current database of 219 patients, only 42 received EVT + OTSC. The propensity matching yielded 42 pairs of EVT vs. EVT + OTSC, and thus, 84 patients were analyzed (► Fig. 1). The 135 non-matched EVT-only patients were excluded. Patient characteristics are presented in ► Table 1 and baseline



► **Fig. 1** Flowchart of propensity score matched analysis.

characteristics before matching are presented in **Supplementary Table 1**.

Leakage management

In both groups, patients received EVT within 12 hours after leakage diagnosis. The mean initial leakage diameter was 10 mm in both groups (EVT alone 5–23 mm and EVT + OTSC 6–16 mm). The EVT + OTSC group received the same EVT as the EVT alone group before OTSC application. OTSC application was performed at the end of leakage therapy in all patients in this group. No patient in this group received an additional endoscopic intervention.

The duration of leakage therapy was a median 6 days shorter in the EVT + OTSC group without statistical significance (20 [7–31] vs. 26 days [15–41]; $P = 0.059$). Patients in the EVT + OTSC group received in median fewer sponge changes during EVT without statistical significance (6 [3–9] vs. 8 [4–10]; $P = 0.073$). Stenosis occurred less frequently in the EVT + OTSC group (2% vs. 12%; $P = 0.048$). Placement of additional self-expanding-metal-stents (SEMS) was not necessary in the EVT + OTSC group (0% vs. 12%; $P = 0.021$). Representative endoscopic findings are shown in ► **Fig. 2**.

Patient outcome

Success of EVT treatment was 100% in both groups and there were no deaths according to the exclusion criteria. Of note, the mortality rate for all patients treated with EVT in our center was 2.2% (5/219) regardless of indication or diagnosis. The overall success rate for all EVTs was 90.9% (199/219). The inter-

► **Table 1** Patient characteristics.

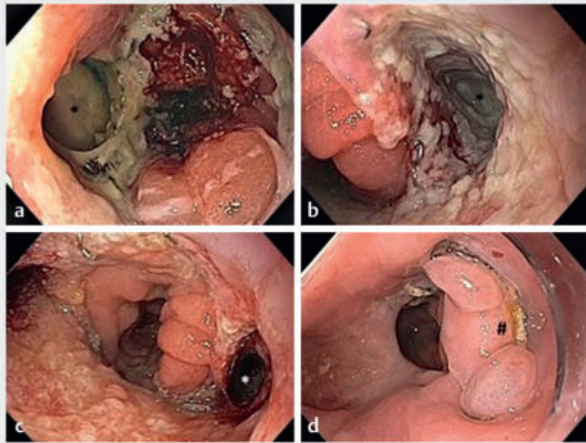
Characteristic	Patients, no. (%)	
	EVT only (n = 42)	EVT + OTSC (n = 42)
Sex ratio, no. (M:F)	31:11	31:11
Age, mean (SD), years	62 (31–79)	60 (31–78)
BMI, mean (SD), kg/m ²	25.3 (18.3–52.4)	26.1 (17.8–54.4)
Charlson comorbidity index, mean (SD)	4 (0–10)	4 (0–9)
Benign disease	17 (40)	15 (36)
Malignant tumor	25 (60)	27 (64)
▪ Neoadjuvant therapy	17 (41)	24 (57)
Type of surgery		
▪ Esophagectomy	13 (31)	15 (36)
▪ Gastrectomy*	13 (31)	18 (42)
▪ Upper gastrointestinal surgery†	16 (38)	9 (21)
▪ Interval from surgery to diagnosis of leakage, mean (95%CI), days	9 (6–12)	10 (7–13)

Not shown are leakage distance from incisors, other laboratory parameters, and clinical situation at baseline of leakage, because no differences were observed. Values are n (%) unless otherwise indicated.

BMI, body mass index; CI, confidence interval; EVT, endoscopic vacuum therapy; SD, standard deviation.

*Including transhiatal and partial gastrectomy.

†Including metabolic surgery, hiatal hernia surgery, Heller myotomy.

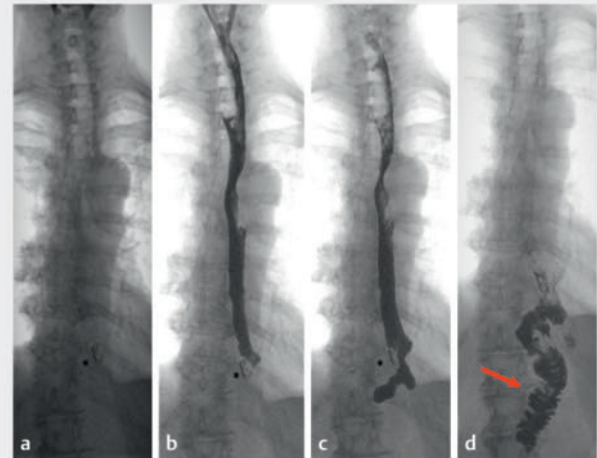


► **Fig. 2** EVT and OTSC therapy in a leakage after gastrectomy.

val from postoperative leakage to discharge was a median 13 days shorter in the EVT+OTSC vs. EVT group (33 days [19–48] vs. 46 days [29–77]; $P = 0.004$). Sufficient oral nutrition at discharge was more frequent in the EVT+OTSC vs. EVT group (98% vs. 60%; $P \leq 0.001$). During further follow-up (1 year), no recurrent leakage was observed. Detailed data are shown in ► **Table 2**. A representative image of contrast medium swallow after EVT+OTSC treatment is shown in ► **Fig. 3**.

Discussion

The present propensity-matched analysis demonstrates the potential for shortening EVT by OTSC application for the first time. We were able to demonstrate in our patient cohort that



► **Fig. 3** Barium swallow after successful EVT+OTSC (patient after gastrectomy)

additional OTSC closure resulted in a clinically relevant shorter hospital stay after leakage with a higher rate of sufficient oral nutrition at discharge. Interestingly, no adverse events were recorded.

The large number of patients treated with EVT at our institution enabled a propensity-matched analysis with a reasonable number of cases. Although propensity matching ruled out major bias from group differences, the analyzed cohort was heterogeneous overall regarding type of surgery, and therefore, comorbidities and leakage therapy duration.

We were able to prove that EVT treatment is safe and effective for leakages in the UGI tract with both techniques. The efficacy of EVT to improve local and systemic inflammation after

► **Table 2** EVT and outcome.

Characteristic	Patients, No. (%)		P value
	EVT only (n = 42)	EVT + OTSC (n = 42)	
Interval from diagnosis of leakage until start of EVT, mean (95%CI), hours	12 (4–78)	12 (4–24)	1
CRP at start of EVT mean (95%CI)	20.7 (0–42.6)	19.3 (0.3–44.8)	0.576
WBC at start of EVT mean (95%CI)	15.4 (2.1–43.9)	14.5 (8–29.3)	0.603
Initial leakage diameter, mean (95%CI), mm	10 (5–23)	10 (6–16)	1
Duration of leakage therapy, median (quartiles), days	26 (15–41)	20 (7–31)	0.059
Sponge changes, median (quartiles)	8 (4–10)	6 (3–9)	0.073
Development of stenosis	6 (14)	1 (2)	0.048
Additional SEMS placement	5 (12)	0	0.021
Interval from leakage until discharge, median (quartiles), days	46 (29–77)	33 (19–48)	0.004
Oral nutrition on discharge	25 (60)	41 (98)	<0.001

Values are n (%) unless otherwise indicated.

CI, confidence interval; CRP, C-reactive protein; EVT, endoscopic vacuum therapy; SEMS, self-expanding-metal-stent.

* $P < 0.05$.

postoperative UGI leakage have been demonstrated in multiple reports [1, 3, 4, 6]. Local focus control enables granulation and step-wise closure of the leakage. Long intraluminal EVT may also promotes development of a stenosis due to luminal granulation.

All patients who developed stenoses in our cohort were oncologic patients receiving esophagectomies who had intrathoracic esophageal anastomoses. All stenoses occurred in the EVT only group. A possible explanation for this observation could be subclinical ischemia of the proximal gastric conduit. This is supported by a recent meta-analysis on gastric ischemic conditioning of prior esophagectomies, which showed fewer leakages but also stenoses in preconditioned patients [11].

Despite an extensive literature research, we did not find any reports of treatment comparable to ours. Therefore, we cannot compare our findings to existing literature. However, recent studies with smaller numbers describe an overall closure rate with EVT of 78% [12]. A recently published Spanish multicenter registry-based study with 102 patients found an 82% closure success rate [13]. This underscores the importance of gaining competence with these method(s), as we have shown before [4].

The ongoing debate about EVT should be favored over SEMS for leakage treatment gets further support from a recent meta-analysis showing the superiority of EVT with higher effectiveness, shorter treatment times, and less septic complications [14]. Also, a recent study demonstrated the superiority of EVT vs. SEMS for treatment of leakage after esophagectomies and the results were comparable to our study, with 90.5% success in the EVT group [6]. In this study the overall leakage therapy duration was 16 days in the EVT group vs. 70 days in the conventional treatment group with a wide range from 4 to 142 days vs. 8 to 604, which underscores the heterogeneity in leakage treatment duration. In our hands, the effectiveness of EVT treatment for leakage after esophagectomies with gastric pull-up and thoracic anastomosis was 90.9% and convincingly superior to SEMS treatment. We also assume that shortening the EVT treatment may be beneficial for patients in terms of comfort because one of the main disadvantages of EVT is its long treatment course with impaired oral intake, this outcome remains hypothetical, because we did not investigate subjective measures of patient wellbeing during the treatment period.

In context of emerging treatment options, the recently launched VACStent (MICROTECH Europe GmbH, Düsseldorf, Germany) represents a combination of the sealing effect of a stent with the advantages of EVT inducing tissue granulation and may be useful for leaks with small defects but it is not yet well-established for granulation tissue [15].

This study contains some limitations. The first is its retrospective single-center design. Second, the cohort overall was heterogeneous and included oncological as well as functional and bariatric patients. This heterogeneity explains the wide range of lengths of stay and duration of leakage therapy. Also, constant improvement and implementation of new therapeutic options may result in certain learning curves. Also, all patients whose leakages were closed by EVT+OTSC were clinically stable without systemic inflammation and were usually treated

on a general ward. This may have led to selection bias. It is not possible to fully appraise and quantify if or how many of the EVT group patients might have been candidates for OTSC because of the retrospective nature of this analysis. The alternative of OTSC clip application would have been a continuation of EVT owing to the continued presence of a defect.

We find it important, however, to emphasize that we performed propensity matching to exclude failure to cure patients to reduce bias. As stated in **Supplementary Table 1**, the unmatched, non-OTSC cohort has even smaller leakage sizes at the start of EVT. Therefore, we believe propensity matching did reduce selection bias.

Numerous confounding factors can affect a patient's clinical course during and after EVT. The intention of this analysis was to compare our OTSC cohort with individually matched patients of the same age and with the same disease, comorbidity, surgical procedure, and anastomotic leakage to enable a valid comparison. However, individual selection of patients for OTSC application remains an important selection bias because the decision was left to each endoscopist if they estimated that the leakage was suitable for OTSC.

Nevertheless, the question of alternative leakage management with either OTSC or EVT continuation would have led to other results that can only be addressed in a prospective trial with defined criteria for choosing to apply an OTSC.

In addition, all endoscopists were experienced in EVT treatment and use of OTSC, which also may have led to favorable results that may not be transferable to other centers.

Another benefit of use of OTSCs may be that it is a more cost-effective approach because treatment time is shortened as is LOS and fewer sponge changes are needed. Because we did not measure cost differences between groups, this is an assumption but has not been proven.

Further studies, and particularly prospective trials, are required to determine standardized clinical criteria after EVT for application of OTSCs and to identify the optimal timing for application after EVT.

Conclusions

Additional OTSC closure might be a safe option in order to reduce the duration of postoperative leakage management, number of endoscopies, and time to hospital discharge. In addition, it enables most patients to be discharged on full oral nutrition and may be an option to prevent stenosis after long-lasting EVT therapy.

Conflict of Interest

Alexander Meining is a consultant for OVESCO and co-patentholder for several devices manufactured and distributed by the company. All other authors declare no conflict of interest.

References

- [1] Loske G, Schorsch T, Muller C. Endoscopic vacuum sponge therapy for esophageal defects. *Surg Endosc* 2010; 24: 2531–2535 doi:10.1007/s00464-010-0998-x
- [2] Jung DH, Yun HR, Lee SJ et al. Endoscopic vacuum therapy in patients with transmural defects of the upper gastrointestinal tract: A systematic review with meta-analysis. *J Clin Med* 2021; 10: 2346
- [3] Ahrens M, Schulte T, Egberts J et al. Drainage of esophageal leakage using endoscopic vacuum therapy: a prospective pilot study. *Endoscopy* 2010; 42: 693–698 doi:10.1055/s-0030-1255688
- [4] Reimer S, Seyfried F, Flemming S et al. Evolution of endoscopic vacuum therapy for upper gastrointestinal leakage over a 10-year period: a quality improvement study. *Surg Endosc* 2022; 36: 9169–9178 doi:10.1007/s00464-022-09400-w
- [5] Rausa E, Asti E, Aiolfi A et al. Comparison of endoscopic vacuum therapy versus endoscopic stenting for esophageal leaks: systematic review and meta-analysis. *Dis Esophagus* 2018; 31: doi:10.1093/dote/doy060
- [6] Lee J, Jeon JH, Yoon SH et al. The optimal treatment strategy for postoperative anastomotic leakage after esophagectomy: A comparative analysis between endoscopic vacuum therapy and conventional treatment. *J Gastrointest Surg* 2023; 27: 2899–2906
- [7] Kollmann L, Reimer S, Lock JF et al. Endoscopic vacuum therapy as a first-line treatment option for gastric leaks after bariatric surgery: evidence from 10 years of experience. *Surg Obes Relat Dis* 2023; 19: 1041–1048
- [8] Mennigen R, Senninger N, Laukoetter MG. Novel treatment options for perforations of the upper gastrointestinal tract: endoscopic vacuum therapy and over-the-scope clips. *World J Gastroenterol* 2014; 20: 7767–7776 doi:10.3748/wjg.v20.i24.7767
- [9] Kirschniak A, Kratt T, Stüker D et al. A new endoscopic over-the-scope clip system for treatment of lesions and bleeding in the GI tract: first clinical experiences. *Gastrointest Endosc* 2007; 66: 162–167 doi:10.1016/j.gie.2007.01.034
- [10] Ogrinc G, Davies L, Goodman D et al. SQUIRE 2.0-standards for quality improvement reporting excellence-revised publication guidelines from a detailed consensus process. *J Am Coll Surg* 2016; 222: 317–323
- [11] Aiolfi A, Bona D, Bonitta G et al. Gastric Ischemic Conditioning (GIC) International Collaborative Group. Short-term outcomes of different techniques for gastric ischemic preconditioning before esophagectomy: A network meta-analysis. *Ann Surg* 2024; 279: 410–418 doi:10.1007/s13304-023-01515-6
- [12] Luttikhold J, Pattynama LMD, Seewald S et al. Endoscopic vacuum therapy for esophageal perforation: a multicenter retrospective cohort study. *Endoscopy* 2023; 55: 859–864 doi:10.1055/a-2042-6707
- [13] Momblan D, Gimeno Garcia AZ, Busquets D et al. Endoscopic vacuum therapy for upper gastrointestinal leaks and perforations: Analysis from a multicenter Spanish registry. *Am J Gastroenterol* 2023; 118: 1797–1806
- [14] Mandarino FV, Fanti L, Barchi A et al. Endoscopic vacuum therapy for esophageal perforations: is it risk effective for every size of defect? *Endoscopy* 2023; 55: 971 doi:10.1055/a-2070-5524
- [15] Lange J, Dormann A, Bulian DR et al. VACStent: Combining the benefits of endoscopic vacuum therapy and covered stents for upper gastrointestinal tract leakage. *Endosc Int Open* 2021; 9: E971–E976 doi:10.1055/a-1474-9932