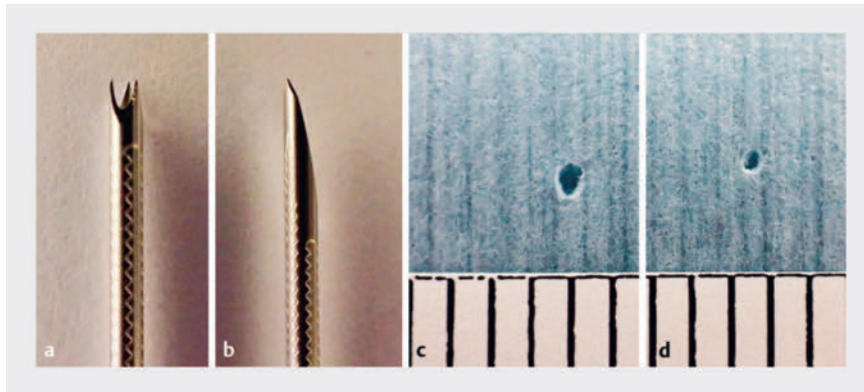


One-step primary endoscopic ultrasound-guided choledochoduodenostomy without lumen-apposing metal stent using a Franseen needle and an ultra-stiff high-sliding guidewire

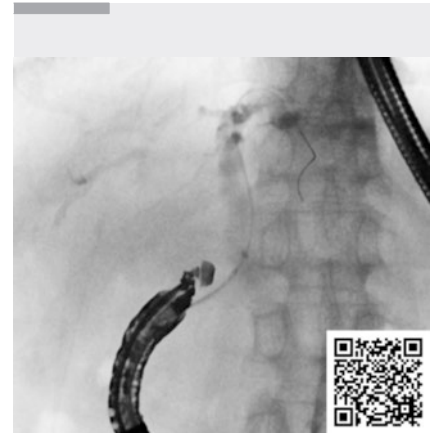OPEN
ACCESS



► **Fig. 1** **a, c** In the bench test, the 19-G Franseen needle (SonoTip TopGain; Medi-Globe, Rohrdorf, Germany) creates a 1.27 mm-diameter hole. **b, d** In contrast, the 19-G standard needle (SonoTip Pro Control; Medi-Globe) creates a 0.70 mm-diameter hole.



► **Fig. 2** The novel guidewire measures 0.035 inches and features a thick, high-rigidity nickel-titanium core. The surface is coated with polytetrafluoroethylene, using “ridge-processing”, which reduces contact area and friction with devices, enhancing followability and insertability.



► **Video 1** One-step primary endoscopic ultrasound-guided choledochoduodenostomy using a Franseen needle and an ultra-stiff, high-sliding guidewire

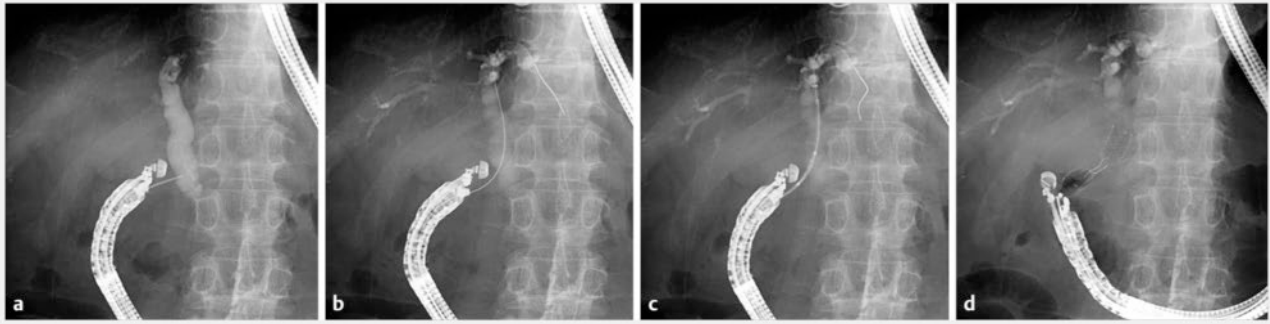Endoscopic ultrasound-guided choledochoduodenostomy (EUS-CDS) using a lumen-apposing metal stent (LAMS) can be used as a primary treatment for malignant distal biliary obstruction because of its higher technical success rates and shorter procedure times than conventional transpapillary metal stent placement [1, 2]. However, it is unsuitable for minimally dilated common bile ducts (CBDs) and thin 6-mm-diameter LAMS

are commonly used owing to large flanges. Other disadvantages include high costs, early stent dysfunction, and adverse events caused by biliary wall compression, duodenobiliary reflux, and cautery puncture [3]. Conversely, EUS-CDS with conventional metal stents requires a fistula dilation step that is time-consuming, leading to biliary peritonitis and a high risk of stent migration. Therefore, we propose a novel one-step EUS-CDS

method without a LAMS using a Franseen needle and an ultra-stiff, high-sliding guidewire.

The Franseen needle creates a larger-diameter fistula during puncture than standard needles [4] (► **Fig. 1**). The 0.035-inch guidewire has a thick, high-rigidity nickel-titanium core and polytetrafluoroethylene coating with “ridge-processing” to minimize the contact area and friction, enhancing device followability and insertability (► **Fig. 2**). This combination can eliminate the need for fistula dilation even when inserting a thick delivery system. A dumbbell-shaped metal stent [5] was employed for stenting owing to its antimigration properties.

An 83-year-old man with obstructive jaundice due to malignant distal biliary obstruction was scheduled for primary EUS-CDS drainage. After CBD puncture from the duodenum using a 19-G Fran-



► **Fig. 3** **a** A 19-G Franseen needle was used to puncture the common bile duct from the duodenum. **b** The novel guidewire was inserted into the intrahepatic bile duct. **c** Subsequently, the 8-Fr delivery system of the dumbbell-shaped metal stent was smoothly inserted without the need for fistula dilation. **d** The metal stent (12×50 mm) was then placed from the common bile duct to the duodenum.

seen needle (SonoTip TopGain; Medi-Globe, Rohrdorf, Germany), an ultra-stiff guidewire (SeekMaster Hard; Piolax Medical Devices, Kanagawa, Japan) was inserted into the intrahepatic bile duct. Subsequently, the 8-Fr delivery system of the dumbbell-shaped stent (BONASTENT M-Intraductal; Standard Sci-Tech Inc., Seoul, Korea) was smoothly inserted without fistula dilation, followed by placement of the stent from the CBD to the duodenum (► **Fig. 3**, ► **Video 1**). The procedure was completed within five minutes. No adverse events or stent dysfunction, including biliary peritonitis or migration, occurred until the patient's death.

This method offers a straightforward and effective primary drainage approach for malignant distal biliary obstruction, addressing the limitations of EUS-CDS with a LAMS.

Endoscopy_UCTN_Code_TTT_1AS_2AH

Conflict of Interest

The authors declare that they have no conflict of interest.

The authors

Tadahisa Inoue¹, Rena Kitano¹, Mayu Ibusuki¹, Tomoya Kitada¹, Kazumasa Sakamoto¹, Jun Arai¹, Kiyooki Ito¹

¹ Department of Gastroenterology, Aichi Medical University, Nagakute, Japan

Corresponding author

Tadahisa Inoue, MD

Department of Gastroenterology, Aichi Medical University, 1-1 Yazakokarimata, Nagakute, Aichi 480-1195, Japan
tinoue-tag@umin.ac.jp

References

- [1] Teoh AYB, Napoleon B, Kunda R et al. EUS-guided choledochoduodenostomy using lumen apposing stent versus ERCP with covered metallic stents in patients with unresectable malignant distal biliary obstruction: A multicenter randomized controlled trial (DRA-MBO Trial). *Gastroenterology* 2023; 165: 473–482.e2
- [2] Chen YI, Sahai A, Donatelli G et al. Endoscopic ultrasound-guided biliary drainage of first intent with a lumen-apposing metal stent vs endoscopic retrograde cholangiopancreatography in malignant distal biliary obstruction: A multicenter randomized controlled study (ELEMENT Trial). *Gastroenterology* 2023; 165: 1249–1261.e5
- [3] Fritzsche JA, Fockens P, Besselink MG et al. Endoscopic ultrasound-guided choledochoduodenostomy using single-step lumen-apposing metal stents for primary drainage of malignant distal biliary obstruction (SCORPION-p): a prospective pilot study. *Endoscopy* 2024; 56: 47–52. doi:10.1055/a-2134-3537
- [4] Okuno N, Hara K, Haba S et al. The new potential for using Franseen needles in interventional EUS. *Intern Med* 2024. doi:10.2169/internalmedicine.3207-23
- [5] Choi HJ, Moon JH, Lee YN et al. Evaluation of a newly modified nonflared fully covered metal stent, 12 mm in diameter, for intraductal placement in patients with malignant biliary strictures: a feasibility study. *Endoscopy* 2016; 48: 625–631

Bibliography

Endoscopy 2024; 56: E726–E727

DOI 10.1055/a-2374-8711

ISSN 0013-726X

© 2024. The Author(s).

This is an open access article published by Thieme under the terms of the Creative Commons Attribution License, permitting unrestricted use, distribution, and reproduction so long as the original work is properly cited.

(<https://creativecommons.org/licenses/by/4.0/>)

Georg Thieme Verlag KG, Rüdigerstraße 14, 70469 Stuttgart, Germany



ENDOSCOPY E-VIDEOS

<https://eref.thieme.de/e-videos>



E-Videos is an open access online section of the journal *Endoscopy*, reporting on interesting cases

and new techniques in gastroenterological endoscopy. All papers include a high-quality video and are published with a Creative Commons CC-BY license. *Endoscopy E-Videos* qualify for HINARI discounts and waivers and eligibility is automatically checked during the submission process. We grant 100% waivers to articles whose corresponding authors are based in Group A countries and 50% waivers to those who are based in Group B countries as classified by Research4Life (see: <https://www.research4life.org/access/eligibility/>).

This section has its own submission website at

<https://mc.manuscriptcentral.com/e-videos>