

# Chronic Venous Disease: Pathophysiological Aspects, Risk Factors, and Diagnosis

Philip Kienzl<sup>1</sup> Julia Deinsberger<sup>1</sup> Benedikt Weber<sup>1</sup>

<sup>1</sup>Department of Dermatology, Medical University of Vienna, Vienna, Austria

**Address for correspondence** Philip Kienzl, Ap.Prof. Priv.-Doz. Dr. Benedikt Weber, Department of Dermatology, Medical University of Vienna, Vienna, Austria (e-mail: philip.kienzl@meduniwien.ac.at).

Hamostaseologie 2024;44:277–286.

## Abstract

Chronic venous disease (CVD) is highly prevalent in the general population and encompasses a range of pathological and hemodynamic changes in the veins of the lower extremities. These alterations give rise to a variety of symptoms, with more severe forms resulting in venous ulceration, which causes morbidity and high socioeconomic burden. The origins and underlying mechanisms of CVD are intricate and multifaceted, involving environmental factors, genetics, hormonal factors, and immunological factors that bring about structural and functional alterations in the venous system. This review offers the latest insights into the epidemiology, pathophysiology, and risk factors of CVD, aiming to provide a comprehensive overview of the current state of knowledge. Furthermore, the diagnostic approach for CVD is highlighted and current diagnostic tools are described.

## Keywords

- ▶ chronic venous insufficiency
- ▶ ultrasound
- ▶ CEAP
- ▶ genetics

## Part I: Pathophysiological Aspects of Chronic Venous Disease

### Epidemiology

Chronic venous disease (CVD), which was defined by the VEIN-TERM transatlantic interdisciplinary consensus document as “(Any) morphological and functional abnormalities of the venous system of long duration manifested either by symptoms and/or signs indicating the need for investigation and/or care,” is a very common disease entity and clinicians are confronted with CVD patients on a daily basis.<sup>1</sup> At the end of the 1970s, the “Tübingen Study” estimated the frequency of chronic venous insufficiency in the German population at 13%, and only 14% demonstrated no pathologic venous findings.<sup>2</sup> The term “chronic venous insufficiency” is “reserved for advanced CVD, which is applied to functional abnormalities of the venous system producing edema, skin changes, or venous ulcers.”<sup>1</sup> In the early 2000s, the “Bonn Study” showed varicosis without the typical signs of chronic vein insufficiency in 14.3% of the examined population. In contrast, the frequency of advanced stages of CVD, characterized by skin changes up to leg ulcers, at 3.6% were considerably lower than in the “Tübingen Study.”<sup>3</sup> This might

be an indication for higher treatment rates of chronic venous insufficiency at the time of the study given that the high prevalence of venous disease remained constant.<sup>4</sup> The Framingham Study on varicose veins found that while the incidence is higher in women, with associated factors such as obesity and sedentary behavior, men with varicose veins tend to exhibit lower physical activity levels and higher smoking rates.<sup>5</sup>

The San Diego Population Study found ethnic disparities in CVD. Hispanics had the highest visible varicose vein prevalence, while non-Hispanic whites had more trophic changes and deep functional disease. Women showed more superficial venous manifestations but fewer trophic changes and deep functional disease than men. Visible and functional venous diseases were closely linked but not always predictive of each other, highlighting disease complexity.<sup>6</sup>

The prevalence of CVD increases with age and without medical intervention CVD progression is common.<sup>7,8</sup> After 13.4 years, progression of CVD was seen in 57.8% of patients with truncal insufficiency or chronic venous insufficiency in the “Edinburgh Vein Study” (4.3% per year).<sup>9</sup>

received

November 5, 2023

accepted after revision

April 25, 2024

© 2024. Thieme. All rights reserved.  
Georg Thieme Verlag KG,  
Rüdigerstraße 14,  
70469 Stuttgart, Germany

DOI <https://doi.org/10.1055/a-2315-6206>.  
ISSN 0720-9355.

### Venous Anatomy

A consensus regarding the nomenclature of anatomical terminology was achieved by an International Interdisciplinary Committee in 2001 and 2005.<sup>10,11</sup> The three main components of the venous system of the lower limb are (1) the superficial venous system which comprises the great saphenous vein, the small saphenous vein, and their respective tributaries; (2) the deep venous system, responsible for the majority of venous blood flow; and (3) the perforating veins connecting both the superficial and the deep venous system.<sup>12</sup>

Histologically, veins are composed of three individual layers: (1) the innermost layer, tunica intima, is mainly composed of endothelial cells; (2) the muscular layer, tunica media, provides elastic and stabilizing properties to the venous vessel through smooth muscle cells and elastic fibers; (3) the outermost layer, tunica adventitia, is formed by connective tissue and elastic fibers, serving to anchor the vessel to the surrounding tissue, providing both support and elasticity to the vessel. Venous valves ensure the unidirectional flow of blood from the periphery to the central venous system. Valvular function within veins is of paramount importance for maintaining optimal venous blood flow, effectively counteracting abdominal pressure and hydrostatic forces.<sup>13</sup> Venous valves of the lower extremity are most concentrated in the infrapopliteal segment, underscoring their functional significance in this region.<sup>14</sup> Additionally, venous valves can be found in the femoro-popliteal segment, including locations such as the common femoral vein near the inguinal ligament, the superficial femoral vein just beyond the tributary of the deep femoral vein, and in the popliteal vein near the adductor hiatus.<sup>15</sup>

The contractions of the calf muscles during ambulation or running, referred to as “calf muscle pump,” exert pressure on neighboring veins and hence drive venous blood flow against the pull of gravity.<sup>16</sup>

### Pathophysiology

Although the exact details have not been fully elucidated yet, current evidence suggests venous hypertension as the initiating factor of primary CVD. Alterations in the venous wall, which lead to dilation and weakness of the vein and dysfunction of the venous valves, result in reflux of venous blood which subsequently leads to venous hypertension.<sup>15</sup> However, secondary causes of venous hypertension include obstruction of the venous flow (i.e., after thrombosis) or dysfunction of the lower extremity muscle pump as well as congenital factors.<sup>17</sup> Reflux can occur in both the superficial and deep venous systems. In the majority of cases of primary CVD, the saphenous veins are affected, known as truncal insufficiency.<sup>18</sup> Pathological reflux in ultrasound examination is defined by a reflux duration exceeding 0.5 seconds for superficial veins, or > 1.0 second for deep veins.<sup>19</sup> Genetics as well as environmental factors (i.e., standing or sedentary occupation) contribute to the susceptibility, development, and progression of primary CVD, although the exact mechanism needs to be further elucidated.

Under physiological conditions, endothelial cells experience frictional force because of the venous blood flow.

However, elevated venous pressure and dilation of blood vessels lead to a reduction in shear stress, which is detected by endothelial cells resulting in altered cell signaling. This initiates a detrimental cycle in CVD characterized by increased venous blood pressure, structural changes in the venous wall, and inflammation.<sup>20</sup>

The venous lumen is coated with glycoproteins, proteoglycans, and glycosaminoglycans, collectively referred to as glycocalyx, which forms a protective layer over the endothelial cells. This layer serves as a mechanotransducer to relay mechanical signals to the endothelial cells and allows for selective passage of macromolecules. Additionally, it regulates processes such as coagulation and fibrinolysis and inhibits platelet and leukocyte adhesion.<sup>21</sup> Venous hypertension leads to damage of the Glycocalyx, thereby facilitating leukocyte adhesion to the venous wall and transmigration, which are important steps in the inflammation cascade leading to secretion of proinflammatory cytokines, chemokines, growth factors, and proteases.<sup>22,23</sup>

Additionally, in post-capillary venules, which are positioned at the distal part of the venous system, high hydrostatic pressure drives extravasation of leukocytes, proteins, fluids, as well as erythrocytes causing an inflammatory reaction, formation of edema, and hypoxic conditions.<sup>24</sup> Over time, these changes progressively spread along the veins in a centripetal manner and cause structural changes of the venous wall leading to an altered composition of the extracellular matrix, namely, an accumulation of collagen and a reduction of elastin.<sup>25</sup> A pivotal role in the vein remodeling process is attributed to matrix metalloproteinases (MMPs), which are zinc-dependent endopeptidases, able to cleave several extracellular matrix components.<sup>26</sup> MMPs and tissue inhibitor of metalloproteinases exert a substantial influence on the restructuring of blood vessels and are likely to play a pivotal role in the development of varicose veins, where they impact the structural integrity of vein walls.<sup>27</sup> MMP-2 has been shown to induce venous relaxation in a rat model, with activator protein-1 controlling MMP expression in response to strain caused by increased hydrostatic pressure in the venous wall.<sup>28–30</sup> In a study involving 541 CVD patients, the analysis of serum protein levels of MMPs revealed that elevated serum levels of MMP-2, ADAMTS-1, and ADAMTS-7 were associated with the early stages of CVD. Meanwhile, increased serum levels of MMP-1, MMP-8, MMP-9, NGAL, ADAM-10, ADAM-17, and ADAMTS-4 were particularly implicated in patients with CVD-associated skin changes.<sup>31</sup>

In summary, the alteration of the composition of the venous wall leads to decreased elasticity and structural weakness, which, in turn, results in venous reflux, fueling a vicious cycle.<sup>32</sup> In its most severe forms, the pathological changes described earlier lead to destruction of the skin resulting in non-healing ulcerations.<sup>33</sup>

## Part II: Risk Factors

### Environmental Factors

Studies like the Edinburgh Vein Study and surveys in the United States support an age-related rise in prevalence of

CVD.<sup>6,34–36</sup> Influencing factors are increased vein pressure and vessel wall deterioration.<sup>7</sup> A comparison of reflux sites in varicose limbs between two age groups (< 30 years and > 60 years) showed that reflux was primarily observed in saphenous tributaries (25%) and non-saphenous veins (36%) in younger participants, whereas in the older population, the predominant location of reflux was in the saphenous veins (62%).<sup>37</sup>

A major study used machine learning to discover taller height as a risk factor for varicose veins, alongside known factors like age and obesity.<sup>38</sup> Furthermore, a Mendelian randomization study analyzed genetic associations with varicose veins and found that genetically predicted height, body mass index, smoking, and circulating iron levels were linked to an increased risk of varicose veins. Conversely, genetically predicted higher circulating calcium and zinc levels were associated with a reduced risk. These findings suggest that life style factors may potentially be modifiable risk factors for varicose vein development.<sup>39</sup>

A case–control study conducted in France aimed to investigate the potential relationship between tobacco smoking and lower limb venous insufficiency. Results from matching 1,806 cases with controls revealed a significant association between smoking and lower limb venous insufficiency, even after adjusting for known risk factors. The findings suggest that smoking may indeed be a risk factor for lower limb venous insufficiency, consistent with biological and pathophysiological evidence.<sup>40</sup> Although current evidence does not definitively demonstrate an influence of physical activity on varicose veins or CVD, the findings of the VARISPORT study suggest that high physical activity might be detrimental to vein health.<sup>7,41</sup> Regarding oral contraceptives, a recent study revealed an association between their use and a decreased risk of chronic venous insufficiency.<sup>42</sup>

When analyzing hemostatic factors among patients participating in the Edinburgh Vein Study, elevated levels of fibrinogen, tissue plasminogen activator, and von Willebrand factor were observed in individuals with trunk varicose veins and chronic venous insufficiency. However, upon adjusting for confounding factors, these associations were attenuated.<sup>43</sup>

Although primarily based on evidence from studies relying on self-reports, family history constitutes an important risk factor with an overall risk ratio of up to 4.4 ( $p = 0.001$ ).<sup>44</sup>

A systematic meta-analysis, comprising 15 publications, revealed that the mean prevalence of CVD among healthcare workers, who typically have to endure prolonged standing, was 58.5% and the mean prevalence of varicose veins was 22.1%.<sup>45</sup> Both frequencies exceeded those found in the general population.<sup>46</sup> Furthermore, this effect seems to be dependent on increased standing time and increased time in night shift rotation.<sup>47</sup> Another study including hair dressers showed similar results.<sup>48</sup>

Overweight (body mass index: 25.0–29.9 kg/m<sup>2</sup>) and obesity (body mass index  $\geq 30$  kg/m<sup>2</sup>) exhibited a significant correlation with advanced CVD as classified by the clinical, etiologic, anatomic, and pathophysiologic (CEAP) system. This association remained significant after adjusting for

factors such as age, sex, and other confounders.<sup>49</sup> On the other hand, sport was not associated with CVD but is regarded as a measure to prevent further progression of CVD.<sup>50</sup>

The most important risk factor for secondary CVD is previous venous thromboembolic events.<sup>51–53</sup>

Female gender has been widely acknowledged as a risk factor for CVD in the majority of studies with large sample sizes.<sup>54</sup> Factors such as hormonal fluctuations, pregnancy, and anatomical differences in venous structure have been proposed to contribute to this sex disparity in the incidence of venous disease. Additionally, genetic predispositions and lifestyle factors may further modulate the risk profile in females.<sup>7</sup> Specifically, multiparity was associated with an increased risk of venous disease, with women reporting two or more births having a higher relative risk compared with nulliparous women.<sup>55</sup>

Given the notable impact of genetics and immunological factors on venous disease, the subsequent sections of this review will delve into their intricate roles and contributions to the development and progression of CVD.

## Genetics

A noticeable genetic influence underlies the development of primary CVD, with over 60% of CVD patients having family members affected by this disease.<sup>56</sup> Various methods have been employed to investigate the genetic factors associated with CVD. These approaches encompass heritability analysis through familial investigations and exploration of genomic variations, which involves the examination of specific candidate genes or taking a broader approach through genome-wide association studies (GWAS) as well as differential gene expression on mRNA level.<sup>57</sup> However, the development of CVD is a highly intricate and multifaceted process, in which the influence of a single-gene effect alone may have limited impact. Moreover, the significance of a specific genetic variation depends on interactions between one's genotype and environmental factors, with the additional influence of unique epigenetic mechanisms.<sup>58</sup> A multi-ancestry GWAS meta-analysis of 49,765 individuals with varicose veins and over 1 million controls identified 139 risk loci and a genetic overlap between arterial and venous disease. Moreover, it highlighted the pleiotropic effects of obesity and related anthropometric traits on vascular diseases and discovered pathways relevant to varicose vein pathogenesis.<sup>59</sup>

## Heritability Analysis and Familial Investigations

A study including 134 families found a 90% risk for the development of varicose veins if both parents had the condition, 25% for males and 62% for females when one parent was affected, and a 20% risk when neither parent had varicose veins.<sup>60</sup> A Swedish nationwide study found that individuals with affected family members had significantly elevated standardized incidence ratios. Furthermore, an increased risk for spouses suggested a potential role of non-genetic familial factors such as lifestyle in varicose vein development.<sup>61</sup> A study encompassing 16,434

individuals in Germany found that CVD had a heritability of 17.3%. Additionally, age and sex accounted for 10.7% of CVD risk.<sup>62</sup>

### Genome-Wide Association Studies

A GWAS study conducted in the Finnish population, comprising 17,027 cases and 190,028 controls, identified 50 genetic loci associated with varicose veins, 29 of which were novel. These included loci near the *ERG* gene, a transcriptional regulator of embryonic development, cell proliferation, differentiation, angiogenesis, inflammation, and apoptosis, which displayed female-specific effects. Additionally, new associations with varicose veins were discovered for the *TGFB2* (*TGF-β* pathway) and *GJD3* (member of the connexins family) loci. Notably, the study revealed a low-frequency missense variant in the *GJD3* gene associated with a markedly reduced risk of varicose veins (odds ratio = 0.62 [0.55–0.70],  $p = 1.0 \times 10^{-14}$ ).<sup>63</sup> Furthermore, several large GWAS studies exist which corroborate previously characterized genes and also identified several other genes with implication for CVD, including *HFE*, *MTHFR*, *PPP3R1*, *NFATC2*, *THBD*, *SYNM*, *PIEZO1*, *MCP1*, and *COL27A1*.<sup>57</sup>

### Role of Specific Genes and Molecular Pathways

An interesting study from Turkey suggests a potential role of low  $\alpha$ -1-antitrypsin levels in the etiology of CVD, particularly in the CEAP C class 4 group, although the observed increased  $\alpha$ -1-antitrypsin levels in the CEAP C class 5 group may be a reactive response to higher leukocyte esterase levels due to elevated CRP levels, indicating a complex relationship that warrants further investigation.<sup>64</sup>

One of the genes for which a well-established contribution to CVD has been described is forkhead box protein C2 (*FOXC2*), which plays a crucial role in orchestrating interactions between mesenchymal cells during the formation of lymphatic and blood vessels, lymph nodes, and valves, and regulates the expression of key angiogenesis control genes, including delta-like 4, *Hey2*, integrin  $\beta$ 3, *CXCR4*, *Ang2*, among others.<sup>27</sup> Genetic variants within *FOXC2* are associated with CVD risk and alterations in molecular signaling pathways, particularly the Notch pathway.<sup>65–67</sup>

The mRNA expression and protein content of vascular endothelial growth factor-A (*VEGF-A*) and its receptors, *VEGFR1* and *VEGFR2*, were increased in the walls of varicose veins and varicose veins complicated by thrombophlebitis, indicating a possible contribution of these factors to clinical symptoms of varicose veins and their progression.<sup>68</sup>

Additionally, a study utilizing PCR and restriction genotyping revealed that the G allele of *MMP-2*-790 T/G was more common in men with CVD, while the T allele of *MMP-9*-1562 C/T was significantly associated with CVD in both men and women. Additionally, the G allele of *MMP-12* rs7123600 was more prevalent in female CVD patients, particularly those with ulceration, underscoring the potential relevance of these genetic variants.<sup>69</sup>

A novel study in mice revealed that the receptor tyrosine kinase *EPHB4*, associated with lymphatic anomalies, and its ligand, *ephrinB2*, played vital roles in organizing valve-

forming endothelial cells, influencing their reorientation, elongation, polarity, and proliferation, shedding light on a potential novel cause of primary human venous valve aplasia.<sup>70</sup>

### Epigenetic Regulators

Factors regulating mRNA expression such as long non-coding RNAs and microRNAs were shown to be differentially expressed in CVD.<sup>71</sup> Various microRNAs (*miR-17-5p*, *miR-129-5p*, *miR-1297*, *miR-20b-5p*, *miR-33a-3p*) are associated with CVD onset, while specific long non-coding RNAs (*AC114730*, *AC002127*, *AC073342*) could serve as biomarkers for identifying vein incompetence in CVD patients.<sup>72,73</sup> Additionally, microRNAs, including *miR-199a-5p*, *miR-202*, and *miR-301a-3p*, play roles in regulating vascular smooth muscle cells, endothelial damage, and gene expression, contributing to the development and progression of CVD.<sup>74–76</sup>

### Hormonal Factors

Sex hormones, particularly through interaction with estrogen receptors and progesterone receptors, play a significant role in the onset and progression of CVD, predominantly affecting women.<sup>77,78</sup> Varicose veins are associated with increased expression of estrogen and progesterone receptors and decreased expression of androgen receptors in various layers of vein wall.<sup>79</sup> Moreover, the severity and clinical stage of CVD appear to be correlated with the expression of specific ERs, including *ER $\alpha$* , *ER $\beta$* , and G protein-coupled ER.<sup>80</sup>

ERs contribute to venous relaxation and reduced contraction, resulting in more distensible veins, while progesterone inhibits the contraction of vascular smooth muscles, with a more pronounced effect in women due to higher estrogen levels.<sup>81–83</sup> Additionally, estrogens promote the migration of vascular smooth muscle cells and the expression of *MMP-2* and *MMP-9* through ERs, further contributing to CVD development.<sup>84</sup> This hormonal influence may partially explain the strong association between pregnancy, the number of pregnancies, and the development of varicose veins.<sup>85</sup>

### Immunological Factors

Elevated levels of monocyte chemoattractant protein-1, macrophage inflammatory protein 1 $\beta$ , vascular cellular adhesion molecule, along with L-selectin, E-selectin, and intercellular adhesion molecule 1, promote increased leukocyte rolling, adhesion, and migration through the endothelium of the vein wall and valve. This cascade initiates an inflammatory response, characterized by the production of various cytokines such as tumor necrosis factor- $\alpha$ , transforming growth factor- $\beta$  (*TGF-β*), and *IL-1*, as well as MMPs.<sup>86,87</sup>

A study including 23 samples of peripheral blood mononuclear cells from CVD patients, venous ulcer patients, and controls studied the gene expression of interleukin 23 receptor, interleukin 17, retinoic acid receptor-related orphan receptor- $\gamma$ , *TGF-β*, serum and glucocorticoid regulated kinase 1, RAN binding protein 1, and Forkhead Box O1. These genes are involved in the Th17 immune response pathway and except for *RANBP1* showed significantly higher expression in CVD patients compared with controls. In addition,

IL23R, IL17A, and FOXO1 showed excellent diagnostic potential for discriminating CVD from healthy controls (AUC = 1 in ROC analysis). Finally, multivariable analysis identified IL23R, IL17, ROR $\gamma$ , and RANBP1 as potential risk factors for developing CVD and chronic venous leg ulcerations.<sup>88</sup> The significance of venous hypertension in the inflammatory process is underscored by the fact that even just 30 minutes of quiet standing can trigger an inflammatory response.<sup>89</sup>

### Part III: Diagnosis

To establish an accurate diagnosis of chronic venous insufficiency, it is crucial to consider the patient's medical history (including symptoms like nocturnal leg cramps, "heavy legs," evening edema, pruritus, past episodes of thrombosis, and family history of venous issues); conduct a thorough physical examination focusing on skin changes, varicose veins, edema, and ulcer presence; and rule out other possible causes.<sup>90</sup> Currently, ultrasound using a linear probe is the gold standard examination for the diagnosis of CVD.<sup>91</sup> Hach's classification is often used in German-speaking regions to assess the severity of venous reflux, particularly in truncal veins. It categorizes the condition into several stages based on the extent of venous reflux. In case of reflux of the greater saphenous vein, stage I denotes reflux in the groin, in stage II the reflux extends to the femoral region, stage III involves reflux below to the knee, and stage IV encompasses reflux extending down to the ankle.<sup>92</sup>

#### Clinical Signs of CVD

To clinically stage CVD, Widmer et al introduced a system to describe venous disease.<sup>93</sup> It has been developed and applied predominantly in German-speaking countries for many years but gradually got replaced by the more accurate and internationally accepted CEAP classification nomenclature, an acronym standing for clinical (C), etiologic (E), anatomical (A), and pathophysiological (P).<sup>94–96</sup>

The CEAP classification system categorizes CVD into seven clinical stages based on clinical presentation. It comprises four causative factors in the etiologic category, outlines four venous systems in the anatomical classification, and encompasses four pathophysiological factors (**→Table 1**).<sup>94</sup>

#### Ultrasound

In the past, continuous wave Doppler ultrasound using a stencil probe was utilized to measure vein incompetence predominantly in the superficial veins or to assess arterial blood supply by determining the ankle-brachial index.<sup>97</sup> However, because continuous wave ultrasound lacks imaging, color-flow duplex sonography is the method of choice for morphological and functional assessment of the venous system, which can also be used to investigate thromboembolic events with high accuracy.<sup>98</sup>

Nevertheless, in practice, duplex ultrasound of the lower limbs serves as the primary diagnostic tool for chronic venous insufficiency, providing insight into venous anatomy, patency, and flow characteristics.<sup>99</sup> The examination, typically performed in upright positions, allows for the assessment of

**Table 1** CEAP classification system

Code	Description
C0	No visible or palpable signs of venous disease
C1	Telangiectasias or reticular veins
C2	Varicose veins; distinguished from reticular veins by a diameter of 3 mm or more
C2r	Recurrent varicose veins
C3	Edema
C4	Changes in skin and subcutaneous tissue secondary to CVD
C4a	Pigmentation or eczema
C4b	Lipodermatosclerosis or atrophie blanche
C4c	Corona phlebectatica
C5	Healed venous ulcer
C6	Active venous ulcer
C6r	Recurrent active venous ulcer
Ec	Congenital
Ep	Primary
Es	Secondary
Esi	Secondary—intravenous
Esa	Secondary—extravenous
En	No venous cause identified
As	Superficial veins
Ap	Perforating veins
Ad	Deep veins
An	No venous location identified
Pr	Reflux
Po	Obstruction
Pr,o	Reflux and obstruction
Pn	No venous pathophysiology identifiable

Abbreviations: CEAP, clinical, etiologic, anatomic and pathophysiological; CVD, chronic venous disease.

Note: The presence or absence of symptoms for each clinical class attributable to venous disease can be designated by subscript "s" for symptomatic or "a" for asymptomatic.

reflux using various provocation maneuvers. Key parameters assessed include reflux duration and vein diameter, aiding in treatment planning and intervention.<sup>100</sup> Additionally, the creation of a graphical representation ("venous mapping") facilitates accurate interpretation and guides venous interventions. The Valsalva maneuver, achieved by elevating intra-abdominal pressure to induce central to peripheral reflux, is frequently employed to evaluate the sapheno-iliac junction. To assess the more peripheral veins of the lower limb, reflux is induced by applying pneumatic pressure or manually compressing the thigh, calf, or foot. A vein's functionality is assessed using standardized thresholds for reflux time, commonly set at 1 second for the common femoral vein, femoral vein, and popliteal vein reflux, and 0.5 seconds for superficial veins and perforating veins.<sup>19</sup>

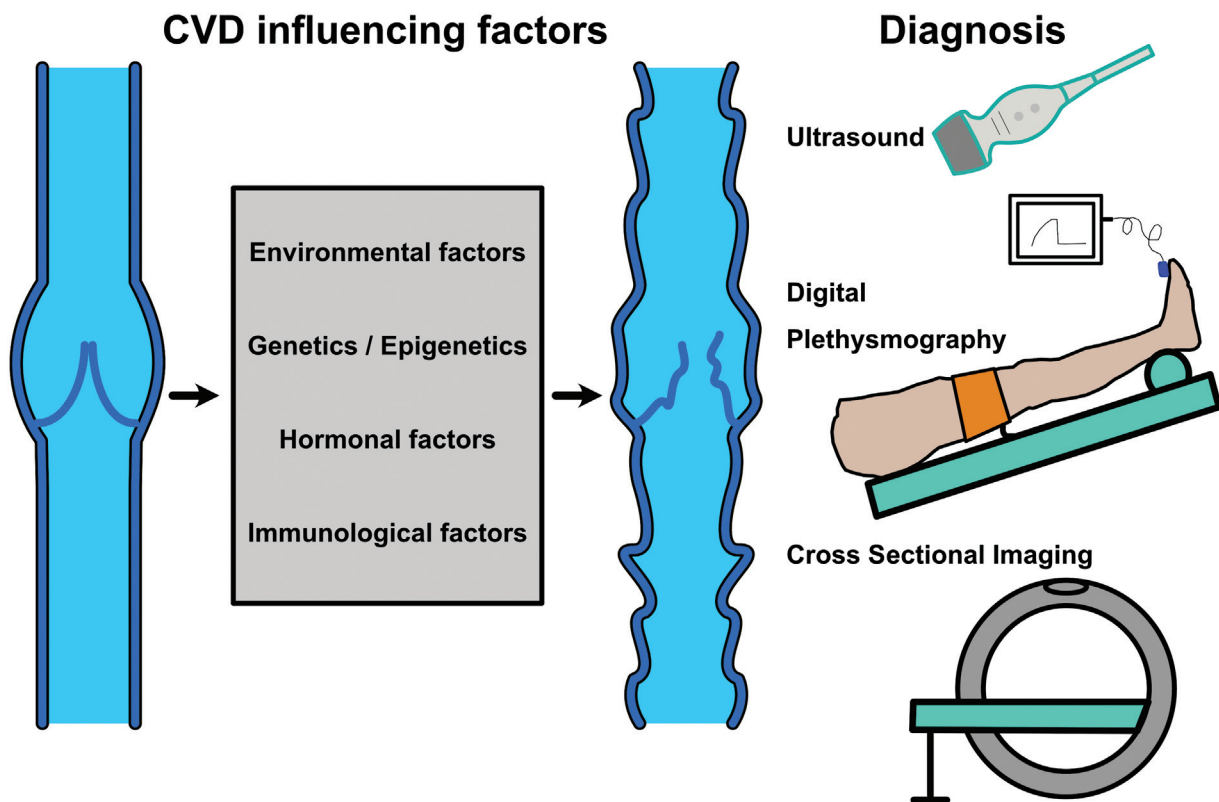
**Digital Plethysmography**

Plethysmography, a noninvasive imaging modality, enables quantitative evaluation of venous dynamics in the lower extremities by application of various physical principles (light, air). Plethysmography offers insights into venous return efficiency and the functioning of the calf muscle pump to detect venous reflux.<sup>101</sup> Photoplethysmography measures the filling time of the subcutaneous venous plexus through the detection of reflected infrared light from hemoglobin. The intensity of light correlates with blood volume in the skin, allowing inferences to be made about changes in blood flow and blood volume in the skin.<sup>102</sup> In venous occlusion plethysmography and air plethysmography, a cuff is placed around the lower leg and a strain gauge or air chambers inside the cuff determine the change of leg circumference, a surrogate for venous capacity and venous drainage.<sup>103,104</sup> Plethysmographic techniques are useful when assessing hemodynamic parameters like ejection fraction or pump performance but are not recommended for diagnosing venous reflux due to their lower accuracy and reproducibility compared with color-flow duplex ultrasound.<sup>105</sup> In practice, digital photoplethysmography, which involves computerized self-standardization and assessment using modern technology, allows for relatively rapid measurements of both amplitude- and time-related parameters.<sup>106</sup> It can be used as a screening test for cardiovascular disease or to assess the overall physiological function of the lower extremity veins due to its noninvasive

nature. However, to confirm and localize the anatomic distribution of the reflux, duplex ultrasound investigation is mandatory.<sup>107</sup> A diagnostic algorithm has been described to categorize patients into three groups using photoplethysmography: normal valvular function, superficial valvular incompetence, and deep valvular incompetence. In case the venous refill time is short (<20 seconds in the sitting position<sup>108</sup> or depending on the source, in the standing position 25 seconds<sup>109,110</sup> or 18 seconds<sup>103</sup>), the measurement should be repeated with a narrow cuff (width of 2.5 cm) placed around the ankle or below the knee. The subsequent return of the venous refill time to normal values indicates superficial reflux, whereas its persistence signifies deep venous or perforating vein reflux.<sup>103,110</sup>

**Cross-Sectional Imaging**

Magnetic resonance imaging (MRI) is not routinely applied for the diagnosis of CVD because of limited resources. However, for the evaluation of pelvic veins, MRI or computed tomography venography represents the methods of choice.<sup>111</sup> Emerging MRI imaging methods that eliminate the need for contrast agents and incorporate analysis using an artificial neural network for quantifying venous reflux are currently under development.<sup>112,113</sup> While widely accessible, CT venography carries both higher contrast exposure and radiation doses compared with alternative imaging techniques. However, it remains a valuable tool for evaluating severe venous obstructions like chronic iliofemoral deep



**Fig. 1** Overview of the influencing factors and diagnosis of chronic venous disease (CVD).

venous thrombosis, tumor compression, and anatomical anomalies like May-Thurner syndrome, offering detailed insights that aid in precise treatment planning.<sup>114</sup>

### Endovenous Imaging

Intravascular ultrasound is primarily employed in diagnosing iliac vein obstructions and is typically recommended for patients seeking treatment, albeit it is worth noting that it is an invasive procedure. This technique provides detailed imaging of the iliac veins, aiding in the precise assessment of venous conditions and guiding therapeutic interventions.<sup>115,116</sup>

### Summary and Conclusion

CVD is a prevalent and multifaceted medical condition with a complex pathophysiology (→Fig. 1). This review has highlighted key pathophysiological aspects, risk factors, and diagnostic approaches associated with this condition. It is evident that CVD arises from a combination of environmental factors, genetics, hormonal factors, and immunological factors, contributing to venous insufficiency and varicose veins. A comprehensive understanding of the pathophysiological processes is essential for effective diagnosis. In terms of diagnosis, this review has underlined the significance of noninvasive imaging techniques, such as duplex ultrasound, in accurately assessing venous function and identifying the severity of the disease.

In conclusion, CVD demands a deep comprehension of its pathophysiology and the multitude of associated risk factors. Leveraging advanced diagnostic tools such as duplex ultrasound empowers healthcare professionals to accurately diagnose and proficiently manage this condition.

### Abbreviations

ABI	ankle-brachial index
CEAP	Clinical, Etiological, Anatomical, and Pathophysiological
CVD	chronic venous disease
FOXC2	forkhead box protein C2
GWAS	genome wide association studies
MMP	matrixmetalloproteinase
MRI	magnetic resonance imaging
TGF-β	transforming growth factor-β
TNF-α	tumor necrosis factor-α
VCAM	vascular cellular adhesion molecule
VEGF	vascular endothelial growth factor

### Conflict of Interest

The authors declare that they have no conflict of interest.

### References

- 1 Eklöf B, Perrin M, Delis KT, Rutherford RB, Gloviczki P American Venous Forum European Venous Forum International Union of Phlebology American College of Phlebology International Union of Angiology. Updated terminology of chronic venous disorders: the VEIN-TERM transatlantic interdisciplinary consensus document. *J Vasc Surg* 2009;49(02):498–501
- 2 Fischer H. Socioepidemiologic study of venous disorders in the adult resident population of the Federal Republic of Germany. In: Voelter W, Jung G, eds. O-(β-Hydroxyethyl)-Rutoside. Springer; 1983:121–134
- 3 Rabe E, Pannier-Fischer F, Bromen K, et al. Bonner Venenstudie der Deutschen Gesellschaft für Phlebologie: Epidemiologische Untersuchung zur Frage der Häufigkeit und Ausprägung von chronischen Venenkrankheiten in der städtischen und ländlichen Wohnbevölkerung. *Phlebologie* 2003;32(01):1–14
- 4 Kahle B, Stücker M. Diagnostik und Therapie der Varikosis. *Aktuelle Derm* 2009;35(06):243–255
- 5 Brand FN, Dannenberg AL, Abbott RD, Kannel WB. The epidemiology of varicose veins: the Framingham Study. *Am J Prev Med* 1988;4(02):96–101
- 6 Criqui MH, Jamosmos M, Fronck A, et al. Chronic venous disease in an ethnically diverse population: the San Diego Population Study. *Am J Epidemiol* 2003;158(05):448–456
- 7 Beebe-Dimmer JL, Pfeifer JR, Engle JS, Schottenfeld D. The epidemiology of chronic venous insufficiency and varicose veins. *Ann Epidemiol* 2005;15(03):175–184
- 8 Pannier F, Rabe E. Progression in venous pathology. *Phlebology* 2015;30(1, Suppl):95–97
- 9 Lee AJ, Robertson LA, Boghossian SM, et al. Progression of varicose veins and chronic venous insufficiency in the general population in the Edinburgh Vein Study. *J Vasc Surg Venous Lymphat Disord* 2015;3(01):18–26
- 10 Caggiati A, Bergan JJ, Gloviczki P, Jantet G, Wendell-Smith CP, Partsch H International Interdisciplinary Consensus Committee on Venous Anatomical Terminology. Nomenclature of the veins of the lower limbs: an international interdisciplinary consensus statement. *J Vasc Surg* 2002;36(02):416–422
- 11 Caggiati A, Bergan JJ, Gloviczki P, Eklof B, Allegra C, Partsch H International Interdisciplinary Consensus Committee on Venous Anatomical Terminology. Nomenclature of the veins of the lower limb: extensions, refinements, and clinical application. *J Vasc Surg* 2005;41(04):719–724
- 12 Youn YJ, Lee J. Chronic venous insufficiency and varicose veins of the lower extremities. *Korean J Intern Med (Korean Assoc Intern Med)* 2019;34(02):269–283
- 13 Goldman MP, Fronck A. Anatomy and pathophysiology of varicose veins. *J Dermatol Surg Oncol* 1989;15(02):138–145
- 14 Baliyan V, Tajmir S, Hedgire SS, Ganguli S, Prabhakar AM. Lower extremity venous reflux. *Cardiovasc Diagn Ther* 2016;6(06):533–543
- 15 Meissner MH, Moneta G, Burnand K, et al. The hemodynamics and diagnosis of venous disease. *J Vasc Surg* 2007;46(Suppl S):4S–24S
- 16 Recek C. Calf pump activity influencing venous hemodynamics in the lower extremity. *Int J Angiol* 2013;22(01):23–30
- 17 Raju S, Knepper J, May C, Knight A, Pace N, Jayaraj A. Ambulatory venous pressure, air plethysmography, and the role of calf venous pump in chronic venous disease. *J Vasc Surg Venous Lymphat Disord* 2019;7(03):428–440
- 18 Meissner MH, Gloviczki P, Bergan J, et al. Primary chronic venous disorders. *J Vasc Surg* 2007;46(Suppl S):54S–67S
- 19 Labropoulos N, Tiongson J, Pryor L, et al. Definition of venous reflux in lower-extremity veins. *J Vasc Surg* 2003;38(04):793–798
- 20 Baeyens N, Bandyopadhyay C, Coon BG, Yun S, Schwartz MA. Endothelial fluid shear stress sensing in vascular health and disease. *J Clin Invest* 2016;126(03):821–828
- 21 Frati-Munari AC. Medical significance of endothelial glycocalyx. *Arch Cardiol Mex* 2013;83(04):303–312
- 22 Giantsos-Adams KM, Koo AJA, Song S, et al. Heparan sulfate regrowth profiles under laminar shear flow following enzymatic degradation. *Cell Mol Bieng* 2013;6(02):160–174

- 23 Castro-Ferreira R, Cardoso R, Leite-Moreira A, Mansilha A. The role of endothelial dysfunction and inflammation in chronic venous disease. *Ann Vasc Surg* 2018;46:380–393
- 24 Raffetto JD. Pathophysiology of wound healing and alterations in venous leg ulcers-review. *Phlebology* 2016;31(1, Suppl):56–62
- 25 Ligi D, Croce L, Mannello F. Chronic venous disorders: the dangerous, the good, and the diverse. *Int J Mol Sci* 2018;19(09):2544
- 26 MacColl E, Khalil RA. Matrix metalloproteinases as regulators of vein structure and function: implications in chronic venous disease. *J Pharmacol Exp Ther* 2015;355(03):410–428
- 27 Serra R, Ssempijja L, Provenzano M, Andreucci M. Genetic biomarkers in chronic venous disease. *Biomarkers Med* 2020;14(02):75–80
- 28 Raffetto JD, Ross RL, Khalil RA. Matrix metalloproteinase 2-induced venous dilation via hyperpolarization and activation of K<sup>+</sup> channels: relevance to varicose vein formation. *J Vasc Surg* 2007;45(02):373–380
- 29 Raffetto JD, Qiao X, Koledova VV, Khalil RA. Prolonged increases in vein wall tension increase matrix metalloproteinases and decrease constriction in rat vena cava: potential implications in varicose veins. *J Vasc Surg* 2008;48(02):447–456
- 30 Pfisterer L, König G, Hecker M, Korff T. Pathogenesis of varicose veins - lessons from biomechanics. *Vasa* 2014;43(02):88–99
- 31 Serra R, Gallelli L, Butrico L, et al. From varices to venous ulceration: the story of chronic venous disease described by metalloproteinases. *Int Wound J* 2017;14(01):233–240
- 32 Ortega MA, Fraile-Martínez O, García-Montero C, et al. Understanding chronic venous disease: a critical overview of its pathophysiology and medical management. *J Clin Med* 2021;10(15):3239
- 33 Bonkemeyer Millan S, Gan R, Townsend PE. Venous ulcers: diagnosis and treatment. *Am Fam Physician* 2019;100(05):298–305
- 34 Laurikka JO, Sisto T, Tarkka MR, Auvinen O, Hakama M. Risk indicators for varicose veins in forty- to sixty-year-olds in the Tampere varicose vein study. *World J Surg* 2002;26(06):648–651
- 35 Franks PJ, Wright DD, Moffatt CJ, et al. Prevalence of venous disease: a community study in west London. *Eur J Surg* 1992;158(03):143–147
- 36 Clark A, Harvey I, Fowkes FGR. Epidemiology and risk factors for varicose veins among older people: cross-sectional population study in the UK. *Phlebology* 2010;25(05):236–240
- 37 Caggiati A, Rosi C, Heyn R, Franceschini M, Acconcia MC. Age-related variations of varicose veins anatomy. *J Vasc Surg* 2006;44(06):1291–1295
- 38 Fukaya E, Flores AM, Lindholm D, et al. Clinical and genetic determinants of varicose veins. *Circulation* 2018;138(25):2869–2880
- 39 Yuan S, Bruzelius M, Damrauer SM, Larsson SC. Cardiometabolic, lifestyle, and nutritional factors in relation to varicose veins: a Mendelian randomization study. *J Am Heart Assoc* 2021;10(21):e022286
- 40 Gourgou S, Dedieu F, Sancho-Garnier H. Lower limb venous insufficiency and tobacco smoking: a case-control study. *Am J Epidemiol* 2002;155(11):1007–1015
- 41 Béliard S, Ferreira D, Thomas H, Mourot L, Tordi N. High physical activity volume is associated with an increase in the calibre of the lower limb veins without impact on functional discomfort: the VARISPORT study. *Eur J Vasc Endovasc Surg* 2023;66(06):856–863
- 42 Xiang Y, Zhou Q, Wu Z, Gou J. Chronic venous insufficiency in a selected nurse population: a cross-sectional study. *Angiology* 2024;75(01):29–35
- 43 Lee AJ, Lowe GD, Rumley A, Ruckley CV, Fowkes FG. Haemostatic factors and risk of varicose veins and chronic venous insufficiency: Edinburgh Vein Study. *Blood Coagul Fibrinolysis* 2000;11(08):775–781
- 44 Komsuoğlu B, Göldeli O, Kulan K, Cetinarslan B, Komsuoğlu SS. Prevalence and risk factors of varicose veins in an elderly population. *Gerontology* 1994;40(01):25–31
- 45 Benn S, Moore Z, Patton D, et al. What is the prevalence of chronic venous disease among health care workers? A scoping review. *Int Wound J* 2023;20(09):3821–3839
- 46 Rabe E, Régnier C, Goron F, Salmat G, Pannier F. The prevalence, disease characteristics and treatment of chronic venous disease: an international web-based survey. *J Comp Eff Res* 2020;9(17):1205–1218
- 47 Xiang Y, Zhou Q, Wu Z, Gou J. Chronic venous insufficiency in a selected nurse population: a cross-sectional study. *Angiology* 2024;75(01):29–35
- 48 Chen CL, Guo HR. Varicose veins in hairdressers and associated risk factors: a cross-sectional study. *BMC Public Health* 2014;14:885
- 49 Vlajinac HD, Marinkovic JM, Maksimovic MZ, Matic PA, Radak DJ. Body mass index and primary chronic venous disease – a cross-sectional study. *Eur J Vasc Endovasc Surg* 2013;45(03):293–298
- 50 Jones WS, Vemulapalli S, Parikh KS, et al. Treatment Strategies for Patients with Lower Extremity Chronic Venous Disease (LECVD). Agency for Healthcare Research and Quality (US); 2017
- 51 Scott TE, LaMorte WW, Gorin DR, Menzoian JO. Risk factors for chronic venous insufficiency: a dual case-control study. *J Vasc Surg* 1995;22(05):622–628
- 52 Mohr DN, Silverstein MD, Heit JA, Petterson TM, O'Fallon WM, Melton LJ. The venous stasis syndrome after deep venous thrombosis or pulmonary embolism: a population-based study. *Mayo Clin Proc* 2000;75(12):1249–1256
- 53 Vlajinac HD, Radak DJ, Marinkovic JM, Maksimovic MZ. Risk factors for chronic venous disease. *Phlebology* 2012;27(08):416–422
- 54 Robertson L, Evans C, Fowkes FGR. Epidemiology of chronic venous disease. *Phlebology* 2008;23(03):103–111
- 55 Dindelli M, Parazzini F, Basellini A, Rabaiotti E, Corsi G, Ferrari A. Risk factors for varicose disease before and during pregnancy. *Angiology* 1993;44(05):361–367
- 56 Radhakrishnan N. The pathophysiology of varicose veins of the lower limb. In: Radhakrishnan N, ed. *Genesis, Pathophysiology and Management of Venous and Lymphatic Disorders*. Academic Press; 2022:95–137
- 57 Costa D, Andreucci M, Ielapi N, et al. Molecular determinants of chronic venous disease: a comprehensive review. *Int J Mol Sci* 2023;24(03):1928
- 58 Smetanina MA, Shevela AI, Gavrilov KA, Filipenko ML. The genetic constituent of varicose vein pathogenesis as a key for future treatment option development. *Vessel Plus* 2021;5:19 <https://www.oaepublish.com/articles/2574-1209.2021.17>
- 59 Levin MG, Huffman JE, Verma A, et al. Genetics of varicose veins reveals polygenic architecture and genetic overlap with arterial and venous disease. *Nat Cardiovasc Res* 2023;2(01):44–57
- 60 Cornu-Thenard A, Boivin P, Baud JM, De Vincenzi I, Carpentier PH. Importance of the familial factor in varicose disease. Clinical study of 134 families. *J Dermatol Surg Oncol* 1994;20(05):318–326
- 61 Zöller B, Ji J, Sundquist J, Sundquist K. Family history and risk of hospital treatment for varicose veins in Sweden. *Br J Surg* 2012;99(07):948–953
- 62 Fiebig A, Krusche P, Wolf A, et al. Heritability of chronic venous disease. *Hum Genet* 2010;127(06):669
- 63 Helkkula P, Hassan S, Saarentaus E, et al; FinnGen. Genome-wide association study of varicose veins identifies a protective missense variant in GJD3 enriched in the Finnish population. *Commun Biol* 2023;6(01):71
- 64 Limandal HK, Kaygın MA, Özkaya AL, et al. The role of alpha-1-antitrypsin in the etiopathogenesis of chronic venous disease: a prospective clinical trial. *Phlebology* 2023;38(01):16–21



- 65 Serra R, Buffone G, de Franciscis A, et al. A genetic study of chronic venous insufficiency. *Ann Vasc Surg* 2012;26(05):636–642
- 66 Surendran S, Girijamma A, Nair R, et al. Forkhead box C2 promoter variant c.-512C>T is associated with increased susceptibility to chronic venous diseases. *PLoS One* 2014;9(03):e90682
- 67 Surendran S, S Ramegowda K, Suresh A, et al. Arterialization and anomalous vein wall remodeling in varicose veins is associated with upregulated FoxC2-Dll4 pathway. *Lab Invest* 2016;96(04):399–408
- 68 Kowalewski R, Małkowski A, Sobolewski K, Gacko M. Vascular endothelial growth factor and its receptors in the varicose vein wall. *Acta Angiologica* 2011;17(02):141–149
- 69 Slonková V, Slonková V Jr, Vašků A, Vašků V Genetic predisposition for chronic venous insufficiency in several genes for matrix metalloproteinases (MMP-2, MMP-9, MMP-12) and their inhibitor TIMP-2. *J Eur Acad Dermatol Venereol* 2017;31(10):1746–1752
- 70 Lyons O, Walker J, Seet C, et al. Mutations in EPHB4 cause human venous valve aplasia. *JCI Insight* 2021;6(18):e140952
- 71 de Franciscis S, Metzinger L, Serra R. The discovery of novel genomic, transcriptomic, and proteomic biomarkers in cardiovascular and peripheral vascular disease: the state of the art. *BioMed Res Int* 2016;2016:7829174
- 72 Biranvand AS, Khosravi M, Esfandiari G, et al. Associations between miR-661, miR-1202, lncRNA-HOTAIR, lncRNA-GAS5 and MMP9 in differentiated M2-macrophages of patients with varicose veins. *Int Angiol* 2018;37(06):451–456
- 73 Zalewski DP, Ruszel KP, Stepniewski A, et al. Dysregulations of MicroRNA and gene expression in chronic venous disease. *J Clin Med* 2020;9(05):1251
- 74 Huang X, Liu Z, Shen L, et al. Augmentation of miR-202 in varicose veins modulates phenotypic transition of vascular smooth muscle cells by targeting proliferator-activated receptor- $\gamma$  coactivator-1 $\alpha$ . *J Cell Biochem* 2019;120(06):10031–10042
- 75 Cao Y, Cao Z, Wang W, Jie X, Li L. MicroRNA-199a-5p regulates FOXC2 to control human vascular smooth muscle cell phenotypic switch. *Mol Med Rep* 2021;24(03):627
- 76 Wang Y, Du J, Liu Y, Yang S, Wang Q. microRNA-301a-3p is a potential biomarker in venous ulcers vein and gets involved in endothelial cell dysfunction. *Bioengineered* 2022;13(06):14138–14158
- 77 Eberhardt RT, Raffetto JD. Chronic venous insufficiency. *Circulation* 2014;130(04):333–346
- 78 Alsaigh T, Fukaya E. Varicose veins and chronic venous disease. *Cardiol Clin* 2021;39(04):567–581
- 79 García-Honduvilla N, Asúnsolo Á, Ortega MA, et al. Increase and redistribution of sex hormone receptors in premenopausal women are associated with varicose vein remodelling. *Oxid Med Cell Longev* 2018;2018:3974026
- 80 Serra R, Gallelli L, Perri P, et al. Estrogen receptors and chronic venous disease. *Eur J Vasc Endovasc Surg* 2016;52(01):114–118
- 81 Raffetto JD, Qiao X, Beauregard KG, Khalil RA. Estrogen receptor-mediated enhancement of venous relaxation in female rat: implications in sex-related differences in varicose veins. *J Vasc Surg* 2010;51(04):972–981
- 82 Kendler M, Makrantonaki E, Tzellos T, et al. Elevated sex steroid hormones in great saphenous veins in men. *J Vasc Surg* 2010;51(03):639–646
- 83 Ropacka-Lesiak M, Kasperczak J, Breborowicz GH. Risk factors for the development of venous insufficiency of the lower limbs during pregnancy – Part 1 [article in Polish]. *Ginekol Pol* 2012;83(12):939–942
- 84 Zhao MY, Zhao T, Meng QY, Zhao L, Li XC. Estrogen and estrogen receptor affects MMP2 and MMP9 expression through classical ER pathway and promotes migration of lower venous vascular smooth muscle cells. *Eur Rev Med Pharmacol Sci* 2020;24(03):1460–1467
- 85 Ismail L, Normahani P, Standfield NJ, Jaffer U. A systematic review and meta-analysis of the risk for development of varicose veins in women with a history of pregnancy. *J Vasc Surg Venous Lymphat Disord* 2016;4(04):518–524.e1
- 86 Raffetto JD. Inflammation in chronic venous ulcers. *Phlebology* 2013;28(Suppl 1):61–67
- 87 Mannello F, Ligi D, Canale M, Raffetto JD. Sulodexide down-regulates the release of cytokines, chemokines, and leukocyte colony stimulating factors from human macrophages: role of glycosaminoglycans in inflammatory pathways of chronic venous disease. *Curr Vasc Pharmacol* 2014;12(01):173–185
- 88 Amato R, Dattilo V, Brescia C, et al. Th17-gene expression profile in patients with chronic venous disease and venous ulcers: genetic modulations and preliminary clinical evidence. *Biomolecules* 2022;12(07):902
- 89 Saharay M, Shields DA, Georgiannos SN, Porter JB, Scurr JH, Coleridge Smith PD. Endothelial activation in patients with chronic venous disease. *Eur J Vasc Endovasc Surg* 1998;15(04):342–349
- 90 Wrona M, Jöckel KH, Pannier F, Bock E, Hoffmann B, Rabe E. Association of venous disorders with leg symptoms: results from the Bonn Vein Study 1. *Eur J Vasc Endovasc Surg* 2015;50(03):360–367
- 91 Coleridge-Smith P, Labropoulos N, Partsch H, Myers K, Nicolaidis A, Cavezzi AUIP. Duplex ultrasound investigation of the veins in chronic venous disease of the lower limbs – UIP consensus document. Part I. Basic principles. *Vasa* 2007;36(01):53–61
- 92 Hach W. Spezielle Diagnostik Der Primären Varikose: Untersuchungen Des Extradiazialen Venensystems Unter Besonderer Berücksichtigung Der Aszendierenden Pressphlebographie. *Demeter*; 1981
- 93 Widmer L, Stähelin H, Nissen C, Da Silva A, Eds. Venen-, Arterien-Krankheiten, Koronare Herzkrankheit Bei Berufstätigen (Basler Studie I–III). *Huber*; 1981
- 94 Eklöf B, Rutherford RB, Bergan JJ, et al; American Venous Forum International Ad Hoc Committee for Revision of the CEAP Classification. Revision of the CEAP classification for chronic venous disorders: consensus statement. *J Vasc Surg* 2004;40(06):1248–1252
- 95 Lurie F, Passman M, Meisner M, et al. The 2020 update of the CEAP classification system and reporting standards. *J Vasc Surg Venous Lymphat Disord* 2020;8(03):342–352
- 96 Porter JM, Moneta GL International Consensus Committee on Chronic Venous Disease. Reporting standards in venous disease: an update. *J Vasc Surg* 1995;21(04):635–645
- 97 McMullin GM, Coleridge Smith PD. An evaluation of Doppler ultrasound and photoplethysmography in the investigation of venous insufficiency. *Aust N Z J Surg* 1992;62(04):270–275
- 98 Santler B, Goerge T. Chronic venous insufficiency – a review of pathophysiology, diagnosis, and treatment. *J Dtsch Dermatol Ges* 2017;15(05):538–556
- 99 De Maeseener MG, Kakkos SK, Aherne T, et al; ESVS Guidelines Committee. Editor's choice - European Society for Vascular Surgery (ESVS) 2022 Clinical Practice Guidelines on the management of chronic venous disease of the lower limbs. *Eur J Vasc Endovasc Surg* 2022;63(02):184–267
- 100 Mendoza E, Blättler W, Amsler F. Great saphenous vein diameter at the saphenofemoral junction and proximal thigh as parameters of venous disease class. *Eur J Vasc Endovasc Surg* 2013;45(01):76–83
- 101 Menzinger G. Modern diagnostic methods of chronic venous insufficiency [article in German]. *Wien Med Wochenschr* 2016;166(9–10):275–277
- 102 Molitor H, Kniajuk M. A new bloodless method for continuous recording of peripheral circulatory changes. *J Pharmacol Exp Ther* 1936;57:6–18
- 103 Nicolaidis AN, Miles C. Photoplethysmography in the assessment of venous insufficiency. *J Vasc Surg* 1987;5(03):405–412

- 104 Janssen MC, Claassen JA, van Asten WN, Wollersheim H, de Rooij MJ, Thien T. Validation of the supine venous pump function test: a new non-invasive tool in the assessment of deep venous insufficiency. *Clin Sci (Lond)* 1996;91(04):483–488
- 105 van Bemmelen PS, van Ramshorst B, Eikelboom BC. Photoplethysmography reexamined: lack of correlation with duplex scanning. *Surgery* 1992;112(03):544–548
- 106 Kerner J, Schultz-Ehrenburg U, Lechner W. Quantitative Photoplethysmographie bei gesunden Erwachsenen, Kindern und Schwangeren und bei Varizenpatienten. *Phlebologie* 1992;21:134–139
- 107 Nicolaides AN. Cardiovascular Disease Educational and Research Trust European Society of Vascular Surgery The International Angiology Scientific Activity Congress Organization International Union of Angiology Union Internationale de Phlebologie at the Abbaye des Vaux de Cernay. Investigation of chronic venous insufficiency: a consensus statement (France, March 5-9, 1997). *Circulation* 2000;102(20):E126–E163
- 108 Abramowitz HB, Queral LA, Finn WR, et al. The use of photoplethysmography in the assessment of venous insufficiency: a comparison to venous pressure measurements. *Surgery* 1979;86(03):434–441
- 109 Schultz-Ehrenburg U, Blazek V. Quantitative digital photoplethysmography (D-PPG): first results with on line registration and significance of VO (venous pump power). In: Schultz-Ehrenburg U, Blazek V, eds. *Advances in Computer Aided Noninvasive Vascular Diagnostics*. VDI Verlag Düsseldorf; 1994
- 110 Blazek V, Schultz-Ehrenburg U, Fronck A, et al. Quantitative Audio-Photoplethysmographie: Eine effektive Screeningmethode für kontinuierliche, akustische Wiederherstellung peripherer Blutvolumenpulse. *Phlebologie* 1996;25:158–164
- 111 Ruehm SG, Wiesner W, Debatin JF. Pelvic and lower extremity veins: contrast-enhanced three-dimensional MR venography with a dedicated vascular coil-initial experience. *Radiology* 2000;215(02):421–427
- 112 Chen CW, Tseng YH, Ngo YG, Yang TY, Huang YK. Vein of Giacomini detected through noncontrast magnetic resonance imaging plus QFlow for guided endovenous ablation. *J Vasc Surg Venous Lymphat Disord* 2022;10(06):1376–1377
- 113 Wong MY, Chen CW, Tseng YH, et al. Noncontrast MRI in assessing venous reflux of legs using QFlow analysis and radial basis function neural network technique. *Sci Rep* 2023;13(01):3263
- 114 Coelho A, O'Sullivan G. Usefulness of direct computed tomography venography in predicting inflow for venous reconstruction in chronic post-thrombotic syndrome. *Cardiovasc Intervent Radiol* 2019;42(05):677–684
- 115 Gagne PJ, Tahara RW, Fastabend CP, et al. Venography versus intravascular ultrasound for diagnosing and treating iliofemoral vein obstruction. *J Vasc Surg Venous Lymphat Disord* 2017;5(05):678–687
- 116 Villalba L, Larkin TA. Transabdominal duplex ultrasound and intravascular ultrasound planimetry measures of common iliac vein stenosis are significantly correlated in a symptomatic population. *J Vasc Surg Venous Lymphat Disord* 2021;9(05):1273–1281