Accepted Manuscript online: 2024-04-10 Article published online: 2024-06-14

Volumizing Threads (Jamber) in the Midface and Managing Side Effects: Clinical Cases

Kyu-Ho Yi, MD, PhD[1,2,*] Soo-Yeon Park, MD[3,*]

[1] Division in Anatomy and Developmental Biology, Department of Oral Biology, Human Identification Research Institute, BK21 FOUR Project, Yonsei University College of Dentistry, Seodaemun-gu, Seoul, The Republic of Korea
[2] Maylin Clinic (Apgujeong), Seoul, (the Republic of) Korea
[3] Division of Aesthetic Made-Young Plastic Surgery Clinic, Seoul, The Republic of Korea

Address for correspondence Kyu-Ho Yi, MD, PhD, Division in Anatomy and Developmental Biology, Department of Oral Biology, Yonsei University College of Dentistry, 50-1 Yonsei-ro, Seodaemun-gu, Seoul, 03722, The Republic of Korea (e-mail: kyuho90@daum.net).

Arch Plast Surg 2024;51:350–355.

Abstract

The clinical application of polydioxanone (PDO) threads, traditionally utilized for tissue lifting, is now being explored for its volumizing effects in midface rejuvenation. The novel approach involves employing PDO volumizing threads to achieve physical augmentation akin to a "solid filler." The study introduces a more convenient insertion method for these threads, prioritizing ease and efficacy. Clinical cases demonstrate the efficacy of volumizing threads in addressing midface concerns, such as nasolabial folds and midcheek grooves. Additionally, the integration of volumizing threads to provide support in sagging areas is examined for achieving natural-looking enhancements. While highlighting positive outcomes, potential side effects like thread protrusion are addressed, along with strategies for their mitigation. Volumizing threads are presented as a suitable procedure for patients wary of traditional fillers or seeking subtle enhancements, with the recommendation of combining them with cog threads for those desiring more pronounced changes in facial contour. In summary, volumizing thread offers a minimally invasive alternative with fewer side effects for midface rejuvenation.

Keywords
- jamber thread
- volumizing thread
- midface rejuvenation
- thread lifting

Introduction

As individuals age, prominent manifestations include a decline in skin elasticity and a reduction in facial volume, attributed to diminished collagen synthesis and the gravitational effects on facial tissues, resulting in facial ptosis. (The Facial Aging Process From the "Inside Out") While cog thread lifting, a technique aimed at facial tightening, has been extensively investigated,[1–4] there exists a relative scarcity of literature regarding volumizing threads dedicated to enhancing facial volume, particularly when contrasted with conventional lifting approaches. Nevertheless, the clinical relevance of volumizing threads remains significant.[5]

The significance of polydioxanone (PDO) threads in aesthetic procedures is well-established. Widely recognized for their tissue-lifting properties, PDO threads are extensively utilized in clinical settings. These threads serve multiple purposes, including the improvement of static wrinkles and addressing areas requiring volumization, making them a preferred option, especially for patients reluctant to undergo hyaluronic acid (HA) filler injections.[6–8]

PDO threads demonstrate strong tensile strength compared with other absorbable threads and have a dissolution period exceeding 6 months. This prolonged duration of effectiveness contributes to their widespread adoption. (What are the

* *These two authors contributed equally as first authors.*

received
January 16, 2024
accepted after revision
April 8, 2024
accepted manuscript online
April 19, 2024
article published online
June 14, 2024

DOI https://doi.org/10.1055/a-2303-5156.
eISSN 2234-6171.

© 2024. The Author(s).
This is an open access article published by Thieme under the terms of the Creative Commons Attribution License, permitting unrestricted use, distribution, and reproduction so long as the original work is properly cited. (https://creativecommons.org/licenses/by/4.0/)
Thieme Medical Publishers, Inc., 333 Seventh Avenue, 18th Floor, New York, NY 10001, USA

Factors that Enable Thread Lifting to Last Longer?, Tissue changes over time after polydioxanone thread insertion: An animal study with pigs, Histological and molecular biological analysis on the reaction of absorbable thread; Polydioxanone and polycaprolactone in rat model) Additionally, despite having a lower elastic limit, PDO threads possess a high elastic modulus, providing robust elasticity due to material rigidity. (Two years' outcome of thread lifting with absorbable barbed PDO threads: Innovative score for objective and subjective assessment., Use of Polydioxanone Threads as an Alternative in Nonsurgical Procedures in Facial Rejuvenation) This firmness offers adequate support to tissues during the initial stages of the procedure and helps maintain lifted skin and tissues to some extent, even during facial movements. (What are the Factors that Enable Thread Lifting to Last Longer?)

When employing conventional PDO cog thread as depicted in ►**Fig. 1**, they can be strategically folded and inserted directly beneath static wrinkles to achieve a volumizing effect. This thread augmentation process yields physical volume augmentation, later complemented by mild local reactions such as edema, lymphocytic infiltration, and fibrosis. Referred to as a "solid filler" in the literature, PDO threads serve as a robust alternative to soft tissue fillers[9]; however, the insertion process for cog threads can be cumbersome due to the need for rotation and withdrawal. To address this, exploration into PDO cog volumizing threads in this study proposes a more convenient insertion method, involving simultaneous use of multiple threads without overlapping.

This innovative technique utilizes tightly wound long threads, similar to a rubber band, to achieve a convenient and effective method of thread compression for volumetric enhancement. Abundant collagen deposition occurs both inside and around the thread, facilitating the formation of a network between reinforced fibrous tissue and the surrounding tissue through the generated collagen (►**Fig. 2**). Furthermore, the thread itself, with its thickness, provides stability and a natural outcome to the deflated area, supporting and lifting the sagging region. When utilized alongside fillers, the spring-shaped scaffold within the thread partially prevents filler migration, enabling the creation of the desired voluminous shape precisely in the targeted location (►**Fig. 3**).

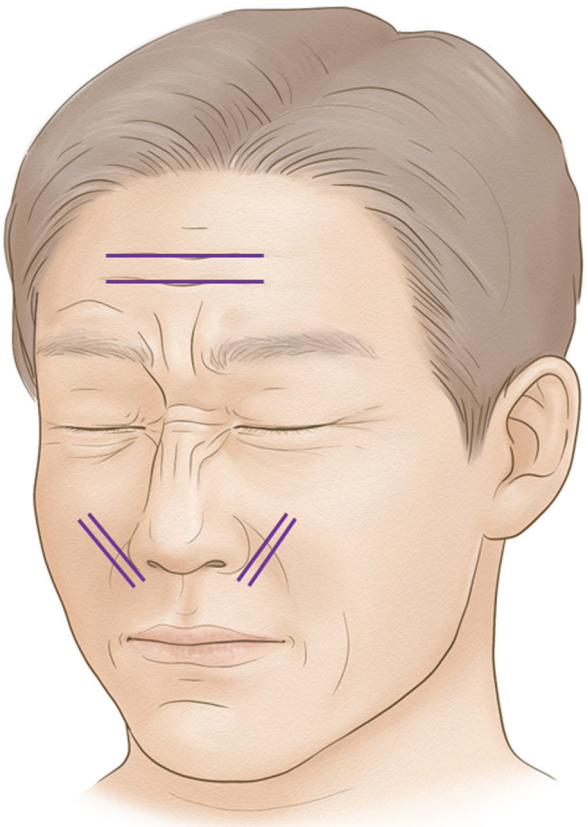

Fig. 1 Demonstrating the use of the conventional polydioxanone cog thread, folded and inserted directly beneath the static wrinkle, resulting in a volumizing effect.

Volumizing Thread (Jamber Thread)

In essence, the introduction of volumizing thread (Licellvi Jamber F [JWorld Co., Ltd.] and countourel Jamber F [Croma

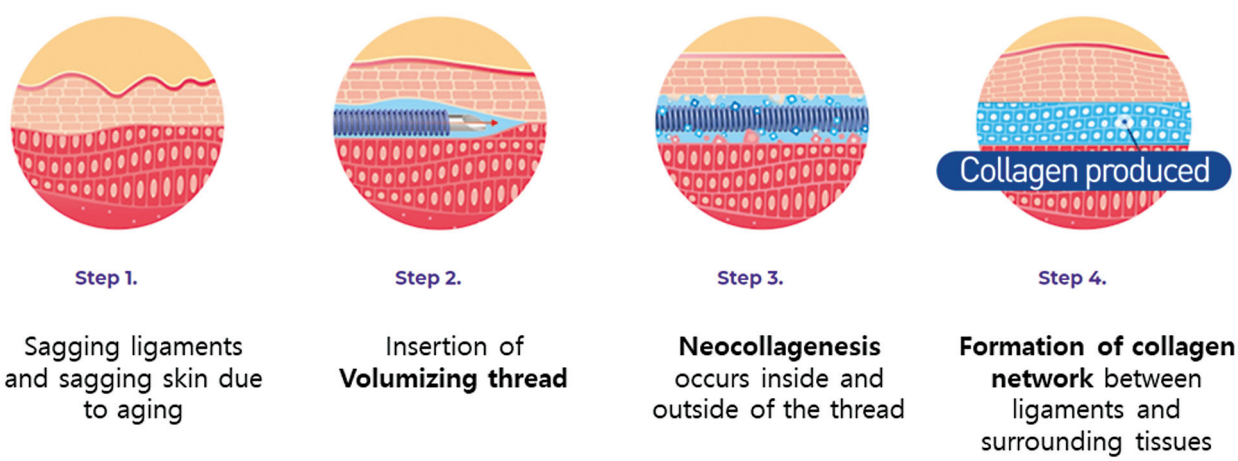

Fig. 2 Demonstrating the process of tightly winding a long thread similar to a rubber band, effectively compressing the thread to increase volume. Abundant collagen forms inside and around the thread, creating a network between the reinforced fibrous tissue and the surrounding area.

Fig. 3 Example of Jamber thread insertion on the anterior cheek (green arrow), nasolabial fold (red), subzygomatic arch depression (blue arrow), vermilion line (yellow), and prejowl sulcus (purple).

Fig. 4 Jamber thread, a volumizing thread, available in various sizes including Jamber I (27G) and Jamber F (21G, 23G), providing flexibility in selection.

Pharma GmbH], ►**Fig. 4**) serves to stabilize the sagging area while concurrently administering filler in that specific location. This approach allows for precise volumizing effects without filler displacement, particularly in regions such as marionette lines or nasolabial folds. The maintained and undistorted appearance can be attributed to the effective action of the thread, which penetrates the skin, smoothing wrinkled lines, enhancing volume, and preventing volume loss through the promotion of collagen regeneration in high-tension areas.

To address the Indian band, a thread is gently inserted, extending slightly beyond the targeted area, as depicted in ►**Fig. 5A**. Similarly, for marionette lines, as shown in ►**Fig. 5B**, the thread is inserted to subtly modify the fold, mitigating volume discrepancies between the adjacent areas. Additionally, a slightly more acute angle is utilized within the fold to achieve volumizing effects. ►**Fig. 5C** illustrates the application of the same technique to marionette lines. Given their relatively superficial insertion, a gauge of 27 is predominantly used.

Fig. 5 To correct the Indian band, a thread is gently inserted, extending slightly beyond the targeted area (**A**). Similarly, in addressing marionette lines (**B**), the thread is inserted to subtly modify the fold, reducing the volume difference between the adjacent areas. Additionally, a slightly more acute angle is employed within the fold to enhance volumizing effects (**C**). Given the relatively superficial insertion depth for marionette lines, a gauge of 27 is commonly utilized.

Fig. 6 Use of Jamber thread on the nasolabial fold. Improvement of nasolabial folds using 21G Jambe threads, with four lines each, totaling eight lines. Positive results are well-maintained up to 2 weeks (**A**), 2 months (**B**), and 6 months posttreatment (**C**).

Prior to treatment, all participants received comprehensive information regarding the potential benefits and risks of the procedure and provided written informed consent.

Case 1

A woman in her forties, reluctant to undergo filler treatment yet seeking to improve her nasolabial folds, opted for 21G Jamber threads. Four lines of threads were individually inserted into each nasolabial fold to improve their appearance. Notable improvement was observed by the second week primarily attributable to the volume provided by the coiling threads. Further reduction in the appearance of nasolabial folds and enhanced overall facial contouring was observed during follow-up assessments in the second month (►**Fig. 6**).

Case 2

In this case (►**Fig. 7**), a 31-year-old male received 21G Jamber threads, with two sutures on each side, targeting the anterior cheek region. Inserted in a manner traversing the zygomaticocutaneous ligament, the initial impact is due to the volume of the threads. Subsequent improvements in the midcheek groove were observed.

Case 3

A 50-year-old woman presented concerned with noticeable tear troughs attributed to midface sagging. To address this concern, 21G Jamber threads were inserted into the anterior cheek, with two threads on each side, aiming to enhance volume. Observations revealed well-maintained volume up to approximately 6 months posttreatment (►**Fig. 8**)..

All patients reported high satisfaction levels following the application of Jamber threads.

Discussion

The phenomenon can be conceptualized as the formation of a collagen tube, which protrudes in the anteroposterior direction, inducing a lifting effect. Essentially, collagen formation results in the creation of a stick that mimics a ligament, thereby supporting the tissue.[7] Even as the thread dissolves with collagen generation, the induced collagen can help maintain volume. Moreover, when Jamber thread and fillers are used concurrently, the filler occupies the space created by the thread, forming a collagen stick that minimizes filler migration. However, instances may arise where the thickness of the thread causes protrusion (►**Fig. 9**). It may protrude

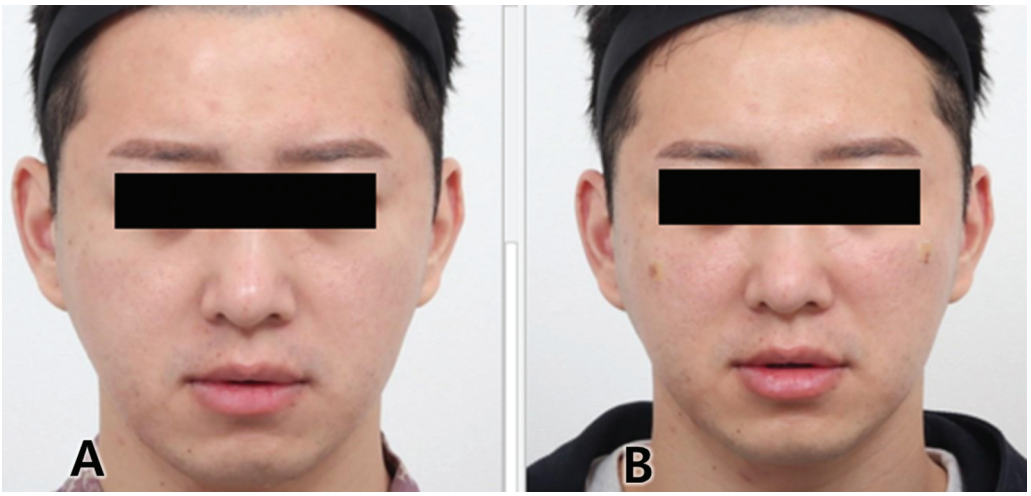

Fig. 7 A 31-year-old male with anterior cheek treatment using Jamber 21G, with two threads inserted each side, immediately postprocedure. By inserting Jamber threads through the zygomaticocutaneous ligament, initial volumization is achieved. Subsequently, collagen formation due to fibroblast infiltration around the polydioxanone further enhances the improvement of the midcheek groove. Before (**A**) and after 2 months of treatment (**B**).

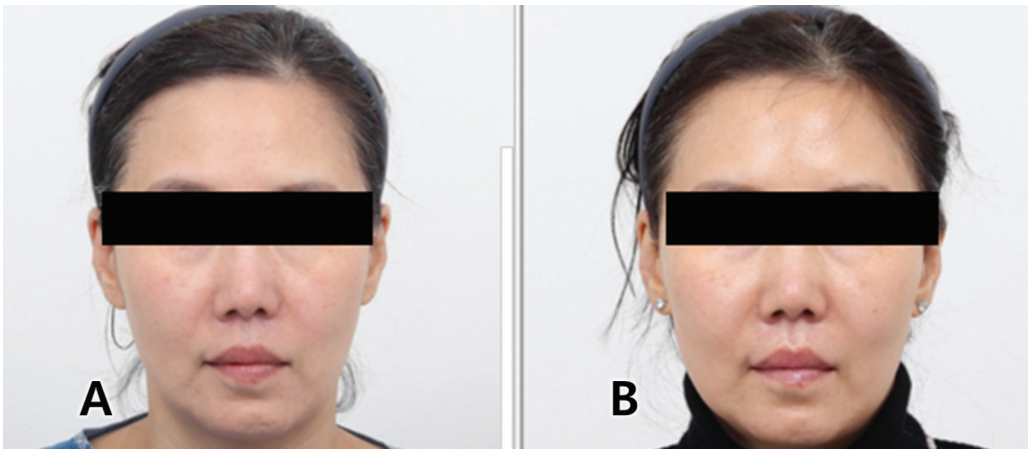

Fig. 8 A 50-year-old female with anterior cheek treatment using volumizing two threads each (**A**), 6 months posttreatment (**B**).

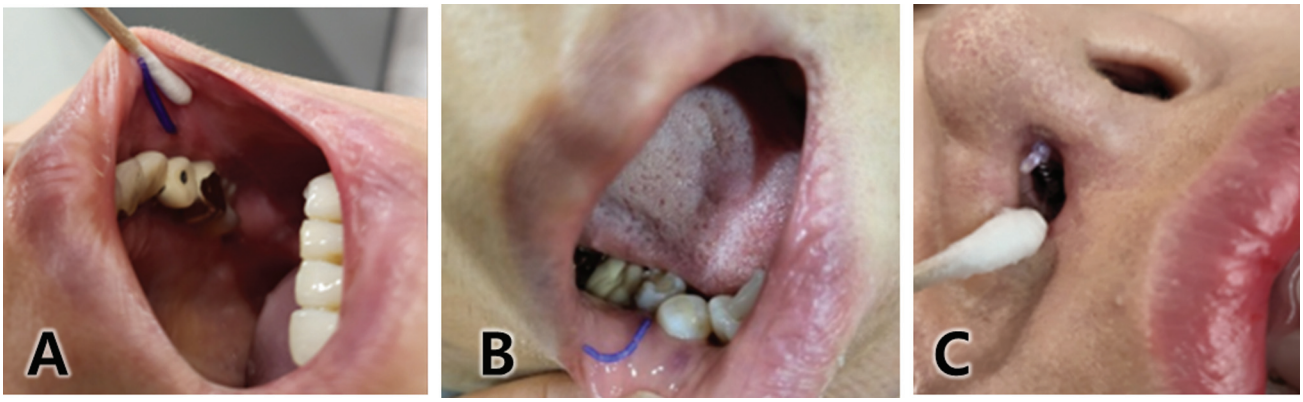

Fig. 9 Protrusion of volumizing thread intraorally (**A, B**) and intranasally (**C**).

into the oral cavity or around the nasal area, and in such cases, gently pulling on the end can release the thread, causing it to be expelled.

For threads that are on the verge of protrusion, creating a slight hole with a needle and carefully extracting it can facilitate removal (►**Fig. 10**). Additionally, if Jamber thread is inserted too superficially, it may come into contact with the dermis, affecting its shape (►**Fig. 11**). While threads inserted superficially typically improve over time, there is a risk of them becoming persistent scar tissue. Options for improvement include removing the thread through a minor incision or performing subcision and injecting substances such as HA to dissolve the thread.

In a study by Su et al[10] conducted on pigs, PDO threads were found to induce mild inflammation and stimulate collagen production, peaking at 12 weeks and persisting until 48 weeks before complete degradation. Additionally, PDO threads exhibited a fibrous bridging effect, enhancing tissue connectivity and thickness without causing severe side effects such as foreign body granuloma. Furthermore, Ha et al[11] found in a study on rat models that PDO threads significantly increased collagen type 1 α1 after approximately 8 weeks, indicating stimulation of fibroblast proliferation and collagen formation through the TGF-β1 signaling system.

In considering alternative methods for midface lifting, such as fillers or additional mesotherapy, it is essential to weigh the potential benefits against any associated risks. Further investigation into the benefit–harm ratio of these non-Jamber applications can provide valuable insights into their efficacy and safety profiles.

Fig. 10 Removal of palpable Jamber near protrusion with the surgical forceps by pulling outward.

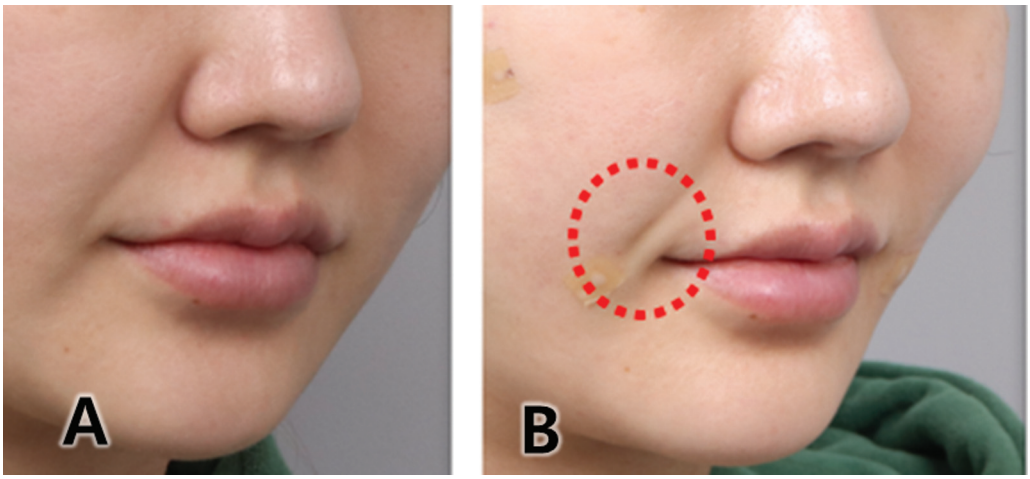

Fig. 11 If the Jamber thread is inserted too superficially, there may be cases where the thread touches the dermis, affecting its shape. Panel (**A**) is before the treatment and Panel (**B**) is the side effect of volumizing thread.

In summary, Jamber threads can provide satisfactory results for individuals with sagging facial areas who may prefer to avoid fillers or those seeking subtle facial enhancements without significant alterations to their overall facial structure. However, when performed alone, it may offer less volume compared with HA fillers. Since it does not directly manipulate the tissues or induce changes in the fascia or skin texture, individuals desiring distinct alterations in facial shape may consider combining it with cog threads. With minimal side effects, situations involving thread protrusion or contact can typically be resolved through gentle removal.

Authors' Contributions
Both the authors have reviewed and approved the article for submission.
Conceptualization: K-H.Y., S-Y.P.
Writing—original draft preparation: K-H.Y., S-Y.P.
Writing—review and editing: K-H.Y., S-Y.P.
Visualization: K-H.Y., S-Y.P.
Supervision: K-H.Y., S-Y.P.

Ethical Approval
This study was conducted in compliance with the principles set forth in the Declaration of Helsinki.

Patient Consent
Prior to treatment, all participants received comprehensive information regarding the potential benefits and risks of the procedure and provided written informed consent.

Funding
None.

Conflict of Interest
None declared.

References
1 Coleman SR, Grover R. The anatomy of the aging face: volume loss and changes in 3-dimensional topography. Aesthet Surg J 2006;26 (1S):S4–S9
2 Gierloff M, Stöhring C, Buder T, Gassling V, Açil Y, Wiltfang J. Aging changes of the midfacial fat compartments: a computed tomographic study. Plast Reconstr Surg 2012;129(01):263–273
3 Gold MH. Use of hyaluronic acid fillers for the treatment of the aging face. Clin Interv Aging 2007;2(03):369–376
4 Kahn JL, Wolfram-Gabel R, Bourjat P. Anatomy and imaging of the deep fat of the face. Clin Anat 2000;13(05):373–382
5 Wu WTL, Mendelson B. Invited discussion on: Mesh suspension thread for facial rejuvenation. Aesthetic Plast Surg 2020;44(03): 775–779
6 El-Mesidy MS, Alaklouk WT, Azzam OA. Nasolabial fold correction through cheek volume loss restoration versus thread lifting: a comparative study. Arch Dermatol Res 2020;312(07):473–480
7 Park YJ, Cha JH, Han SE. Maximizing thread usage for facial rejuvenation: a preliminary patient study. Aesthet Plast Surg 2021;45(02):528–535
8 Wanitphakdeedecha R, Yan C, Ng JNC, Fundarò S Absorbable barbed threads for lower facial soft-tissue repositioning in Asians. Dermatol Ther (Heidelb) 2021;11(04):1395–1408
9 Kang SH, Moon SH, Rho BI, Youn SJ, Kim HS. Wedge-shaped polydioxanone threads in a folded configuration ("Solid fillers"): a treatment option for deep static wrinkles on the upper face. J Cosmet Dermatol 2019;18(01):65–70
10 Su D, Wang S, He T, Wang J. Experimental investigation of biostimulatory effects after polydioxanone thread insertion in a pig model. J Cosmet Dermatol 2024;23(02):658–665
11 Ha YI, Kim JH, Park ES. Histological and molecular biological analysis on the reaction of absorbable thread; Polydioxanone and polycaprolactone in rat model. J Cosmet Dermatol 2022;21(07): 2774–2782