



# Use of Negative Pressure Wound Therapy in Pedicled Flaps can Improve Graft Integration and Minimize Complications

Maria A. Suarez, MD<sup>1,2</sup> Luis F. Latorre, MD<sup>1,3</sup> Jorge I. Quintero, MD, MHPE<sup>1,3</sup> and Hand Microsurgery Research Group

<sup>1</sup>Division of Hand and Microsurgery, Department of Orthopedics and Traumatology, Hospital Universitario Fundación Santa Fe de Bogotá, Bogotá, Colombia

<sup>2</sup>Universidad del Rosario, Bogotá, Colombia

<sup>3</sup>Universidad de los Andes, School of Medicine, Bogotá, Colombia

**Address for correspondence** Jorge I. Quintero, MD, MHPE, Fundación Santa Fe de Bogotá, Carrera 7 n 123-35 piso 10, Bogotá 110111, Colombia (e-mail: jorge.quintero@fsfb.org.co).

J Reconstr Microsurg Open 2024;9:e64–e68.

## Abstract

Negative pressure wound therapy (NPWT) has been used in the treatment of open fractures to improve local wound treatment, to allow skin integration when skin grafting is needed. During the last decade, the use of this device contributes to decreasing the venous congestion in microsurgical procedures in free flaps and finger replantation. The negative pressure increases the vascularization and decreases the edema, allowing the integration of tissue. Nine patients were included in this protocol. These patients had an open wound, and primary healing was not an option. Therefore, reconstructive surgery was needed. One female and eight male patients were included. Five reconstructive surgeries were performed in the lower limb and four in the upper limb due to an open fracture, skin defect secondary to infection, avulsion injury of the upper limb, and electric burn. Following the reconstructive procedure, NPWT was applied immediately peripheral to the pedicled flap. Our protocol indicates that the suction was placed for 5 days, set at continuous pressure of –100 mm Hg. At the end of the treatment, no complications were observed, and full integration of the flap was achieved. NPWT avoids local complications such as hematoma, shearing forces, and infection.

## Keywords

- ▶ NPWT
- ▶ pedicled flaps
- ▶ healing

Negative pressure wound therapy (NPWT) has been widely used in the treatment of open fractures, diabetic foot ulcers, mediastinal wounds, and skin graft integration.<sup>1</sup> NPWT is now being used in the treatment of venous congestion after microsurgical procedures.<sup>2</sup> This case series aims to demonstrate the applicability of NPWT for pedicled flap reconstruction using our institutional protocol.

## Materials and Methods

We present nine patients, one female and eight male patients, who underwent reconstructive surgery of the upper and/or lower extremities secondary to open fractures, open fracture dislocations, electrical burns, infections, exposed hardware, and soft tissue defects after oncological resection. Patients

received

July 18, 2023

accepted after revision

March 8, 2024

accepted manuscript online

March 14, 2024

DOI <https://doi.org/10.1055/a-2287-6535>.

ISSN 2377-0813.

© 2024. The Author(s).

This is an open access article published by Thieme under the terms of the Creative Commons Attribution-NonDerivative-NonCommercial-License, permitting copying and reproduction so long as the original work is given appropriate credit. Contents may not be used for commercial purposes, or adapted, remixed, transformed or built upon. (<https://creativecommons.org/licenses/by-nc-nd/4.0/>)

Thieme Medical Publishers, Inc., 333 Seventh Avenue, 18th Floor, New York, NY 10001, USA

were treated from January 2020 to December 2022 at a large academic institution by our group of microsurgeons. The average age of this cohort was 43.4 years with patients ranging from 27 to 60 years. None of the patients had a prior history of tobacco use, smoking, high blood pressure, or diabetes.

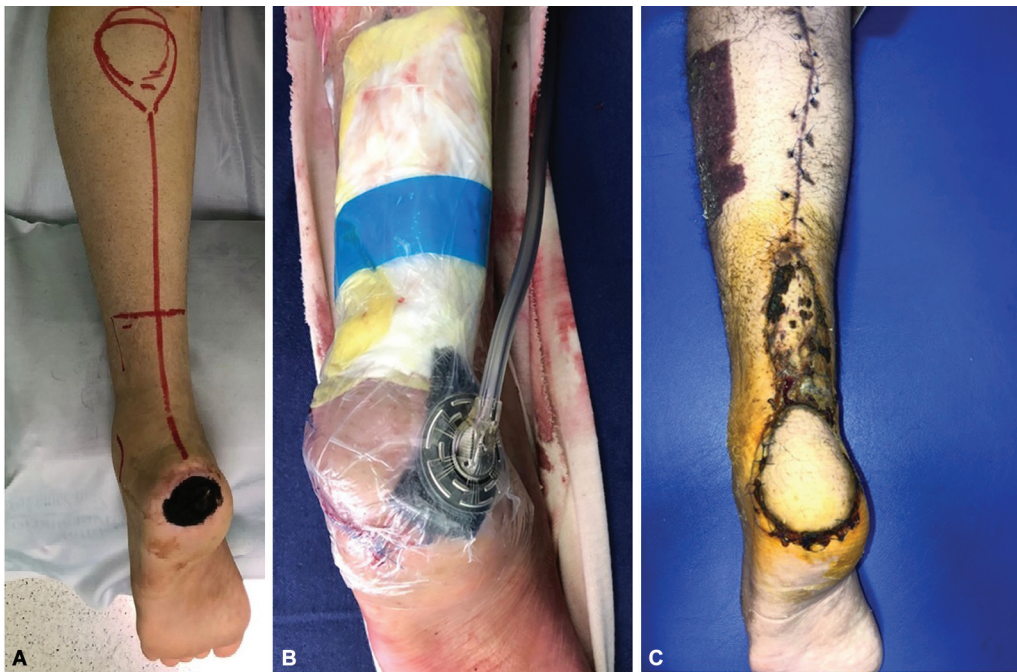NPWT was applied using granufoam (3M V.A.C. USA) on the periphery of the pedicle and the flap was covered with the adhesive; when NPWT is applied peripheral to the flap, neovascularization is increased and established and venous congestion is less likely secondary to the negative pressure. In some cases the pedicle was grafted with a partial thickness skin graft and granufoam was also used to improve integration of the skin around the pedicle. The therapy unit (3M V.A.C. Ultra Therapy System) was connected in a standard fashion over the granufoam. The device was set to continuous suction at  $-100$  mm Hg for 5 days (which is based on our prior experience).<sup>2</sup> The granufoam was placed over the distalmost one-third of the circumference of the flap, away from the pedicle's arterial inflow (which minimizes flap burden). In finger injuries (specially the index finger), the granufoam was applied with the middle finger interposed due to the cumbersome nature of isolated finger NPWT application. Patients who also underwent skin grafting near the pedicle had the NPWT applied to both the flap and the skin graft. The NPWT was removed at bedside in six of the nine patients with use of local anesthesia. All flaps were secured with simple nylon stitches. Three patients required NPWT removal in the operating room due to the location and size of the surgical site. No anti-coagulation protocol was used and the average follow-up was 3.6 months (range: 1–14 months; ►Figs. 1–3)

## Results

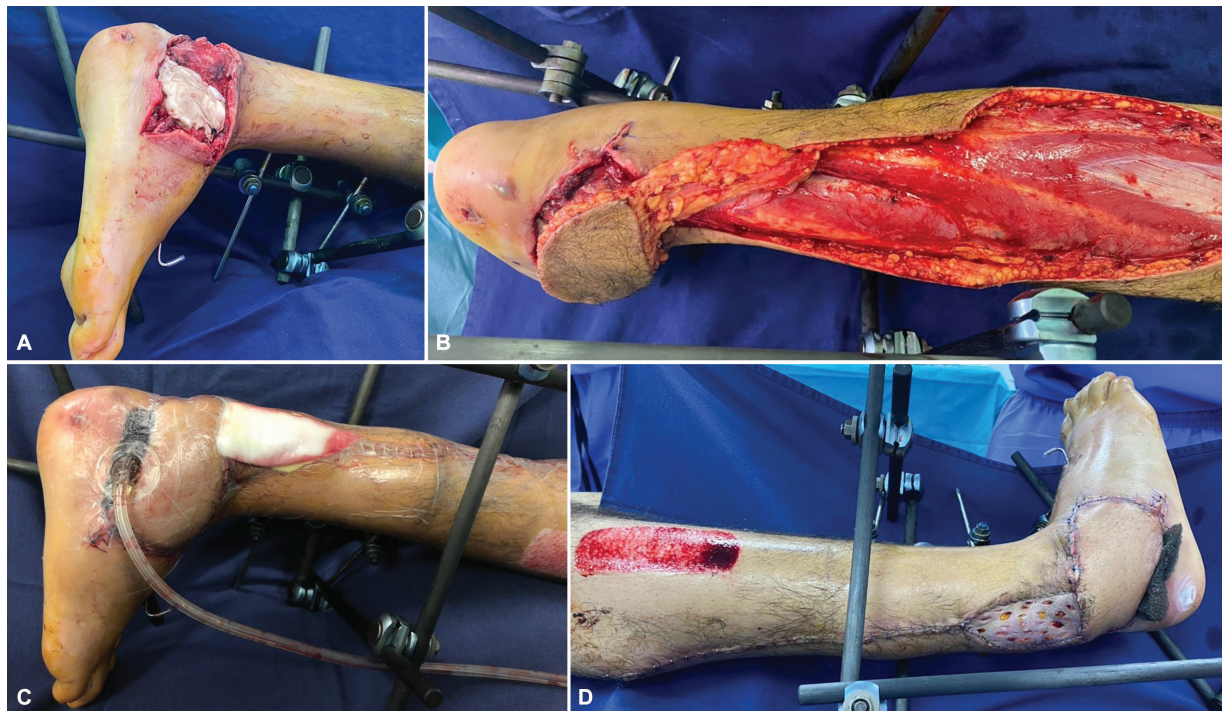
All nine patients underwent NPWT for 5 days without failure or malfunction of the suction device. Four patients underwent upper limb soft tissue reconstruction and five patients underwent lower limb reconstruction. In the only infected patient, irrigation and debridement was performed, antibiotic treatment was administered for 5 days, and soft tissue reconstruction was performed once the infection was controlled. All patients had 100% healing and no complications, such as seroma, dehiscent wound, local necrosis, infection, were identified up to the time of their last follow-up visit. ►Table 1 shows patient details including anatomic location, size of defects, and outcome. Patients' satisfaction was demonstrated with a pain scale of 0 when the patients used the NPWT and after the removal of the device.

## Discussion

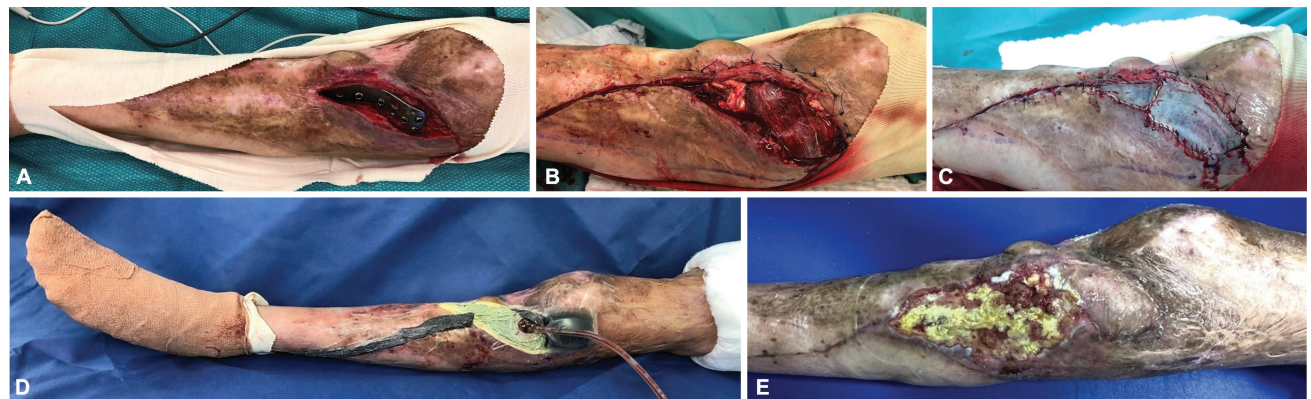
For over 20 years NPWT has been an ally in surgical reconstruction of skin and soft tissue defects. It has proven beneficial in decreasing risk of infection, reducing the number of dressing changes, and allowing faster healing. In animal models, NPWT leads to an increase in granulation tissue formation, blood flow velocity, and capillary caliber as early as 3 days after its use. In addition, it minimizes edema (which allows improvement in oxygen transportation). Following 5 days of NPWT use, there is evidence of fibroblast conversion to fibrocytes, which increases the quality and quantity of the extracellular matrix.<sup>3</sup> This is the reason we



**Fig. 1** (A) Patient #3: heel defect and initial drawing of the flap. (B) Patient #3: immediately postoperative, reverse sural pedicled flap with NPWT. Wet gauze in split-thickness skin graft (STSG) nonincluded in the NPWT. (C) Patient #3: postoperative integration of the flap at 6 weeks. NPWT, negative pressure wound therapy.



**Fig. 2** (A) Patient #8: heel defect with bone cement after fracture dislocation. (B) Patient #8: sural reverse flap. (C) Patient #8: immediately postoperative, reverse sural pedicled flap with NPWT. Wet gauze in split-thickness skin graft (STSG) nonincluded in the NPWT. (D) Patients #8, 5: postoperative, flap integration. NPWT, negative pressure wound therapy.



**Fig. 3** (A) Patient #9: proximal tibia defect and hardware exposure. (B) Patient #9: rotational gastrocnemius flap. (C) Patient #9: split-thickness skin graft. (D) Patient #9: NPWT. (E) Patient #9: 6-week follow-up, full integration of the flap, superficial necrosis of the skin. NPWT, negative pressure wound therapy.

use the NPWT for 5 days in all our patients, increasing the neovascularization rate and decreasing the complications.

Plikaitis and Molnar<sup>4</sup> demonstrated that the use of NPWT with intermittent suction therapy at a setting of  $-125$  mm Hg improves oxygenation and nutrient delivery to the wound bed. Intermittent suction therapy leads to changes in the pattern of blood flow and improves neovascularization in complex wounds. Our findings suggest that either continuous or intermittent therapy allow integration of the flap without complications. Plikaitis and a prior study<sup>2</sup> reported that using NPWT in skin grafts minimizes shear forces, removes exudate, and increases blood flow and NPWT in pedicled grafts also allows for indirect graft immobilization.

Kim and Hong<sup>5</sup> demonstrated that NPWT can remove blood and exudates, minimizing the risk of hematoma and infection. It also noted that continuous therapy was much more tolerable and less painful than intermittent therapy. Additionally, an important reason for maintaining continuous therapy was to avoid any risk of failure of the graft secondary to shearing forces when intermittent therapy is used.

Chim et al<sup>6</sup> used NPWT in 9 of 16 patients who had undergone free flaps for reconstruction of lower extremity defects. They noted that there was no difference in flap survival rates. However, it was noted that flaps treated with NPWT were thinner, which led to an improved cosmetic outcome.

**Table 1** Demographics, diagnosis, type of flap, negative pressure wound therapy information

Case	Age	Sex	Diagnosis	Defect	Area of defect (cm)	Pedicled flap	NPWT application	NPWT type and pressure	Duration (d)	Integration (%)	Complication in receptor area
1	31	Female	Open fracture proximal phalanx index finger	Dorsoradial aspect proximal phalanx index finger	2 × 2	Heterodigital from the ulnar side of the middle finger pedicled flap	Immediately	Continuous –100 mm Hg	5	100	No
2	60	Male	Skin defect mid third of the leg	Mid third of the leg	9 × 7	Reverse sural pedicled flap	Immediately	Continuous –100 mm Hg	5	100	No
3	28	Male	Heel defect secondary to pressure ulcer	Heel	5 × 5	Neurocutaneous sural pedicled flap	Immediately	Continuous –100 mm Hg	5	100	No
4	61	Male	Diabetic foot	Skin defect dorsal aspect of the foot	7 × 5	Supramalleolar pedicled flap	Immediately	Continuous –100 mm Hg	5	100	No
5	37	Male	Thumb ring avulsion	Avulsion distal the MCP joint	7 × 7	Reverse radial forearm pedicled flap	Immediately	Continuous –100 mm Hg	5	100	No
6	48	Male	Upper limb electric burn 25%	Elbow exposure and distal third of the arm	11 × 14	Lattissimus dorsi pedicled flap	Immediately	Continuous –100 mm Hg	5	100	No
7	48	Male	Elbow skin defect after oncological resection of mixofibrosarcoma	Elbow defect	10 × 8	Reverse radial forearm pedicled flap	Immediately	Continuous –100 mm Hg	5	100	No
8	27	Male	Open fracture dislocation of the talus and calcaneus	Skin defect lateral aspect of the ankle	9 × 7	Reverse sural pedicled flap	Immediately	Continuous –100 mm Hg	5	100	No
9	51	Male	Open reduction internal fixation lateral tibial plateau (burn patient)	Skin defect and exposed hardware in the proximal aspect of the knee	9 × 9	Lateral gastrocnemius pedicled flap	Immediately	Continuous –100 mm Hg	5	100	No

Abbreviations: MCP joint, metacarpophalangeal joint; NPWT, negative pressure wound therapy. Note: In patients 5, 6, and 8, NPWT was removed in operating room for pain control and due to the size of the defect.

Bi et al<sup>7</sup> reported the immediate use of NPWT after free tissue transfers in 24 patients. NPWT was used at continuous –125 mm Hg therapy for 7 days. He noted that none of the patients had drained more than 10 mL in a 24-hour period. None of the patients required return to the operating room, and no cases of loss or partial loss were documented.

Eisenhardt et al<sup>8</sup> performed 14 free gracilis flaps with split-thickness skin graft (STSG), 7 rectus abdominis muscle flaps, 4 latissimus dorsi free flaps, and 1 combined latissimus dorsi-serratus anterior muscle flap for lower limb reconstruction. NPWT settings were not described. STSG were applied after the flaps were secured. Only two flaps failed, which again provides evidence of the important role that NPWT may play in avoiding complications and allowing integration in the recipient wound.

Goldstein et al<sup>9</sup> published a total of 10 patients who underwent random flaps for coverage of ankle defects. A total of 17 flaps were performed (which included transposition, rotational, advancement flaps, and rotational pedicled muscles flaps). NPWT was set to –125 mm Hg continuous therapy and was removed on postoperative day 4. Two patients had a small wound dehiscence.

We present 9 flaps with use of NPWT for 5 days set at continuous –100mmHg, with no complications at the end of the follow-up, NPWT would improve neovascularization according to Chen et al,<sup>3</sup> could avoid venous congestion and allow integration. Gabriel et al<sup>10</sup> demonstrated the use of NPWT for 7 days in a lateral local flap of the ankle, which healed without complications.

## Conclusion

NPWT used immediately after the fixation of a pedicled flap avoids local complications such as hematoma, seroma, infection and minimizes the shearing forces that can lead to dehiscence of suture in the recipient area. Less bulky flaps can be the consequence of the NPWT, and control of the pedicled flap can be established with a simple standardization protocol. NPWT does not control the complications during the harvesting process of the flap, and this process depends only on the surgeon's ability.

### Author's Contributions

J.I.Q. helped in conceptualization, methodology, validation, formal analysis, investigation, resources, writing—original draft, writing—review and editing, visualization, supervision. M.A.S. contributed in conceptualization, methodology, validation, formal analysis, investigation,

resources, writing—original draft, writing—review and editing, visualization, supervision. L.F.L. helped in conceptualization, methodology, validation, formal analysis, investigation, resources, writing—original draft, writing—review and editing, visualization, supervision.

### Informed Consent

This case series has institutional review board approval by our institution.

### Funding

The author(s) received financial support from 3M, 2021-ISR-000285 to conduct and publish this research.

### Conflict of Interest

None declared.

## References

- Desai KK, Hahn E, Pulikkottil B, Lee E. Negative pressure wound therapy: an algorithm. *Clin Plast Surg* 2012;39(03):311–324
- Quintero JJ, Cárdenas LL, Achury AC, Vega-Hoyos D, Bermúdez JFSFB Hand and Microsurgery Research Group. Negative pressure wound therapy as a salvage procedure in venous congestion of microsurgical procedures. *Plast Reconstr Surg Glob Open* 2021;9(08):e3725
- Chen SZ, Li J, Li XY, Xu LS. Effects of vacuum-assisted closure on wound microcirculation: an experimental study. *Asian J Surg* 2005;28(03):211–217
- Plikaitis CM, Molnar JA. Subatmospheric pressure wound therapy and the vacuum-assisted closure device: basic science and current clinical successes. *Expert Rev Med Devices* 2006;3(02):175–184
- Kim EK, Hong JP. Efficacy of negative pressure therapy to enhance take of 1-stage allodermis and a split-thickness graft. *Ann Plast Surg* 2007;58(05):536–540
- Chim H, Zoghbi Y, Nugent AG, Kassira W, Askari M, Salgado CJ. Immediate application of vacuum assisted closure dressing over free muscle flaps in the lower extremity does not compromise flap survival and results in decreased flap thickness. *Arch Plast Surg* 2018;45(01):45–50
- Bi H, Khan M, Li J, Pestana IA. Use of incisional negative pressure wound therapy in skin-containing free tissue transfer. *J Reconstr Microsurg* 2018;34(03):200–205
- Eisenhardt SU, Momeni A, Iblher N, et al. The use of the vacuum-assisted closure in microsurgical reconstruction revisited: application in the reconstruction of the posttraumatic lower extremity. *J Reconstr Microsurg* 2010;26(09):615–622
- Goldstein JA, Iorio ML, Brown B, Attinger CE. The use of negative pressure wound therapy for random local flaps at the ankle region. *J Foot Ankle Surg* 2010;49(06):513–516
- Gabriel A, Pfaffenberger M, Eldenburg E. Successful salvage of a lower extremity local flap using multiple negative pressure modalities. *Plast Reconstr Surg Glob Open* 2020;8(06):e2801