

Persistent and Poor-Responsive Cystoid Macular Edema after Stereotactic Radiotherapy in Neovascular Age-Related Macular Degeneration: A Case Report of Three Patients

Persistierendes und schlecht ansprechendes zystoides Makulaödem nach stereotaktischer Strahlentherapie bei neovaskulärer altersabhängiger Makuladegeneration: ein Fallbericht von 3 Patienten



Background

Low-Dose stereotactic radiotherapy (SRT) is an adjuvant therapy for wet AMD, proved to reduce anti-VEGF treatment frequency [1, 2]. SRT provides stereotactic application of low-energy X-ray radiation to the retina, through a device capable to deliver radiation over a 4-mm treatment zone in a single treatment session [3]. SRT radiations attenuate the inflammatory response that is believed to play an important role in choroidal neovascularization (CNV) reactivation. They can also reduce scar formation by inhibiting fibroblasts and lead to the death of rapidly dividing endothelial cells, the main pathological component of CNV complexes [3]. SRT treatment, although still an experimental treatment, is known to be a safe and efficient procedure, but some long-term side effects are known. Radiation retinopathy (RR) is the most dreaded long-term complication of radiotherapy to the eye but because the SRT device delivers precisely targeted radiotherapy, and as the area of retinal exposure is extremely small a larger area of RR is not expected to develop [4–6].

However, microvascular abnormalities (MVAs) are a sign of ionizing radiation damage, with an incidence of 36% in patients treated with SRT at 2 years [4–6]. Retinal MVA found in color fundus photography, fluorescein angiography and/or A-OCT included nerve fibre infarcts, retinal haemorrhages, microaneurysms, luminal irregularities, focal areas of capillary closure, distended (bullous) arteriolar and venular tips, telangiectatic segments, and late staining of the vessel walls [4, 5]. Here, we present three typical cases with initial good response to SRT including reduction of injection frequency but developing a persistent and poorly responsive cystoid macular edema.

History and Signs

A large number of patients with diagnosis of wet AMD were regularly treated in our clinic with intravitreal anti-VEGF therapy (ranibizumab, aflibercept, faricimab) according to a Treat and Extend regimen (TER) [7]. However, a considerable proportion of patients needed 4-weekly treatment, and for this reason a few of them underwent SRT as an adjunct treatment

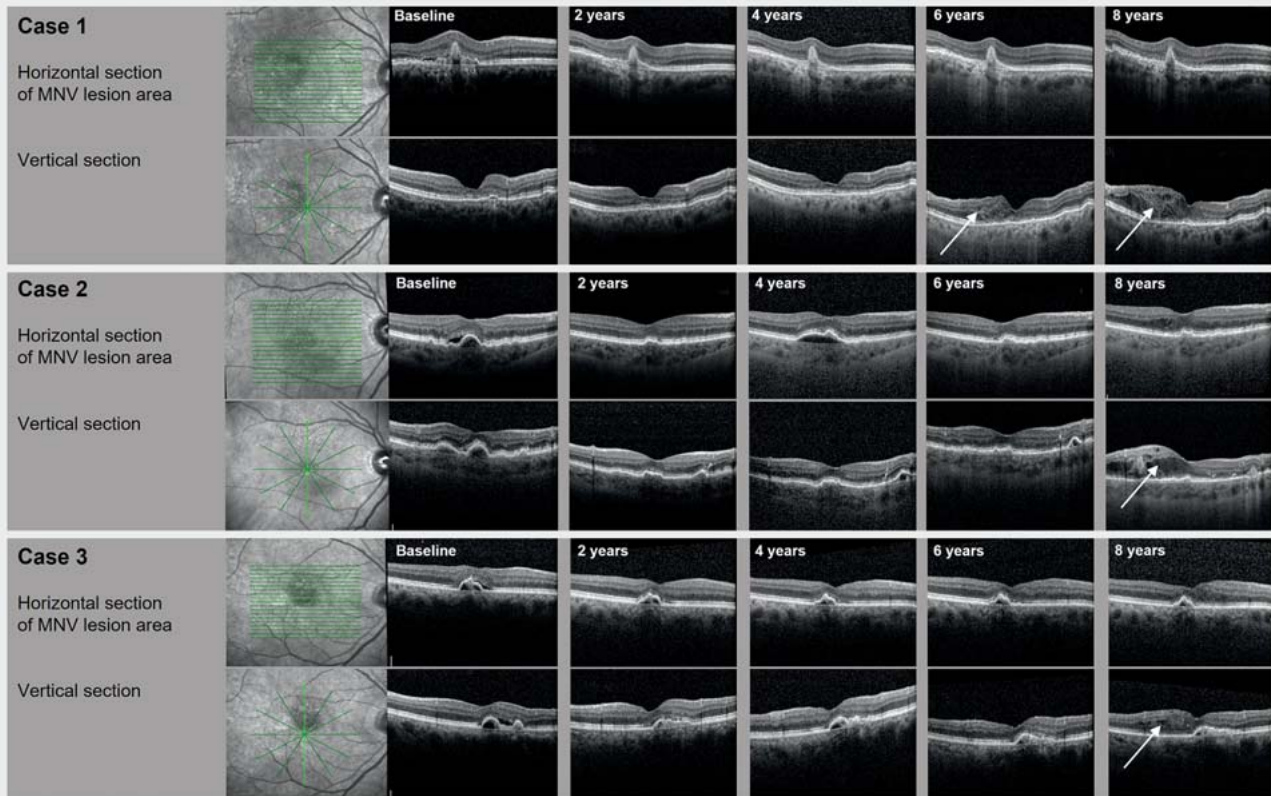
applying a 16-Gy single dose to an area of 4 mm diameter centered to the fovea (IRAY System; initially Oraya Therapeutics, Newark, CA, USA now Carl Zeiss Meditec AG, Jena, Germany). The three reported cases were treated with SRT between 2014 and 2015; anti-VEGF treatment is described at ► **Table 1**.

Case 1

A 65-year-old female had been treated in her right eye for a type 1 MNV (Macular neovascularization) including polypoid parts with 11 ranibizumab injections within 10 months and still showed MNV activity (treatment interval 4 weeks). Within month 11 after diagnosis SRT was performed (09/2014). 5 months after adjunct SRT treatment intra- and subretinal fluid had completely resolved and ranibizumab treatment intervals were extended up to 12 weeks; 21 months after SRT regular exit of the TER followed. After 8 months of follow-up without activity and treatment a recurrence occurred and anti-VEGF treatment was restarted and performed applying ranibizumab/aflibercept injections within 6 to 8 weekly intervals according to TER up to almost year 6 after SRT. Then a

► **Table 1** Anti-VEGF Therapy: treatment and Follow-up.

	Pretreatment	Treatment at SRT Baseline	Treatment at 2 years after SRT	Treatment at 4 years after SRT	Treatment at 6 years after SRT	Treatment at 8 years after SRT
Case 1	11× ranibizumab	ranibizumab 4-weekly	no anti-VEGF treatment, regular TER exit reached	aflibercept 8-weekly	aflibercept 4-weekly	aflibercept 4-weekly, start faricimab 4-weekly
Case 2	3× ranibizumab, 10× aflibercept	aflibercept 4-weekly	aflibercept 7-weekly	aflibercept 4-weekly	aflibercept 4-weekly	faricimab 4-weekly
Case 3	28× ranibizumab, 3× aflibercept	aflibercept 4-weekly	aflibercept 10-weekly	aflibercept 4-weekly	aflibercept 6-weekly	aflibercept 4-weekly



► **Fig. 1** OCT follow-up showing stable regression of MNV activity (horizontal sections across MNV area) and development of radiation retinopathy associated macular edema (white arrows) at inferior macular regions (not related to primary MNV area).

cystoid macular edema developed in the inferior macular region which was not related to the primary MNV (► **Fig. 1**).

Case 2

A 78-year-old female received adjunct SRT (02/2015) in her right eye for a persisting active type 1 MNV after pretreatment with 3× ranibizumab/10× aflibercept injections within 12 months (treatment interval 4 weeks). Nine months after SRT extension of treatment intervals started due to resolution of all fluid; aflibercept treatment intervals could be extended up to 8 weeks. About 2.5 years after SRT intervals needed to be shortened again and during further follow-up all extension attempts failed. At year 6 after SRT first intraretinal cysts in the lower macular region appeared and continued to increase despite continued 4-weekly anti-VEGF treatment (► **Fig. 1**). Fluorescein angiography revealed microvascular abnormalities including a retinal aneurysm in this area (► **Fig. 2**).

Case 3

A 68-year-old male showed persisting active type 1 MNV after 28 ranibizumab/3 aflibercept injections with a 4-week treatment interval and therefore, received adjunct SRT (02/2014). After a first failed treatment interval extension attempt to 6 weeks as early as 4 months after SRT further attempts from month 7 onwards succeeded with reaching the maximum interval of 14 weeks about 3 years after SRT. Almost 4 years after SRT, due to a recurrence of MNV activity TER at short intervals (4 weeks) was restarted but during years 5–8 longer intervals up to 10 weeks could be reached. At 8 years follow-up visit new intraretinal fluid in the inferior macular region which was not related to the primary MNV was observed (► **Fig. 1**).

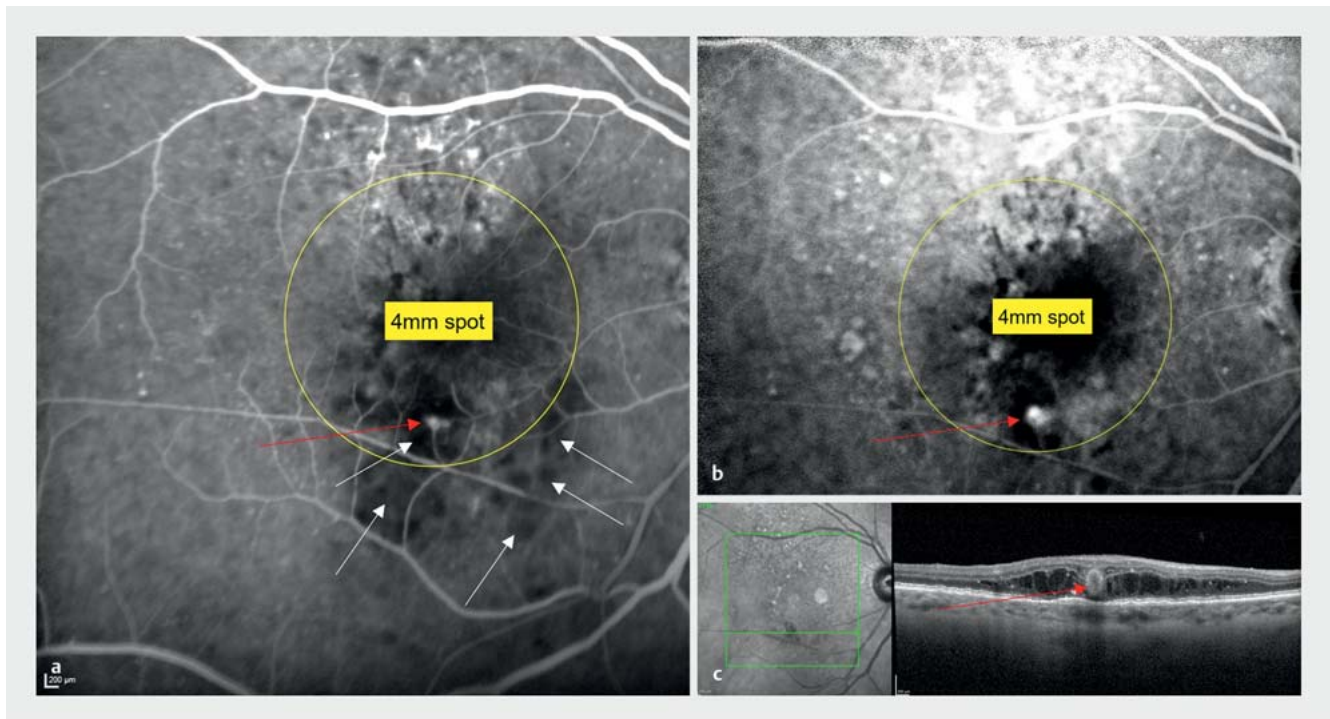
Therapy and Outcomes

6–8 years after SRT, the three described cases showed a new cystoid macular edema in the inferior macular region while

the primary MNV lesion had no or only mild activity. In all three cases neither interval shortening to 4 weeks (with aflibercept) nor switch to faricimab led to edema resolution. In case 3 an intravitreal dexamethasone implant treatment applied at year 9 after SRT led to an increase in macular edema 2 months after implantation. To date all three patients are treated with 4-weekly faricimab injections without successful treatment interval extension.

Discussion

Like in previous studies in our three cases SRT as adjunctive therapy to intravitreal injections of anti-VEGF for nAMD provided an extension of anti-VEGF treatment interval for years [1, 2]. After about 3–4 years, a considerable proportion of patients show MVA that could be attributed to SRT and are most frequently localized in the inferior parafoveal and nasal region [4–6]. Also in the three patients described in this report a prominent involvement of the



► **Fig. 2** Fluorescein angiography in early (a) and late (b) phase (Case 2) at year 8 after SRT. The yellow circle shows the 4 mm treatment spot, white arrows small areas of capillary nonperfusion and the red arrow a retinal aneurysm with late phase leakage. The horizontal SD-OCT (c) scan shows a section through the retinal aneurysm (red arrow).

parafoveal inferior region previously irradiated with SRT was shown. It has been discussed that the inferior part of the retina is exposed to higher doses compared with the upper part caused by the entrance of all three beams from the inferior sclera to avoid a relevant dose to the radiosensitive lens [5].

Beside the known types of microvascular abnormalities further vascular changes like polypoidal choroidal vasculopathy [8] and sub foveal choroidal thickness thinning secondary to SRT have been described [9]. This is the first report, describing three cases with additional long-term massive cystoid edema unresponsive to anti-VEGF therapy after SRT. After radiation therapy involving larger areas than SRT macular edema is a known complication that can often be difficult to treat [10]. Like used in our cases, the first-line treatment is usually intravitreal injection of anti-VEGF drugs, but intravitreal dexamethasone implants are described to be an option for those with poor anti-VEGF

response [9]. In our case 3 dexamethasone implant led to an increase in edema compared to anti-VEGF treatment. Beside steroids new bispecific agents might be a further option.

Our findings demonstrate a possible sight threatening long-term complication of adjunctive SRT therapy to the standard anti VEGF treatment in patients with nAMD. Even in small radiation treated retinal areas like with SRT radiation retinopathy accompanied by cystoid macular edema can occur late after exposure. Ophthalmologists should be aware that regular long-term follow-up is crucial in patients receiving SRT for nAMD. Multimodal imaging with fluorescein angiography, OCT, and OCTA can detect changes which might be difficult to treat.

Conflict of Interest

The authors declare that they have no conflict of interest.

Authors

Filippo Billia^{1,2} , Katja Hatz-Wurziger^{1,3}

- 1 Ophthalmology, Vista Augenklinik Binningen, Switzerland
- 2 Ophthalmology, Avanti Clinica Oculistica, Lugano, Switzerland
- 3 Ophthalmology, Faculty of Medicine, University of Basel, Switzerland

Correspondence

Dr. Filippo Billia
Ophthalmology
Vista Augenklinik Binningen
Hauptstraße 55
4102 Binningen
Switzerland
Phone: + 41 (0) 6 14 26 6000
Fax: + 41 (0) +41 6 14 26 60 01
filippo.billia@vista.ch

References

- [1] Jackson TL, Chakravarthy U, Slakter JS et al.; INTREPID Study Group. Stereotactic radiotherapy for neovascular age-related macular degeneration: year 2 results of the INTREPID study. *Ophthalmology* 2015; 122: 138–145

- [2] Hatz K, Zimmermann F, Kardamakis D et al. Low-Energy Stereotactic Radiotherapy for Treatment of Exudative Age-Related Macular Degeneration in a Treat-and-Extend Regimen. *Ophthalmic Surg Lasers Imaging Retina* 2018; 49: 86–93
- [3] Cantley JL, Hanlon J, Chell E et al. Influence of eye size and beam entry angle on dose to non-targeted tissues of the eye during stereotactic x-ray radiosurgery of AMD. *Phys Med Biol* 2013; 58: 6887–6896
- [4] Freiberg FJ, Michels S, Muldrew A et al. Microvascular abnormalities secondary to radiation therapy in neovascular age-related macular degeneration: findings from the INTREPID clinical trial. *Br J Ophthalmol* 2019; 103: 469–474
- [5] Hatz K, Zimmermann F, Lazaridis E et al. Microvascular abnormalities and long-term efficacy after stereotactic radiotherapy under continued intravitreal anti-VEGF treatment for neovascular AMD. *Br J Ophthalmol* 2022; 106: 415–421
- [6] Evans JR, Igwe C, Jackson TL et al. Radiotherapy for neovascular age-related macular degeneration. *Cochrane Database Syst Rev* 2020; 8: CD004004. doi:10.1002/14651858.CD004004.pub4
- [7] Hoffmann L, Hatz K. External Limiting Membrane Disruption Predicts Long-Term Outcome in Strict Treat-And-Extend Regimen in Neovascular Age-Related Macular Degeneration. *Front Med (Lausanne)* 2021; 8: 706084
- [8] Steinemann A, Hoffmann L, Hatz KB. Polypoidal Choroidal Vasculopathy after Stereotactic Radiotherapy for Neovascular Age-Related Macular Degeneration: A Case Report with Long-Term Follow-Up. *Case Rep Ophthalmol* 2021; 12: 299–305
- [9] Prasuhn M, Kurz M, Grisanti S et al. Three-year clinical and optical coherence tomography follow-up after stereotactic radiotherapy for neovascular age-related macular degeneration. *Adv Med Sci* 2021; 66: 215–220
- [10] Fallico M, Chronopoulos A, Schutz JS et al. Treatment of radiation maculopathy and radiation-induced macular edema: A systematic review. *Surv Ophthalmol* 2021; 66: 441–460

Bibliography

Klin Monatsbl Augenheilkd 2024; 241: 459–462

DOI 10.1055/a-2276-6309

ISSN 0023-2165

© 2024. The Author(s).

This is an open access article published by Thieme under the terms of the Creative Commons Attribution-NonDerivative-NonCommercial-License, permitting copying and reproduction so long as the original work is given appropriate credit. Contents may not be used for commercial purposes, or adapted, remixed, transformed or built upon. (<https://creativecommons.org/licenses/by-nc-nd/4.0/>)

Georg Thieme Verlag KG, Rüdigerstraße 14,
70469 Stuttgart, Germany

