

Is Appendectomy During Late Stages of Pregnancy Associated with an Increased Cesarean Delivery Rate? – a Retrospective Analysis of One Center During 10 Years

Gibt es einen Zusammenhang zwischen Appendektomie in der späten Schwangerschaft und einer höheren Rate an Kaiserschnittentbindungen? – eine retrospektive monozentrische 10-Jahres-Analyse



Authors

Julia Kummer¹ , Josefine Koenigbauer², Falko Stephan Joachim Peters¹, Christian Rickert³, Lars Hellmeyer¹

Affiliations

- 1 Department of Obstetrics and Gynecology, Klinikum im Friedrichshain, Berlin, Germany
- 2 Department of Obstetrics, Charité University Hospital, Berlin, Germany
- 3 Department of Pathology, Klinikum im Friedrichshain, Berlin, Germany

Keywords

appendectomy in pregnancy, appendicitis in pregnancy, cesarean section, surgical intervention pregnancy, imaging diagnostics appendicitis

Schlüsselwörter

Appendektomie in der Schwangerschaft, Appendizitis in der Schwangerschaft, Sectio caesarea, operativer Eingriff in der Schwangerschaft, diagnostische Bildgebung und Appendizitis

received 3.11.2023

accepted after revision 20.2.2024

Bibliography

Geburtsh Frauenheilk 2024; 84: 378–386

DOI 10.1055/a-2273-2672

ISSN 0016-5751

© 2024. The Author(s).

This is an open access article published by Thieme under the terms of the Creative Commons Attribution-NonDerivative-NonCommercial-License, permitting copying and reproduction so long as the original work is given appropriate credit. Contents may not be used for commercial purposes, or adapted, remixed, transformed or built upon. (<https://creativecommons.org/licenses/by-nc-nd/4.0/>).

Georg Thieme Verlag KG, Rüdigerstraße 14,
70469 Stuttgart, Germany

Correspondence

Julia Kummer
Department of Obstetrics and Gynecology
Klinikum im Friedrichshain
Landsberger Allee 49
10249 Berlin, Germany
julia.kummer@vivantes.de

ABSTRACT

Introduction

About one in 500 pregnant women requires a surgical intervention that is not pregnancy-related. One of the most common surgical interventions during pregnancy is appendectomy. The primary aim of this study was to assess surgical access of appendectomy during pregnancy and pregnancy outcome. Secondary outcomes were clinical symptoms and diagnostics as well as histopathological analysis.

Methods and Material

This is a single-center retrospective data analysis conducted at a tertiary perinatal center. A digital search of the hospital record archive was conducted focusing on pregnant women beyond 24 0/7 weeks of pregnancy encoding appendectomy. Descriptive statistical analysis was performed.

Results

Between January 2013 and January 2023, a total of 20 appendectomies were performed during pregnancy with gestational age beyond 24 0/7 weeks of pregnancy. All of them were performed as lower midline laparotomy. The rate of appendix perforation was 3/20 (15.0%). 19/20 patients (95.0%) delivered via cesarean. In 7/20 patients (35.0%) appendectomy was performed during cesarean delivery due to incidental finding of irritated or abnormal vermiform appendix. In the pathological work-up, only 2/7 (28.6%) of these subjects had inflammation.

Conclusion

In this small monocentric cohort, only open appendectomies were performed. Our data indicate that it is safe to perform open appendectomy during pregnancy if necessary. In this small patient group, there was an increase in simultaneous cesarean deliveries.

ZUSAMMENFASSUNG

Einleitung

Eine von 500 schwangeren Frauen benötigt während der Schwangerschaft einen operativen Eingriff, der nicht mit der Schwangerschaft in Zusammenhang steht. Die Appendektomie stellt einen der häufigsten chirurgischen Eingriffe während der Schwangerschaft dar. Hauptziel dieser Studie war es, den Operationszugang sowie das Schwangerschafts-Outcome nach Appendektomie zu beurteilen. Sekundäre Outcomes waren klinische Symptome und Diagnosen sowie die histopathologische Analyse.

Methoden und Material

Es handelt sich hier um eine retrospektive monozentrische Datenanalyse, die an einem Perinatalzentrum Level 1 durchgeführt wurde. Es wurde eine digitale Suche des Krankenhausaktenarchivs nach schwangeren Frauen mit einem Gestationsalter von mehr als 24 0+7 Wochen und einer

Appendektomie-Kodierung durchgeführt. Eine deskriptive statistische Analyse wurde durchgeführt.

Ergebnisse

Zwischen Januar 2013 und Januar 2023 wurden insgesamt 20 Appendektomien bei schwangeren Frauen mit einem Gestationsalter von mehr als 24 + 0 SSW durchgeführt. Alle Eingriffe wurden als Pfannenstielschnitt durchgeführt. Insgesamt hatten 3/20 Frauen (15,0%) einen Blinddarmdurchbruch. 19/20 der Patientinnen (95,0%) wurden per Sectio caesarea entbunden. Bei 7/20 der Patientinnen (35,0%) wurde die Appendektomie aufgrund des Zufallsbefunds eines gereizten bzw. abnormen Wurmfortsatzes während einer Kaiserschnittentbindung durchgeführt. Bei der pathologischen Abklärung fand sich nur bei 2/7 (28,6%) dieser Patientinnen eine Entzündung.

Schlussfolgerung

In dieser kleinen monozentrischen Kohorte wurden nur offene Appendektomien durchgeführt. Unsere Daten zeigen, dass – falls ein Eingriff nötig ist – eine offene Appendektomie relativ gefahrlos während der Schwangerschaft durchgeführt werden kann. Diese kleine Patientinnengruppe hatte einen höheren Anteil gleichzeitiger Kaiserschnittentbindungen.

Introduction

One in 500 pregnant women requires a surgical intervention that is not primarily pregnancy related [1]. Elective surgeries ought to be postponed until after delivery [2]. Nonobstetric surgeries that need to be performed due to urgency include abdominal, dental, skin-related or bone-related surgeries [2]. An appendectomy is among the most frequent intraabdominal surgical procedures per-

formed during pregnancy [3]. In most cases appendectomy during pregnancy is performed in women who exhibit clinical signs of appendicitis. Histopathologically, appendicitis is classified into 4 stages as depicted in ► **Table 1** [4]. In 0.1% of all pregnancies appendicitis is suspected [5]. Acute appendicitis with peritonitis is associated with higher rates of morbidity and mortality for the mother and her offspring [6].

► **Table 1** Histopathological stages of appendicitis. Overview of classification of appendicitis and associated histopathological changes.

Classification		Histopathological changes
Acute appendicitis	Erosive appendicitis	Inflammation limited to the mucosa or submucosa. It is usually not accompanied by macroscopic changes.
	Ulcerative phlegmonous appendicitis	Phlegmonous appendicitis is characterized by neutrophilic infiltration and often circumferential involvement of the muscularis propria. The mucosa is usually inflamed, ulcerated and often accompanied by edema, serositis and microabscesses.
	Gangrenous appendicitis	Necrotic changes occur due to transmural inflammation of the wall layers. As the inflammation progresses, the organ can perforate.
Chronic appendicitis		Chronic appendicitis is characterized by fibrosis and inflammatory infiltrates such as lymphocytes, histiocytes and plasma cells. In addition, periappendicitous adhesions and lipomatous transformations can be detected.

Due to changes in anatomy related to the growing uterus, physiological leukocytosis and nonspecific or altered symptoms throughout gestation, diagnosing acute appendicitis in pregnant women is challenging. Mentioned factors could cause a delay in diagnosis and treatment [3, 7]. Through the visualization of the vermiform appendix, ultrasound technology can aid in the more precise classification of suspected non-obstetrical illnesses affecting the abdomen [8]. Unfortunately, it frequently lacks conclusiveness and is heavily dependent on the operator [1, 9]. Magnetic resonance imaging (MRI) is advised as the preferred imaging modality after an inconclusive ultrasound in order to visualize and evaluate the appearance of the appendix in pregnant women [10, 11].

In some cases chronic or even acute appendicitis do not present clinically but are suspected when looking at the vermiform appendix during elective cesarean delivery. However, visual diagnosis and histopathological analysis might not match.

We conducted a retrospective data analysis from January 2013 to January 2023 on the performance of appendectomy during pregnancy beyond 24 0/7 weeks of gestation. The primary aim of this study was to assess surgical access and pregnancy outcome. Secondary outcomes were clinical symptoms and diagnostics as well as histopathological analysis (► Fig. 1).

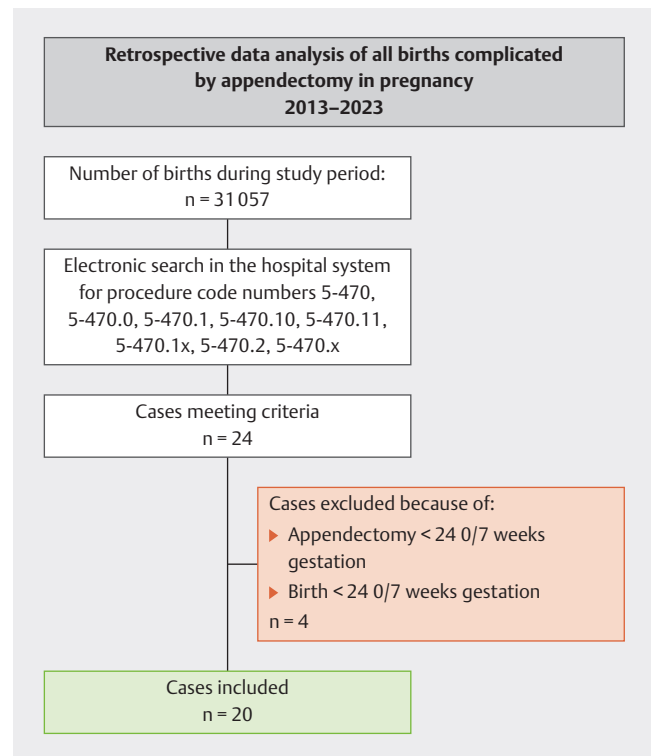
Methods and Material

Study design

This is a single-center retrospective data analysis conducted at a tertiary perinatal center in the metropolitan region of Berlin, Germany. Selection of study population is shown in ► Fig. 1. The study was approved by the local Ethics Committee (Eth-23/23, June 2 nd, 2023) (Clinical Trial Registration: drks.de, DRKS number: DRKS00032003). Due to the retrospective nature of the study, written patient consent was not necessary. This study was performed in accordance with the ethical standards of the institutional and/or national research committee and with the 1964 Helsinki declaration and its later amendments or comparable ethical standards. The analysis period was January 2013 to January 2023. A digital search of the hospital record archive for obstetrical cases encoding for German operation and procedure code numbers 5–470 (appendectomy), 5–470.0 (open appendectomy), 5–470.1 (laparoscopic appendectomy), 5–470.10 (laparoscopic appendectomy via ligature), 5–470.11 (laparoscopic appendectomy via stapler), 5–470.1x (other laparoscopic appendectomy), 5–470.2 (changing from laparoscopic appendectomy to open appendectomy), 5–470.x (other appendectomy) was conducted.

Baseline variables

Baseline characteristics were obtained and recorded anonymously in a data base. Baseline characteristics included maternal age, gestational age, past obstetric history, existence of symptoms of appendicitis (maternal fever, lower right abdominal pain, upper abdominal pain), elevated inflammation parameters including white blood cell count > 10.5/nl and C-reactive protein > 5 mg/l according to hospital laboratory standards, sonographic reference of appendicitis, performance of computer tomography, performance



► Fig. 1 Flowchart describing the study population.

of magnetic resonance imaging, preoperative application of antibiotics and application of antenatal corticosteroid therapy.

Obstetrical management as well as maternal and fetal outcome

Outcome of interest were spontaneous vaginal delivery, operative vaginal delivery, cesarean delivery, 5 minutes APGAR, umbilical cord arterial pH and maternal or fetal admission to Intensive Care Unit (ICU) or Neonatal Intensive Care Unit (NICU).

Surgical outcome

The surgical technique as well as intra- and postoperative complications were recorded.

Histopathological analysis

Appendices underwent routine clinical examination consisting of storage at 4°C prior to fixation, fixation in 4% buffered formalin, measurement, trimmed weight, sectioning, and examination of the cut surface. Sections underwent routine processing, embedding, sectioning at 2 µm and staining with hematoxylin and eosin stain. Histologic examination was performed by authorized pathologists.

Statistical analysis

Descriptive statistical analysis was performed, calculating means and standard deviation for continuous variables and actual values or percentages for categorical variables. Analyses were conducted in SPSS Version 24.

► **Table 2** Baseline variables and obstetrical outcome.

	Appendectomy in pregnancy > 24 0/7 weeks of gestation n = 20
Maternal characteristics	
Nullipara (n)	12 (60.0%)
Smoker (n)	1 (5.0%)
BMI (kg/m ²)	25.8 (± 7.4)
In-hospital stay (d)	7.4 (± 3.4)
Gestational week at time of appendectomy	37 (± 3.8)
Gestational week at time of birth	38 (± 3.3)
Mode of delivery	
Vaginal	1 (5.0%)
Vaginal operative	0
Cesarean delivery	19 (95.0%)
Neonatal outcome	
Weight (Perc.)	50.7 (± 27.2)
APGAR < 7 5 min (n)	1 (5.0%)
Arterial pH umbilical cord < 7.15 (n)	0
Preterm delivery	6 (30.0%)
Admission NICU	5 (25.0%)
Maternal outcome	
Admission ICU	0

Results are shown in absolute numbers and percentages respectively mean and standard deviation when applicable. d = days; ICU = intensive care unit; min = minute; n = number; NICU = neonatal intensive care unit; Perc. = percentile

Results

The clinic recorded 31057 deliveries between January 2013 and January 2023, of which 20 deliveries (0.06%) were complicated by appendectomy during pregnancy with gestational age beyond 24 0/7 weeks of pregnancy.

Baseline variables

Baseline variables are shown in ► **Table 2**. Mean patient age at the time of surgery was 32.1 years (± 6.25 years).

Clinical symptoms and diagnostic methods

13/20 patients (65.0%) presented with clinical symptoms. Mentioned symptoms are shown in ► **Table 3**. In 10/20 cases (50.0%) a conciliar presentation to the surgical attending had occurred prior to surgery. Performance of imaging diagnostics is shown in ► **Table 3**. An ultrasound of the vermiform appendix was performed in 6/20 patients (30.0%). In two cases the sonography was positive and substantiated suspicion of appendicitis which was confirmed in histopathologic work-up. In 66.7% of the cases the performed ultrasound was inconclusive.

► **Table 3** Overview of clinical and paraclinical symptoms of appendicitis in pregnant women.

	Appendectomy in pregnancy > 24 0/7 weeks of gestation n = 20
Symptoms	
Fever	5 (25.0%)
Right abdominal pain	11 (55.0%)
Upper abdominal pain	4 (20.0%)
Defensive tension	6 (30.0%)
Nausea	5 (25.0%)
Vomiting	5 (25.0%)
Diarrhea	1 (5.0%)
Time interval of symptom onset to surgery in h	51.0 (± 39.3)
Laboratory findings	
Leukocytes > 15	11 (55.0%)
C-reactive protein > 5	12 (60.0%)
Imaging	
Performance of ultrasound	6 (30.0%)
Performance of computer tomography	0
Performance of magnetic resonance imaging	1 (5.0%)

Results are presented in absolute numbers and percentages respectively mean and standard deviation when applicable. h = hour; n = number

One patient underwent an MRI due to an unclear clinical presentation that included diffuse abdominal pain, elevated paraclinical inflammation parameters and incohesive ultrasound. The MRI revealed a tubular structure with a retrocecal wall that was up to 8 mm in diameter and basal surrounding adipose tissue, which corresponded to the picture of phlegmonous appendicitis (► **Fig. 2**).

Maternal and fetal outcome

The average week of pregnancy at the time of appendectomy was 37 weeks of gestation (± 3.8 weeks of gestation). The average week of pregnancy at the time of birth was 38 weeks of gestation (± 3.3 weeks of gestation).

Details of obstetrical management as well as maternal and fetal outcome can be found in ► **Table 2**.

There were 6/20 cases (30.0%) of preterm delivery before 37 0/7 weeks of gestation. In four cases the premature delivery took place before 34 0/7 weeks of gestation. Of these women, only two received corticosteroids prior to delivery. Instead of the standard two injections, each patient received a single intramuscular injection of 12 mg of betamethasone. These two preterm deliveries occurred in 33 0/7 weeks of gestation and 30 4/7 weeks of

gestation. Both patients required urgent therapy because they presented in a significantly reduced general condition with an acute abdomen. In both cases a cesarean delivery combined with open appendectomy was performed within two hours after application of the first dose of betamethasone. The other two preterm deliveries occurred in 33 4/7 weeks of gestation and 31 3/7 weeks of gestation. In both cases, patients were in a significantly reduced general condition and presented with an acute abdomen. Both patients required immediate surgical care.

Only one patient delivered spontaneously in 41 6/7 weeks of gestation after appendectomy had been performed at 32 weeks of gestation. In 7/20 cases (35.0%) the appendectomy was performed due to an incidental visual finding of an altered vermiform appendix in an asymptomatic patient during a planned cesarean delivery. Out of the 13/20 cases (65.0%) where appendectomy occurred because the patient was symptomatic, 12/20 cases (60.0%) had a simultaneous cesarean delivery due to fear of fetal impairment.

During the observation period all 20 appendectomies were performed as open appendectomies. A perforated appendicitis was found in three cases (15.0%). There were neither intraoperative complications such as injuries or increased bleeding nor postoperative complications such as wound infections or events of thrombosis or embolisms. No repeat laparotomies were performed within 30 days after surgery.

Histopathological analysis

Histopathology examination was performed in all cases. The histopathological analysis of the 20 appendices revealed information as follows. ► **Table 4** gives an overview.

Three appendectomy specimens showed catarrhal stage of appendicitis being described as catarrhal appendicitis with cicatricial obliteration and fatty degeneration in the apex.

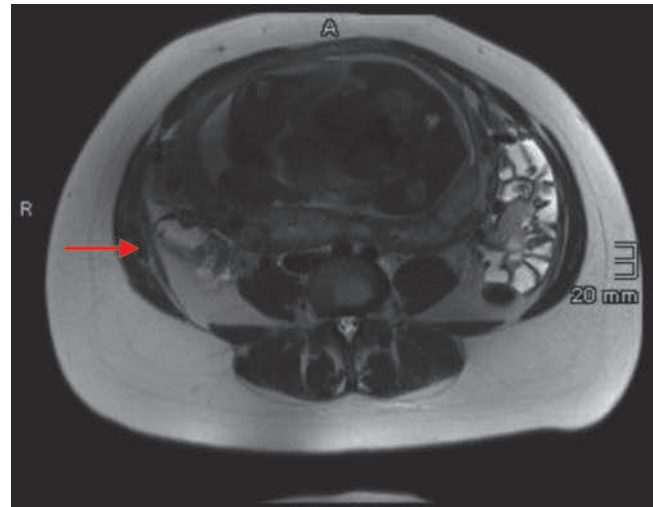
In four cases pathological analysis showed appendicitis with ulcerated mucosa, streaked lympho-follicular architecture, transmural granulocytes and focal wall necrosis corresponding to an ulcero-phlegmonous appendicitis (► **Fig. 3 a, b**).

In one case in addition to diagnosing phlegmonous appendicitis, serosal decidual tissue parts were noted compatible with endometriosis.

Gangrenous appendicitis was diagnosed in four cases showing appendix with a dense transmural infiltrate of neutrophilic granulocytes with a completely necrotic wall of the appendix.

Pathological work-up showed chronic inflammation in four cases described as chronic recurrent cicatricial appendicitis with luminal obliteration, adipose tissue degeneration and localized minimal fibrous serositis.

In five cases histopathological examinations showed no significant inflammation or other abnormalities.



► **Fig. 2** T2 weighted MR image of the mid abdominal axial plane displaying the fetus in the middle of the image and the inflamed appendix (arrow).

► **Table 4** Overview of histopathological findings.

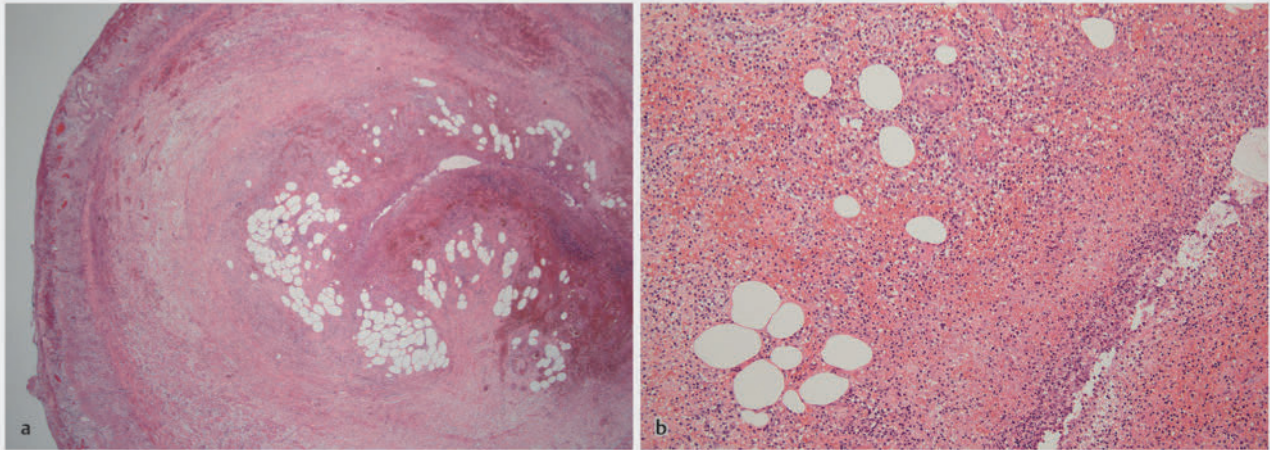
	Appendectomy in pregnancy > 24 0/7 weeks of gestation n = 20
Histopathology examination	
Acute appendicitis	11 (55.0%)
Chronic appendicitis	4 (20.0%)
Tumor	0
Other	1 (5.0%)
WPF	5 (25.0%)

Results are shown in absolute numbers and percentages
n = number; WPF = without pathological findings

Discussion

Principal findings

Pregnancy rarely necessitates the need for appendectomies, according to this retrospective analysis. Only open appendectomies were done on this small patient group. According to our research, if an open appendectomy is required during pregnancy, it can be safely done. From our data we were able to show low risk for adverse maternal as well as fetal outcome and intraoperative and postoperative surgical complications for pregnancies complicated by appendectomy. At the same time, cesarean deliveries increased in this small patient cohort. In our cohort all of the symptomatic patients had histopathological evidence of appendicitis.



► **Fig. 3** a Histological specimen of appendix vermiformis, H.E. stain, 20 × magnification: Purulent exudate in the lumen, ulceration of the mucous membrane, phlegmonous inflammatory infiltrates in all wall layers. b Histological specimen of appendix vermiformis, H.E. stain, 100 × magnification: granulocytic inflammatory infiltrate.

Comparison with other studies

During pregnancy, appendicitis occurs more often during the second than during the first and third trimester of pregnancy. It is therefore associated with increased fetal morbidity [2]. However, in this patient collective appendicitis occurred during the third trimester in all cases. Partially this can be explained by the study protocol which required patients to have reached 24 0/7 weeks of gestations to be included in this study.

Fetal death rate has been described as 1.8% in women with appendicitis during pregnancy [12]. Appendicitis complicated by peritonitis increases the fetal death rate of up to 10.9% [6]. In our study cohort no fetal death was noted.

If surgical intervention becomes necessary during pregnancy, appendectomy has been described to be related to surgery-induced labor [6]. The rate of surgery-induced labor is around 4.6% which is 1.3 times higher than in other non-obstetric related surgical interventions [6]. Only one case was recorded in which an appendectomy took place without parallel delivery, which is consistent with the data mentioned above.

Appendix perforation rate was low and comparable to other studies [13]. However, this has to be seen in contrast to the high rate of surgical removal of unaffected appendices. 7/20 patients (35.0%) did not show any symptoms of appendicitis. In all of these cases appendectomy was performed during cesarean delivery due to visual impression. In 5/20 cases (25.0%) histological analysis revealed no significant inflammation of the vermiform appendix. Negative appendectomy rate is higher in pregnant women than in non-pregnant women [14]. It has been described as 23–36% before [13, 14]. It is associated with risk of fetal loss [14]. This is comparable to the data of this study. So far, there is no universally accepted guideline on whether or not to look for the vermiform appendix during cesarean delivery.

A Swedish registry study of 1991 indicated that in 64% of the cases of appendectomy during pregnancy an acute appendicitis

was proven histopathologically [12]. This is comparable to the data of this study.

In one case histological work-up showed a phlegmonous appendicitis as well as serosal decidual tissue parts compatible with endometriosis. Deep infiltrating endometriosis is the most severe form and can affect the intestines in up to 25% of cases [15]. Only very rarely does endometriosis manifest itself in the vermiform appendix [16].

Clinical and research implications

Irrespective of gestational age, pain in the lower right quadrant of the abdomen is the most common sign of appendicitis in pregnant women which could also be shown in this study [5].

When assessing pregnant women experiencing pain in the lower right abdomen, we recommend using an accurate and safe imaging method in addition to clinical and laboratory testing [7].

The usage of imaging methods lowers the negative appendectomy rate in young women [17]. Sensitivity and specificity of ultrasound in diagnosing appendicitis is estimated to be 77% and 86% [18]. Sensitivity and specificity can be increased to 100% and 86% by additional usage of computer tomography [18]. However, risks of ionizing radiation associated with this imaging method limit the usability in pregnant women [7, 19]. Risks associated with fetal exposure to ionizing radiation depend on the gestational age as well as the dose of radiation [20]. Fetuses are more susceptible to the dose-dependent teratogenic effects of ionizing radiation like malformations, mental retardation or growth restrictions [20]. No profound data exist on the risk of carcinogenesis after in utero exposure to ionizing radiation [19]. There seems to be a 1.5-fold increase in childhood leukemia dose-dependent after in utero radiation exposure [19, 21].

Radiation exposure can be avoided by the usage of magnetic resonance imaging compared to computer tomography [22, 23]. MRI performance can improve specificity and sensitivity of diag-

► **Table 5** Overview of recent systematic reviews on the topic of surgical access for appendectomy during pregnancy.

Characteristics	Systematic review		
	Chakraborty 2019 [28]	Lee 2019 [3]	Frontzas 2019 [29]
Study aim	Safety of laparoscopic surgery in pregnancy	Safety of laparoscopic appendectomy versus open appendectomy for suspected appendicitis during pregnancy	Compare the surgical and obstetrical outcomes between laparoscopic and open appendectomy during pregnancy
Databases that were searched	Medline and Embase	PubMed, Embase and Cochrane Library	Medline, SCOPUS, Clinicaltrials.gov, CENTRAL and Google Scholar
Search time range	2000–2017	NM	1996–2016
Number of studies included	16 retrospective non-randomized studies, 1 prospective observational study	19 comparative retrospective reviews of patients' medical records, 3 comparative prospective cohort studies	20 retrospective non-randomized studies, 1 prospective observational study
Number of women included	LA group: 1886 patients OA group: 4261 patients	LA: 905 patients OA: 3789 patients	LA: 1963 patients OA: 4313 patients
Gestational week at appendectomy	LA 37.1–39.3 weeks OA 36.7–39 weeks	NM	NM
Fetal loss	LA: pooled OR: 1.84 (95% CI: 1.31–2.58, $p < 0.001$)	LA: OR 1.16 (95% CI: 0.68–1.99; $p = 0.581$)	LA: OR: 2.11 (95% CI: 1.44–3.09, $p = 0.0001$)
Preterm delivery	LA: pooled OR: 0.39 (95% CI 0.27–0.55, $p < 0.001$)	LA: OR 0.76 (95% CI: 0.51–1.15)	LA: OR: 0.72 (95% CI 0.40–1.29, $p = 0.27$)
Wound infection		Wound infection (OR 0.40, 95% CI: 0.21–0.76)	Wound infection (OR 0.47, 95% CI 0.15–1.48, $p = 0.20$)

CI = confidence interval; LA = laparoscopic appendectomy; NM = not mentioned; OA = open appendectomy; OR = odds ratio; p = p -value

nosing appendicitis in pregnancy up to 100.0% and 98.3%, respectively, for patients with inconclusive ultrasound diagnostics [24].

To choose the optimal imaging technique, close collaboration with the supervising radiologist should be sought after [25].

In this patient collective in all cases open appendectomy was performed when a pathology of the vermiform appendix was suspected.

There are two ways of surgical access to perform appendectomy: conventional appendectomy via lower midline transverse abdominal incision and laparoscopic appendectomy [3, 26]. In their systematic review Adamani et al. recommend laparoscopic approach until the 20th week of gestation or when the fundus uteri is below the level of the umbilicus [27]. In cases of suspected appendicitis in pregnant women beyond 20 weeks of gestation or in pregnant women with the fundus uteri being located above the level of the umbilicus surgical access should depend on the expertise and preference of the surgeon [27]. Due to the later pregnancy dates of the appendectomies performed on this patient group, the technical challenges of performing laparoscopic surgery were considered significant by the performing surgeons. After ruling out all differential diagnosis at any stage of pregnancy, appendectomy should be performed when appendicitis is suspected [26]. If the appendix is not perforated, no simultaneous cesarean delivery is indicated [26]. There is currently a lack of clarity regarding the effects of laparoscopic surgery versus open appendectomy on preterm delivery and fetal loss [3, 28, 29]. An

overview of recent systematic reviews on surgical access for appendectomy during pregnancy is provided in ► **Table 5**.

The sole use of antibiotics in treating appendicitis has not been analyzed methodically in pregnant women so far [1]. In this study in five cases antibiotic treatment was initiated before surgery. However, no patient received antibiotic therapy exclusively. Surgery was performed in all cases. Further studies are needed to evaluate conservative treatment for appendicitis in pregnancy.

Strengths

The findings of this study can be used to design prospective studies in the field of imaging diagnostics as well as treatment of pregnant women with suspected appendicitis or tumors of the vermiform appendix.

In addition, the study might suggest that all surgeries unrelated to pregnancy be registered in a registry in order to monitor the frequency, results, and complications among perinatal facilities.

Limitations

The study's primary constraint is the small number of cases, which, however, can be classified as large for a single perinatal center. For this reason, further statistical analyses had to be omitted. Şahin et al. analyzed 11 513 deliveries during 2015–2020 complicated by appendectomy during pregnancy. In their cohort they found 12 cases [30]. This number of cases is comparable to our data. An acute appendicitis rate of 6.3 and 9.9 per 10 000 per-

son-years, respectively, was determined for the antepartum and postpartum periods by Zingone et al. also supporting our case number [31].

In this small patient collective only open appendectomies were performed followed by cesarean deliveries in almost all cases. In contrast to the procedures presented in this case series, this study is intended to serve as a suggestion to reconsider laparoscopic appendectomy even in more advanced weeks of pregnancy and to optimize surgical skills accordingly. A careful assessment of the necessity of a simultaneous cesarean delivery should be made. Due to the retrospective character of the study findings of this study are limited.

Conclusion

This retrospective study showed that appendectomies rarely need to be performed during pregnancy. In the event of appendicitis being suspected during pregnancy, we advise pursuing additional diagnostic tests, such as ultrasound and MRI if needed, in addition to a serological work-up and consulting with general surgery and neonatology. In this small patient collective only open appendectomies were performed. Our data indicate that it is safe to perform an open appendectomy during pregnancy if necessary. In this small patient group, there was an increase in simultaneous cesarean deliveries.

Clinical Trial

Registration number (trial ID): DRKS00032003 | German Clinical Trials Register (<https://drks-neu.uniklinik-freiburg.de/>) | Type of Study: single-center retrospective data analysis

Contributors' Statement

Dr. med. Kummer, Julia – study design, data collection, statistical analysis, writing.
Dr. med. Koenigbauer, Josefine – data collection, writing.
Peters, Falko Stephan Joachim – data collection.
PD Dr. med. Rickert, Christian – histopathological analysis.
Prof. Dr. med. Hellmeyer, Lars – senior consultant.

Conflict of Interest

The authors declare that they have no conflict of interest.

References

- [1] Pearl JP, Price RR, Tonkin AE et al. SAGES guidelines for the use of laparoscopy during pregnancy. *Surg Endosc* 2017; 31: 3767–3782. doi:10.1007/s00464-017-5637-3
- [2] Norwitz ER, Park JS. Nonobstetric surgery in pregnant patients: Patient counseling, surgical considerations, and obstetric management. *Topic 121990 Version 8.0*. Waltham: Up-to-Date; 2023

- [3] Lee SH, Lee JY, Choi YY et al. Laparoscopic appendectomy versus open appendectomy for suspected appendicitis during pregnancy: a systematic review and updated meta-analysis. *BMC Surg* 2019; 19: 41. doi:10.1186/s12893-019-0505-9
- [4] Carr NJ. The pathology of acute appendicitis. *Ann Diagn Pathol* 2000; 4: 46–58. doi:10.1016/s1092-9134(00)90011-x
- [5] Mourad J, Elliott JP, Erickson L et al. Appendicitis in pregnancy: new information that contradicts long-held clinical beliefs. *Am J Obstet Gynecol* 2000; 182: 1027–1029. doi:10.1067/mob.2000.105396
- [6] Cohen-Kerem R, Railton C, Oren D et al. Pregnancy outcome following non-obstetric surgical intervention. *Am J Surg* 2005; 190: 467–473. doi:10.1016/j.amjsurg.2005.03.033
- [7] Long SS, Long C, Lai H et al. Imaging strategies for right lower quadrant pain in pregnancy. *AJR Am J Roentgenol* 2011; 196: 4–12. doi:10.2214/a jr.10.4323
- [8] Katz DS, Klein MA, Ganson G et al. Imaging of abdominal pain in pregnancy. *Radiol Clin North Am* 2012; 50: 149–171. doi:10.1016/j.rcl.2011.08.001
- [9] Wonski S, Ranzenberger LR, Carter KR. *Appendix Imaging*. 2023 Apr 17. StatPearls [Internet]. Treasure Island (FL): StatPearls Publishing; 2023
- [10] Kave M, Parooie F, Salarzaei M. Pregnancy and appendicitis: a systematic review and meta-analysis on the clinical use of MRI in diagnosis of appendicitis in pregnant women. *World J Emerg Surg* 2019; 14: 37. doi:10.1186/s13017-019-0254-1
- [11] Oto A, Ernst RD, Ghulmiyyah LM et al. MR imaging in the triage of pregnant patients with acute abdominal and pelvic pain. *Abdom Imaging* 2009; 34: 243–250. doi:10.1007/s00261-008-9381-y
- [12] Mazze RI, Källén B. Appendectomy during pregnancy: a Swedish registry study of 778 cases. *Obstet Gynecol* 1991; 77: 835–840
- [13] Lindqvist PG, Pettersson H, Dahlberg M et al. Appendectomy during pregnancy: rates, safety, and outcomes over a five-year period. A hospital-based follow-up study. *J Matern Fetal Neonatal Med* 2023; 36: 2160629. doi:10.1080/14767058.2022.2160629
- [14] McGory ML, Zingmond DS, Tillou A et al. Negative appendectomy in pregnant women is associated with a substantial risk of fetal loss. *J Am Coll Surg* 2007; 205: 534–540. doi:10.1016/j.jamcollsurg.2007.05.025
- [15] Abrão MS, Petraglia F, Falcone T et al. Deep endometriosis infiltrating the recto-sigmoid: critical factors to consider before management. *Hum Reprod Update* 2015; 21: 329–339. doi:10.1093/humupd/dmv003
- [16] Gustofson RL, Kim N, Liu S et al. Endometriosis and the appendix: a case series and comprehensive review of the literature. *Fertil Steril* 2006; 86: 298–303. doi:10.1016/j.fertnstert.2005.12.076
- [17] Coursey CA, Nelson RC, Patel MB et al. Making the diagnosis of acute appendicitis: do more preoperative CT scans mean fewer negative appendectomies? A 10-year study. *Radiology* 2010; 254: 460–468. doi:10.1148/radiol.09082298
- [18] Poortman P, Oostvogel HJ, Bosma E et al. Improving diagnosis of acute appendicitis: results of a diagnostic pathway with standard use of ultrasonography followed by selective use of CT. *J Am Coll Surg* 2009; 208: 434–441. doi:10.1016/j.jamcollsurg.2008.12.003
- [19] Anonymous. Committee Opinion No. 723: Guidelines for Diagnostic Imaging During Pregnancy and Lactation. *Obstet Gynecol* 2017; 130: e210–e216. doi:10.1097/AOG.0000000000002355
- [20] American College of Radiology (ACR). ACR–SPR practice parameter for imaging pregnant or potentially pregnant patients with ionizing radiation. 2023. Accessed February 07, 2023 at: <http://www.acr.org/-/media/acr/files/practice-parameters/pregnant-pts.pdf>
- [21] Stewart A, Kneale GW. Radiation dose effects in relation to obstetric x-rays and childhood cancers. *Lancet* 1970; 1: 1185–1188. doi:10.1016/s0140-6736(70)91782-4

- [22] Pedrosa I, Laforanara M, Pandharipande PV et al. Pregnant patients suspected of having acute appendicitis: effect of MR imaging on negative laparotomy rate and appendiceal perforation rate. *Radiology* 2009; 250: 749–757. doi:10.1148/radiol.2503081078
- [23] Baron KT, Arleo EK, Robinson C et al. Comparing the diagnostic performance of MRI versus CT in the evaluation of acute nontraumatic abdominal pain during pregnancy. *Emerg Radiol* 2012; 19: 519–525. doi:10.1007/s10140-012-1066-8
- [24] Ramalingam V, LeBedis C, Kelly JR et al. Evaluation of a sequential multimodality imaging algorithm for the diagnosis of acute appendicitis in the pregnant female. *Emerg Radiol* 2015; 22: 125–132. doi:10.1007/s10140-014-1260-y
- [25] Chen MM, Coakley FV, Kaimal A et al. Guidelines for computed tomography and magnetic resonance imaging use during pregnancy and lactation. *Obstet Gynecol* 2008; 112: 333–340. doi:10.1097/AOG.0b013e318180a505
- [26] Fischer T, Grab D, Grubert T, Hantschmann P, Kainer F, Kästner R, Kantenich C, Klockenbusch W, Lammert F, Louwen F, Mylonas I, Pildner von Steinburg S, Rath W, Schäfer-Graf UM, Schleußner E, Schmitz R, Steitz HO, Verlohren S. 17 – Maternale Erkrankungen in der Schwangerschaft. Kainer F (ed.). *Facharztwissen Geburtsgynäkologie*. München: Urban & Fischer; 2016: 347–618
- [27] Adamina M, Andreou A, Arezzo A et al. EAES rapid guideline: systematic review, meta-analysis, GRADE assessment, and evidence-informed European recommendations on appendicitis in pregnancy. *Surg Endosc* 2022; 36: 8699–8712. doi:10.1007/s00464-022-09625-9
- [28] Chakraborty J, Kong JC, Su WK et al. Safety of laparoscopic appendectomy during pregnancy: a systematic review and meta-analysis. *ANZ J Surg* 2019; 89: 1373–1378. doi:10.1111/ans.14963
- [29] Frountzas M, Nikolaou C, Stergios K et al. Is the laparoscopic approach a safe choice for the management of acute appendicitis in pregnant women? A meta-analysis of observational studies. *Ann R Coll Surg Engl* 2019; 101: 235–248. doi:10.1308/rcsann.2019.0011
- [30] Şahin B, Tinelli A, Augustin G. Are Cesarean Section and Appendectomy in Pregnancy and Puerperium Interrelated? A Cohort Study. *Front Surg* 2022; 9: 819418. doi:10.3389/fsurg.2022.819418
- [31] Zingone F, Sultan AA, Humes DJ et al. Risk of acute appendicitis in and around pregnancy: a population-based cohort study from England. *Ann Surg* 2015; 261: 332–337. doi:10.1097/SLA.0000000000000780