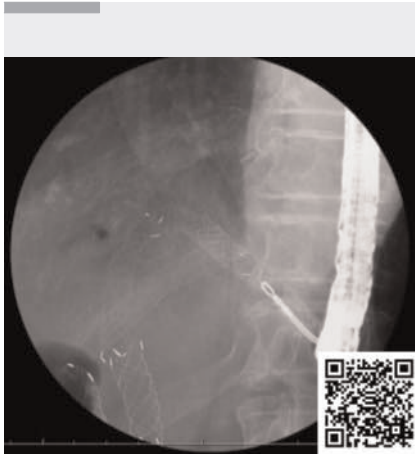

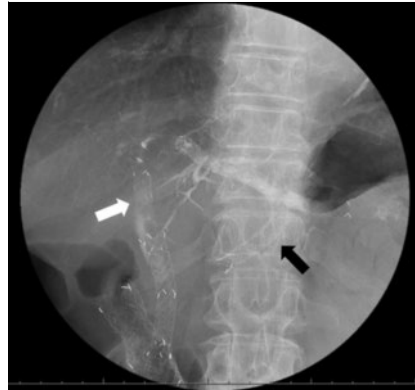## Salvage technique for covered metal stent migration during endoscopic reintervention after endoscopic ultrasound-guided hepaticogastrostomy



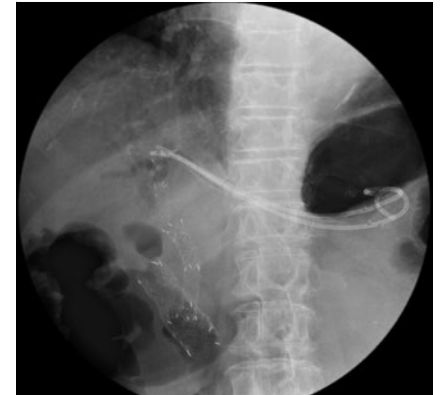**▶ Video 1** Endoscopic removal of a migrated self-expandable metal stent (SEMS) and antegrade SEMS using grasping forceps via the hepaticogastrostomy route.

Endoscopic ultrasound (EUS)-guided hepaticogastrostomy (EUS-HGS) is an alternative drainage method for malignant biliary obstruction (MBO) when endoscopic retrograde cholangiopancreatography (ERCP) has failed [1]. A partially covered self-expandable metal stent (PCSEMS) is often used for EUS-HGS, but it cannot be removed. A new metal or plastic stent is therefore placed as endoscopic reintervention following EUS-HGS [2–4]; however, troubleshooting after endoscopic reintervention remains problematic because of a paucity of reported cases.

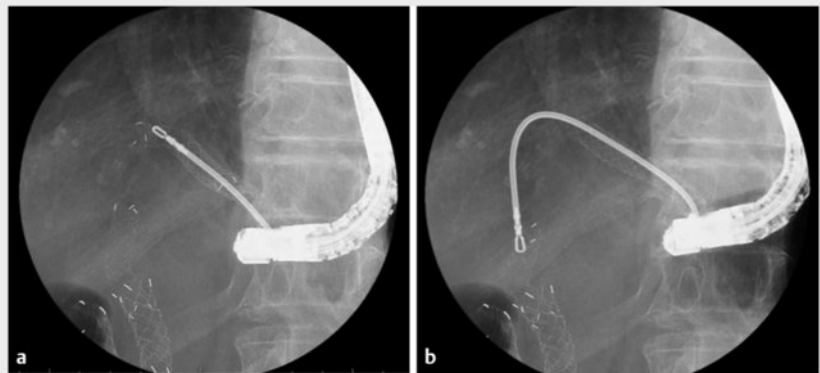
An 81-year-old woman who had previously undergone ERCP for MBO due to pancreatic cancer presented with recurrent biliary obstruction and duodenal stricture. An EUS-HGS using a PCSEMS (EGIS biliary stent, double-covered, 8 mm × 12 cm; S&G Biotech Inc., Yongin, South Korea) and duodenal stent placement were successfully performed. After 5 months, the patient underwent endoscopic reintervention for recurrent bili-



**▶ Fig. 1** Fluoroscopic image showing endoscopic reintervention for recurrent biliary obstruction. Because the partially covered self-expandable metal stent (PCSEMS) inserted for endoscopic ultrasound-guided hepaticogastrostomy (EUS-HGS) was not removed, an additional SEMS (black arrow) was deployed through the stent mesh of the EUS-HGS PCSEMS, with an additional antegrade stent placed across the malignant biliary obstruction (white arrow).



**▶ Fig. 2** During a second endoscopic reintervention for self-expandable metal stent occlusion, new plastic stents were placed through the distal end of the endoscopic ultrasound-guided hepaticogastrostomy (EUS-HGS) self-expandable metal stent (SEMS), after the stent mesh had been broken by argon plasma coagulation, because of the difficulty removing the EUS-HGS SEMS.



**▶ Fig. 3** Fluoroscopic images showing: **a** the migrated self-expandable metal stent (SEMS) in the left intrahepatic bile duct being grasped with grasping forceps and removed via the hepaticogastrostomy; **b** the antegrade SEMS in the common bile duct being grasped with grasping forceps and gradually removed via the hepaticogastrostomy.

ary obstruction. An additional fully covered SEMS (FCSEMS; HANAROSTENT benefit, 8 mm × 8 cm; Boston Scientific Co., Tokyo, Japan) was deployed through

the stent mesh of the EUS-HGS PCSEMS because of the difficulty removing the PCSEMS, along with placement of an antegrade stent across the MBO

(► **Fig. 1**). A second endoscopic reintervention was required for SEMs occlusion, during which new plastic stents (Through & Pass Type-IT; Gadelius Medical, Tokyo, Japan) were placed through the distal end of the EUS-HGS SEMs after the stent mesh had been broken using argon plasma coagulation (► **Fig. 2**).

After 2 months, the patient developed acute cholangitis due to migration of the EUS-HGS SEMs placed during the first endoscopic reintervention and cholecystitis due to the antegrade SEMs. After the plastic stents had been removed, grasping forceps (Rat Tooth; Olympus, Tokyo, Japan) were inserted via the EUS-HGS SEMs. The migrated SEMs was grabbed (► **Fig. 3 a**) and removed. Additionally, the antegrade SEMs was firmly grasped and gradually removed via the EUS-HGS route (► **Fig. 3 b**; ► **Video 1**). The successful removal of the two SEMs was followed by the insertion of new plastic stents and the patient's cholangitis and cholecystitis subsequently improved. This technique demonstrates successful troubleshooting of endoscopic reintervention after EUS-HGS.

Endoscopy\_UCTN\_Code\_TTT\_1AS\_2AD

### Conflict of Interest

The authors declare that they have no conflict of interest.

### The authors

**Yuki Ikeda<sup>1</sup>, Daichi Watanabe<sup>1</sup>, Ginji Oomori<sup>1</sup>, Shota Yamada<sup>1</sup>, Toshinori Okuda<sup>1</sup>, Shinya Minami<sup>1</sup>**

<sup>1</sup> Department of Gastroenterology, Medical Corporation Oji General Hospital, Tomakomai, Japan

### Corresponding author

**Yuki Ikeda, MD**

Department of Gastroenterology, Oji General Hospital, 3-4-8, Wakakusachou, Tomakomai, Hokkaido, 053-8506, Japan  
yu\_ikeda86@yahoo.co.jp

### References

- [1] Moole H, Bechtold ML, Forcione D et al. A meta-analysis and systematic review: Success of endoscopic ultrasound guided biliary stenting in patients with inoperable malignant biliary strictures and a failed ERCP. *Medicine (Baltimore)* 2017; 96: e5154
- [2] Minaga K, Kitano M, Uenoyama Y et al. Feasibility and efficacy of endoscopic reintervention after covered metal stent placement for EUS-guided hepaticogastrostomy: A multicenter experience. *Endosc Ultrasound* 2022; 11: 478–486. doi:10.4103/EUS-D-22-00029
- [3] Yane K, Katanuma A, Maguchi H et al. Successful reintervention with metal stent trimming using argon plasma coagulation after endoscopic ultrasound-guided hepaticogastrostomy. *Endoscopy* 2014; 46: E391–E392
- [4] Takenaka M, Minaga K, Yoshikawa T et al. Novel concept using a plastic stent for endoscopic ultrasound-guided hepaticogastrostomy adjusting the length according to the patient's anatomy. *Endoscopy* 2019; 51: E362–E363. doi:10.1055/a-0948-3630

### Bibliography

*Endoscopy* 2024; 56: E51–E52

DOI 10.1055/a-2228-4400

ISSN 0013-726X

© 2024. The Author(s).

This is an open access article published by Thieme under the terms of the Creative Commons Attribution License, permitting unrestricted use, distribution, and reproduction so long as the original work is properly cited.

(<https://creativecommons.org/licenses/by/4.0/>)

Georg Thieme Verlag KG, Rüdigerstraße 14, 70469 Stuttgart, Germany



### ENDOSCOPY E-VIDEOS

<https://eref.thieme.de/e-videos>



*E-Videos* is an open access online section of the journal *Endoscopy*, reporting on interesting cases

and new techniques in gastroenterological endoscopy. All papers include a high-quality video and are published with a Creative Commons CC-BY license. *Endoscopy E-Videos* qualify for HINARI discounts and waivers and eligibility is automatically checked during the submission process. We grant 100% waivers to articles whose corresponding authors are based in Group A countries and 50% waivers to those who are based in Group B countries as classified by Research4Life (see: <https://www.research4life.org/access/eligibility/>).

This section has its own submission website at

<https://mc.manuscriptcentral.com/e-videos>