

Thyroid Inflammation and Immunity During the COVID-19 Pandemic: A Comprehensive Review and Case Study

Authors

Eleni Lampropoulou¹ , Claus Benz², George J. Kahaly³, Dagmar Führer¹

Affiliations

- 1 Department of Endocrinology, Diabetes and Metabolism, University Hospital Essen, Essen, Germany
- 2 Department of Gastroenterology, Ev. Klinikum Koeln-Weyertal, Koeln, Germany
- 3 Dept. of Medicine I, Gutenberg University Hospital, Mainz, Germany

Key words

COVID-19, SARS-CoV-2 vaccination, subacute thyroiditis, Graves' disease, thyrotropin receptor autoantibodies

received 23.05.2023

accepted after revision 04.12.2023

accepted manuscript online 05.12.2023

Bibliography

Horm Metab Res 2024; 56: 111–117

DOI 10.1055/a-2222-6300

ISSN 0018-5043

© 2024, Thieme. All rights reserved.

Georg Thieme Verlag, Rüdigerstraße 14,
70469 Stuttgart, Germany

Correspondence

Dr. Eleni Lampropoulou
University Hospital Essen
Department of Endocrinology, Diabetes and Metabolism
Hufelandstrasse 55
45147 Essen
Germany
Tel.: 004920172383281
eleni.lampropoulou@uk-essen.de

ABSTRACT

The coronavirus disease 2019 (COVID-19) pandemic caused by severe acute respiratory syndrome coronavirus 2 (SARS-CoV-2) has led to the development of various vaccines. Reports have emerged suggesting a possible association between SARS-CoV-2 vaccination and the onset of thyroid diseases. This review explores the clinical aspects of thyroid disorders following SARS-CoV-2 vaccination, including a case report of a patient with concomitant subacute thyroiditis (SAT) and Graves' disease (GD) with blocking thyrotropin receptor autoantibodies (TSH-R-Ab) following SARS-CoV-2 vaccination. SAT, characterized by transient inflammation of the thyroid gland, has been reported after SARS-CoV-2 vaccination. GD, an autoimmune hyperthyroidism, has also been observed post-vaccination, often with stimulating TSH-R-Ab. Graves' orbitopathy (GO) has been associated with SARS-CoV-2 vaccination in patients with a history of immune thyroid disease. The unique case underscores a very rare thyroid condition of functional hypothyroidism in possible relation to SARS-CoV-2 vaccination and the usefulness of functional analysis of TSH-R-Ab that can provide valuable insights into disease pathogenesis and help to guide treatment. This review highlights the need for continued monitoring and awareness of potential thyroid-related complications following SARS-CoV-2 vaccination.

Introduction

Coronavirus disease 2019 (COVID-19) caused by the severe acute respiratory syndrome coronavirus 2 (SARS-CoV-2), first appeared in December 2019, has spread around the world with persisting impact on various health issues [1] and several vaccines were developed in a hitherto unprecedented successful effort to fight the pandemic [2]. Since 2021, a possible association between SARS-CoV-2 infection, vaccination and new onset of thyroid diseases has been

suggested through individual case reports and small patient series. Thereby the spectrum of reported SARS-CoV-2 associated thyroid disorders ranges from inflammatory subacute thyroiditis (SAT) to immune hyperthyroidism in form of Graves' disease (GD) with and without orbitopathy (GO) [3, 4]. In this review, we discuss clinical aspects of thyroid disorders in the context of SARS-CoV-2 vaccination including a case report on patient with concomitant SAT and GD with transient thyrotoxicosis followed by rapidly evolving per-

sistent hypothyroidism due to blocking thyrotropin receptor autoantibodies (TSH-R-Ab).

Occurrence of SAT after SARS-CoV-2-Vaccination

SAT is a condition characterized by transient inflammation of the thyroid gland, often following a viral infection [5]. Manifestation of SAT after SARS-CoV-2 vaccination has been reported in several papers since 2021 [3, 6–8] and typically presents with neck pain, malaise and transient thyrotoxicosis. In a systematic review, 51 patients with new-onset SAT after SARS-CoV-2 vaccination were included. The majority were women (74.5%), with a median age of 39.5 years [3]. SAT occurred after a median of 10 days following vaccination [3]. Thyrotoxicosis was observed in 88.2% of patients initially, but this decreased to 31.6% during follow-up over 4–8 weeks [3]. Corticosteroids were administered to tamper SAT symptoms in more than half of the documented treated patients [3]. Another study reported 11 cases of SAT after SARS-CoV-2 vaccination [6]. The average time to symptom onset after vaccination was 22 days. SAT occurred after both messenger RNA (mRNA) and inactivated virus vaccines [6]. Remission of SAT was reported in the majority of cases with subsequent hypo- or euthyroidism occurring within a median of 11.5 weeks [7].

Autoimmune thyroid disease after SARS-CoV-2-Vaccination

GD in relation to SARS-CoV-2 vaccination has been reported in the literature, mostly in small case series and manifesting with thyrotoxicosis due to stimulating TSH-R-Ab [9–11].

In recent studies on Graves' disease (GD) following SARS-CoV-2 vaccination, a systematic review identified a total of 60 diagnoses, comprising 48 new diagnoses of GD and 12 GD recurrences [12] highlighting the substantial number of cases. Twelve patients from a single tertiary institution in Singapore developed hyperthyroidism, either as new-onset or relapse of previously well-controlled GD, after receiving the first SARS-CoV-2 mRNA vaccination. The median time to onset of thyrotoxicosis was 17 days, ranging from 5 to 63 days post-vaccination. The majority (11/12) of patients were female with a median age of 35.5 years [9]. Interestingly, most patients were able to receive the second dose of the vaccine without experiencing further exacerbations. The same study identified 21 additional cases of Graves' disease following SARS-CoV-2 vaccination. Among these cases, 16 individuals experienced new-onset hyperthyroidism, 3 had worsening of pre-existing Graves' hyperthyroidism, 1 patient converted from hyperthyroidism to hypothyroidism after vaccination, and another individual was diagnosed with newly acquired Graves' disease along with concurrent subacute thyroiditis [9].

Another study, focusing on early-onset GD within 4 weeks of COVID-19 vaccination, revealed distinctive features in this patient group, such as an older age at onset, a higher prevalence of males, and an initially favorable response to treatment [13].

Another case series from Turkey reported the clinical course of seven adult GD patients, including relapsed and newly diagnosed cases following SARS-CoV-2 vaccination. The median time from vaccination to symptom onset was 7 days. Previous autoimmune thyroid disease (AITD) was documented in 4 of these patients [11].

Graves orbitopathy, the most frequent extrathyroidal manifestation of GD [14] has also been observed in association with SARS-CoV-2 vaccination [15]. Recently a French group reported on six patients (mean age of 53 years) with GO following vaccination [16]. All of these had a previous history of immune thyroid disease. GO manifested as new-onset in 2 patients and recurrence in 4 patients with an average time of 23.8 days from vaccination to onset of eye symptoms. Thyrotoxicosis was confirmed in one patient, while the others were on thyroxine substitution. Four patients had elevated TSH-R-Ab levels. Treatment varied based on the severity and activity of GO, including selenium, intravenous glucocorticoids, teprotumumab, tocilizumab, and orbital decompression, resulting in significant improvement in GO signs and symptoms [16].

In another report of 2 GO cases [17], one patient had a pre-existing history of GD with GO, while the other had a known history of autoimmune thyroiditis (AIT) without GO [17]. Lastly, two cases of GO were reported; both patients had a history of Graves' disease, and the worsening of the GO occurred two weeks after receiving the SARS-CoV-2 vaccination [18].

Furthermore, a notable case report presented a patient who developed both GD and autoimmune diabetes mellitus following SARS-CoV-2 vaccination, considering various mechanisms that might lead to these autoimmune disorders [19].

Concomitant onset of SAT and GD with blocking TSHR-antibodies

Within the literature of thyroid dysfunction following SARS-CoV-2 vaccination, reported cases have highlighted occurrence of SAT and GD with stimulating TSH-R-Ab [3, 4, 9]. However, a recent case of a German patient who developed both SAT and GD concurrently, with persisting hypothyroidism and blocking TSH-R-Ab, illustrates that the spectrum of immune thyroid disorders may be more complex.

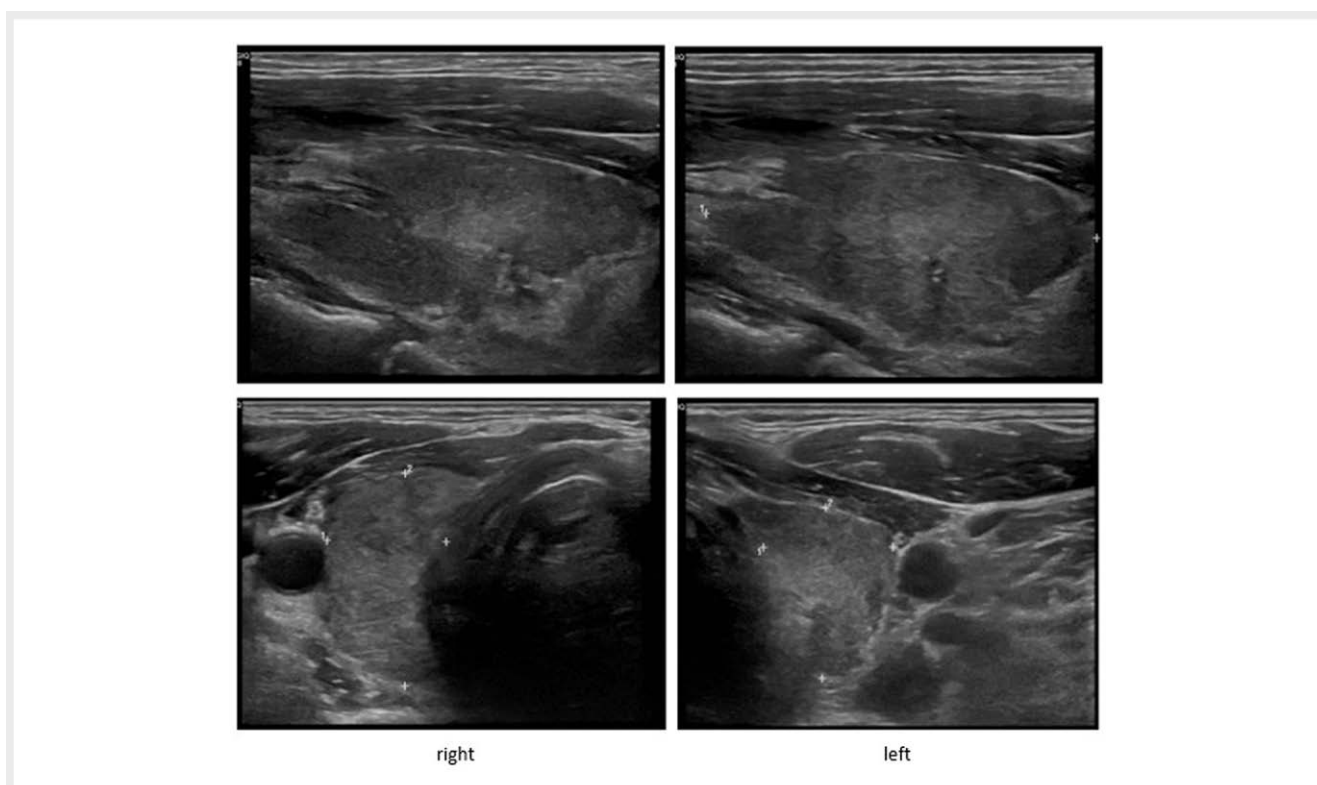
A 63-year-old Caucasian male with no previous history of thyroid disease received the first and the second dose of the BNT162b2 SARS-CoV-2 (Pfizer-BioNTech) vaccine on 19 January 2021 and 9 February 2021, respectively. In April 2021, he developed fatigue and tiredness followed by discomfort in the left neck, that lasted for two weeks and disappeared without treatment. At this point, no further investigation was done. Mid May 2021 symptoms recurred, this time with significant pain on movement in the right neck, followed by new onset of hyperhidrosis, palpitations and subsequently weight loss. There was bilateral sensitivity of the neck on palpation. Magnet resonance imaging (MRI) of the neck was unremarkable, except for some contrast uptake in the right thyroid lobe. At laboratory investigation, C-reactive protein (CRP) and erythrocyte sedimentation rate (ESR) were elevated.

Subsequent evaluation in August 2021 revealed overt hyperthyroidism with positive TSH-R-Ab, thyroid peroxidase (anti-TPO) and thyroglobulin (anti-TG) antibodies (▶ **Table 1**). TSH-R-Ab was measured using the Abbott Alinity i Thyroid-Stimulating Hormone Receptor Antibody (TRAb) Chemiluminescent Microparticle Immunoassay (CMIA) kit. Ultrasound imaging showed a normal-sized thyroid gland (thyroid volume 20 ml) with inhomogeneous texture suggestive of thyroiditis (▶ **Fig. 1**), no nodules, and no cervical lymphadenopathy. Thyroid scintigraphy showed decreased ^{99m}Tc pertechnetate uptake (▶ **Fig. 2**). There was no thyroid eye disease.

► **Table 1** Thyroid function tests.

	Normal value	02.08.21	17.08.21	31.08.21	09.09.21	05.10.21	19.01.22	25.02.22	30.08.2022
TSH	0.27–4.20 μ IU/ml	< 0.03	0.57	43.3	28.5	3.52	4.96	1.84	1.81
ft3	2.0–4.8 pg/ml	6.6	1.6	1.2	2	3	2	2,2	2.3
ft4	0.9–1.8 ng/dl	3.6	0.6	0.7	1	1,5	1.3	2	1.6
TSH-R-Ab	< 1.8 IU/l	7.3	7.5				5.5		2.1
Tg-Ab	< 115 IU/ml	1.051					88		134
Anti-TPO	< 34 IU/ml	206					36		24

TSH: Thyroid stimulating hormone; ft3: Free triiodothyronine; ft4: Free thyroxine; TSH-R-Ab: Thyrotropin receptor antibodies; Anti-TPO: Anti-thyroid peroxidase antibodies; Tg-Ab: Anti-thyroglobulin antibodies.



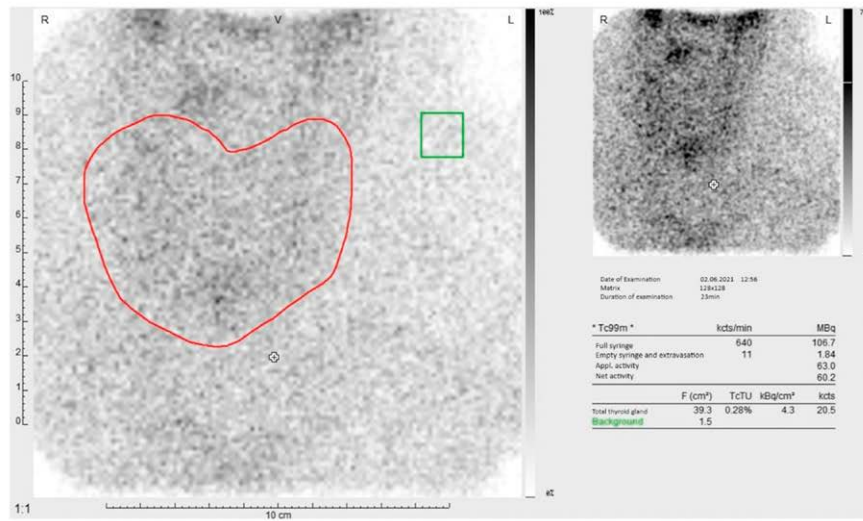
► **Fig. 1** Initial thyroid ultrasound showing an inhomogeneous normal large thyroid (thyroid volume 20 ml) with irregular and ill-defined hypoechoic areas suggestive of thyroiditis.

Family history was negative for autoimmune thyroid diseases. Based on clinical symptoms and laboratory examinations, a diagnosis of SAT was established, and the patient was started on ibuprofen and propranolol, resulting in improvement of symptoms. The reduced uptake on thyroid scintigraphy was considered to argue against GD [20].

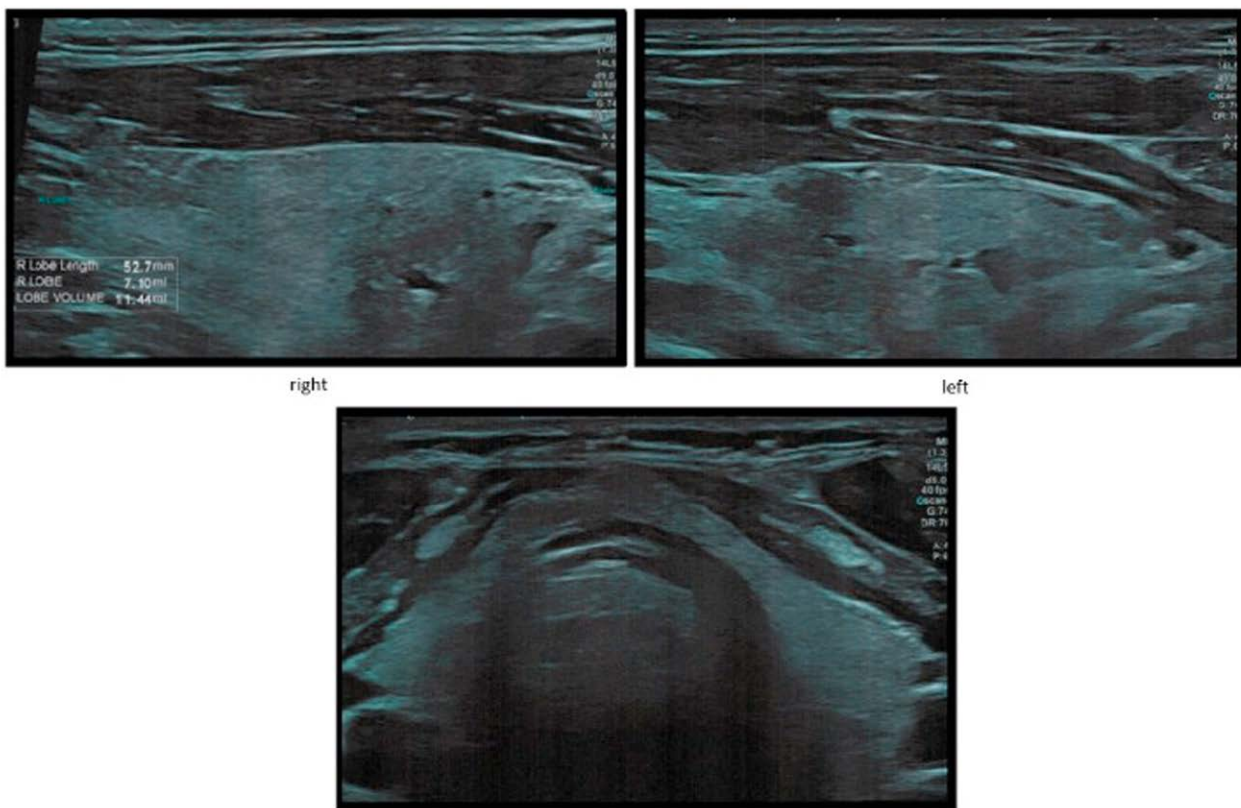
Remarkably, follow-up after two weeks showed rapid development of overt hypothyroidism with low serum ft3 and ft4 concentrations. Levothyroxine (LT4) substitution was initiated, and the daily dose was subsequently increased to achieve biochemical euthyroidism (► **Table 1**). In November 2021, the patient received a

booster vaccination with AstraZeneca's SARS-CoV-2 vaccine with no impact on his thyroid function parameters.

At four months follow-up, the patient was euthyroid on 150 μ g LT4 with positive TSH-R-Ab. Ultrasound showed a decrease in thyroid volume (thyroid volume 11.4 ml) (► **Fig. 3**). Our department was approached for a second opinion. Because of the unusual constellation, GD with blocking TSH-R-Ab was suspected. Hence, TSH-R-Ab functionality was determined through cell-based bioassays as previously described [21]. Both bioassays use Chinese hamster ovary (CHO) cells expressing a chimeric TSHR (Mc4) and cyclic adenosine 5'-monophosphate (cAMP) response element (CRE)-de-



► **Fig. 2** Thyroid scintigraphy showing decreased ^{99m}Tc pertechnetate uptake.



► **Fig. 3** One-year follow-up thyroid ultrasound showing a decrease in thyroid volume (thyroid volume 11.4 ml).

► **Table 2** Conventional binding and functional TSH-R-Ab status.

	Normal value	20.12.2021	24.01.2022	22.02.2022
TSH-R-Ab	≤ 2.58 IU/l	4.1	3.6	3.1
TBAb	≤ 34% Inhib	61	55	57
TSAb	≤ 140 SRR %	141	167	121

All TSH-R-Ab measurements shown in ► **Table 2** were done at the accredited and certified thyroid lab of the Johannes Gutenberg University Medical Center, Mainz, Germany. TSH-R-Ab: Binding thyrotropin receptor antibodies; TBAb: Blocking TSH-R-Ab; TSAb: Stimulating TSH-R-Ab.

pendent luciferase. Serum TSAb concentrations were measured with a chimeric TSHR bioassay using the FDA-cleared cell-based assay (Thyretain, Quidel, San Diego, CA, USA) according to the manufacturer's instructions. Serum TBAb levels were measured using the CE-marked cell-based assay (Quidel) according to the manufacturer's instructions. The TSH-R-Ab functionality assessment [21] revealed the presence of blocking (TBAb) and borderline stimulating (TSAb) TSH-R-Ab in the patient's serum (► **Table 2**).

HLA class I type revealed alleles (► **Table 2**), which have been associated with AITD in previous studies such as the HLA-DRB1*03 allele [22]. In addition, the presence of the HLA-DQ2 haplotype, also detected in our patient is observed in both AITD as well as celiac disease [22]. Overall, the HLA typing results in the patient suggest a higher predisposition to the development of AITD.

In January 2022, the patient's peripheral blood mononuclear cells (PBMC) showed an increase in total cell count and FACS analysis revealed a relatively high proportion of B-cells suggesting the possibility of B-cell activation or expansion, which may be related to the underlying autoimmune disorder.

At the last follow-up of TSH-R-Ab function in February 2022, only blocking TBAb were detected, and at the last follow-up of thyroid hormones and antibody levels in August 2022, the patient was euthyroid on LT4 125 µg/d with persistent GD.

Discussion

Since the beginning of the COVID-19 pandemic in 2019 and the introduction of SARS-CoV-2 vaccination in late 2020, a possible association between new onset of thyroid dysfunction, notably SAT and GD, infection and administration of the vaccine has been suggested [4]. Further vaccination did not seem to impact negatively on thyroid function, since no recurrence of SAT has been reported, while data on GD are sparse [7].

SARS-CoV-2-associated thyroiditis was first reported in 2020, most prominently in COVID patients treated on the intensive care unit (ICU) at a Milan hospital, who showed disproportionately low TSH levels in combination with normal or elevated serum fT4 concentrations, clearly distinguishing them from ICU patients with non-thyroidal illness syndrome. On follow-up of eight COVID pa-

tients with thyroid dysfunction, two exhibited signs of autoimmune thyroiditis and six were euthyroid without detectable thyroid-related antibodies, but with diffuse hypoechoic thyroid texture on ultrasound [23]. The causes and pathomechanism of SAT are not fully understood but have been suggested to reflect post-viral inflammatory response in patients with genetic predisposition [5, 24].

As summarized above, several studies have reported cases of SAT or GD following SARS-CoV-2 vaccination, with a short time interval of 4 to 14 days and 5 to 63 days, respectively between vaccination and onset of thyroid dysfunction [3, 9]. In the reported German patient, the time interval between the first and second SARS-CoV-2 vaccination and symptomatic thyroiditis was longer than usual. Considering the course of disease, thyroid disease in this patient could be related to SARS-CoV-2 vaccination, but other causes cannot be excluded.

As possible pathophysiological mechanisms of thyroid disease following SARS-CoV-2 vaccination, two main hypotheses have been proposed: molecular mimicry and adjuvant-induced autoimmune/inflammatory syndrome (ASIA) [19, 20]. Molecular mimicry refers to the similarity or homology between certain SARS-CoV-2 proteins and human proteins. This genetic resemblance can lead to an immune response targeting both viral and human tissues, potentially resulting in autoimmune thyroid diseases [19, 20]. A study investigating immune reactivity found that anti-SARS-CoV-2 antibodies reacted with various human tissue antigens, including those found in the gastrointestinal, thyroid, and neural tissues [20]. Adjuvant-induced autoimmune/inflammatory syndrome (ASIA) is another proposed mechanism. Adjuvants are substances used in vaccines to enhance the immune response. In some individuals, exposure to adjuvants can lead to immune dysregulation and the development of autoimmune diseases [25].

The German patient reported here is remarkable for several reasons: A limited number of cases has been described in the literature, in which GD with stimulating TSH-R-Ab indeed occurred after SAT [26–28]. In the published literature however, there is no report on presence of TBAb or persistent Graves' hypothyroidism after SARS-CoV-2 vaccination, so the German patient is unique in this respect. Furthermore, TSH-R-Ab, whether stimulating or blocking, pathognomonic for GD, were present when our patient clinically had SAT with TH excess. However, due to the local symptoms with cervical pain and increased inflammation values, we assumed a SAT and since thyroid scintigraphy showed no uptake, one likely explanation is that initially and temporarily destructive thyroiditis overruled GD. Of the 51 patients included in the first systematic review of SAT secondary to SARS-CoV-2 vaccination, none was TSH-R-Ab-positive [3].

After transient thyrotoxicosis, the here reported patient rapidly developed persistent hypothyroidism, which now persists over more than 12 months requiring permanent weight adapted full replacement dosage of daily 125 µg pf levothyroxine. SAT itself can result in long-term hypothyroidism due to severe destruction of functional thyroid tissue [29]. In a series of patients who developed SAT after SARS-CoV-2 vaccination with follow-up over 8 to 16 weeks, four of ten patients for whom data were available, still had hypothyroidism [3]. We suggest however, that the persistence of hypothyroidism in the German patient is due to persistent TSH-R

blocking antibodies, underscoring an unusual case of GD. TSH-R-Ab can be stimulatory (TSAb), blocking (TBAb) or neutral. The stimulating TSH-R-Ab are characteristic of immune hyperthyroidism, while blocking TSH-R-Ab confer immune hypothyroidism [30].

The use of cell-based bioassays for the detection and measurement of TSH-R-Ab is advantageous because, compared with the conventional binding immunoassay, this assay is more sensitive at lower concentrations of TSH-R-Ab and is exclusively specific at distinguishing the functionality of TSH-R-Ab [31].

Since TSH-R-Ab functionality was only determined in the course of the disease, one could speculate whether the initially detected TSH-R-Ab in the German patient had blocking or stimulating activity or both [32–34]. Studies have shown that differentially functioning TSH-R-Ab can coexist in the same patient [35, 36]. The balance between TBAb and TSAb determines whether a patient has hypo- or hyperthyroidism at any given time [36]. In the here reported case, borderline positive stimulating and high concentrations of blocking antibodies were observed at first measurement. However, TSAb disappeared rapidly while positive TBAb sustained in further measurements hence explaining biochemical hypothyroidism and LT4 substitution.

The clinical significance of the presence of TBAb in the context of autoimmune thyroid diseases is a subject of ongoing research and an issue for disease definition. Due to their blocking nature, TBAb are naturally associated with some degree of thyroid atrophy [37], also observed in the German patient. Whether this is transient or further propelled by additional destructive thyroiditis is not known. In a case series, in which 34 TBAb-positive patients with hypothyroidism were studied over a 10-year period, half of the TBAb-positive patients with hypothyroidism continued to have persistently positive TBAb serum levels and hypothyroidism, from which they did not recover [38]. In the German patient, the persistence of TBAb leading to hypothyroidism and thyroid volume reduction was still present at the last follow-up, 12 months after first diagnosis of thyroid dysfunction.

Conclusion

This review summarizes published reports on SAT and GD following SARS-CoV-2 vaccination. Although the temporal sequence of the cases described so far may suggest a possible association between new onset of symptoms, thyrotoxicosis and SARS-CoV-2 vaccination, a causal relationship is not proven. Research regarding possible side effects of vaccination are key elements of public health practice. Triggering of auto-immune processes is possible but in view of the billions of SARS-CoV-2 vaccinations administered to date may be considered a very rare event. This is also backed by safety data and previous publications addressing impact of SARS-Cov-2 vaccination in Turkish, Hong Kong and Singaporean individuals with and without autoimmune thyroid disease [7, 9]. However, the reported German case illustrates that these exceedingly rare events should not be overlooked in the general population. Furthermore, though not routinely available functional analysis of TSH-R-Ab may clarify unusual thyroid function in patients with immune thyroid disease. Additionally, monitoring TBAb serially may affect the accurate management of this patient. In fact, serocon-

version with disappearance of these functional (blocking) TSH-R-Ab will have an impact on daily LT4 dosage and potentially even thyroid volume.

Conflict of Interest

The authors declare that they have no conflict of interest.

References

- [1] Zhou P, Yang XL, Wang XG et al. Addendum: A pneumonia outbreak associated with a new coronavirus of probable bat origin. *Nature* 2020; 588: E6
- [2] Chung YH, Beiss V, Fiering SN et al. COVID-19 Vaccine frontrunners and their nanotechnology design. *ACS Nano* 2020; 14: 12522–12537
- [3] Ippolito S, Gallo D, Rossini A et al. SARS-CoV-2 vaccine-associated subacute thyroiditis: insights from a systematic review. *J Endocrinol Invest* 2022; 45: 1189–1200
- [4] Jafarzadeh A, Nemati M, Jafarzadeh S et al. Thyroid dysfunction following vaccination with COVID-19 vaccines: a basic review of the preliminary evidence. *J Endocrinol Invest* 2022; 45: 1835–1863
- [5] Nishihara E, Ohye H, Amino N et al. Clinical characteristics of 852 patients with subacute thyroiditis before treatment. *Intern Med* 2008; 47: 725–729
- [6] Yorulmaz G, Sahin Tekin M. SARS-CoV-2 vaccine-associated subacute thyroiditis. *J Endocrinol Invest* 2022; 45: 1341–1347
- [7] Oguz SH, Sendur SN, Iremlı BG et al. SARS-CoV-2 Vaccine-induced thyroiditis: safety of revaccinations and clinical follow-up. *J Clin Endocrinol Metab* 2022; 107: e1823–e1834
- [8] Iremlı BG, Sendur SN, Unluturk U. Three cases of subacute thyroiditis following SARS-CoV-2 vaccine: postvaccination ASIA syndrome. *J Clin Endocrinol Metab* 2021; 106: 2600–2605
- [9] Chee YJ, Liew H, Hoi WH et al. SARS-CoV-2 mRNA Vaccination and Graves' disease: a report of 12 cases and review of the literature. *J Clin Endocrinol Metab* 2022; 107: e2324–e2330
- [10] Brancatella A, Viola N, Santini F et al. COVID-induced thyroid autoimmunity. *Best Pract Res Clin Endocrinol Metab* 2023; 101742
- [11] Bostan H, Ucan B, Kizilgul M et al. Relapsed and newly diagnosed Graves' disease due to immunization against COVID-19: a case series and review of the literature. *J Autoimmun* 2022; 128: 102809
- [12] Patrizio A, Ferrari SM, Elia G et al. Graves' disease following SARS-CoV-2 vaccination: a systematic review. *Vaccines (Basel)* 2022; 10: 1445
- [13] di Filippo L, Castellino L, Allora A et al. Distinct clinical features of post-COVID-19 vaccination early-onset Graves' disease. *J Clin Endocrinol Metab* 2022; 108: 107–113
- [14] Eckstein AK, Losch C, Glowacka D et al. Euthyroid and primarily hypothyroid patients develop milder and significantly more asymmetrical Graves ophthalmopathy. *Br J Ophthalmol* 2009; 93: 1052–1056
- [15] Chin YH, Ng CH, Lee MH et al. Prevalence of thyroid eye disease in Graves' disease: A meta-analysis and systematic review. *Clin Endocrinol (Oxf)* 2020; 93: 363–374
- [16] Abeillon-du Payrat J, Grunenwald S, Gall E et al. Graves' orbitopathy post-SARS-CoV-2 vaccines: report on six patients. *J Endocrinol Invest* 2023; 46: 617–627

- [17] Mohamed A, Tzoulis P, Kossler AL et al. New onset or deterioration of thyroid eye disease after mRNA SARS-CoV-2 vaccines: report of 2 cases and literature review. *J Clin Endocrinol Metab* 2023; 108: 979–985
- [18] Patrizio A, Ferrari SM, Antonelli A et al. Worsening of Graves' ophthalmopathy after SARS-CoV-2 mRNA vaccination. *Autoimmun Rev* 2022; 21: 103096
- [19] Patrizio A, Ferrari SM, Antonelli A et al. A case of Graves' disease and type 1 diabetes mellitus following SARS-CoV-2 vaccination. *J Autoimmun* 2021; 125: 102738
- [20] Kahaly GJ, Bartalena L, Hegedus L et al. 2018 European thyroid association guideline for the management of Graves' hyperthyroidism. *Eur Thyroid J* 2018; 7: 167–186
- [21] Kahaly GJ, Diana T, Kanitz M et al. Prospective trial of functional thyrotropin receptor antibodies in Graves disease. *J Clin Endocrinol Metab* 2020; 105: e1006–e1014
- [22] Kahaly GJ, Frommer L, Schuppan D. Celiac disease and endocrine autoimmunity - the genetic link. *Autoimmun Rev* 2018; 17: 1169–1175
- [23] Muller I, Cannavaro D, Dazzi D et al. SARS-CoV-2-related atypical thyroiditis. *Lancet Diabetes Endocrinol* 2020; 8: 739–741
- [24] Desailly R, Hober D. Viruses and thyroiditis: an update. *Virology* 2009; 6: 5
- [25] Shoenfeld Y, Agmon-Levin N. 'ASIA' - autoimmune/inflammatory syndrome induced by adjuvants. *J Autoimmun* 2011; 36: 4–8
- [26] Werner SC. Graves' disease following acute (subacute) thyroiditis. *Arch Intern Med* 1979; 139: 1313–1315
- [27] Nagai Y, Toya T, Fukuoka K et al. Occurrence and spontaneous remission of Graves' hyperthyroidism preceded by painless thyroiditis. *Endocr J* 1997; 44: 881–885
- [28] Jafarzadeh A, Nemati M, Jafarzadeh S et al. Thyroid dysfunction following vaccination with COVID-19 vaccines: a basic review of the preliminary evidence. *J Endocrinol Invest* 2022; 45: 1835–1863
- [29] Fatourehchi V, Aniszewski JP, Fatourehchi GZ et al. Clinical features and outcome of subacute thyroiditis in an incidence cohort: Olmsted County, Minnesota, study. *J Clin Endocrinol Metab* 2003; 88: 2100–2105
- [30] Kahaly GJ, Diana T, Olivo PD. Tsh Receptor antibodies: relevance & utility. *Endocr Pract* 2020; 26: 97–106
- [31] Diana T, Wuster C, Olivo PD et al. Performance and specificity of 6 immunoassays for TSH receptor antibodies: a multicenter study. *Eur Thyroid J* 2017; 6: 243–249
- [32] Faust B, Billesbolle CB, Suomivuori CM et al. Autoantibody mimicry of hormone action at the thyrotropin receptor. *Nature* 2022; 609: 846–853
- [33] Duan J, Xu P, Luan X et al. Hormone- and antibody-mediated activation of the thyrotropin receptor. *Nature* 2022; 609: 854–859
- [34] Diana T, Olivo PD, Kahaly GJ. Thyrotropin receptor blocking antibodies. *Horm Metab Res* 2018; 50: 853–862
- [35] Evans M, Sanders J, Tagami T et al. Monoclonal autoantibodies to the TSH receptor, one with stimulating activity and one with blocking activity, obtained from the same blood sample. *Clin Endocrinol (Oxf)* 2010; 73: 404–412
- [36] Takasu N, Yamashiro K, Ochi Y et al. TSBAbs (TSH-stimulation blocking antibody) and TSAB (thyroid stimulating antibody) in TSBAbs-positive patients with hypothyroidism and Graves' patients with hyperthyroidism. *Horm Metab Res* 2001; 33: 232–237
- [37] McLachlan SM, Rapoport B. Thyrotropin-blocking autoantibodies and thyroid-stimulating autoantibodies: potential mechanisms involved in the pendulum swinging from hypothyroidism to hyperthyroidism or vice versa. *Thyroid* 2013; 23: 14–24
- [38] Takasu N, Matsushita M. Changes of TSH-stimulation blocking antibody (TSBAbs) and thyroid stimulating antibody (TSAB) over 10 years in 34 TSBAbs-positive patients with hypothyroidism and in 98 TSAB-positive Graves' patients with hyperthyroidism: reevaluation of TSBAbs and TSAB in TSH-receptor-antibody (TRAb)-positive patients. *J Thyroid Res* 2012; 182176: