Article published online: 2024-02-08

Esophageal Leiomyoma: Case Report

OPEN ACCESS

Background

Benign esophageal neoplasms are rare and account for less than 10 % of esophageal tumors. Esophageal leiomyomas are benign mesenchymal tumors of the esophagus, which are usually located in the distal esophagus (Wong T et al. Case Rep Gastroenterol 2021; 15: 861–868). Despite its rarity, esophageal leiomyoma is considered the most common benign form of esophageal tumor. Leiomyoma consists of smooth muscle and fibrous tissue. It usually occurs in middle-aged patients and is twice as common in men (Andrási L et al. BMC Gastroenterol 2021; 21: 47). The size of esophageal leiomyoma is quite variable, but is usually less than 3 cm. Most patients are asymptomatic so that esophageal leiomyoma is detected incidentally during radiological examinations for other reasons. There are very few cases of ultrasound diagnosis of leiomyoma in the literature. Symptoms such as dysphagia, chest pain, and regurgitation are usually associated with a large tumor size (Hasan W et al. Am J Case Rep 2021; 15: 22).

Case presentation

We present a case of a 20-year-old female who visited our clinic for a routine ultrasound study of the thyroid gland. The patient did not have any complaints regarding the esophagus or lungs. Her family and social history were unremarkable. During examination of the thyroid gland, in the projection of the esophagus (cervical section, upper third), an additional mass measuring 28 x 13 mm, with an oval shape, homogeneous structure, an even contour, no blood flow, and medium echogenicity that was not displaced by swallowing and not compressed by the sensor was detected on Doppler color flow mapping. When the patient drank 10 ml of fluid, the detected mass did not change its location and shape, and the fluid was visualized along the outer edges of the mass (▶ **Fig. 1, 2**).

The patient was referred for examination of the esophagus with barium. It was diagnosed that in the upper third of the esophagus at the border of the transition of the cervical to the thoracic department, there was a round-shaped filling defect of 25 x 35 mm in size, where at this level the relief is not clearly visible, the outer contours of the esophagus are smooth, and the elasticity of the walls is preserved (▶ **Fig. 3**). Esophagogastroduodenoscopy showed: in the upper third of the esophagus, at a distance of 20–22 cm from the incisors, a submucosal mass with a spherical shape and a smooth surface and on a wide base. The mucosa above it was not changed, and the lumen of the esophagus in this location was deformed (▶ **Fig. 4**).

Discussion

Most esophageal tumors are asymptomatic and are detected by chance. The presented case of ultrasound diagnosis of upper esophageal leiomyoma was not accompanied by symptoms. Usually, clinical symptoms occur when the tumor is large enough to compress adjacent structures, causing dysphagia, chest pain, or regurgitation. Unlike gastric leiomyoma, upper gastrointestinal leiomyomas rarely cause bleeding. Interestingly, the literature describes very few cases of ultrasound diagnosis of esophageal leiomyomas.

Although this case involved a solitary esophageal leiomyoma, it should be noted that 3 % to 4 % of patients have multiple leiomyomas. In addition, gynecologic leiomyomas can coexist in certain genetic syndromes (Peixoto A. Radiol Case Rep 2022;

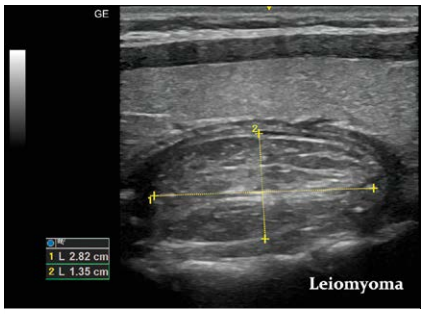

▶ **Fig. 1** Ultrasound examination of the thyroid gland with a linear probe. In the projection of the lower border of the thyroid gland, an additional mass with a size of 28 x 13 mm can be seen. Oval shape with clear smooth contours.

▶ **Fig. 2** Ultrasound examination of the thyroid gland with a linear probe. In the projection of the esophagus, on the left, an additional mass is seen, oval in shape with clear smooth contours.

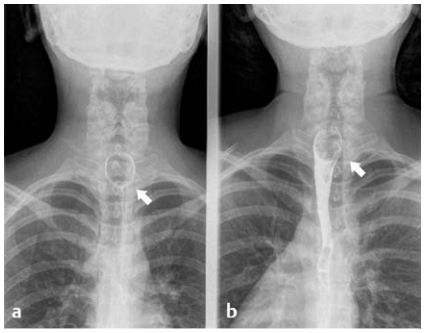

▶ **Fig. 3** X-ray examination of the esophagus with barium. In the upper third of the esophagus on the border of the transition of the cervical to the thoracic department, a round-shaped filling defect is determined, 25 x 35 mm in size, the outer contours of the esophagus are smooth, the elasticity of the walls is preserved. (**a** – on the back, **b** – on the stomach).

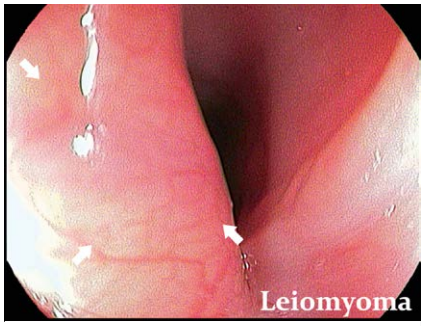

▶ **Fig. 4** Esophagogastroduodenoscopy in the upper third of the esophagus. A submucosal, spherical mass is detected, smooth on a wide base, the mucosa above it is not changed, the lumen of the esophagus in this area is deformed.

17: 4417–4420). Radiological imaging is important to establish the diagnosis, as some findings may be unique to leiomyoma. As in this case, chest radiography may show a posterior mediastinal mass (Yang PS et al. Korean J Radiol 2001; 2: 132–137). Upper gastrointestinal studies, which are most commonly performed to evaluate esophageal lesions, typically show lesions with a smooth surface and normal mucosa, with the upper and lower borders of the lesion forming acute or slightly obtuse angles with the adjacent esophageal wall (Shi YJ et al. Abdom Radiol 2022; 47: 2747–2759). Endoscopic ultrasound demonstrates high accuracy in the diagnosis of esophageal leiomyomas exhibiting a hypoechoic and homogeneous mass with sharply demarcated margins in the muscular layer (Liang M et al. J Int Med Res. 2020; 48: 30006052096 1246). Although the identification of some of these lesions can be carried out immediately, solely based on their echo characteristics, for certain lesions histological examination is necessary. New methods have been developed in recent years to assist decision making, such as contrast-enhanced endosonography, endoscopic ultrasound elastography with guided fine-needle biopsy and fine-needle aspiration, and artificial intelligence systems.

Conclusion

Esophageal leiomyoma is quite rare, especially if it affects the upper part of the thoracic esophagus. The tumor may present exclusively with respiratory symptoms without any involvement of the gastrointestinal tract or can be asymptomatic. Esophageal leiomyomas may be misdiagnosed due to atypical symptoms, an unusual location, or atypical imaging features. Recognizing the ultrasound imaging features of esophageal leiomyoma is essential for detection, early diagnosis, and treatment. Endoscopic and radiological studies are important to differentiate esophageal leiomyoma from other esophageal lesions, including malignant tumors.

Conflict of Interest

The authors declare that they have no conflict of interest.

Authors

Olga Kharlamova[1], **Maksym Zhayvoronok**[2]

Affiliations

1 Diagnostic Ultrasound Unit, Volyn Regional Medical Center of Oncology, Lutsk, Ukraine

2 Department of Nuclear Medicine, Radiation Oncology and Radiation Safety, Shupyk National Healthcare University of Ukraine, Kyiv, Ukraine, Kyiv, Ukraine

Correspondence

Maksym Zhayvoronok
Department of Nuclear Medicine, Radiation Oncology and Radiation Safety, Shupyk National Healthcare University of Ukraine
03037 Kyiv
Ukraine
zhayvoronok.m@ukr.net

published online 2024

Bibliography

Ultrasound Int Open 2024; 10: a22216110
DOI 10.1055/a-2221-6110
ISSN 2509-596X

Georg Thieme Verlag KG, Rüdigerstraße 14, 70469 Stuttgart, Germany