

# Bilateral Spontaneous Suprachoroidal Haemorrhage Induced by the Valsalva Manoeuvre: A Challenging Diagnosis

## Bilaterale spontane suprachoroidale Blutung, hervorgerufen durch das Valsalva-Manöver: eine herausfordernde Diagnose



### Introduction

Suprachoroidal haemorrhage (SCH) denotes a pathological entity characterised by the pathologic accumulation of blood within the suprachoroidal space, a virtual compartment between the choroid and the sclera. SCH occurrence, while relatively infrequent, carries substantial clinical significance, and it may develop spontaneously, during or after ophthalmic surgical procedures, or as a sequel to ocular trauma. In the event that postoperative SCH remains undetected and untreated, it can lead to profound visual impairment, potentially culminating in complete vision loss or blindness [1–3]. It occurs when the vortical veins or the long and/or short ciliary arteries rupture, and its most significant risk factor is hypotony, or the sudden intraocular pressure drops during or after ophthalmic surgery [4,5]. SCH has also been reported subsequent to ocular trauma, or spontaneously in patients harbouring specific ocular or systemic predisposing risk factors, such as advanced age, atherosclerosis, vascular disease, arterial hypertension, anticoagulation therapy, chronic kidney disease, aphakia, age-related macular degeneration, myopia, and glaucoma [6–11].

In the majority of spontaneous cases documented in the literature, patients exhibited a predisposition to haemorrhagic events due to underlying inherited blood dyscrasia or a history of systemic antithrombotic therapy usage, including antiplatelet, anticoagulation, or thrombolytic agents [3, 12, 13].

The aim of this report is to present the case of a patient who developed bilateral spontaneous suprachoroidal haemorrhage (SSCH) following a Valsalva manoeuvre, without a preexisting inherited bleeding disorder or the use of an antithrombotic agent, and no other known ocular condi-

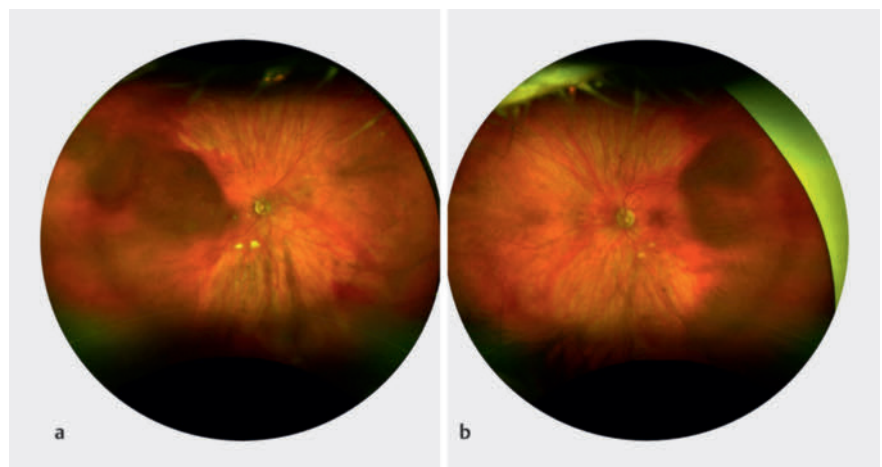
tion predisposing to choroidal bleeding. To the best of our knowledge, this is the first time that a bilateral SSCH following a Valsalva manoeuvre has been reported.

This report followed the tenets of the Declaration of Helsinki.

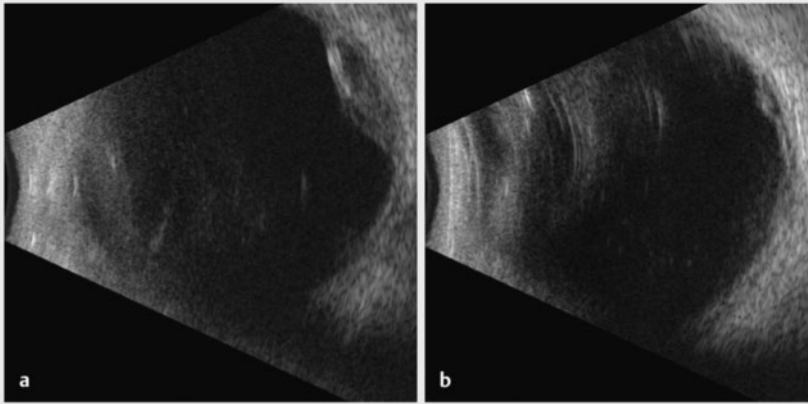
### Case Presentation

A 75-year-old Caucasian female was referred to our ophthalmology department because a bilateral hyperdense mass in both eyeballs was revealed on a head CT scan. The patient reported blurred vision in the right eye since the previous night, following a Valsalva manoeuvre because of intense vomiting due to alcohol consumption. She was known to be mildly myopic for both eyes, with no relevant ophthalmic history, except for bilateral cataract surgery several years before. General history revealed treated and well-controlled hypertension. There was no history of clotting disorders, nor anticoagulation medication. Best-corrected visual acuity was 20/20 for both eyes. The slit lamp examination of the anterior segment was

unremarkable. However, the dilated funduscopy revealed a bilateral posterior red-brown mass in the upper-temporal quadrant (► Fig. 1). The B-scan ultrasonography examination revealed those masses to be isoechogenic and into the choroid structure, with a thickness of 3.5 mm for the right eye and 1.5 for the left eye without any sign of choroidal excavation (► Fig. 2). Those lesions remained unrevealed through fluorescein and indocyanine green angiography (► Fig. 3). Thanks to enhanced depth imaging spectral-domain optical coherence tomography (SD-OCT) scans, the lesions were located in the suprachoroidal space. Even if not involving the macular region, the right eye lesion showed retinal folds in the foveal region (► Fig. 4). The clinical presentation, the aspect of the B-scan ultrasonography, and SD-OCT, as well as the absence of any identifiable systemic aetiology led to the diagnosis of Valsalva-induced bilateral SSCH. Given the fact that visual acuity was preserved in both eyes, we closely followed up with the patient without any intervention. The workup for blood clotting disorders returned negative. One week



► Fig. 1 Fundus photography of the RE (a) and LE (b) revealing a bilateral posterior red-brown choroidal mass in the upper temporal quadrant.



► **Fig. 2** B-scan ultrasonography showing an isoechoic mass of 3.5 mm thickness of the RE (a) and 1.5 mm for the LE (b).

after the first evaluation, the patient was asymptomatic and the suprachoroidal haemorrhages in both eyes were diminishing.

## Discussion

SSCH is an infrequent condition, characterised by an unfavourable visual prognosis [8, 11]. Literature is scarce of reports presenting SSCH development in patients with no predisposing systemic or ocular conditions, and very few of them with bilateral involvement [14–17].

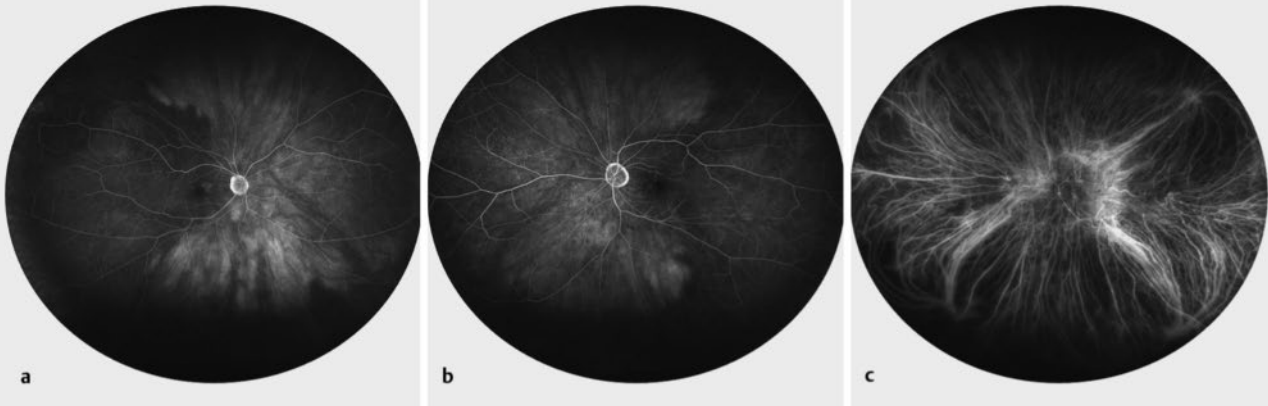
The Valsalva manoeuvre is an established cause of intraretinal and preretinal haemorrhage, but the association with SCH has

been rarely reported, and never bilateral [18–24]. It induces a rapid increase in intrathoracic or intra-abdominal pressure while the glottis remains closed. Due to the absence of valves within the venous system, this elevated pressure is transferred to the eye, leading to the rupture of vessel walls, probably due to an excessive pressure gradient acting across the vessel wall [18, 25]. The causal relationship between the Valsalva manoeuvre subsequent to emesis resulting from alcohol ingestion and the onset of bilateral SSCH in our patient remains uncertain. We postulate that our patient might have harboured preexisting choroidal anomalies associated with her advanced age and/or vascular pathology, which could have con-

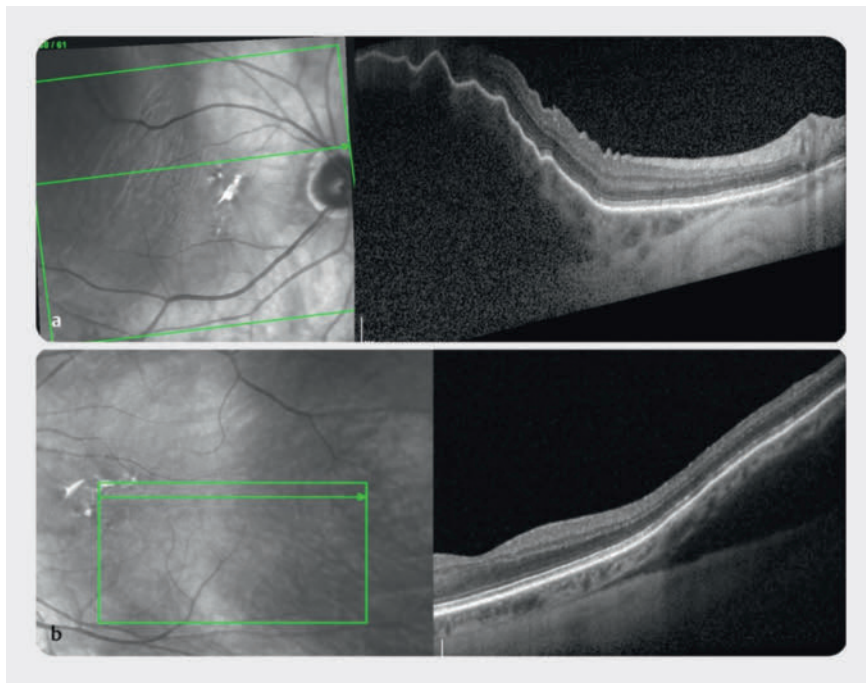
tributed to the development of bilateral SSCH subsequent to emesis. However, our patient's presentation is particularly unusual due to the absence of ocular risk factors or recent previous ophthalmic surgery.

SCH after a Valsalva manoeuvre has been previously reported in patients either on systemic anti-coagulants, or in eyes with previous ocular surgery, such as scleral buckling [19, 21, 23, 26]. Valsalva-induced SSCH has also been reported to be associated with certain ophthalmic risk factors such as high myopia and age-related macular degeneration [20, 22].

Very few cases have been described in association with Valsalva manoeuvres with no underlying or associated systemic or ophthalmological conditions. In 2003, Hammam and Madhavan described the case of a 65-year-old man who suffered from a unilateral small choroidal haemorrhage caused by the Valsalva manoeuvre that resulted in a sudden increase in intraocular pressure and subsequent corneal oedema. The patient had no history of ocular or bleeding disorder, and a routine coagulation screening test was within normal limits. The correct diagnosis was revealed thanks to ultrasound, and a total resolution of the SCH was detected at 2 weeks [18]. Similar to our case, Castro Flórez and colleagues recently published the case of a 70-year-old woman with a unilateral SCH after a Valsalva manoeuvre during defecation. The patient had no



► **Fig. 3** Fluorescein angiography of the RE (a) and LE (b) showing an attenuated visualisation of the choroidal perfusion; indocyanine green angiography of the LE (c) within normal limits.



► **Fig. 4** SD-OCT of the RE (a) and LE (b). The lesions are located in the suprachoroidal space.

ophthalmological or personal history of interest except for arterial hypertension under treatment, and the lesions completely resolved in 12 weeks [24].

Our findings demonstrate that the enhanced depth imaging SD-OCT improves the visualisation of the choroid due to its greater penetrance. Also, it offers adequate axial resolution to discern tissue layers on the inner boundary of the haemorrhage, as well as sufficient penetration capability through the blood collection for imaging the inner aspect of the sclera and definitively localising the haemorrhage within the suprachoroidal space. However, when it came to our patient's left eye, where the SCH was located in the peripheral fundus, SD-OCT images proved less effective for localising the lesion. In such situations, ultrasound emerged as a more versatile diagnostic tool.

The differential diagnosis of SCH presents a significant challenge in numerous cases, frequently leading to confusion with choroidal tumours. An analysis of 12 000 patients referred to an eye oncology unit over a 25-year period with an initial diagnosis of choroidal melanoma revealed that

29 cases (0.24%) were ultimately found to be choroidal haemorrhages [27]. There are certain clinical characteristics that can help to differentiate a haemorrhage from a choroidal tumour, such as the presence of choroidal folds, absence of drusen, absence of lipofuscin, and a more reddish colour [24]. The images acquired through EDI-OCT play a crucial role in the process of distinguishing between SCH and potential tumours, such as small choroidal melanomas or metastases, in the differential diagnosis [28, 29]. In the case of SCH, the choroidal tissue shows an anterior displacement but retains its normal thickness and appearance, which contrasts with the situation in a choroidal tumour, where the choriocapillaris is compressed and challenging to visualise. Moreover, the elevated surface of SCH has an irregular appearance, which could be due to the retraction of the clot [28]. On the other side, choroidal melanomas typically exhibit a smooth and uniform surface, whereas in the case of choroidal metastases, the anterior contour can sometimes appear irregular, manifesting as a bumpy or lumpy texture [24]. Other important differential diagnoses are choroidal detachment and peripheral exudative haemorrhagic cho-


rioretinopathy (PEHCR), where the presence of a choroidal neovascular membrane typical of the PEHCR.

In conclusion, this case report shows a rare finding of bilateral SSCH induced by the Valsalva manoeuvre. This atypical presentation, and the fact that it was bilateral, has an important clinical relevance in order to make clinicians aware of the possibility of these findings, with the goal to prevent erroneous diagnosis and unnecessary treatments. Ultimately, employing multimodal retinal imaging proves to be a valuable instrument for steering toward an accurate diagnosis.

### Conflict of Interest

The authors declare that they have no conflict of interest.

### Authors

Giorgio Enrico Bravetti , Sébastien Van Delden, Simon Magnin, Gabriele Thumann, Ariane Malclès  
Department of Ophthalmology, Geneva University Hospitals, Genève, Switzerland

### Correspondence

#### Dr. Giorgio Enrico Bravetti

Department of Ophthalmology  
Geneva University Hospitals  
Rue Alcide-Jentz 22  
1205 Geneva  
Switzerland  
Phone: + 41 (0) 2 23 72 84 00  
giorgioenrico.bravetti@gmail.com

### References

- [1] Mohan S, Sadeghi E, Mohan M et al. Suprachoroidal Hemorrhage. *Ophthalmologica* 2023. doi:10.1159/000533937
- [2] Sukpen I, Stewart JM. Acute Intraoperative Suprachoroidal Hemorrhage During Small-Gauge Pars Plana Vitrectomy. *Retin Cases Brief Rep* 2018; 12 (Suppl. 1): S9–S11. doi:10.1097/icb.0000000000000659
- [3] Chu TG, Green RL. Suprachoroidal hemorrhage. *Surv Ophthalmol* 1999; 43: 471–486. doi:10.1016/s0039-6257(99)00037-5
- [4] Jiang H, Gao Y, Fu W et al. Risk Factors and Treatments of Suprachoroidal Hemorrhage. *Biomed Res Int* 2022; 2022: 6539917. doi:10.1155/2022/6539917
- [5] Oliver-Gutierrez D, Martin Nalda S, Segura-Duch G et al. Delayed suprachoroidal hemorrhage after Descemet Stripping Automated

- Endothelial Keratoplasty (DSAEK). *Arch Soc Esp Ophthalmol (Engl Ed)* 2023; 98: 355–359. doi:10.1016/j.oftale.2023.04.001
- [6] Shan H, Wu X, Guo H. Spontaneous suprachoroidal and orbital hemorrhage in an older woman associated with prophylactic antiplatelet therapy: A case report and literature review. *Heliyon* 2022; 8: e11511. doi:10.1016/j.heliyon.2022.e11511
- [7] Azimi A, Abdollahi F, Sadeghi E et al. Epidemiological and Clinical Features of Pediatric Open Globe Injuries: A Report from Southern Iran. *J Ophthalmic Vis Res* 2023; 18: 88–96. doi:10.18502/jovr.v18i1.12729
- [8] Akkan Aydoğmuş FS, Serdar K, Kalayci D et al. Spontaneous Suprachoroidal Hemorrhage Associated with Iatrogenic Coagulopathy. *Retin Cases Brief Rep* 2019; 13: 174–175. doi:10.1097/icb.0000000000000554
- [9] Chandra A, Barsam A, Hugkulstone C. A spontaneous suprachoroidal haemorrhage: a case report. *Cases J* 2009; 2: 185. doi:10.1186/1757-1626-2-185
- [10] Chen YY, Chen YY, Sheu SJ. Spontaneous suprachoroidal hemorrhage associated with age-related macular degeneration and anticoagulation therapy. *J Chin Med Assoc* 2009; 72: 385–387. doi:10.1016/s1726-4901(09)70393-4
- [11] Srikanth K, Kumar MA. Spontaneous exulsive suprachoroidal hemorrhage caused by decompensated liver disease. *Indian J Ophthalmol* 2013; 61: 78–79. doi:10.4103/0301-4738.107201
- [12] Saatci AO, Kuvaki B, Oner FH et al. Bilateral massive choroidal hemorrhage secondary to Glanzmann's syndrome. *Ophthalmic Surg Lasers* 2002; 33: 148–151
- [13] Yang SS, Fu AD, McDonald HR et al. Massive spontaneous choroidal hemorrhage. *Retina* 2003; 23: 139–144. doi:10.1097/00006982-200304000-00001
- [14] Collon S, Teske M, Simonett J. Bilateral Spontaneous Suprachoroidal Hemorrhage after Systemic Tissue Plasminogen Activator. *Ophthalmol Retina* 2022; 6: 519. doi:10.1016/j.oret.2022.03.023
- [15] Salvá-Palomeque T, Ruiz-Casas D, Alonso-Formento N. Bilateral spontaneous suprachoroidal hemorrhage in a patient taking a low-molecular-weight-heparin. *Arch Soc Esp Ophthalmol (Engl Ed)* 2021; 96: 615–617. doi:10.1016/j.oftale.2020.11.004
- [16] Haridas A, Litwin AS, Coker T. Perioperative spontaneous bilateral suprachoroidal hemorrhage. *Digit J Ophthalmol* 2011; 17: 9–11. doi:10.5693/djo.02.2011.02.002
- [17] Cheung AY, David JA, Ober MD. Spontaneous Bilateral Hemorrhagic Choroidal Detachments Associated with Malignant Hypertension. *Retin Cases Brief Rep* 2017; 11: 175–179. doi:10.1097/icb.0000000000000322
- [18] Hammam T, Madhavan C. Spontaneous suprachoroidal haemorrhage following a Valsalva manoeuvre. *Eye (Lond)* 2003; 17: 261–262. doi:10.1038/sj.eye.6700298
- [19] van Meurs JC, van den Bosch WA. Suprachoroidal hemorrhage following a Valsalva maneuver. *Arch Ophthalmol* 1993; 111: 1025–1026. doi:10.1001/archoph.1993.01090080021008
- [20] Zahid S, Dansingani KK, Fisher Y. Optical Coherence Tomography Evaluation of Valsalva-Induced Suprachoroidal Hemorrhage. *Ophthalmic Surg Lasers Imaging Retina* 2016; 47: 674–676. doi:10.3928/23258160-20160707-11
- [21] Pollack AL, McDonald HR, Ai E et al. Massive suprachoroidal hemorrhage during pars plana vitrectomy associated with Valsalva maneuver. *Am J Ophthalmol* 2001; 132: 383–387. doi:10.1016/s0002-9394(01)01049-2
- [22] Hsiao SF, Shih MH, Huang FC. Spontaneous suprachoroidal hemorrhage: Case report and review of the literature. *Taiwan J Ophthalmol* 2016; 6: 36–41. doi:10.1016/j.tjo.2014.10.008
- [23] Bijon J, Schalenbourg A. Valsalva-Induced Spontaneous Suprachoroidal Hemorrhage: A Case Report and Review of the Literature. *Klin Monbl Augenheilkd* 2022; 239: 559–564. doi:10.1055/a-1785-4912
- [24] Castro Flórez R, Azpitarte C, Arcos Villegas G et al. Suprachoroidal hemorrhage due to Valsalva maneuver, importance of enhanced depth imaging optical coherence tomography in differential diagnosis. *Arch Soc Esp Ophthalmol (Engl Ed)* 2021; 96: 442–445. doi:10.1016/j.oftale.2020.08.003
- [25] Meyers SM, Foster RE. Choroidal hemorrhage after Valsalva's maneuver in eyes with a previous scleral buckle. *Ophthalmic Surg* 1995; 26: 216–217
- [26] Alexandrakis G, Chaudhry NA, Liggett PE et al. Spontaneous suprachoroidal hemorrhage in age-related macular degeneration presenting as angle-closure glaucoma. *Retina* 1998; 18: 485–486. doi:10.1097/00006982-199805000-00023
- [27] Shields JA, Mashayekhi A, Ra S et al. Pseudomelanomas of the posterior uveal tract: the 2006 Taylor R. Smith Lecture. *Retina* 2005; 25: 767–771. doi:10.1097/00006982-200509000-00013
- [28] Fung AT, Fulco EM, Shields CL et al. Choroidal hemorrhage simulating choroidal melanoma. *Retina* 2013; 33: 1726–1728. doi:10.1097/IAE.0b013e31828dac9d
- [29] Shields CL, Pellegrini M, Ferenczy SR et al. Enhanced depth imaging optical coherence tomography of intraocular tumors: from placid to seasick to rock and rolling topography—the 2013 Francesco Orzalesi Lecture. *Retina* 2014; 34: 1495–1512. doi:10.1097/iae.0000000000000288

## Bibliography

Klin Monatsbl Augenheilkd 2024; 241: 449–452

DOI 10.1055/a-2219-0330

ISSN 0023-2165

© 2024. The Author(s).

This is an open access article published by Thieme under the terms of the Creative Commons Attribution-NonDerivative-NonCommercial-License, permitting copying and reproduction so long as the original work is given appropriate credit. Contents may not be used for commercial purposes, or adapted, remixed, transformed or built upon. (<https://creativecommons.org/licenses/by-nc-nd/4.0/>)

Georg Thieme Verlag KG, Rüdigerstraße 14, 70469 Stuttgart, Germany

