



A Rare Atypical Case of Asymptomatic and Spontaneous Intraneural Hematoma of Sural Nerve: A Case Report and Literature Review

Shin Hyuk Kang, MD, PhD¹ Il Young Ahn, MD¹ Han Koo Kim, MD, PhD¹ Woo Ju Kim, MD, PhD²
Soo Hyun Woo, MD, PhD¹ Seung Hyun Kang, MD¹ Soon Auck Hong, MD, PhD³
Tae Hui Bae, MD, PhD²

¹Department of Plastic and Reconstructive Surgery, Chung-Ang University Hospital, Dongjak-Gu, Seoul, Republic of Korea

²Department of Plastic and Reconstructive Surgery, Chung-Ang University Gwangmyeong Hospital, Gwangmyeong-si, Gyeonggi-do, Republic of Korea

³Department of Pathology, Chung-Ang University Hospital, Dongjak-Gu, Seoul, Republic of Korea

Address for correspondence Tae Hui Bae, MD, PhD, Department of Plastic and Reconstructive Surgery, Chung-Ang University Gwangmyeong Hospital, 110, Deokan-ro, Gwangmyeong-si, Gyeonggi-do 14353, Republic of Korea (e-mail: psbth@cau.ac.kr).

Arch Plast Surg 2024;51:208–211.

Abstract

Intraneural hematoma is a rare disease that results in an impaired nerve function because of bleeding around the peripheral nerve, with only 20 cases reported. Trauma, neoplasm, and bleeding disorders are known factors for intraneural hematoma. However, here we report atypical features of asymptomatic and spontaneous intraneural hematoma which are difficult to diagnose.

A 60-year-old woman visited our clinic with the complaint of a palpable mass on the right calf. She reported no medical history or trauma to the right calf and laboratory findings showed normal coagulopathy. Ultrasonography was performed, which indicated hematoma near saphenous vein and sural nerve or neurogenic tumor. We performed surgical exploration and intraneural hematoma was confirmed on sural nerve. Meticulous paraneuriotomy and evacuation was performed without nerve injury. Histological examination revealed intraneural hematoma with a vascular wall. No neurologic symptoms were observed.

Keywords

- ▶ hematoma
- ▶ intraneural
- ▶ subparaneurial
- ▶ sural nerve
- ▶ case report

In literature review, we acknowledge that understanding anatomy of nerve, using ultrasonography as a diagnostic tool and surgical decompression is key for intraneural hematoma. Our case report may help establish the implications of diagnosis and treatment. Also, we suggested surgical treatment is necessary even in cases that do not present symptoms because neurological symptoms and associated symptoms may occur later.

Introduction

Intraneural hematoma is a rare disease that results in an impaired nerve function because of bleeding around or into

the peripheral nerve.¹ Trauma, neoplasm, bleeding disorders, and anticoagulants are known factors that contribute to hemorrhagic neuropathy. It can also be caused by interventional procedures such as fine needle aspiration or nerve

received

June 29, 2023

accepted after revision

November 24, 2023

article published online

January 24, 2024

DOI <https://doi.org/10.1055/a-2218-8461>.

10.1055/a-2218-8461.

eISSN 2234-6171.

© 2024. The Author(s).

This is an open access article published by Thieme under the terms of the Creative Commons Attribution License, permitting unrestricted use, distribution, and reproduction so long as the original work is properly cited. (<https://creativecommons.org/licenses/by/4.0/>)

Thieme Medical Publishers, Inc., 333 Seventh Avenue, 18th Floor, New York, NY 10001, USA

blocks.²⁻⁴ Most of intraneural hematoma is known to appear on median nerve, but there are few cases from lower extremity nerve. Neuropathic symptoms such as neuropathic pain, paresthesia, and weakness in the innervation area of the affected nerve are common symptoms of intraneural hematoma.^{3,5} However, it is difficult to make a diagnosis encountering a patient with atypical clinical features, especially on rare diseases. Here, we report a case of spontaneous and asymptomatic subparaneurial hematoma of the sural nerve in a healthy woman.

Case

A 60-year-old woman with a history of osteoarthritis in both knees visited the plastic and reconstructive surgery outpatient clinic with the chief complaint of a palpable mass on the right calf. About 1.5-cm round and hard mass was shown on right calf without skin lesion or distinct symptoms such as pain, paresthesia, or weakness. She reported no history of trauma or medical procedures such as nerve block or fine needle aspiration to the right calf. She had not taken any anticoagulants such as aspirin or warfarin and had no family history on vascular diseases. For preoperative evaluation, ultrasonography and laboratory examinations were performed. Ultrasonography showed a heterogenic hypoechoic mass near the saphenous vein and sural nerve indicating organized thrombus or neurogenic tumor (►Fig. 1). No abnormal results were confirmed on laboratory examination including prothrombin time, activated partial thromboplastin time, and international normalized ratio. For possibility of enlargement of mass and neurogenic symptoms, we decided to remove it surgically.

With transverse incision, meticulous dissection was performed ensuring no damage to blood vessels and nerves including saphenous vein. After careful dissection, intraneural mass with hematoma formation in sural nerve near the saphenous vein was found. We carefully performed paraneuriotomy with hematoma evacuation using microscissors to prevent damage to the nerve fascicles (►Fig. 2A-C). No active bleeding was shown. After saline irrigation, layer-by-layer closure was performed.

Histological examination confirmed an intraneural hematoma with highlighted vascular wall on Masson's trichrome staining (►Fig. 3A, B). The wound was clean and no neurologic

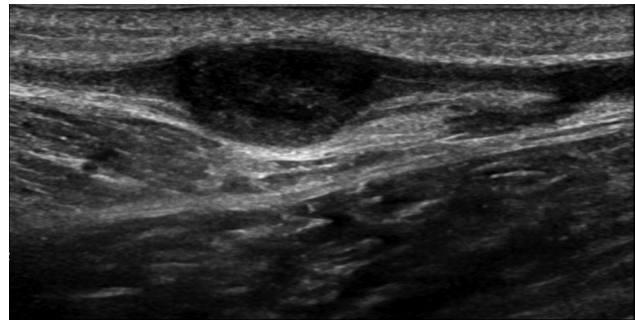


Fig. 1 Ultrasonography findings of intraneural hematoma on the right calf.

symptoms such as hypoesthesia or weakness of leg were observed.

Discussion

Intraneural hematoma is a rare disease, with only 20 reported cases in the literature.⁶ It is known that upper extremity nerve, especially median nerve is the most common site, but rarely appears in lower extremity nerve. Etiology of intraneural hematoma includes trauma from blunt injury or puncture wound, neoplasm, prolonged anti-coagulant therapy, inherited coagulopathy, or interventional procedures such as fine needle aspiration or nerve block.^{1,3,4}

The case of our patient is rare because she had not consumed any anticoagulants, did not have inherited bleeding disorders, and had no specific traumatic or surgical history. There is a report of spontaneous intraneural hematoma on sural nerve.⁷ Since course of sural nerve runs superficial area of posterior leg, there are chances of trauma that patient could not relate with hematoma. Extraneural compression of sural nerve due to direct trauma has been previously reported owing to high chance of trauma on superficial posterior leg.^{8,9} Nevertheless, cases of intraneural hematoma are extremely rare with only one case report.

Ultrasonography and magnetic resonance imaging are generally considered the standard imaging modalities for evaluating hemangiomas.¹⁰ Ultrasonography is considered the initial imaging modality of choice. On ultrasonograms, hemangiomas may have a heterogeneous appearance ranging from hypo-echoic to hyperechoic relative to the surrounding soft tissue.

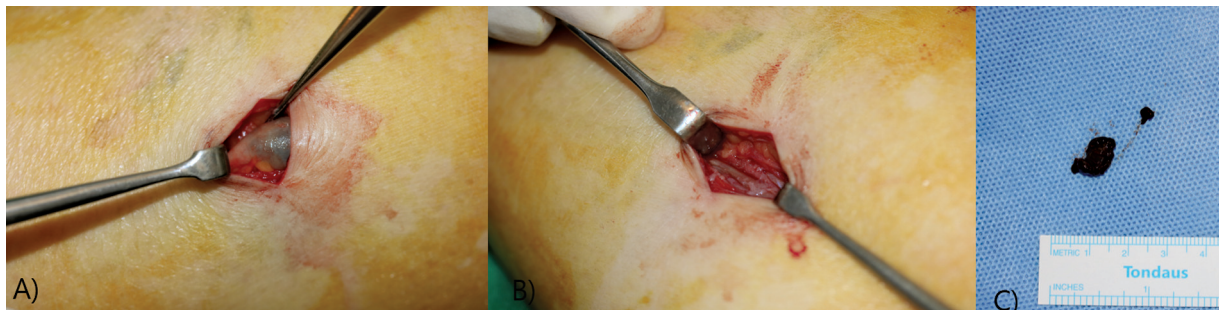


Fig. 2 (A) Preoperative findings: subparaneurial hematoma of sural nerve. (B) Postoperative findings: paraneuriotomy and hematoma evacuation is performed. (C) Excised hematoma of sural nerve.

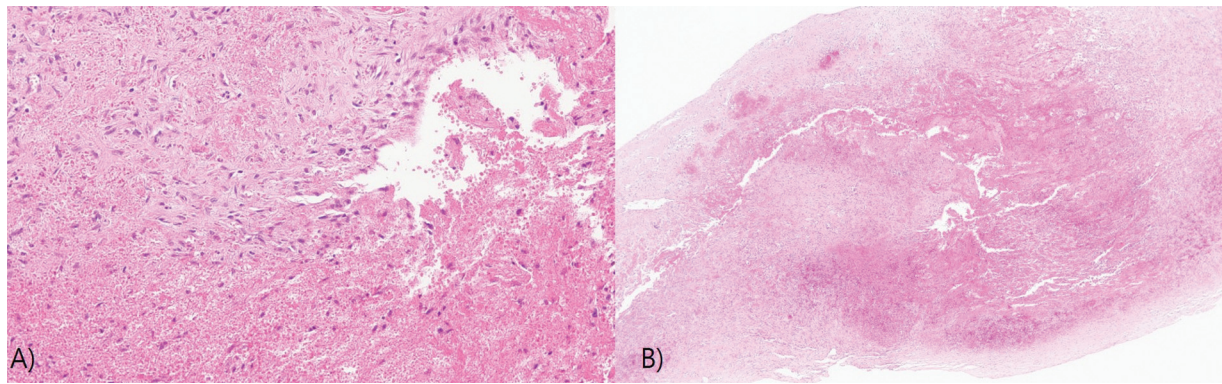


Fig. 3 (A) Pathological finding, intraneural hematoma with a vascular wall ($\times 40$). (B) Pathological findings of organized hematoma was observed in high-power view ($\times 200$).

Intraneural hemangiomas may present as intraneural and circumscribed lesions of varying echogenicity. On magnetic resonance imaging, hemangiomas may have intermediate to decreased signal intensity on T1-weighted images and generally show increased signal intensity on T2-weighted images. Heterogeneous signal intensity can be observed in case of thrombosis or hemorrhage.^{6,11} In our case, ultrasonography showed a hypoechoic mass of 1.5 cm on the right calf. Therefore, we considered it an intravenous thrombus or neurogenic hemangioma.

Contrary to other reports about intraneural hematoma, our patient did not present any symptoms such as pain, paresthesia, and numbness. Asymptomatic intraneural hematoma on lower extremity nerve has not been reported to our knowledge. This is probably because the hematoma was identified before it grew larger and compressed the nerve. Surgical treatment is necessary even in cases that do not present symptoms because neurological symptoms and associated symptoms may occur later. If patients refuse surgical treatment, they should be explained that that if repeated pressure is applied to the hematoma, it may grow larger and can press on adjacent nerves, which can cause neurogenic symptoms. Prophylactic surgical treatment might be an option since there are chances of becoming larger mass to avoid associated symptoms. Furthermore, patients need to be careful when taking medications such as anticoagulants to prevent the progression of the hematoma. Radiologic tests should be conducted regularly to monitor the size of the intraneural hematoma. If any symptoms surface, surgical treatment should be performed immediately.

A literature review was conducted to examine clinical data, the available diagnostic data, or treatment options of intraneural hematoma. de Ruyter et al⁶ reported types of intraneural hematoma based on anatomical framework of nerve. Nerve layer anatomy was classified into paraneurium, epineurium, and intrafascicular layer (perineurium and endoneurium) and type of intraneural hematoma was also classified into subparaneurial, subepineurial, intrafascicular, and multicompartmental hematoma. For deciding adequate surgical treatment of intraneural hematoma, classifying clinical patient based on anatomy is essential.

Padua et al¹² described usefulness of ultrasonography on peripheral nerve system disease. In patient with peripheral nerve disease including compression of nerve due to intra- or extraneural hematoma, up to 82% of group could confirm or modify the diagnosis and therapeutic plan by ultrasonography. Arányi et al¹³ also reported utility of ultrasonography on nerve injury by confirming intraneural neovascularization after penetrating nerve injuries. This indicates that high-resolution ultrasound can easily diagnose rare intraneural hematoma from other mass diseases. Rusu et al¹⁴ also advocate Doppler ultrasonography as a first choice of diagnostic method on peripheral intraneural vascular anomalies disease. Even though MRI is widely regarded as a diagnostic gold standard for evaluating hemangiomas,^{10,14} ultrasonography can also be a first choice of diagnosis for its usefulness of directly depicting intraneural location of abnormality and accurately differential diagnosing the anomalies of vessels. Therefore, concerning cost-effectiveness and accuracy of diagnosis, ultrasonography should be in an important role in diagnosis on intraneural hematoma or perineural vascular anomalies. However, for more accurate diagnosis, well-suited skills on ultrasonography are required on clinics by training.¹²

There are some case reports without surgical excision of intraneural hematoma. Schwab et al¹⁵ reported surgical exploration of intraneural hematoma without evacuation, due to diffuse spreading of hematoma with no relevant thickening of nerve. However, in most of intraneural hematoma, surgical evacuation was performed with good neurological outcomes.^{1,5,7} de Ruyter et al⁶ also described surgical treatment based on anatomical location of intraneural hematoma: paraneuriotomy, epineuriotomy with or without interfascicular neurolysis, or resection and reconstruction of affected nerve segment on severe case. However, owing to its rarity, comparison between surgical evacuation and conservative management cannot be made.

There are articles advocating surgical treatment through animal experiments. Rayan et al¹⁶ and Scopel et al¹⁷ reported that studies with rats have shown that intraneural hematoma-associated compression of nerve fibers causes axonal degeneration. Furthermore, surgical decompression is associated with a shorter functional recovery time. Therefore, on intraneural hematoma with compression and thickening of

specific lesion of nerve, surgical evacuation might be better option than conservative management. Also, through future study, there should be consensus on severe cases that require segmental resection of nerve.

Ethical Approval

All research protocols were performed in accordance with National Institutes of Health guidelines.

Patient Consent

Written informed consent was obtained from the patient for publication of this case presentation and any accompanying images.

Authors' Contributions

Conception and design: S.H.K., I.Y.A., T.H.B.

Acquisition of data: H.K.K., W.J.K., S.H.K.

Data analysis and interpretation: S.A.H.

Manuscript writing: All authors

Revising the content: T.H.B.

All authors have read and approved the final version of this manuscript.

Funding

None.

Conflict of Interest

None declared.

References

- Richardson RR, Hahn YS, Siqueira EB. Intraneural hematoma of the sciatic nerve. Case report. *J Neurosurg* 1978;49(02):298–300
- Dingeman RD, Mutz SB. Hemorrhagic neuropathy of the sciatic, femoral and obturator nerves: case report and review of the literature. *Clin Orthop Relat Res* 1977;(127):133–136
- Rodríguez J, Taboada M, García F, Bermúdez M, Amor M, Alvarez J. Intraneural hematoma after nerve stimulation-guided femoral block in a patient with factor XI deficiency: case report. *J Clin Anesth* 2011;23(03):234–237
- Chuang YM, Luo CB, Chou YH, Cheng YC, Chang CY, Chiou HJ. Sonographic diagnosis and treatment of a median nerve epineurial hematoma caused by brachial artery catheterization. *J Ultrasound Med* 2002;21(06):705–708
- Kokkinakis M, Hinsche A, Rajeev A. Spontaneous intraneural haematoma causing acute neuropathy of the median nerve. *J Hand Surg Eur Vol* 2009;34(02):280–281
- de Ruiter GC, Prasad NK, Spinner RJ, Maniker AH. Intraneural hematoma: a proposed anatomic classification with potential treatment implications. *World Neurosurg* 2015;84(06):1977–1984
- Richardson SS, McLawhorn AS, Mintz DN, DiCarlo EF, Weiland AJ. Spontaneous intraneural hematoma of the sural nerve. *Skeletal Radiol* 2015;44(04):605–608
- Bryan BM III, Lutz GE, O'Brien SJ. Sural nerve entrapment after injury to the gastrocnemius: a case report. *Arch Phys Med Rehabil* 1999;80(05):604–606
- Babwah T. Sural nerve injury in a footballer related to blunt leg trauma. *Res Sports Med* 2012;20(01):70–73
- Daoud A, Olivieri B, Feinberg D, Betancourt M, Bockelman B. Soft tissue hemangioma with osseous extension: a case report and review of the literature. *Skeletal Radiol* 2015;44(04):597–603
- Song HB, Lee YH, Kang UR, Lee SM, Chae SB. Ultrasound and MRI findings of intraneural capillary hemangioma of the median nerve mimicking traumatic neuroma: a case report. *J Korean Soc Radiol* 2018;78(02):115–119
- Padua L, Liotta G, Di Pasquale A, et al. Contribution of ultrasound in the assessment of nerve diseases. *Eur J Neurol* 2012;19(01):47–54
- Arányi Z, Csillik A, Dévay K, Rosero M. Ultrasonographic demonstration of intraneural neovascularization after penetrating nerve injury. *Muscle Nerve* 2018;57(06):994–999
- Rusu GM, Ciuce C, Fodor L, Manole S, Dudea SM. Ultrasonographic and imaging appearance of peripheral intraneural vascular anomalies: report of two cases and review of the literature. *Med Ultrason* 2018;20(02):237–246
- Schwab S, Kabbasch C, Grau SJ. Spontaneous intraneural hematoma of the common fibular nerve due to oral anticoagulation. *J Surg Case Rep* 2020;2020(08):rjaa207
- Rayan GM, Pitha JV, Wisdom P, Brentlinger A, Kopta JA. Histologic and electrophysiologic changes following subepineurial hematoma induction in rat sciatic nerve. *Clin Orthop Relat Res* 1988;(229):257–264
- Scopel GP, Marques Faria JC, Orpheu SC, Alves HR, Dellon AL, Ferreira MC. Intraneural hematoma with extrinsic compression: experimental study in rats and therapeutic options. *J Reconstr Microsurg* 2007;23(05):275–281