

Current Evidence on Local Therapies in Advanced Adrenocortical Carcinoma



Authors

Otilia Kimpel¹, Ulrich Dischinger¹, Barbara Altieri¹, Carmina Teresa Fuss¹, Bülent Polat², Ralph Kickuth³, Matthias Kroiss^{1, 4}, Martin Fassnacht^{1, 5}

Affiliations

- 1 Division of Endocrinology and Diabetes, Department of Medicine, University Hospital, University of Würzburg, Würzburg, Germany
- 2 Department of Radiation Oncology, University Hospital, University of Würzburg, Würzburg, Germany
- 3 Institute of Diagnostic and Interventional Radiology, University Hospital, University of Würzburg, Würzburg, Germany
- 4 Department of Internal Medicine IV, University Hospital, Ludwig-Maximilians-Universität München, München, Germany
- 5 Comprehensive Cancer Center Mainfranken, University of Würzburg, Würzburg, Germany

Key words

adrenal cancer, advanced disease, local therapies

received 19.06.2023

accepted after revision 25.09.2023

Bibliography

Horm Metab Res 2024; 56: 91–98

DOI 10.1055/a-2209-6022

ISSN 0018-5043

© 2024. The Author(s).

This is an open access article published by Thieme under the terms of the Creative Commons Attribution-NonDerivative-NonCommercial-License, permitting copying and reproduction so long as the original work is given appropriate credit. Contents may not be used for commercial purposes, or adapted, remixed, transformed or built upon. (<https://creativecommons.org/licenses/by-nc-nd/4.0/>)

Georg Thieme Verlag KG, Rüdigerstraße 14,
70469 Stuttgart, Germany

Correspondence

Dr. Otilia Kimpel

Division of Endocrinology and Diabetes, Department of Medicine, University Hospital, University of Würzburg
Oberdürrbacher Str. 6
97080 Würzburg
Germany
Tel.: 0931 201 39885
Kimpel_o@ukw.de

ABSTRACT

International guidelines emphasise the role of local therapies (LT) for the treatment of advanced adrenocortical carcinoma (ACC). However, large studies are lacking in this field. Therefore, we performed a review of the literature to synthesise current evidence and develop clinical guidance. PubMed database was searched for systematic literature. We identified 119 potentially relevant articles, of which 21 could be included in our final analysis. All were retrospective and reported on 374 patients treated with LT for advanced ACC (12 studies on radiotherapy, 3 on transarterial chemoembolisation and radioembolisation, 4 on image-guided thermal ablation [radiofrequency, microwave ablation, and cryoablation, and two studies reporting treatment with several different LT]). Radiotherapy was frequently performed with palliative intention. However, in most patients, disease control and with higher dosage also partial responses could be achieved. Data for other LT were more limited, but also point towards local disease control in a significant percentage of patients. Very few studies tried to identify factors that are predictive on response. Patients with a disease-free interval after primary surgery of more than 9 months and lesions < 5 cm might benefit most. Underreporting of toxicities may be prevalent, but LT appear to be relatively safe overall. Available evidence on LT for ACC is limited. LT appears to be safe and effective in cases with limited disease and should be considered depending on local expertise in a multidisciplinary team discussion.

Introduction

Adrenocortical carcinoma (ACC) is a rare malignant endocrine tumour with poor prognosis. Tumour stage, resection status and the proliferation index Ki67 are the most relevant prognostic factors, which are combined in the S-GRAS score together with age, symptoms at diagnosis in patients undergoing primary tumour resection [1]. The 5-year overall survival ranges from about 80% in patients with ACC stage I to less than 20% in stage IV disease [2–9]. However, even in stage IV some patients survive many years and cases with curable complete treatment responses have been reported [1, 10, 11].

International reviews and society guidelines recommend mitotane alone or in combination with platinum-based chemotherapy as first-line treatment for recurrent or metastatic disease not amenable to complete resection [2, 9, 12–15]. Surgery of metastases is usually the preferred option only if all tumoural lesions can be removed and the time interval to previous surgery is above 12 months [2, 16]. Despite limited evidence, local therapies (LT) should be considered in advanced ACC according to current recommendations [2, 9]. In these guidelines, the panellists agreed that local therapeutic measures [radiotherapy (RT), transarterial chemoembolisation (TACE), radiofrequency ablation (RFA), microwave ablation (MWA), and cryoablation (CA)] are relevant and suggested an individualised decision on which method to choose based on the localisation of the tumour lesion(s), local expertise, prognostic factors and patient's preference [2, 9]. LT may also be indicated for pain, prevention of imminent metastatic complications, severe mass effect or neurological symptoms. The aim of this review is to summarise data regarding the value of LT as alternative therapeutic option beside treatment with chemotherapy and/or surgery for advanced ACC.

Materials and Methods

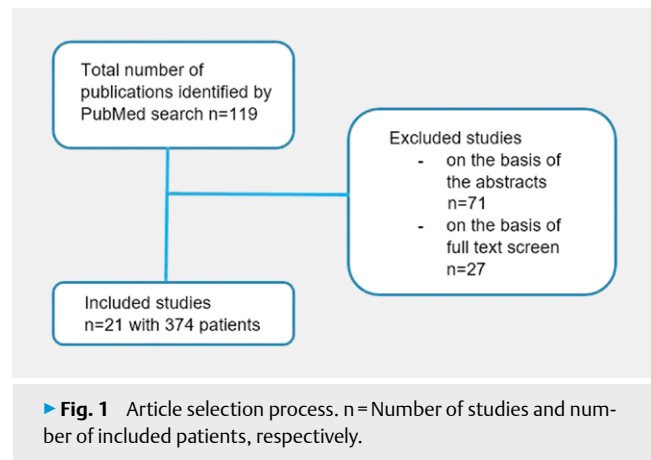
We searched the PubMed database (<https://pubmed.ncbi.nlm.nih.gov>) for manuscripts published until May 2023. Search terms included: adrenocortical tumour, adrenocortical cancer/carcinoma, advanced disease, treatment, local therapies, radiotherapy, transarterial chemoembolisation, transarterial radioembolisation, radiofrequency ablation, microwave ablation, cryoablation using “and” or “or”.

All abstracts were screened by O.K. and those reporting treatment with LT in advanced ACC were reviewed. Overall, we identified 119 potentially relevant manuscripts. Duplicates and articles not relevant to this review (case reports, articles investigating adjuvant therapy, reviews and guidelines) were excluded (► Fig. 1). Finally, data from 21 different full articles could be included in our analysis. In total, the analysed studies reported 374 patients with advanced ACC treated with one or more LT.

Local therapies in advanced adrenocortical carcinoma

Radiotherapy

Radiotherapy is an important modality used as curative or palliative treatment in many different cancer types [17, 18]. The technology developed in the past years leading to a more accurate and faster therapy with less adverse effects and improved treatment



► Fig. 1 Article selection process. n = Number of studies and number of included patients, respectively.

response. An emerging field in radiation oncology is the locally ablative treatment of all lesions in the so called oligo-metastatic disease stage leading to improved survival in randomised trials [19]. In ACC, the evidence is much lower. Radiotherapy is recommended as adjuvant therapy in patients with a high risk for local recurrence (e. g., after R1 resection) [2, 9]. Several studies suggested its efficacy in reducing the risk of local recurrence [12, 20–24], but data on improving recurrence-free and overall survival are conflicting. Furthermore, the current guidelines recommend RT as treatment option alone or in combination with mitotane and/or chemotherapy in advanced ACC [2, 9]. However, evidence for treatment in advanced ACC is scarce.

Our literature search identified 13 studies reporting 200 patients with advanced ACC treated with RT (► Table 1). All studies were retrospective analyses. In 9 studies the primary endpoint was palliation (e. g., pain), but 2 studies including 83 patients focused primarily on tumour control. In nine studies, RT was done as treatment of an irresectable or not completely resectable tumour, as pain therapy, or for the prevention of metastatic complications.

The exact localisation of RT treated lesions was not described in all studies. Most lesions were localised in bones, lung, liver, lymph nodes or an abdominal tumour mass (see ► Table 1).

Reported doses of RT ranged from 10 to 60 Gray (Gy) (median 40 Gy). Only two studies reported the number of fractions and the type of RT. Ho et al. described a median of 15 fractions (5–31) [25]. In a previous study from our group, we reported four types of RT: conventional RT with a lower dosage (20–40 Gy) and a median of 12 fractions (1–28) with 3 Gy as median dose per fraction (1.2–8), conventional RT with a higher dosage (50–60 Gy) and a median of 27 fractions (15–30) with 2.1 Gy as median dose per fraction (1.8–4), a third group with stereotactic body radiotherapy with a median of 3.5 fractions (1–10) and 12.5 Gy as median dose per fraction (4–26) and a fourth group treated with single-dose brachytherapy with a median of 15 Gy (15–20) [26].

Median follow up time of all studies was 14 months ranging from 0.5 to 164 months. The results of these studies are very heterogeneous. The reasons for this are very multifaceted. The main problems are the heterogeneity of the patient groups, the site of the treated lesion and the very variable radiation doses, but above all also the different definitions of the endpoints investigated. Further-

► **Table 1** Published studies on treatment with RT in advanced ACC.

Authors [Ref]	Time frame	Patients n	Localisation of treated lesion	RT dose (Gy)	Reported endpoints	Response
Percarpio & Knowlton [30]	1952–1975	7	Bone, lymph node, LR, DR	15–51	Pain, intestinal obstruction	7/7
King & Lack [31]	1956–1977	12	Bone, bulky flank tumour	NG	Pain	6/12
Henley et al. [32]	1960–1980	10	Irresectable tumour	NG	Pain, tumour burden	4/10
Nader et al. [33] ¹	1944–1982	10	Abdominal recurrence	NG	Tumour control and overall survival	2/10
Venkatesh et al. [34] ¹	1944–1987	19	Abdominal recurrence	NG	Tumour control and overall survival	3/19
Magee et al. [35]	1968–1981	1	Cervical lymph node	NG	Palliation	1/1
Markoe et al. [36]	1962–1991	5	Irresectable tumour or DR, bone, lymph node	30–50	Pain	5/5
Pommier & Brennan [10]	1980–1991	5	Bone	NG	pain	5/5
Polat et al. [37]	1986–2008	26	Bone, LR, abdominal recurrence, lung	10–60	Pain (n = 22) Control of CNS symptoms (n = 6)	7/22 3/6
Hermesen et al. [29]	1990–2008	10	Bone, DR	NG	Pain (n = 6) Palliation (n = 4)	6/6 2/4
Ho et al. [25]	1997–2012	12 with 18 courses of RT	LR or DR	17.5–60	Pain, prevention of metastatic complications	12/18
Roux et al. [27]	2008–2021	3	LR or DR	NG	Tumour control	3/3
Kimpel et al. [26] ²	2000–2022	80	n = 132 LR n = 22 or DR (bone n = 46, lung n = 32, liver n = 16, lymph node n = 3, soft tissue n = 9, brain n = 4)	12–60	Tumour control, overall survival	CR n = 6 PR n = 52 SD n = 60 PD n = 14

RT: Radiotherapy; n: Number; Gy: Gray; CR: Complete response; PR: Partial response; SD: Stable disease; PD: Progressive disease; LR: Local recurrence; DR: Distant recurrence; CNS: Central nervous system; NG: not given.¹ Most likely there is an overlap of patients between the studies of Nader et al. [33] and Venkatesh et al. [34]. ² One patient has also been reported by Polat et al. [37].

more, response to therapy was not uniformly defined. These points are probably also the reason why there are studies that reported a response rate of 100%, while others found only about 20% response. Our own study, which included cases from 2000 to 2022, is by far the largest study and here, among 132 irradiated tumour lesions, only 14 (11%) showed progression, while all other lesions showed at least stable disease or objective tumour response in 89%. In the subgroup of patients with conventional RT with a higher dosage (50–60 Gy) or with stereotactic body radiotherapy the objective response rate was even 95 and 100%, respectively.

Toxicities due to RT were described only in three studies [25–27]. Ho et al. observed toxicities in 6 of 12 patients: three grade 1, three grade 2 and one grade 3 adverse events [25] according to the toxicity criteria of the Radiation Therapy Oncology Group (RTOG) [28]. In our study with 80 patients, we reported 43 grade 1 adverse events including fatigue, anaemia, skin, hepatic, renal, intestinal, and pulmonary toxicities. In addition, we observed 13 grade 2 adverse events with fatigue, musculoskeletal disorders, skin, pulmonary, and intestinal toxicities, and three grade 3 adverse events (with pulmonary and intestinal toxicities) (26). Both of these studies reported no grade 4 or 5 adverse events. Roux et al. reported four grade 3 adverse events and also three grade 4 adverse events

in different LT. However, they did not provide information, which type of LT lead to these adverse events [27].

Some studies reported concomitant therapies with mitotane during RT [25–27, 29]. We reported 38 (29%) patients with a mitotane therapy and a mitotane level > 14 mg/l during RT. However, mitotane treatment had no significant influence on RT treatment response [26]. Roux et al. also included patients with mitotane treatment during RT. More than half of the patients achieved a therapeutic level > 14 mg/l. However, analysing a potential effect of mitotane was not part of the study [27]. Hermesen et al. reported two patients treated with mitotane, but only one patient reached a therapeutic level [29]. Ho et al. reported seven patients receiving concomitant chemotherapy, including mitotane (n = 4). No further information on chemotherapy or mitotane was available [25].

Only few studies investigated possible predictive factors influencing response to RT. We identified the absence of glucocorticoid excess and a Ki67 ≤ 15% as possible predictive factors [26]. Roux et al. could show that a maximum of five metastases or a maximum diameter below 3 cm were associated with higher rates of disease control [27]. No more predictive factors could be identified.

► **Table 2** Published studies on treatment with TACE or TARE of liver metastases in advanced ACC.

Authors [Ref]	Time frame	Patients n	Lesions n	Reported endpoints	Response
Soga et al. [43] ¹	1995–2006	2	2	Tumour control	CR = 2
Cazejust et al. [40]	1995–2005	29	103	Tumour control	PR = 23 SD = 67 PD = 13
Owen et al. [42]	1997–2016	Treatment with TACE n = 2 Treatment with TARE n = 3	NG	Tumour control	Presumably prolonged survival
Roux et al. [27]	2008–2021	20	20	Tumour control	Disease control rate 17/20
Mauda-Havakuk et al. [41] ²	1999–2018	12		Tumour control	No details given

n: Number; CR: Complete response; PR: Partial response; SD: Stable disease; PD: Progressive disease; NG: Not given; TACE: Transarterial chemoembolisation; TARE: Transarterial radioembolisation. ¹Patients were treated with transarterial embolisation (TAE). ²Twelve patients were treated with 35 transarterial embolisation sessions including 5 sessions with TAE and 30 sessions with chemotherapy.

Transarterial chemoembolisation (TACE) and transarterial radioembolisation (TARE)

Transarterial chemoembolisation is the most commonly used transarterial therapy in oncology: Briefly, a mixture of iodised oil and cytotoxic agent (conventional TACE), drug-eluting beads and cytotoxic agent (DEB-TACE) or degradable starch microspheres and cytotoxic agent (DSM-TACE) is administered intraarterially supplying the tumour to be targeted to avoid wash-out of the chemotherapeutic agent, potentiating local effectivity. Due to the limited systemic effect, the delivery of higher doses than in the context of systemic application is possible. In hepatocellular carcinoma (HCC), this treatment strategy has been proven to be beneficial, which has been shown also in randomised, controlled trials [38]. As a consequence, TACE is extensively used in HCC, as part of a curative approach, in a palliative setting, or as a possible bridge to transplantation. With an overall mortality rate of < 1 %, TACE is a very safe treatment option in HCC [39].

Data on TACE as treatment for patients with advanced ACC are very limited. Until now, there are only five studies (► **Table 2**), all reporting TACE of liver metastases. All studies are retrospective analyses. All reported patients presented with advanced disease and were treated with systemic chemotherapy concomitantly (mostly mitotane alone or in combination with etoposide, doxorubicin and platinum (EDP-M)). As an additional confounder, most studies summarise different methods in one report (e. g., cryotherapy, radiofrequency ablation, selective internal radiation therapy). For most of the reported patients, no further information on specifics of the performed TACE is available, in some cases even the information regarding the used cytotoxic drug is missing.

Until now, the largest number of patients (n = 29) treated with TACE in advanced ACC was reported by Cazejust et al. in 2010. In this series a decrease in tumour size in 22 % of 103 treated lesions was observed, an additional 65 % of lesions were stable in size after 3 months. In this study, higher response rates were observed in lesions with a diameter < 3 cm [40]. Roux et al. reported a significantly longer time to second line treatments in 60 patients following loco-regional treatment (n = 20 treated with TACE) and a signifi-

cantly higher rate of disease control in a subgroup of cases (< = 5 metastases or maximum diameter < 3 cm) (27). Mauda-Havakuk et al. stated a possible prolonged life expectancy in patients (n = 39) after loco-regional treatment (TACE: n = 12) [41].

None of the studies reported any high-grade adverse events, which is in line with the data of TACE in HCC.

The use of transarterial radioembolisation (TARE) in patients with ACC and liver metastases is still under debate and restricted to case reports or smaller case series. Owen et al. reported three patients with ACC and liver metastases treated with TARE showing a longer overall survival in comparison to patients without TARE (32.4 months vs. 9.9 months, p = 0.011) [42].

Image-guided thermal ablation: Radiofrequency ablation, microwave ablation and cryoablation

Radiofrequency ablation, microwave ablation and cryoablation are minimally invasive percutaneous thermal ablation therapies which are usually single examination procedures and may provide control of local disease in patients who cannot undergo surgery or refuse surgical treatment. RFA is a percutaneous treatment which generates heat locally that leads to coagulation of the surrounding tissue. The needle and electrode are usually placed under guidance by computer tomography or ultrasound. Like RFA, MWA makes also use of electromagnetic energy causing rotation of water molecules and generates heat around the tip of the antenna causing denaturation of proteins and cell membranes of tumour cells. Cryoablation is a minimally invasive percutaneous technique to target tumour tissue and freeze it by extremely low temperatures resulting in cytotoxic effects and destruction of intracellular contents. It is used for treating various solid tumours and showing a good tumour control [44].

To date, few studies presented data about these interventional treatment options in advanced ACC. All published studies together (n = 6) covered 102 patients with ACC treated with at least one or more image-guided thermal ablation therapy (► **Table 3**).

All studies were retrospective analyses. All patients had an advanced disease and intention to treat was palliative for local tumour control.

RFA was the most frequently used LT (n = 86), 24 lesions were treated with MWA and 10 lesions with CA. The localisation of the treated lesion was described in nearly all studies: liver n = 84, pulmonary n = 18, tumour bed n = 6, bone = 4; retroperitoneum n = 5, subcutaneous n = 2, intracaval = 1, respectively. Only few studies reported technical details on LT (see ► **Table 3**).

Median follow up time was 26.5 months ranging from 5 to 164 months. Most of the patients showed a complete ablation after the treatment (see ► **Table 3**).

Until now, the largest number of patients with advanced ACC treated with a thermal ablation therapy was reported by Mauda-Havakuk et al. in 2020 and Roux et al. in 2022. Mauda-Havakuk et al. reported 39 patients treated with RFA, MWA, CA or a combination of LT. Complete ablation of the treated metastases was achieved in 61 % [41]. Roux et al. showed a similar response rate after treatment with a thermal ablation therapy. Nineteen out of 30 (63 %) patients showed a disease control after therapy [27].

Toxicities due to thermal ablation therapies were rarely reported but might not be sufficiently well documented. Roux et al. re-

ported four grade 3 adverse events consisting of two post-procedure bleedings with spontaneous haemostasis, one gastrointestinal fistula and one mild pancreatitis and also three grade 4 adverse events with two post-procedural adrenal insufficiencies and one pleural haemorrhage. However, they did not distinguish between the different LT [27]. Mauda-Havakuk et al. described two patients with greater than or equal grade 3 complications. One RFA session was complicated by an intrahepatic hematoma. Another patient developed transient atrial fibrillation and electrolyte imbalance. Three patients suffered grade 2 complications. One patient developed an abscess after paraspinal ablation, and two patients developed pneumothoraces [41]. Wood et al. had one patient with a multimicrobial abscess in a 90 mm lesion 11 weeks after his third RFA treatment session [45]. Veltri et al. observed a single major adverse event with an intrahepatic hematoma with subsequent haemothorax [46].

Here again, only some studies investigated possible factors influencing LT. Li et al. showed that microwave ablation can be suitable for different adrenal tumours, especially those smaller than

► **Table 3** Published studies with the use of thermal ablation therapies in advanced ACC.

Authors [Ref]	Time frame	Patients n	Localisation and number of lesions	Lesion size (cm)	Type of local therapy	Technical details	Reported endpoints	Response
Wood et al. [45]	1999–2001	8	LR = 5 DR = 10	Median 4.3 (1.5–9)	RFA n = 15	Ultrasound and/or CT scan guidance 200 Wt, 480 kHz alternating current radiofrequency generator	Tumour control	3/15 (20%) PD 4/15 (27%) SD 8/15 (53%) decreased in size
Ripley et al. [48]	1979–2009	8	Liver n = 8	NG	RFA n = 8	NG	Tumour control	8-Jul
Li et al. [47]	2007–2010	1	LR = 1	6.1 × 3.8	MWA n = 1	70 Wt, 15 Min	Tumour control	Necrotic tumour
Veltri et al. [46]	2000–2017	16	Liver n = 28 Lung n = 4	Median 2.1 (0.6–7.5)	RFA MWA	US guidance for hepatic lesions CT guidance for lung lesions	Tumour control	Complete ablation 29/32
Mauda-Havakuk et al. [41]	1999–2018	39	Liver n = 46 Lung n = 14 Retroperitoneum n = 5 Bone n = 4 Subcutaneous n = 2 Intracaval n = 1	NG	RFA n = 45 MWA n = 18 CA n = 3 Combined n = 3	NG	Tumour control	Complete ablation in 52/84
Roux et al. [27]	2008–2021	30	N = 30 LR or DR	46 lesions with max diameter 3 cm	RFA n = 18 CA n = 7 MWA n = 5	NG	Tumour control	Disease control rate 19/30

n: Number; Wt: Watt, kHz: Kilohertz; Min: Minute; cm: Centimetre; max: Maximum; NG: Not given; LR: Local recurrence; DR: Distant recurrence; US: Ultrasound; CT: Computer tomography; RFA: radiofrequency ablation; MWA: Microwave ablation; CA: Cryoablation.

5 cm in diameter [47]. Roux et al. showed that a maximum of five metastases or a maximum diameter below 3 cm were associated with higher rates of disease control [27]. Mauda-Havakuk et al. reported female gender and longer time from diagnosis to first thermal ablation as potential predictors of prolonged survival [41]. Veltri et al. also described size of metastases as predictive factor. Local tumour progress was significantly higher in larger metastases (20 mm vs. 34.5 mm; $p = 0.009$) [46]. Ripley et al. indicated that disease-free interval greater than 9 months after primary adrenalectomy was associated with longer survival (4.1 vs. 0.9 years; $p = 0.013$) [48]. Wood et al. showed that RFA is most effective for tumours less than 5 cm [45].

Discussion

Despite the recommendation in the two international guidelines [2, 9], it must be noted that the evidence on the effectiveness of local therapies in advanced ACC remains very limited. However, five studies with a total of 202 patients and 305 treated lesions, have been published in the last 5 years, leading to at least some improvement in data quality. In total, this allowed us to evaluate data from 374 patients. Prospective or even randomised studies were still completely missing, which prevented reliable recommendations. Overall, there are only a few studies that reported clearly negative results, although, a selection bias cannot be ruled out here. However, from our point of view there are obvious explanations for these studies with disappointing results (e. g., outdated therapy, extremely advanced disease), we would actually attribute a certain effectiveness to all reported LT. Although toxicity appears to be limited and most reported adverse events were mild or moderate, it must be acknowledged that retrospective studies tend to underestimate negative effects. However, in this context results from other tumour entities can be extrapolated and these data suggest indeed acceptable toxicity for most local treatment modalities [18, 49, 50].

Treatment with RT was mostly (especially in the older publications) used for palliative intention such as pain control and, therefore, these studies did not report objective responses [25, 29, 36]. However, the more recent studies reported also on tumour response [26, 27] and here tumour control was achieved in the vast majority of patients. As described above, toxicity data have to be judged with cautious, but in all studies that report adverse events these were manageable. Thus, we conclude that RT seems to be mostly well-tolerated and effective in the management of metastatic ACC, controlling local symptoms, and preventing complications from large metastases. More recent data clearly suggest that higher radiation dosages (e. g., > 50 Gy) or stereotactic body radiotherapy might – not surprisingly – be more effective in achieving objective tumour response [26].

TACE and TARE are two commonly used loco-regional therapies in several cancer types which aim to prolong survival by slowing tumour progression, or to bridge to more definitive therapies [51, 52]. TACE is extensively used in HCC, as part of a curative approach, in a palliative setting, or as a possible bridge to transplantation. With an overall mortality rate of < 1 %, TACE is a very safe treatment option in HCC [39]. TACE also might be valuable in ACC patients with a small number of only hepatic metastases of limited

sizes, if surgical treatment is not possible. Although there are only few studies investigating treatment with TACE in advanced ACC, most of the reported studies showed a decrease in tumour size or achieved a disease control [27, 40]. In addition, TACE appeared to be a safe treatment option with few adverse events. With limited data available, the use of TACE remains a case-by-case decision to be made by an interdisciplinary tumour board.

Evidence for TARE in ACC is even more limited. Until now there are only some case reports and a case series of 3 patients treated with TARE in advanced ACC with liver metastases. However, this treatment was effective in most cases similar to TACE [42].

Similar to RT and TACE image-guided thermal ablation therapies are of use as curative and palliative cancer treatment.

RFA is an established therapeutic option in patients with lung cancer or metastatic lesions achieving good tumour control [42]. A meta-analysis comparing treatment with RFA versus surgery in non-small cell lung cancer showed similar results regarding overall survival [43].

Although RFA and MWA resemble, MWA showed advantages in larger tumours, in locations close to large vessels and in highly perfused areas [53].

CA is used for treating various solid tumours and showing a good tumour control. Some studies in other tumour entities showed superior tumour response and quicker recovery compared to heat-based ablation therapies [44]. Image-guided thermal ablation therapies also might have an important role in palliative treatment of ACC.

These minimally invasive therapies achieve adequate local tumour control of ACC metastases, providing a safe and effective treatment option in the multidisciplinary management of ACC [27, 41, 46]. Mauda-Havakuk et al. propose a combined use of LT, surgery and chemotherapy in advanced disease. Patients treated with a combination of therapies showed a longer 2 year- and 5 year-survival in comparison to patients with surgery and chemotherapy or chemotherapy and RT [41].

Overall, the summarised studies suggest that most LT are effective for palliative treatment, for example, for pain relief, but also for tumour control. Therefore, we are convinced that LT should be considered more frequently as a treatment option alone or in combination with chemotherapy and/or surgery in advanced disease, and not only in palliative care. Despite the limited number of studies, we believe that especially patients with oligo-metastatic ACC might benefit particularly from LT (either to defer the application of cytotoxic therapy or to provide treatment options when standard systemic therapies have failed).

The most critical part in applying LT to patients with ACC is probably the selection of the most adequate method to the “right” patient. For some localisations certain methods seem to be more suitable than others (e. g., RT for bone or cerebral metastases) and for some modalities the cumulative experience in certain organs is much higher than in other parts of the body (e. g., TACE for liver lesions). However, at the end the indication for any given LT depends heavily also on local experience and expertise. Furthermore, not only the combination of different LT, but also treatment with systemic therapies might be reasonable in selected patients. Thus, the most important issue seems to be that all patients are discussed in

multidisciplinary team meetings as already strongly recommended by the 2018 guidelines [9].

Finally, we would like to call for multi-institutional efforts to start prospective studies on LT in a rare disease like ACC. International networks like ENSAT or A5 are best suited to coordinate such studies. These studies will also help to find factors that predict response to a given therapy or to identify constellation for which certain therapies are not suitable. In conclusion, LT are probably still under-used in ACC and treating physicians are encouraged to consider the different described modalities more frequently.

Funding Information

Clinician Scientist programme RISE funded by the Else Kröner-Fresenius-Stiftung & the Eva Luise und Horst Köhler Stiftung – German Research Foundation (DFG) project 314061271 (TRR-CRC 205) – project 314061271 (TRR-CRC 205)

Conflict of Interest

MF has served in an advisory board of HRA Pharma on the management of adrenocortical carcinoma. Remunerations paid to his university hospital. MK has received consultancy and speaker honoraria from HRA Pharma and Recordati, and research support from Ipsen, and Enterome (to institution). OK received speaker honoraria from HRA Pharma. UD, BA, CTF, BP, RK declare that they have no known competing financial interests or personal relationships that could have appeared to influence the work reported in this paper.

References

- [1] Elhassan YS, Altieri B, Berhane S et al. S-GRAS score for prognostic classification of adrenocortical carcinoma: an international, multicenter ENSAT study. *Eur J Endocrinol* 2021; 186: 25–36
- [2] Fassnacht M, Assie G, Baudin E et al. Adrenocortical carcinomas and malignant pheochromocytomas: ESMO-EURACAN Clinical Practice Guidelines for diagnosis, treatment and follow-up. *Ann Oncol* 2020; 31: 1476–1490
- [3] Megerle F, Kroiss M, Hahner S et al. Advanced adrenocortical carcinoma - what to do when first-line therapy fails? *Exp Clin Endocrinol Diabetes* 2019; 127: 109–116
- [4] Vaidya A, Nehs M, Kilbridge K. Treatment of adrenocortical carcinoma. *Surg Pathol Clin* 2019; 12: 997–1006
- [5] Berruti A, Fassnacht M, Haak H et al. Prognostic role of overt hypercortisolism in completely operated patients with adrenocortical cancer. *Eur Urol* 2014; 65: 832–838
- [6] Baudin E. Adrenocortical carcinoma. *Endocrinol Metab Clin North Am* 2015; 44: 411–434
- [7] Datta J, Roses RE. Surgical management of adrenocortical carcinoma: an evidence-based approach. *Surg Oncol Clin N Am* 2016; 25: 153–170
- [8] Fassnacht M, Johanssen S, Quinkler M et al. Limited prognostic value of the 2004 International Union Against Cancer staging classification for adrenocortical carcinoma: proposal for a Revised TNM Classification. *Cancer* 2009; 115: 243–250
- [9] Fassnacht M, Dekkers OM, Else T et al. European Society of Endocrinology Clinical Practice Guidelines on the management of adrenocortical carcinoma in adults, in collaboration with the European Network for the Study of Adrenal Tumors. *Eur J Endocrinol* 2018; 179: G1–G46
- [10] Pommier RF, Brennan MF. An eleven-year experience with adrenocortical carcinoma. *Surgery* 1992; 112: 963–970. discussion 70–71
- [11] Schulick RD, Brennan MF. Long-term survival after complete resection and repeat resection in patients with adrenocortical carcinoma. *Ann Surg Oncol* 1999; 6: 719–726
- [12] Fassnacht M, Hahner S, Polat B et al. Efficacy of adjuvant radiotherapy of the tumor bed on local recurrence of adrenocortical carcinoma. *J Clin Endocrinol Metab* 2006; 91: 4501–4504
- [13] Else T, Williams AR, Sabolch A et al. Adjuvant therapies and patient and tumor characteristics associated with survival of adult patients with adrenocortical carcinoma. *J Clin Endocrinol Metab* 2014; 99: 455–461
- [14] Kiseljak-Vassiliades K, Bancos I, Hamrahian A et al. American Association of Clinical Endocrinology Disease State Clinical Review on the evaluation and management of adrenocortical carcinoma in an adult: a practical approach. *Endocr Pract* 2020; 26: 1366–1383
- [15] Altieri B, Ronchi CL, Kroiss M et al. Next-generation therapies for adrenocortical carcinoma. *Best Pract Res Clin Endocrinol Metab* 2020; 34: 101434
- [16] Erdogan I, Deutschbein T, Jurowich C et al. The role of surgery in the management of recurrent adrenocortical carcinoma. *J Clin Endocrinol Metab* 2013; 98: 181–191
- [17] Vinod SK, Hau E. Radiotherapy treatment for lung cancer: current status and future directions. *Respirology* 2020; 25: 61–71
- [18] Gómez-Aparicio MA, Valero J, Caballero B et al. Extreme hypofractionation with SBRT in localized prostate cancer. *Curr Oncol* 2021; 28: 2933–2949
- [19] Liu W, Bahig H, Palma DA. Oligometastases: emerging evidence. *J Clin Oncol* 2022; 40: 4250–4260
- [20] Sabolch A, Feng M, Griffith K et al. Adjuvant and definitive radiotherapy for adrenocortical carcinoma. *Int J Radiat Oncol Biol Phys* 2011; 80: 1477–1484
- [21] Gharzai LA, Green MD, Griffith KA et al. Adjuvant radiation improves recurrence-free survival and overall survival in adrenocortical carcinoma. *J Clin Endocrinol Metab* 2019; 104: 3743–3750
- [22] Wu K, Liu X, Liu Z et al. Benefit of postoperative radiotherapy for patients with nonmetastatic adrenocortical carcinoma: a population-based analysis. *J Natl Compr Canc Netw* 2021; 19: 1425–1432
- [23] Habra MA, Ejaz S, Feng L et al. A retrospective cohort analysis of the efficacy of adjuvant radiotherapy after primary surgical resection in patients with adrenocortical carcinoma. *J Clin Endocrinol Metab* 2013; 98: 192–197
- [24] Srougi V, de Bessa J Jr., Tanno FY et al. Adjuvant radiotherapy for the primary treatment of adrenocortical carcinoma: are we offering the best? *Int Braz J Urol* 2017; 43: 841–848
- [25] Ho J, Turkbey B, Edgerly M et al. Role of radiotherapy in adrenocortical carcinoma. *Cancer J* 2013; 19: 288–294
- [26] Kimpel O, Schindler P, Schmidt-Pennington L et al. Efficacy and safety of radiation therapy in advanced adrenocortical carcinoma. *Br J Cancer* 2023; 128: 586–593
- [27] Roux C, Boileve A, Faron M et al. Loco-regional therapies in oligometastatic adrenocortical carcinoma. *Cancers (Basel)* 2022; 14: 2730
- [28] Cox JD, Stetz J, Pajak TF. Toxicity criteria of the Radiation Therapy Oncology Group (RTOG) and the European Organization for Research and Treatment of Cancer (EORTC). *Int J Radiat Oncol Biol Phys* 1995; 31: 1341–1346
- [29] Hermsen IG, Groenen YE, Dercksen MW et al. Response to radiation therapy in adrenocortical carcinoma. *J Endocrinol Invest* 2010; 33: 712–714
- [30] Percarpio B, Knowlton AH. Radiation therapy of adrenal cortical carcinoma. *Acta Radiol Ther Phys Biol* 1976; 15: 288–292

- [31] King DR, Lack EE. Adrenal cortical carcinoma: a clinical and pathologic study of 49 cases. *Cancer* 1979; 44: 239–244
- [32] Henley DJ, van Heerden JA, Grant CS et al. Adrenal cortical carcinoma—a continuing challenge. *Surgery* 1983; 94: 926–931
- [33] Nader S, Hickey RC, Sellin RV et al. Adrenal cortical carcinoma. A study of 77 cases. *Cancer* 1983; 52: 707–711
- [34] Venkatesh S, Hickey RC, Sellin RV et al. Adrenal cortical carcinoma. *Cancer* 1989; 64: 765–769
- [35] Magee BJ, Gattamaneni HR, Pearson D. Adrenal cortical carcinoma: survival after radiotherapy. *Clin Radiol* 1987; 38: 587–588
- [36] Markoe AM, Serber W, Micaily B et al. Radiation therapy for adjunctive treatment of adrenal cortical carcinoma. *Am J Clin Oncol* 1991; 14: 170–174
- [37] Polat B, Fassnacht M, Pfreundner L et al. Radiotherapy in adrenocortical carcinoma. *Cancer* 2009; 115: 2816–2823
- [38] Villanueva A. Hepatocellular carcinoma. *N Engl J Med* 2019; 380: 1450–1462
- [39] Lencioni R, de Baere T, Soulen MC et al. Lipiodol transarterial chemoembolization for hepatocellular carcinoma: a systematic review of efficacy and safety data. *Hepatology* 2016; 64: 106–116
- [40] Cazejust J, De Baère T, Auperin A et al. Transcatheter arterial chemoembolization for liver metastases in patients with adrenocortical carcinoma. *J Vasc Interv Radiol* 2010; 21: 1527–1532
- [41] Mauda-Havakuk M, Levin E, Levy EB et al. Long-term outcomes in patients with advanced adrenocortical carcinoma after image-guided locoregional ablation or embolization. *Cancer Med* 2021; 10: 2259–2267
- [42] Owen DH, Patel S, Wei L et al. Metastatic adrenocortical carcinoma: a single institutional experience. *Horm Cancer* 2019; 10: 161–167
- [43] Soga H, Takenaka A, Ooba T et al. A twelve-year experience with adrenal cortical carcinoma in a single institution: long-term survival after surgical treatment and transcatheter arterial embolization. *Urol Int* 2009; 82: 222–226
- [44] Kwak K, Yu B, Lewandowski RJ et al. Recent progress in cryoablation cancer therapy and nanoparticles mediated cryoablation. *Theranostics* 2022; 12: 2175–2204
- [45] Wood BJ, Abraham J, Hvizda JL et al. Radiofrequency ablation of adrenal tumors and adrenocortical carcinoma metastases. *Cancer* 2003; 97: 554–560
- [46] Veltri A, Basile D, Calandri M et al. Oligometastatic adrenocortical carcinoma: the role of image-guided thermal ablation. *Eur Radiol* 2020; 30: 6958–6964
- [47] Li X, Fan W, Zhang L et al. CT-guided percutaneous microwave ablation of adrenal malignant carcinoma: preliminary results. *Cancer* 2011; 117: 5182–5188
- [48] Ripley RT, Kemp CD, Davis JL et al. Liver resection and ablation for metastatic adrenocortical carcinoma. *Ann Surg Oncol* 2011; 18: 1972–1979
- [49] Fan W, Guo J, Zhu B et al. Drug-eluting beads TACE is safe and non-inferior to conventional TACE in HCC patients with TIPS. *Eur Radiol* 2021; 31: 8291–8301
- [50] Tetta C, Carpenzano M, Algargoush ATJ et al. Non-surgical treatments for lung metastases in patients with soft tissue sarcoma: stereotactic body radiation therapy (SBRT) and radiofrequency ablation (RFA). *Curr Med Imaging* 2021; 17: 261–275
- [51] Brown AM, Kassab I, Massani M et al. TACE versus TARE for patients with hepatocellular carcinoma: overall and individual patient level meta analysis. *Cancer Med* 2023; 12: 2590–2599
- [52] Viñal D, Minaya-Bravo A, Prieto I et al. Yttrium-90 transarterial radioembolization in patients with gastrointestinal malignancies. *Clin Transl Oncol* 2022; 24: 796–808
- [53] Vogl TJ, Nour-Eldin NA, Hammerstingl RM et al. Microwave ablation (MWA): basics, technique and results in primary and metastatic liver neoplasms - review article. *Rofo* 2017; 189: 1055–1066