




Acquired Hemophilia A: A Rare, Acquired Coagulopathy in the Postpartum Setting

Austin Oberlin, MD¹ Nicole M. Krenitsky, MD, MBA² Christy Gandhi, MD² Imo Joseph Akpan, MD³
Andrew Eisenberger, MD³ Ruth Landau, MD⁴ Ladin Yurteri-Kaplan, MD, MS⁵ Lisa Nathan, MD²
Jean-Ju Sheen, MD² Anita LaSala, MD² Mary D'Alton, MD²

¹ Department of Obstetrics and Gynecology, Columbia University Irving Medical Center, New York, New York

² Division of Maternal-Fetal Medicine, Department of Obstetrics and Gynecology, Columbia University Irving Medical Center, New York, New York

³ Division of Hematology and Oncology, Department of Medicine, Columbia University Irving Medical Center, New York, New York

⁴ Department of Anesthesia, Columbia University Irving Medical Center, New York, New York

Address for correspondence Austin Oberlin, MD, Department of Obstetrics and Gynecology, Columbia University Irving Medical Center, New York, NY 10032-3784
(e-mail: austin.m.oberlin@gmail.com).

⁵ Division of Gynecologic Specialty Surgery, Department of Obstetrics and Gynecology, Columbia University Irving Medical Center, New York, New York

AJP Rep 2023;13:e85–e88.

Abstract

Postpartum hemorrhage (PPH) remains a leading cause of maternal morbidity. Pregnancy-associated acquired hemophilia A (AHA) caused by autoantibodies against factor VIII can present with recurrent episodes of postpartum bleeding.

Case 1 A 50-year-old G2P0112 presented with vaginal bleeding 22 days postcaesarean. She underwent dilation and curettage, hysterectomy, and interventional radiology (IR) embolization before AHA diagnosis. She was hospitalized for 32 days and received 23 units of blood product. She remains without relapse of AHA after 5 years.

Case 2 A 48-year-old G3P1021 presented with vaginal bleeding 8 days postcaesarean. She underwent three surgeries and IR embolization before AHA diagnosis. She was hospitalized for 18 days and received 39 units of blood product. Prednisone and cyclophosphamide were continued after discharge.

AHA is a rare cause of PPH. An isolated prolonged activated partial thromboplastin time (aPTT) should prompt further workup in postpartum patients with refractory bleeding. Rapid recognition of AHA can prevent significant morbidity related to hemorrhage, massive transfusion, and multiple surgeries.

Keywords

- ▶ postpartum hemorrhage
- ▶ bleeding disorder
- ▶ coagulopathy
- ▶ maternal morbidity

Postpartum hemorrhage (PPH) remains a leading cause of maternal mortality worldwide.¹ Although the most common causes are uterine atony, obstetric laceration, or retained placenta, recurrent episodes of hemorrhage despite multiple surgical and pharmacologic interventions should elicit consideration of rarer etiologies, including coagulopathies.

Here we present two cases of acquired hemophilia A (AHA) diagnosed in the setting of PPH at a single institution. Both patients provided written consent for publication. In addition, we review the literature on pregnancy-associated AHA including the workup and management for the obstetrician.

received

February 24, 2023

accepted

October 19, 2023

accepted manuscript online

October 25, 2023

DOI <https://doi.org/10.1055/a-2198-7888>.

ISSN 2157-6998.

© 2023. The Author(s).

This is an open access article published by Thieme under the terms of the Creative Commons Attribution-NonDerivative-NonCommercial-License, permitting copying and reproduction so long as the original work is given appropriate credit. Contents may not be used for commercial purposes, or adapted, remixed, transformed or built upon. (<https://creativecommons.org/licenses/by-nc-nd/4.0/>)

Thieme Medical Publishers, Inc., 333 Seventh Avenue, 18th Floor, New York, NY 10001, USA

Case 1

A 50-year-old G2P0010 with dichorionic diamniotic twins was admitted at 29 weeks' gestation with concern for placental abruption and underwent an uncomplicated low-transverse caesarean delivery at 31 weeks in the setting of ongoing vaginal bleeding. She had no history of any bleeding disorder. The patient re-presented on postoperative day 22 with ongoing vaginal bleeding and symptomatic anemia with a hemoglobin of 6.2 g/dL and platelets of 600,000/ μ L. She underwent a suction dilation and curettage during which a uterine scar dehiscence was suspected, and a 3-cm defect was repaired laparoscopically. After this initial reoperation, her hemoglobin steadily decreased with moderate vaginal bleeding. On day 25, hemoperitoneum was noted on ultrasound and she underwent an exploratory laparotomy, supracervical hysterectomy, and evacuation of several liters of hemoperitoneum. Generalized oozing was noted at all surgical sites including peritoneal and skin incisions. Intraoperative prothrombin time (PT) and activated partial thromboplastin time (aPTT) were prolonged, suspected to be secondary to disseminated intravascular coagulation due to surgical blood loss. However, she continued to have anemia and a persistently prolonged aPTT despite transfusion, prompting hematology consultation. A mixing study and measurement of factor activities demonstrated impaired coagulation and a factor VIII activity of 2% (normal > 50%) consistent with AHA. Recombinant porcine factor VIII and prednisone were started. Simultaneously, the patient had a computed tomography (CT) angiogram of the abdomen, which showed active bleeding into the rectus sheath and a pelvic hematoma. She was transferred to the surgical intensive care unit (ICU) and interventional radiology (IR) performed a bilateral uterine artery embolization.

The patient was monitored in the hospital for a total of 32 days, during which she received 16 units of packed red blood cells, 6 units of fresh frozen plasma, and 1 unit of platelets. Her factor VIII levels did not improve despite 15 days of prednisone, so cyclophosphamide was added. Her factor VIII levels rose to 20%. She received a total of 10 days of cyclophosphamide and 5 months of prednisone. After stopping steroid treatment, her factor VIII levels remain normal, and she has had no evidence of recurrence of her AHA 5 years since her initial diagnosis.

Case 2

This is a 48-year-old G3P1021 with a history of an uncomplicated myomectomy and elevated titers of cardiolipin antibodies on prophylactic anticoagulation. With an appropriate window since last dose of heparin (12 hours), neuraxial anesthesia was provided for the primary delivery. Immediate PPH, suspected due to atony, required multiple uterotonics, a Bakri uterine tamponade balloon, and, ultimately, reoperation (under general anesthesia) with placement of a B-lynch suture and coagulation of friable tissue in the vesicouterine space. She returned on postoperative day 8 after awakening in a pool of blood. Upon readmission, she received utero-

tonics, tranexamic acid (TXA), a blood transfusion, and underwent an exploratory laparotomy with supracervical hysterectomy due to ongoing uterine atony and bleeding. Intraoperatively, oozing was noted from the surgical bed as well and skin edges. The patient was transferred to the surgical ICU for postoperative management given massive hemorrhage and concern for coagulopathy.

Twelve hours later, she had severe abdominal pain and a drop in hemoglobin concerning for an intra-abdominal bleed and was taken for a second exploratory laparotomy. Venous bleeding in the vesicovaginal space was cauterized and fresh frozen plasma, platelets, and packed red blood cells were administered. Postoperatively her hemoglobin continued to downtrend and increasing abdominal distension was noted. A CT angiogram demonstrated left epigastric arterial bleeding, and an IR embolization was performed, complicated by recurrent femoral access site bleeding requiring compressive sutures.

Hematology was consulted for a prolonged aPTT value in the setting of ongoing bleeding. It was initially presumed that the aPTT was falsely elevated in the setting of a lupus anticoagulant as she already had cardiolipin antibodies. The mixing study demonstrated immediate correction but subsequent prolongation in the aPTT with incubation suggestive of a time-dependent coagulation factor inhibitor. Factor VIII assay showed less than 0.5% activity (normal > 50%) and subsequent inhibitor assay was positive at 82.4 Bethesda units (BU; titers < 5 BU = low responders; titers > 10 BU = high responders), diagnostic of AHA. FEIBA (factor VIII inhibitor bypassing activity), TXA, and prednisone were started. In the setting of persistent arterial bleeding after removal of a radial arterial line, additional recombinant factor VIIa was given. She was discharged on hospital day 18. In total, she received 24 units of packed red blood cells, 12 units of fresh frozen plasma, 2 units of platelets, and 1 unit of cryoprecipitate. One month after discharge, her factor VIII levels remained undetectable, and cyclophosphamide was added. Five months after delivery, she remains on cyclophosphamide with no additional bleeding.

Discussion

AHA is a rare form of coagulopathy with an incidence of 1.5 per million per year.² Despite the overall rarity, up to 20% of cases of AHA in women are associated with pregnancy, and its incidence in pregnancy is 1 per 350,000 births.³ However, less than 100 cases have been published, the majority being from two large European registries.^{3,4} Most are diagnosed in the postpartum period, although it is likely some have autoantibodies circulating during the antepartum period.⁴ Delayed diagnosis is common, with a median time to diagnosis from delivery of 89 days. Other presenting symptoms include subcutaneous, mucosal, or musculoskeletal bleeding.⁵ Although both patients were of advanced maternal age and had pregnancies resulting from assisted reproductive technology (ART), more data are needed to determine whether these are risk factors for development of AHA.

AHA is characterized by autoantibodies directed against factor VIII, a key component of the intrinsic coagulation

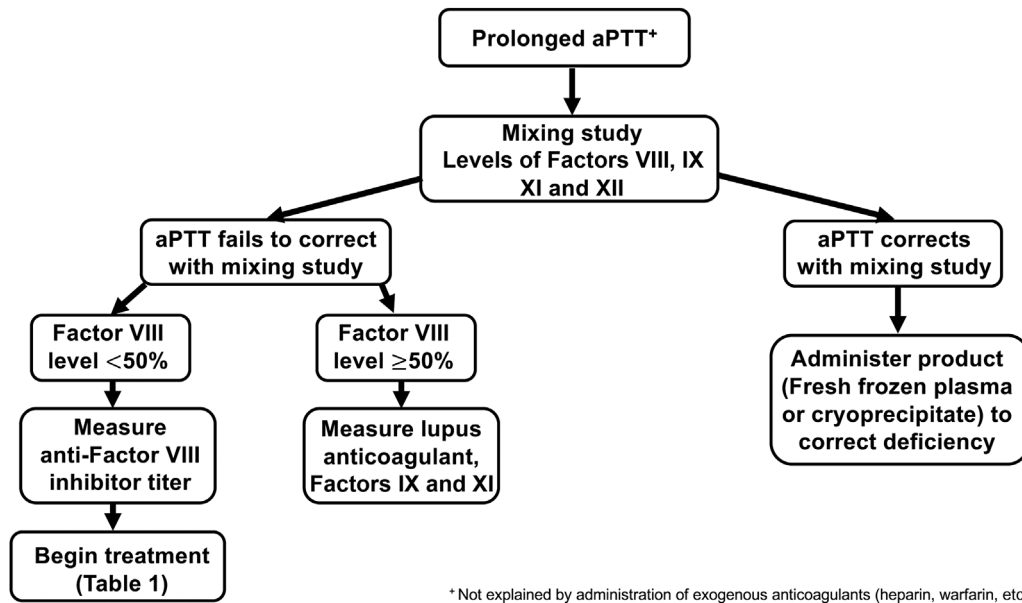


Fig. 1 Algorithm for diagnosis of acquired hemophilia A.

pathway. This autoantibody inhibits the action of factor VIII to a variable degree, leading to a wide range of symptoms from no noticeable bleeding to profound spontaneous bleeding. Pregnancy represents a precipitating event that can lead to the formation of autoantibodies. The first evidence of AHA is a prolonged aPTT. Although the aPTT can be prolonged by other common factors including use of heparin, presence of lupus anticoagulant, or even disseminated intravascular coagulation, a prolonged aPTT with unexplained bleeding should prompt further workup (►Fig. 1). First, a mixing study, in which the patient’s blood is mixed with normal

plasma, will show a persistently prolonged aPTT, due to the presence of the autoantibody. Next, coagulation factor levels (e.g., factors VIII, IX, XI, and XII) will reveal a factor VIII level less than 50% of normal. Finally, a factor VIII antibody assay will show the titer of the antibody present, which may correlate with the severity of the condition.⁵

The risk of mortality with AHA is 20%, although it is substantially lower in patients diagnosed in the peripartum period.^{3,4} Thus, as soon as AHA is suspected, hematology should be consulted. Multidisciplinary discussions between obstetrics, hematology, transfusion medicine, anesthesiology,

Table 1 Treatment options for acquired hemophilia A

Agent	Considerations
Factor replacement	
Recombinant porcine factor VIII	<ul style="list-style-type: none"> ● Easy to monitor ● May require higher doses or may be less effective if autoantibody is cross-reactive with porcine factor VIII
Anti-inhibitor coagulant complex	<ul style="list-style-type: none"> ● More effective for high factor VIII inhibitor titers (> 10 BU) ● No laboratory value to monitor ● Potential risk of arterial and venous clot
Recombinant factor VII activated	<ul style="list-style-type: none"> ● More effective for high factor VIII inhibitor titers (> 10 BU) ● No laboratory value to monitor ● Potential risk of arterial and venous clot
Immunosuppression	
Corticosteroid	<ul style="list-style-type: none"> ● May take ≥ 3 wk to see clinical benefit ● Typical adverse events associated with steroids
Cyclophosphamide (+ corticosteroid)	<ul style="list-style-type: none"> ● May have faster response than steroids alone ● Highest rate of complete remission ● Needs monitoring for bone marrow suppression ● Breastfeeding contraindicated
Rituximab ⁷ (+ corticosteroid)	<ul style="list-style-type: none"> ● Fewer and less severe side effects ● Very few cases reported in the literature ● Acceptable for use while breastfeeding

critical care, and IR should be coordinated as appropriate. As each surgical or procedural intervention carries a high risk of hemorrhage, there should be careful deliberate multidisciplinary considerations for managing further bleeding episodes. If possible, medical management or IR procedures may be preferred to minimize bleeding from surgical sites. As seen in both cases, pregnancy-associated AHA can present with mucosal, venous, and arterial bleeding that is refractory to usual first-line interventions.

Due to the ongoing risk of bleeding in the peripartum period, treatment should be rapidly initiated in patients whose presentations are suspicious for AHA. Treatment generally involves two components: replacement of depleted factor VIII and reduction of the inhibitor via immunosuppression (► **Table 1**). TXA can be used as an adjunct for acute bleeding, but other traditional hemostatic agents such as desmopressin have limited utility and should be avoided. Although the aPTT should begin to normalize once factor VIII levels reach 30 to 50% of normal, response to treatment should be judged clinically. Failed initial therapy, defined as failure of inhibitor titer to decline, or factor VIII level to rise in 3 to 5 weeks, should prompt consideration of second-line therapies. Reasonable second-line options include calcineurin inhibitors (e.g., cyclophosphamide), rituximab, or a combination of immunosuppressive agents.^{6,7}

The long-term prognosis for patients diagnosed with peripartum AHA is mixed. Mortality occurs in less than 5% and remission in greater than 90% of cases. However, depending on the initial immunosuppressive regimen, relapse occurs in approximately 12 to 18% of patients and long-term follow-up with a hematologist is recommended.⁸ Cases of transplacental transmission of antibodies to factor VIII, with neonatal hemorrhage, have been reported.⁹ Neither of the neonates in these cases demonstrated any signs of abnormal bleeding.

In summary, these two cases demonstrate a rare but important consideration for recurrent or delayed PPH. Any peripartum patient with persistent unexplained bleeding and a prolonged aPTT should be promptly evaluated for AHA. Including AHA on the differential in this clinical presentation is critical as (1) failure to quickly diagnose and initiate treatment can lead to significant morbidity and (2) AHA is unlikely to respond to traditional medical and surgical management of PPH, as these do not resolve the underlying

coagulopathy. These cases underscore that early initiation of multidisciplinary care is vital to the successful management of peripartum AHA.

Funding

None.

Conflict of Interest

Dr. D'Alton has a leadership role in ACOG II's Safe Motherhood Initiative, which received unrestricted funding from Merck for Mothers. The other authors do not report any potential conflicts of interest.

References

- 1 Kassebaum NJ, Barber RM, Bhutta ZA, et al; GBD 2015 Maternal Mortality Collaborators. Global, regional, and national levels of maternal mortality, 1990-2015: a systematic analysis for the Global Burden of Disease Study 2015. *Lancet* 2016;388(10053):1775-1812
- 2 Collins PW, Hirsch S, Baglin TP, et al; UK Haemophilia Centre Doctors' Organisation. Acquired hemophilia A in the United Kingdom: a 2-year national surveillance study by the United Kingdom Haemophilia Centre Doctors' Organisation. *Blood* 2007;109(05):1870-1877
- 3 Baudo F, de Cataldo Italian Association of Haemophilia Centres (AICE): Register of acquired factor VIII inhibitors (RIIA) Acquired factor VIII inhibitors in pregnancy: data from the Italian Haemophilia Register relevant to clinical practice. *BJOG* 2003;110(03):311-314
- 4 Tengborn L, Baudo F, Huth-Kühne A, et al; EACH2 registry contributors. Pregnancy-associated acquired haemophilia A: results from the European Acquired Haemophilia (EACH2) registry. *BJOG* 2012;119(12):1529-1537
- 5 Kruse-Jarres R, Kempton CL, Baudo F, et al. Acquired hemophilia A: updated review of evidence and treatment guidance. *Am J Hematol* 2017;92(07):695-705
- 6 Huth-Kühne A, Baudo F, Collins P, et al. International recommendations on the diagnosis and treatment of patients with acquired hemophilia A. *Haematologica* 2009;94(04):566-575
- 7 Bonfanti C, Crestani S, Frattini F, Sissa C, Franchini M. Role of rituximab in the treatment of postpartum acquired haemophilia A: a systematic review of the literature. *Blood Transfus* 2015;13(03):396-400
- 8 Dewarrat N, Gavillet M, Angelillo-Scherrer A, et al. Acquired haemophilia A in the postpartum and risk of relapse in subsequent pregnancies: a systematic literature review. *Haemophilia* 2021;27(02):199-210
- 9 Ries M, Wölfel D, Maier-Brandt B. Severe intracranial hemorrhage in a newborn infant with transplacental transfer of an acquired factor VII:C inhibitor. *J Pediatr* 1995;127(04):649-650