

Imaging findings and treatment in coccydynia – update of the recent study findings

Bildgebende Befunde und Behandlung bei Kokzygodynie – Aktualisierung gemäß der jüngsten Studienergebnisse

Authors

Abdullah Sukun¹, Tijen Cankurtaran², Muhteşem Agildere², Marc-André Weber³

Affiliations

- 1 Radiology, Başkent University Alanya Research and Application Center, Antalya, Turkey
- 2 Radiology, Baskent University, Ankara, Turkey
- 3 Institute of Diagnostic and Interventional Radiology, Pediatric Radiology and Neuroradiology, Rostock University Medical Center, Rostock, Germany

Key words

coccydynia, coccyx fractures, coccygeal hypermobility, imaging findings, treatment in coccydynia

received 14.06.2023

accepted 08.09.2023

published online 2023

Bibliography

Fortschr Röntgenstr

DOI 10.1055/a-2185-8585

ISSN 1438-9029

© 2023, Thieme. All rights reserved.

Georg Thieme Verlag KG, Rüdigerstraße 14,
70469 Stuttgart, Germany

Correspondence

Dr. Abdullah Sukun

Radiology, Baskent University Alanya Practice and Research Hospital, Alanya, 07400 Antalya, Turkey

Tel.: +90 54 39 03 77 20

abdullah.sukun@gmail.com

ABSTRACT

Background Coccydynia is one of the most overlooked symptoms in clinical practice. The diagnosis and radiologic findings of traumatic coccyx can be more easily detected unless it is delayed and postponed. For idiopathic coccydynia, which accounts for one third of cases, patients present with long-standing pain and multiple physician visits.

Method The keywords coccyx, coccydynia, coccygodynia were searched in PubMed, Embase, Scopus databases in the last 5 years. Research articles, reviews and case reports were analyzed. The studies conducted in the last 5 years were presented under the headings of etiology, radiologic assessment, interventional and surgical treatments.

Results and Conclusion The first step is dynamic X-ray of the coccyx in standing and sitting position. In this way, morphologic parameters and hypermobility causing idiopathic coccydynia can be evaluated. Morphologic and morphometric features of the coccyx described in previous CT and MR studies have explained the relationship with coccydynia. The key features are as follows: Type II coccyx morphology, subluxation of the intercoccygeal joint, presence of bony spicules. Knowledge of these definitions as well as the differential diagnosis in this anatomical region will help in reaching the correct diagnosis. The treatment of coccydynia is stepwise like the diagnosis. Conservative treatments are initiated first. Manipulations, ganglion impar block, injections, radiofrequency and shock treatments and finally coccygectomy are treatment methods reported. Radiologists should not overlook this region and should be familiar with the coccyx's morphologic appearance and the sacrococcygeal region's differential diagnosis.

Key points:

- The etiology of coccydynia usually includes trauma, obesity and female sex, special coccyx morphology, and coccygeal hypermobility.
- Coccyx fractures are defined into three groups as flexion type 1, compression type 2, and extension type 3.
- When evaluating coccydynia, the first step is a dynamic X-ray examination of the coccyx in standing and sitting position.
- Hypermobility is defined as more than 25% posterior subluxation while sitting or more than 25° flexion while sitting.
- More than 35° posterior subluxation is considered significant hypermobility.

ZUSAMMENFASSUNG

Hintergrund Die Kokzygodynie ist eines der am häufigsten übersehenen Symptome in der klinischen Praxis. Die Diagnose und der radiologische Befund eines traumatischen Steißbeins können leichter erkannt werden, wenn sie nicht verzögert und aufgeschoben wird. Bei der idiopathischen Kokzygodynie, die ein Drittel der Fälle ausmacht, präsentieren sich die Patienten mit lang anhaltenden Schmerzen und zahlreichen Arztbesuchen.

Methode Mit den Stichwörtern coccyx, coccydynia, coccygodynia wurden die Datenbanken PubMed, Embase und Scopus in den letzten 5 Jahren durchsucht. Es wurden Forschungsartikel, Übersichtsarbeiten und Fallberichte analysiert. Die in den letzten 5 Jahren durchgeführten Studien werden unter den Überschriften Ätiologie, radiologische Beurteilung, interventionelle und chirurgische Behandlungen vorgestellt.

Ergebnisse und Schlussfolgerungen Der erste Schritt ist eine dynamische Röntgenaufnahme des Steißbeins in stehender und sitzender Position. Auf diese Weise können die morphologischen Parameter und die Hypermobilität, die die idiopathische Steißbeinerkrankung verursacht, beurteilt werden. Morphologische und morphometrische Merkmale des Steißbeins, die in früheren CT- und MR-Studien beschrieben wurden, haben den Zusammenhang mit der Kokzygodynie erklärt. Die wichtigsten Merkmale sind die folgenden: Typ II Steißbein Morphologie, Subluxation des Intercoccygealgelenks, Vorhandensein von knöchernen Spicula. Die Kenntnis dieser Kriterien sowie der Differentialdiagnosen in dieser anatomischen Region hilft, die richtige Diagnose zu stellen. Die Behandlung der Kokzygodynie erfolgt schrittweise wie die Diagnose. Zunächst werden konservative Behandlungen eingeleitet. Als Behandlungsmethoden werden Manipulationen, Ganglion-Impar-Blockaden, Injektionen, Radiofrequenz- und

Schockbehandlungen und schließlich die Kokzygektomie genannt. Radiologen sollten Befunde in dieser Region nicht übersehen und mit dem morphologischen Erscheinungsbild des Steißbeins und der Differentialdiagnose der Sakrozygealregion vertraut sein.

Kernaussagen:

Die Ätiologie der Kokzygodynie umfasst in der Regel Trauma, Adipositas und weibliches Geschlecht, spezielle Morphologie des Steißbeins, sowie Hypermobilität des Steißbeins.

- Steißbeinfrakturen werden in drei Gruppen eingeteilt: Flexionstyp 1, Kompressionstyp 2 und Extensionstyp 3.
- Bei der Beurteilung einer Steißbeinfraktur ist der erste Schritt eine dynamische Röntgenuntersuchung des Steißbeins in stehender und sitzender Position.
- Hypermobilität ist definiert als mehr als 25° posteriore Subluxation im Sitzen oder mehr als 25° Flexion im Sitzen.
- Eine hintere Subluxation von mehr als 35° gilt als signifikante Hypermobilität.

Zitierweise

- Sukun A, Cankurtaran T, Agildere M et al. Imaging findings and treatment in coccydynia – update of the recent study findings. *Fortschr Röntgenstr* 2023; DOI 10.1055/a-2185-8585

Introduction

Coccydynia occurs when the coccyx (or tailbone) segment of the spine is affected by various pathologies. The most common cause of coccydynia is trauma, although nontraumatic and idiopathic causes have also been observed. Traumatic causes include fracture, dislocation, and instability; nontraumatic causes include bone protrusion in the distal coccyx, Tarlov cysts, cancer, abnormal flexion or extension, arthritis, and osteomyelitis [1]. Sympathetic nervous system pain, reflected pain from various muscles, somatization, and psychological disorders may cause idiopathic pain [2].

Hypermobility and subluxation of the coccyx can cause coccydynia, as can variations in coccyx morphology. No clear incidence or prevalence has been reported for coccydynia and the condition accounts for less than 1% of all back pain, although its prevalence in women is approximately five times higher than in men. It is usually seen in people over 40 years of age, but it also affects those in other age groups. Increased BMI and two or more vaginal deliveries increase one's risk of experiencing the condition [3].

Cases of coccydynia are usually self-limiting within six months and resolve with little medical treatment. However, other cases are characterized by severe chronic pain that limits daily activities and the difficulty of determining appropriate treatment. Patients often report that there is no specific diagnosis and that clinicians do not attach much importance to this condition. Thus, available diagnostic and treatment options should be evaluated. Treatment generally includes oral and topical medications, injections for pain, and a surgical procedure called coccygectomy [4, 5].

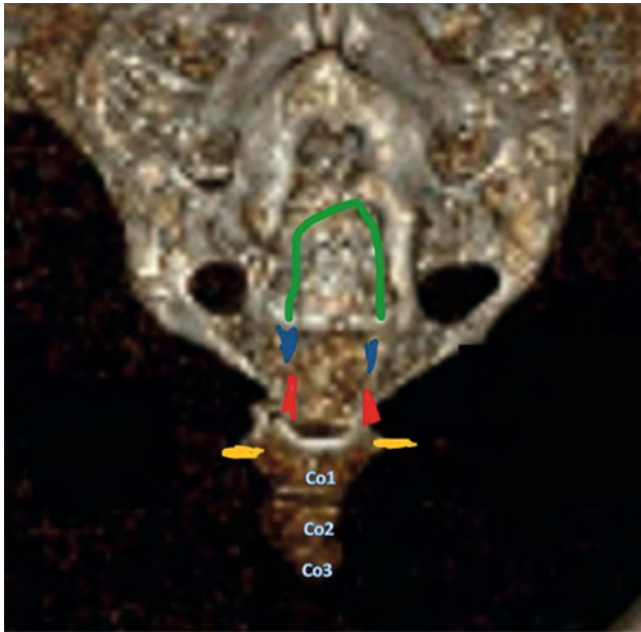
The aim in this article is to present a review of the radiologic findings in the current literature regarding possible causes of coccydynia and to underscore the necessity of examining the coccygeal bone while investigating pathologies in the sacral region.

Methods

The PubMed, Embase, and Scopus databases were searched for literature from the last five years using the keywords coccyx, coccydynia, and coccygodynia. 122 articles were found. Four reviews, six research articles, and ten case reports were included in the anatomy and etiologies section. The radiologic evaluation section included six research articles and one case report; the interventional procedures section included eight research articles, two case reports, and one systematic review (189 patients); the surgical section included seven research articles, one review (826 patients), and one systematic review and meta-analysis (1,980 patients). Research articles with more than 100 patients were included. Out of a total of 47 references, 23 articles were related to radiologic imaging.

Anatomy

The coccyx usually comprises four segments, although it can have three (13%) or five (11%) segments. Posterior to the fifth sacral segment, the sacral hiatus and the transverse processes of the first segment of the coccyx are important anatomical structures



► **Fig. 1** shows the anatomical representation of the coccyx on a 3D tomography image. The transverse processes of the coccyx 1 vertebra (yellow mark), coccygeal horns (red mark), sacral horns (blue mark) and sacral hiatus (green mark) are important anatomical structures to find the sacrococcygeal joint.

to find the sacrococcygeal joint. Additionally, the posterior sacral and coccygeal horns can be used to recognize the sacrococcygeal joint (SCJ). The sacrococcygeal horns can fuse, and there is significant variation in the segmentation of the intercoccygeal joints (ICJs). Anterior to the sacrum and coccyx is the presacral fascia, which inferiorly fuses with the rectosacral ligament and is called the *Waldeyer fascia*. The ganglion impar is an anatomical structure that has an important role in the development of pelvic and coccygeal pain [1, 6]. ► **Fig. 1** presents an anatomical illustration of the coccyx.

Etiology

The etiology of coccydynia usually includes trauma, obesity, female sex, a special coccyx morphology, coccygeal hypermobility, and discogenic pain. Normal static and dynamic radiographs and computed tomography (CT) images are preferred for evaluating radiologic features, although dynamic imaging and magnetic resonance imaging (MRI) scans are also useful. Treatment consists of ergonomic adaptations, manual and physical therapies, injections, nerve blocks, and surgery [7].

Trauma

Trauma and related coccyx fractures have an important role in the causes of coccydynia. ► **Fig. 2** portrays a coccyx fracture, the ventral deviation of the fracture, and the absence of pathologic signal change in a post-resection MRI examination of the coccyx. Coccydynia is typically chronic and may have a triggering cause that is

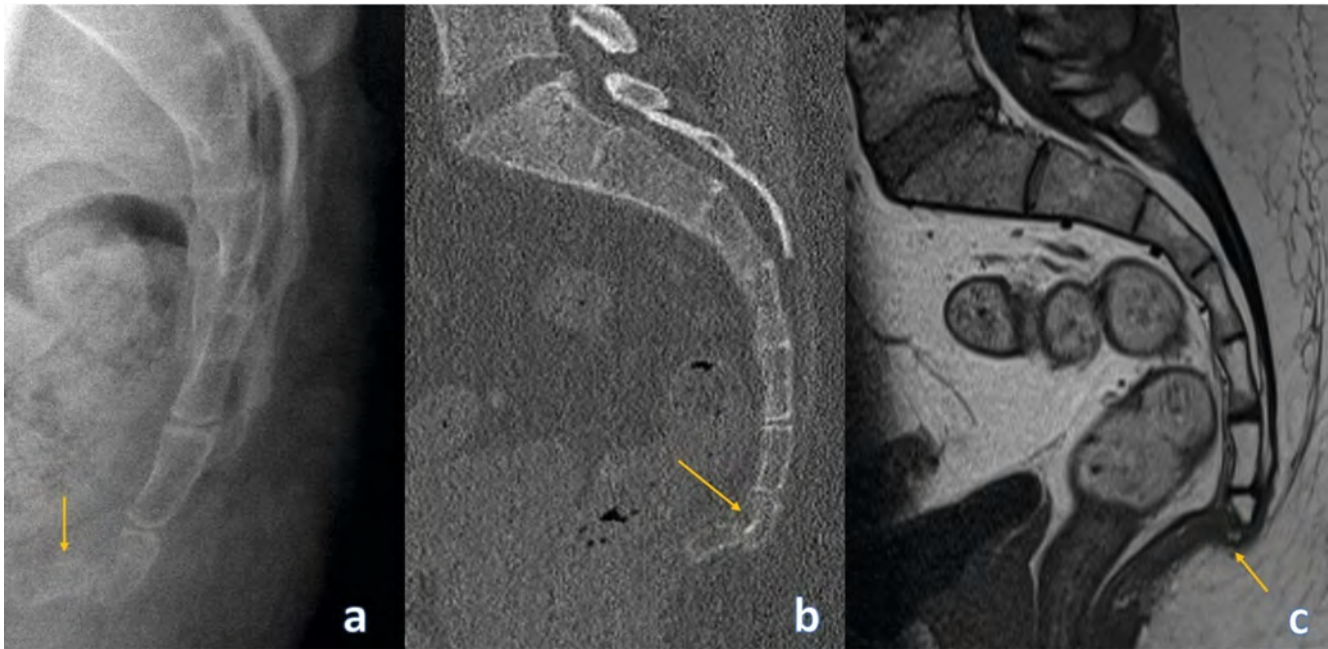
difficult to identify, although a history of direct injury to the coccyx and immediate onset of coccygeal pain suggests a causal link between coccygeal pain and trauma from waterslides (and water channels). These cases indicate that coccygeal trauma from waterslides can exacerbate existing coccygeal pain or cause new-onset coccygeal pain in previously asymptomatic individuals [8]. High-energy trauma with anterior coccyx displacement may be accompanied by cerebrospinal fluid leakage and bladder dysfunction; here, surgical intervention could decompress and stabilize the contused neural structures [9]. Researchers analyzed 104 patients with coccyx fractures and classified the fractures in three groups according to mechanism: flexion, compression, and extension. Flexion fractures are self-limiting, while compression and extension fractures are mostly unstable [10]. Compression fractures have been reported to occur when Co2 vertebrae are square or cuneiform or when Co3 vertebrae are long and straight. Extension fractures, characterized by the separation of the fragments over time, have occurred in obstetric cases. ► **Fig. 3, 4** portray fracture cases in static sagittal coccyx radiography and CT examinations. Some traumatic events, such as a fall, may dislocate the coccyx or SCJ and may cause coccydynia. Dislocations of the SCJ are rare and are usually treated conservatively [11]. ► **Fig. 5** presents cases of coccyx dislocation.

Idiopathic

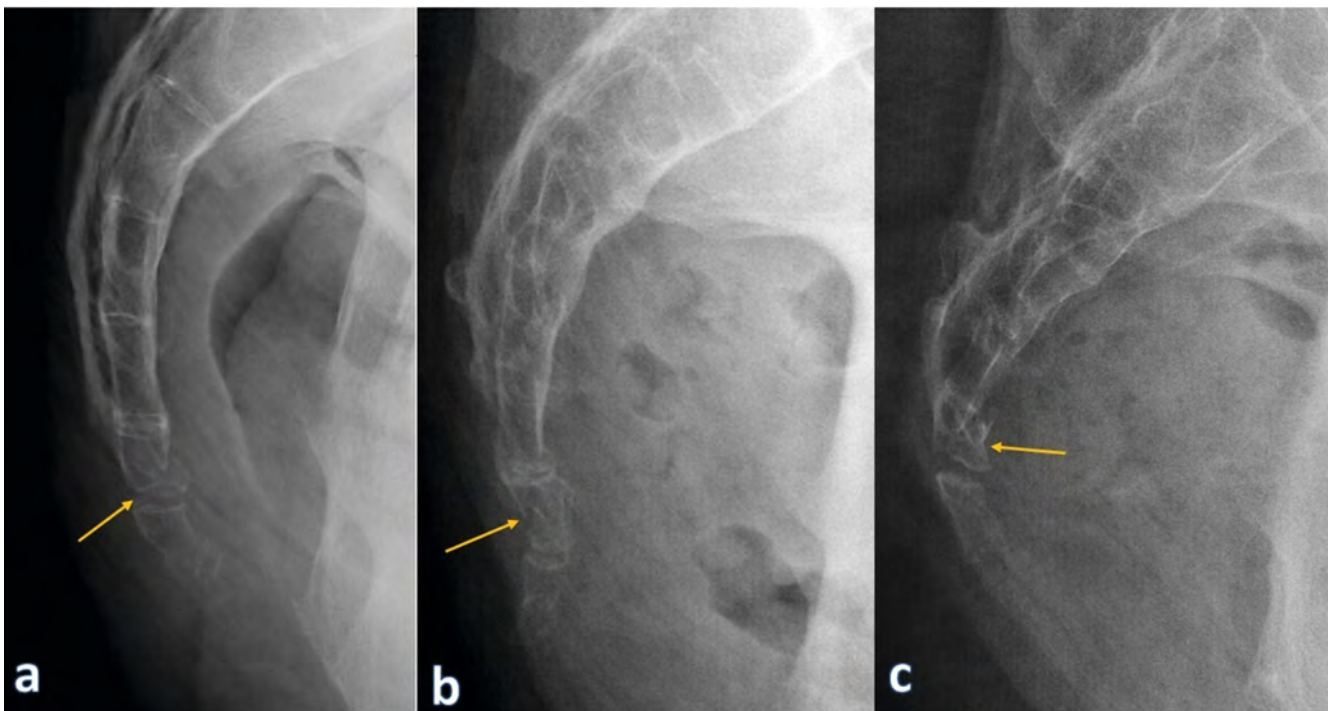
Gupta et al. [12] report that the intercoccygeal angle (ICA) decreases with age and is a possible cause of idiopathic coccydynia. Pelvic floor muscle dysfunction is one of the most important etiologies of coccydynia. Biofeedback is a method for controlling and strengthening the pelvic floor muscles, although it has been investigated as a treatment modality, and researchers have concluded that it does not lead to further improvement in pain or quality of life in patients with coccydynia [13].

Hypermobility

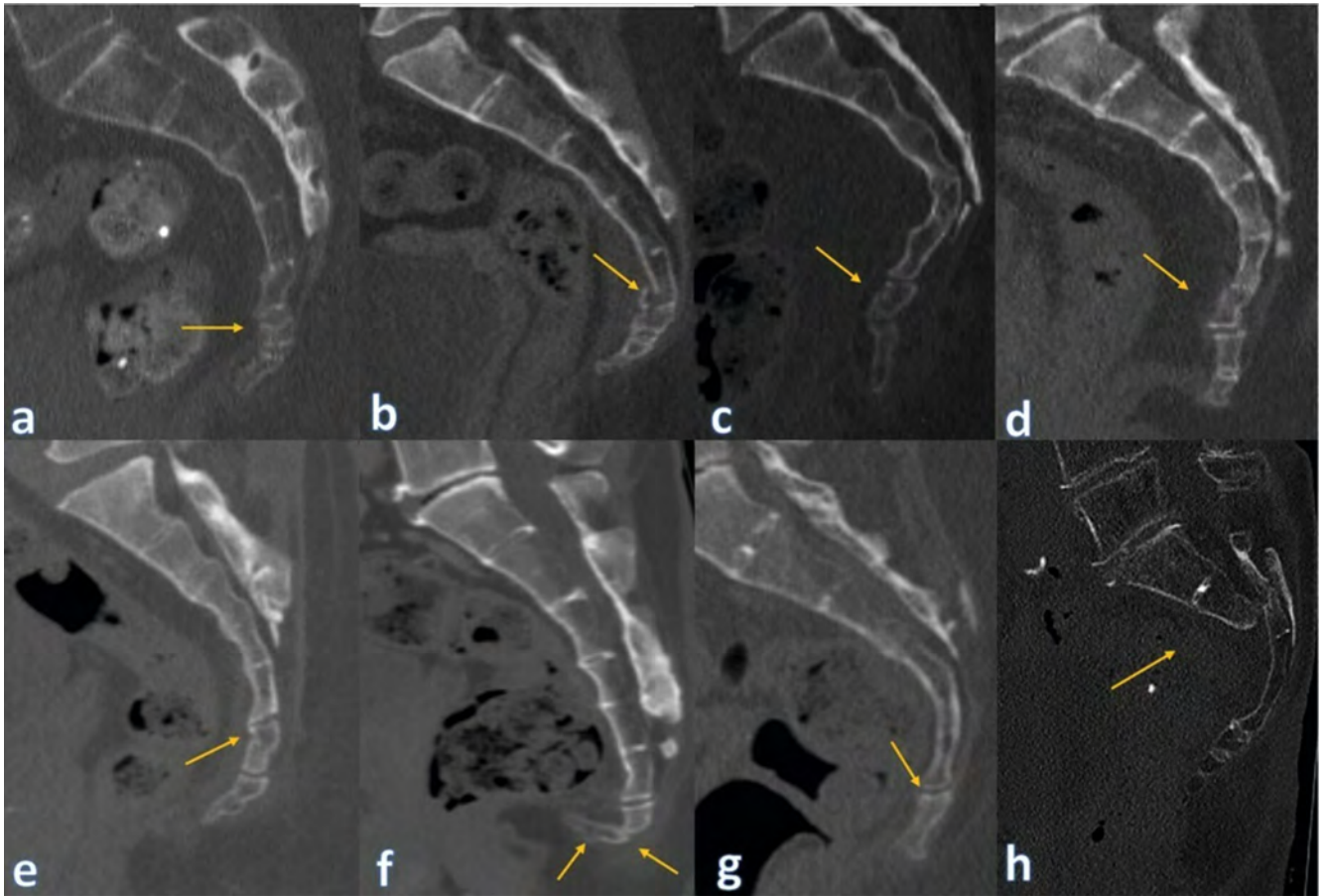
When evaluating coccydynia, dynamic (sitting and standing) lateral radiographs are evaluated. Hypermobility is defined as more than 25% posterior subluxation while sitting or more than 25° of flexion while sitting. More than 35° is considered to be significant hypermobility. In dynamic radiographs, the coccyx is divided into four groups: rigid coccyx, normal mobile coccyx (5°–25° of flexion or extension), hypermobile coccyx (more than 25° of flexion), and luxation. In luxation, the coccyx is displaced posteriorly in the sitting position, and spontaneous reduction occurs in the standing position. Luxation and significant hypermobility are pathologic [6]. If patients have malignancy due to stress or an inflammatory response due to coccyx hypermobility, then differentiation from metastasis is important. ► **Fig. 6** displays the features of stress and inflammatory responses in the coccyx in a patient with a history of malignancy, and ► **Fig. 7** illustrates coccygeal metastasis, fluid accumulation in the coccygeal bursa, and coccydynia due to sacral mass.



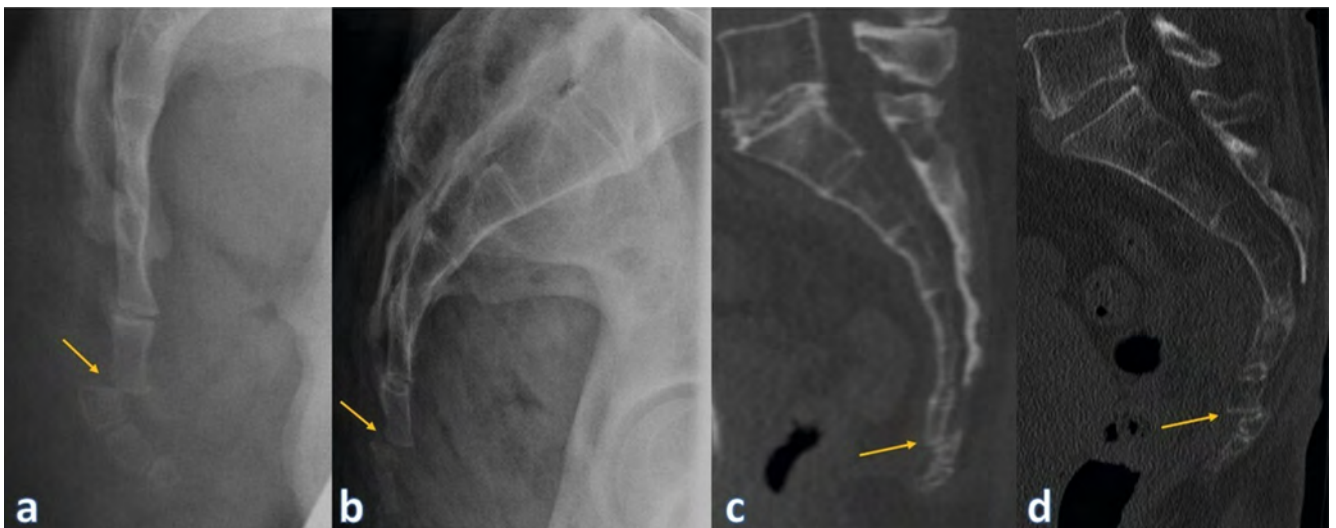
► **Fig. 2** Coccyx fracture **a** Lateral radiograph shows an intervertebral fracture of the caudal part of the os coccyx. **b** In the coccyx fracture, the ventral deviation of the last segment is approximately 40° with a step formation of approximately 5 mm. **c** There is no pathologic signal change in the area of the resected end of the coccyx.



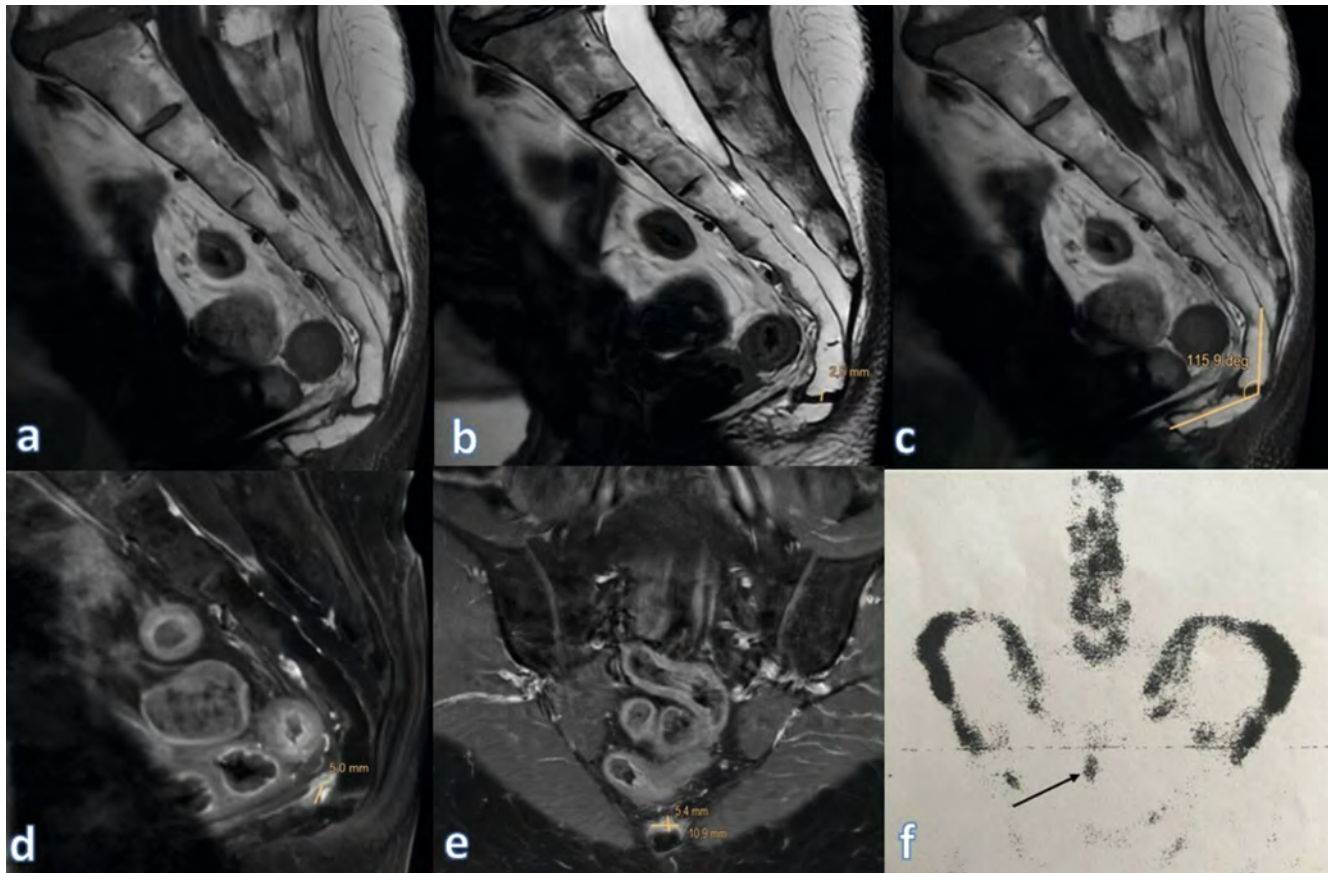
► **Fig. 3** Coccyx fractures **a** Cortical irregularity consistent with fracture in a patient with persistent coccyx fracture after a fall **b** Cortical irregularity in the distal coccyx consistent with fracture **c** Flexion fracture of Co 1 vertebra.



► **Fig. 4** Fracture cases: **a–f** Post-traumatic coccyx fractures **g** Nondisplaced fracture after trauma in a patient with coccygeal spicule **h** Sacral fracture after trauma.



► **Fig. 5** Dislocation cases **a** Dorsal dislocation between Co1 and 2 in a patient who fell on the hip 4 weeks ago. No evidence of fracture. **b** In the lateral radiograph taken in the patient after the fall, the distal part of the coccyx was luxated 7 mm posteriorly. **c** Sagittal CT image shows dislocation between Co2–3. **d** Sagittal CT image shows dislocation between Co1–2.



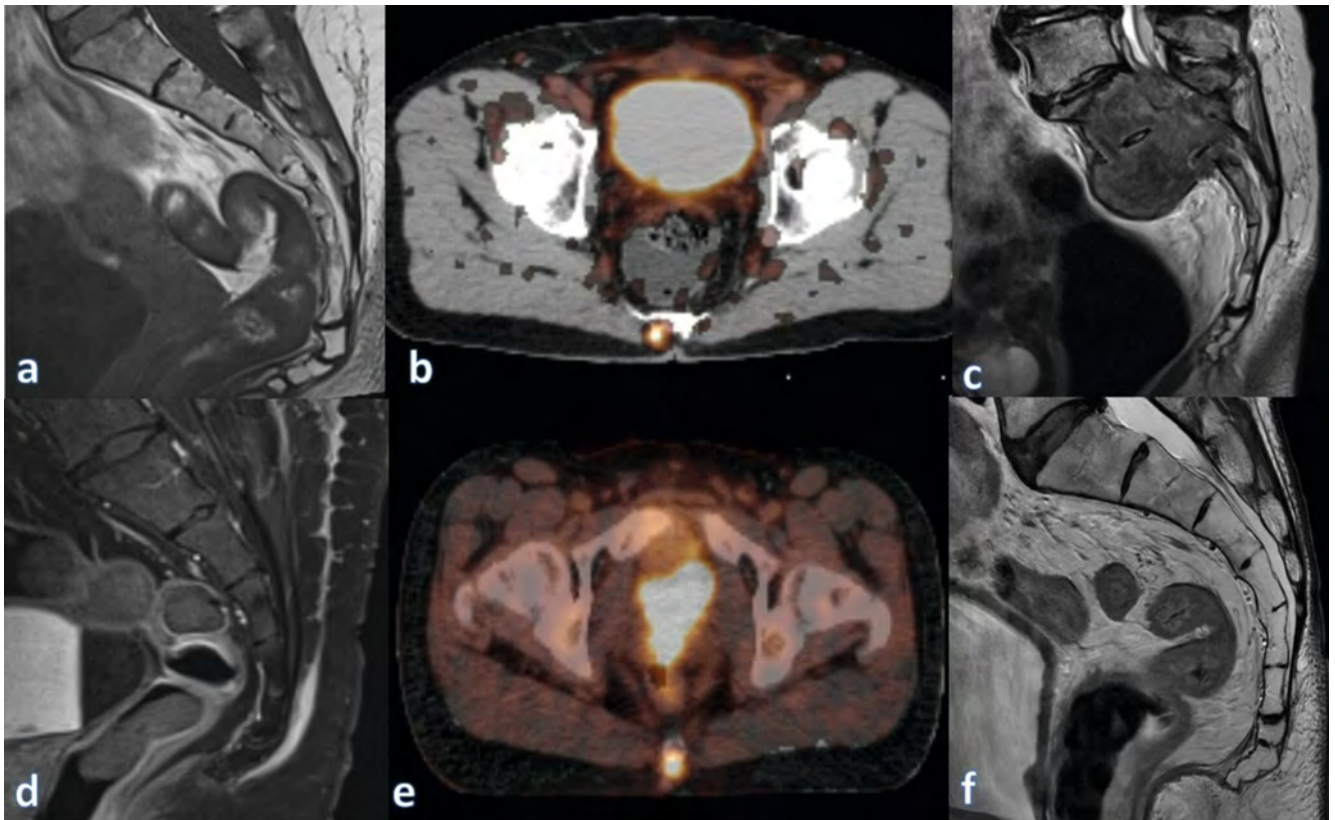
► **Fig. 6** Coccyx stress or inflammatory response: 64-year-old female patient with triple negative breast cancer diagnosed in 2016. She has increasing coccydynia for the last 4 months. No history of trauma. **a** Sagittal T1-weighted MR examination shows no bone lesion suspicious for metastasis. Os coccyx has 4 segments and anterior angulation is observed distally. **b** Separation between Co1 and Co2 segments measured 2.5 mm. **c** There is an angle of 116 degrees between Co1 and distal segments. **d–e** Post-contrast fat-suppressed images show contrast enhancement. **f** Bone scintigraphy shows increased activity at the level of the Os coccyx, which is not compatible with metastasis.

Intrapartum Coccygeal Fracture and Postpartum Coccydynia

Discussions of intrapartum coccygeal fractures are rare in the literature, and only two cases have been reported. However, coccygeal fracture is an important consideration in the early diagnosis of postpartum coccydynia [14] because the coccyx is surrounded by sacrococcygeal ligaments that support movements, and the coccyx may elongate during labor to provide more space for the fetus. In the intrapartum period, a fracture can easily be missed due to nonspecific symptoms, but attention should be paid to localized pain that is aggravated when the patient sits on hard surfaces or changes posture. A coccyx fracture is one of the most common and undetected comorbidities in chronic pain disorders, such as fibromyalgia; one case was diagnosed after 14 months of pain [15]. During labor, the fetal head usually pushes the coccyx backward, resulting in a posterior dislocation, whereas increased coccyx pain in the prone position may indicate an anterior subluxation. A coccyx anterior subluxation associated with vaginal delivery should be suspected when women present with persistent pain in the buttocks and a physical examination reveals localized tenderness in the coccyx [16].

Tumors and Lesions

Tumors and lesions in the coccyx region can cause coccydynia, and perineural cysts without space-occupying lesions in the pericoccygeal region may cause coccydynia. ► **Fig. 8** illustrates coccydynia caused by perineural cysts. Sclerosing epithelioid fibrosarcoma (SFE), which is a rare type of coccygeal tumor, has been reported in only 100 cases in the literature. Although histologically low-grade, SFE is a clinically aggressive malignancy. Consequently, a radiologic evaluation should be performed on every patient with coccydynia rather than treating all instances as idiopathic. A rectal duplication cyst can also cause pain in the coccygeal region [17]. The etiology of non-idiopathic coccydynia may include carcinoid tumors, sacrococcygeal teratomas, sacral giant cell tumors, epithelial cysts, dermoid cysts, and nodular rheumatoid arthritis [18, 19]. Coccydynia caused by lesions and diseases developing around the coccyx is portrayed in ► **Fig. 9**. Autonomic nervous system neoplasms called *paragangliomas* are typically located in the adrenal and extra-adrenal regions. Neurologic complaints, such as back discomfort and paraparesis with or without radiculopathy, are the most typical signs of filum terminale paragangliomas. Patients may sporadically exhibit coccydynia without any neural signs [20].



► **Fig. 7** **a** Increasing pain in the coccyx for months in a patient with known breast cancer. No evidence of metastasis. **b** PSMA positivity consistent with metastasis in os coccyx of prostate carcinoma. **c** Mass lesion compatible with neoplasia in the sacrum in a patient admitted with coccydynia. **d** Sagittal MR image of bladder urachal carcinoma due to increasing coccyx pain shows no pathology in the bony structures but fluid accumulation in the posterior part of the coccyx. **e** Increased activity in the posterior coccyx on PET examination in the same patient. **f** Sagittal T1-weighted MR image of a patient with prostate cancer performed because of coccydynia. There is no bone lesion suspicious for metastasis.

Radiologic Assessment

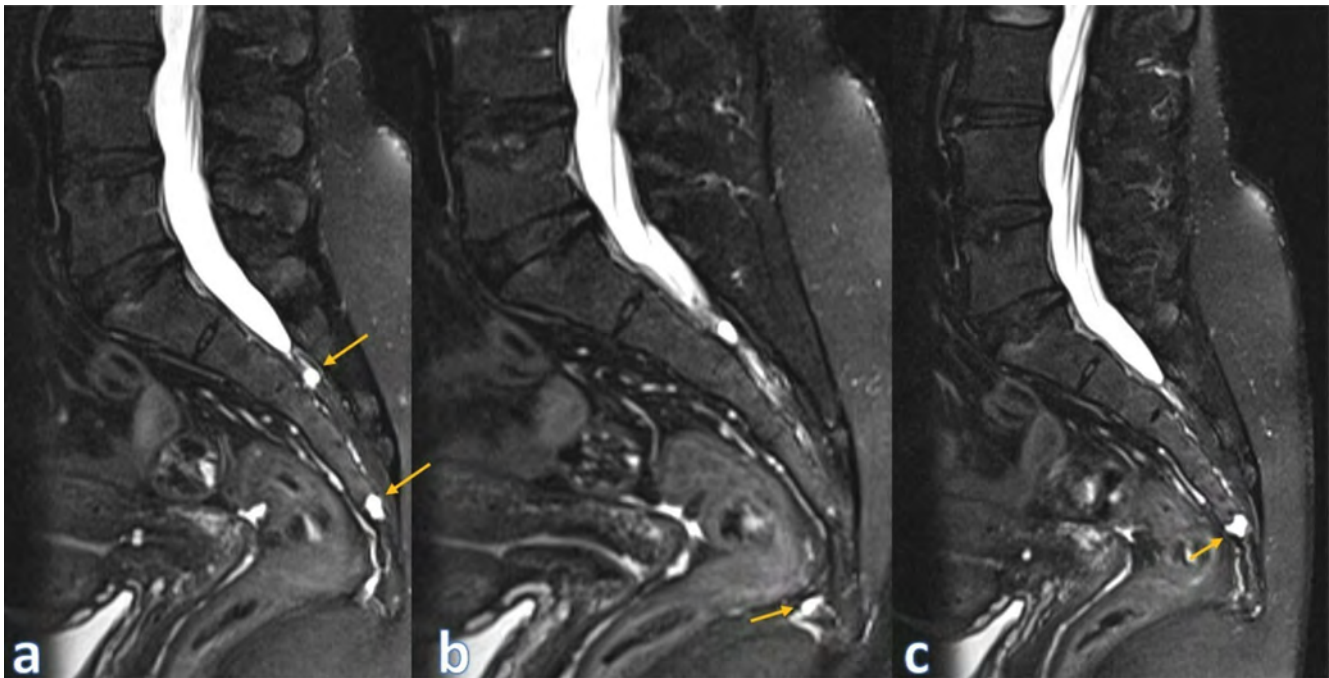
In patients with a clinical picture of coccydynia and persistent pain, lateral coccygeal radiography may be normal or ignored. Therefore, additional imaging modalities should be used in patients with persistent coccydynia [21]. Static projection radiography imaging findings may be normal in patients with coccydynia who do not respond to conservative treatment. Scientists compared normal and abnormal radiologic findings to assess long-term postsurgical outcomes in patients with refractory coccydynia, concluding that surgery failed in 24% of patients with normal images and in 32% of those with abnormal images [22].

Sagittal images are often used for morphologic and morphometric coccyx evaluations. The coccygeal angulation has an important role in diagnosing idiopathic coccydynia. Coccygeal angulation is classified into six types based on the expanded Postacchini and Massobrio classifications: Type I is gently curved with the coccygeal tip directed inferiorly, Type II is more curved with an anteriorly directed tip, Type III is acutely angled anteriorly, Type IV demonstrates anterior subluxation, Type V is retroverted, and Type VI has a scoliotic deformity [6]. ► **Fig. 10** illustrates coccyx types. Pelvic incidence (PI) is a measurement used in pelvic analysis in the sagittal plane. The mean PI values in coccydynia patients

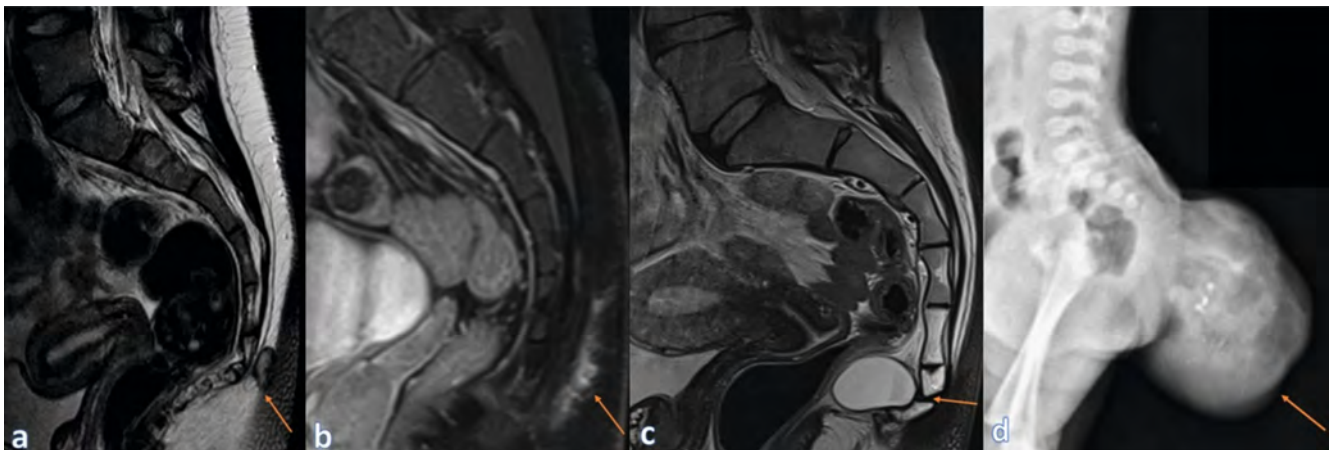
did not differ from those of the healthy population in a study that assesses the PI of patients with coccydynia treated with various techniques to ascertain whether PI is a risk or a prognosis factor. Patients who had greater PIs were more likely to need surgery and have Type III or Type IV coccyx configurations [23].

In a study regarding coccyx morphology via CT in the Turkish population, ICJ fusion was found in 79.4% of cases, SCJ fusion in 68.6%, and sacrococcygeal subluxation in 3.4%. Type 2 was the most common type of coccyx. Coccygeal spicule, which is a risk factor for coccydynia, was reported in 14.6% of cases. Significant differences were found between SCJ and ICJ effusions according to coccyx type and the number of coccyx vertebrae [24]. Yagi et al. compared three-dimensional CT data of the coccyx in standing and supine positions. In the standing position, the coccyx was significantly elongated and flattened, and its tip was placed backward and downward. Additionally, the coccygeal straight length and sacrococcygeal straight length were significantly longer.

► **Fig. 11** presents the morphological and morphometric measurements of the coccyx. The sacrococcygeal angle (SCA) is significantly larger, while the lumbosacral angle is significantly smaller. The migration length of the tip of the coccyx is moderately correlated with BMI. These study results may provide important clues regarding the pathogenesis of coccydynia and pelvic floor dysfunction [25]. Ahmed Shams et al. evaluated sacrococcygeal



► **Fig. 8** Perineural cysts; **a** Perineural cysts without space-occupying effect on the sacral plexus (yellow arrows) **b** 8 × 3 mm long, flat-oval, fluid formation at the tip of the coccyx. **c** No evidence of sacrum/coccyx deformity or fracture, no significant muscle/tendon changes in the pelvic floor. No pericoccygeal space-occupying lesion. Perineural cyst without space-occupying effect at the level of 4th sacral vertebrae (yellow arrow).

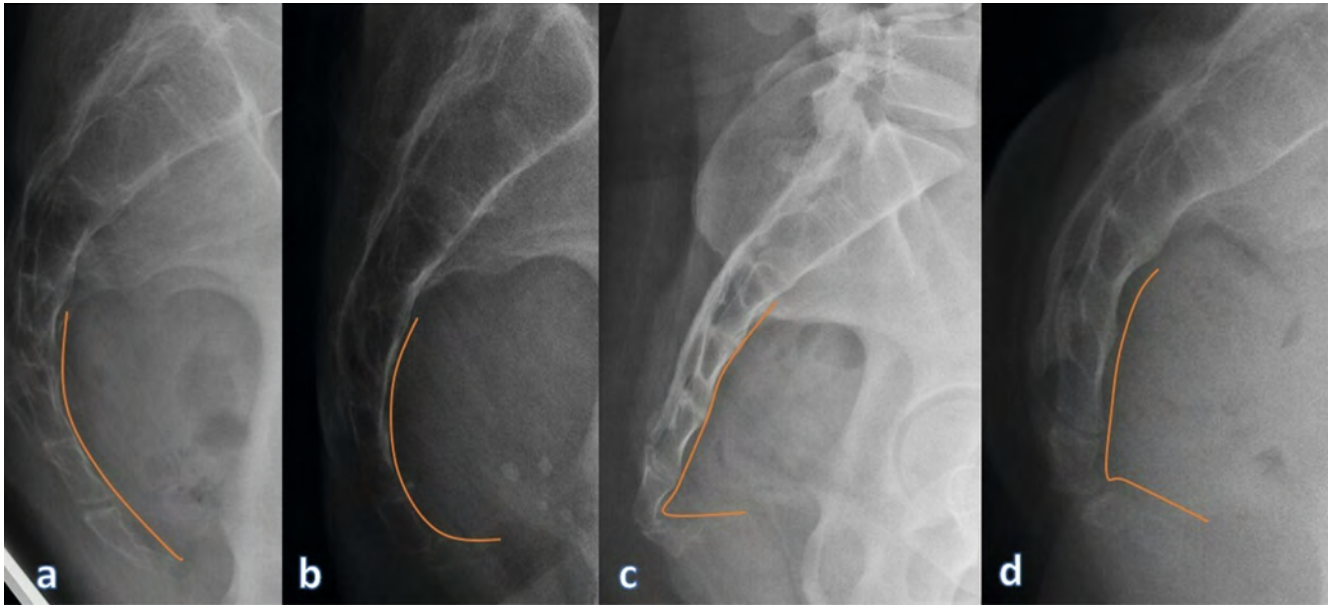


► **Fig. 9** Lesions around the coccyx. **a** Sagittal T2 image shows pilonidal sinus adjacent to the coccyx (arrow). **b** Sagittal fat-suppressed MR image shows inflammatory signal increases in the perianal region due to perianal fistula (arrow). **c** Sagittal T2 image shows an anterior slope of the coccyx and also a rectal duplication cyst (arrow). **d** Lateral infantogram shows a well-circumscribed sacrococcygeal teratoma mass in the sacrococcygeal region containing calcifications and fat (Wattamwar GK, Dhok A, Phatak S et al. An Aberrant Case of Sacrococcygeal Teratoma in a Female Infant Born of Twin Pregnancy. *Cureus* 2023; 15: e37 288. doi:10.7759/cureus.37 288).

morphologic and morphometric parameters via MRI, determining that Type II morphologic coccyx, subluxation of the ICJ, and the presence of bony spicules are more common in patients with idiopathic coccydynia. Additionally, the sacral angle and sacrococcygeal curvature index are lower, while the sacrococcygeal curve length is higher in patients with coccydynia [26].

In the new radiologic classification for surgical decision-making in patients with coccydynia, the SCA, ICA, and intervertebral disc heights were measured on standing and sitting X-rays of

patients with coccydynia. Four types of coccydynia were defined. In Type I, increased SCAs and ICAs were observed in the unsegmented coccyx in the supine position. In Type II, SCA and ICA increases were present in the sitting position in a multi-segmented coccyx. In Type III, negative SCA and ICA values were found with posterior angulation. Type IV is characterized by a positive SCA with anterior-posterior separation of the tailbone and a shift of the ICA from posterior to anterior orientation. The authors report that Type III and IV patients are predisposed to surgery [27]. Radi-



► **Fig. 10** Coccygeal angulation **a** Type I is gently curved with the coccygeal tip directed inferiorly, **b** Type II is more curved with an anteriorly directed tip, **c** Type III is acutely angled anteriorly, **d** Type IV demonstrates anterior subluxation.

ologic evaluation should start with dynamic radiographs if possible, and information about the morphology and mobility of the coccyx should be obtained. Radiologic classification with radiographs does not involve unnecessary ionizing radiation for CT scans, has a cost advantage over MRI, and is practical to perform with dynamic lateral and sitting X-rays. CT is more advantageous for demonstrating variable fusion in the SCJs and ICJs. Furthermore, fractures and coccygeal spicules are more easily recognized on CT than on radiographs. When problems cannot be detected with dynamic radiographs and CT, MRI should be used to evaluate changes in disc and vertebral endplates, bone marrow edema or fluid collection in the posterior bursa of the coccyx, soft tissues around the coccyx, and responses of stress or inflammation due to mobility. Current radiology studies are listed in ► **Table 1**.

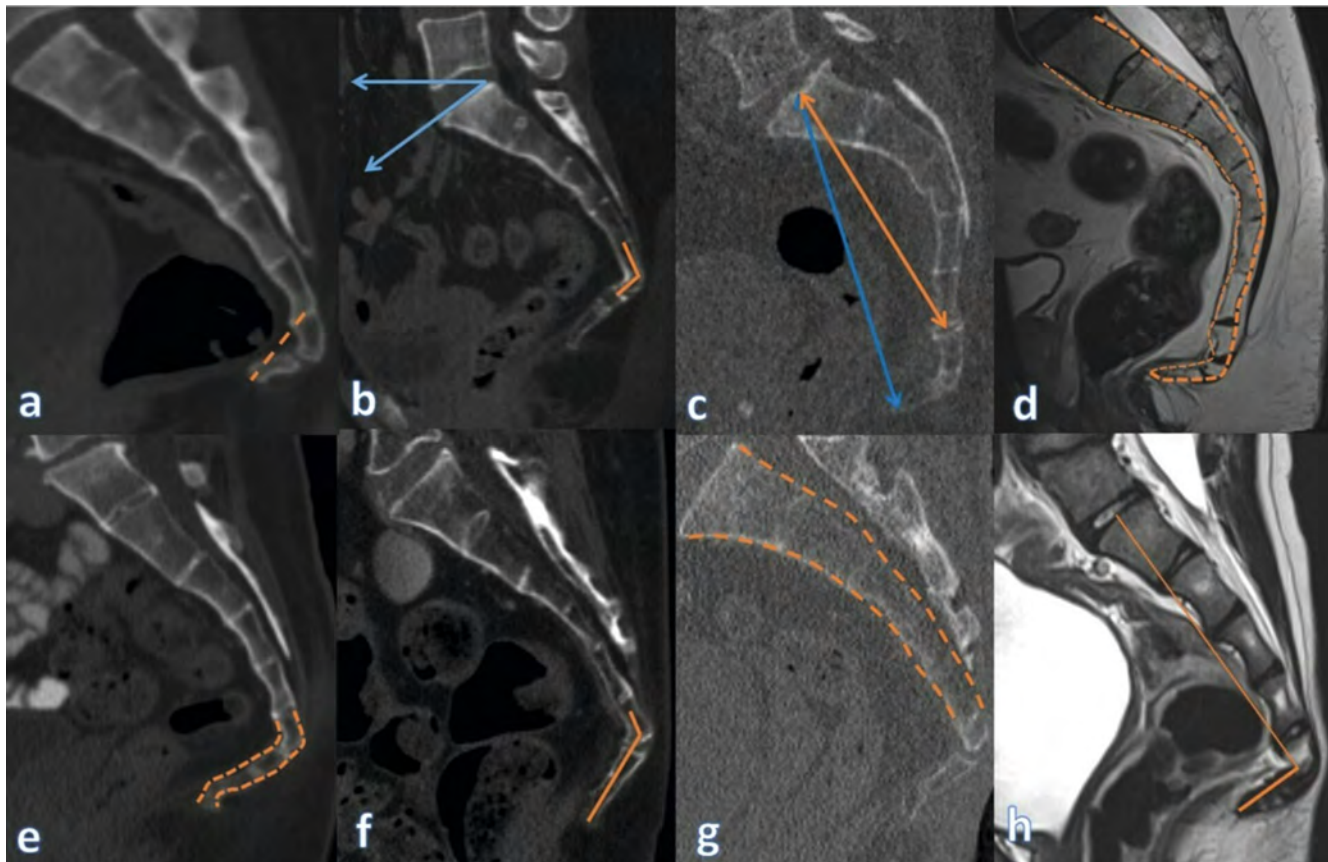
Treatment

Treatment occurs in stages, from conservative to invasive. Patients with idiopathic and traumatic coccydynia respond to conservative treatment in 90% of cases. Ergonomic adaptations (donut or ring-shaped pillows, posture training, hip bands and stool softening measures), manual therapies, and other therapy constitute initial treatments. Injections and nerve blocks for pain management as well as surgical coccygoplasty and coccygectomy are performed in patients who do not respond to treatment for more than six months [1, 6, 7].

Interventional Procedures

Ganglion impar block (GIB) is applied to patients with chronic coccydynia when conservative treatment is unsuccessful. GIB is a safe approach that reduces pain scores and has a low incidence of

complications. Moreover, the procedure takes less than 10 minutes on average [28]. GIB is proven to reduce neuropathic pain in chronic coccydynia, which improves patients' pain-free sitting time. However, the effect on the patient's quality of life is not clear [29]. Ganglion impar radiofrequency thermocoagulation (RFT) treatment is another option; success rates are 67.4% and 61.1% at 6 and 12 months post-intervention, respectively [30]. Side effects of GIB treatment include transient motor dysfunction; bowel, bladder, and sexual dysfunction; neuritis; rectal perforation; sciatic nerve compression; cauda equina syndrome; and infection. One patient with conus infarction after GIB without imaging guidance was reported, thus indicating that imaging should be guided to minimize inappropriate intravascular injection of particulate steroids [31]. In a prospective randomized double-blind study, scientists investigated the role of corticosteroids in impar blockade; one group received only anesthetic while the other group received local anesthetic and steroids. The numerical rating scale (NRS) and Beck depression scale were evaluated before the procedure as well as one and three months after; GIB reduced pain and improved depression in patients with chronic coccydynia. Additionally, steroids further improved GIBs for coccydynia [32]. A systematic review was conducted to determine the efficacy of GIB and RFA (radio frequency ablation) of the ganglion impar in controlling pain in patients with coccydynia; the overall success rate was > 85% for both modalities [33]. One study reports that GIB may be more effective in cancer-related pain than in pain due to benign causes [34]. Researchers investigating which approach should be used to perform GIB randomly grouped 40 patients who did not respond to six-week conservative treatment, and a combination of local anesthetics and steroids was applied to both groups. Both the trans-coccygeal and trans-sacro-coccygeal approaches were found to be safe and effective, and the first intra-coccygeal joint selection improved in pain score,



► **Fig. 11** Coccygeal morphometry parameters **a** Coccygeal straight length, **b** Sacral angle (blue arrows) and sacrococcygeal joint angle and **c** Sacral straight length and sacrococcygeal straight length (blue line), **d** Sacrococcygeal curved length, **e** Coccygeal curved length, **f** Intercoccygeal angle, **g** Sacral curved length **h** Sacrococcygeal angle.

functional disability, patient satisfaction, and ease of application [35]. Celenlioglu et al. investigated the predictive factors that affect the success of GIB in chronic coccydynia and reported that prolonged symptom duration has significant effects on treatment success. The cut-off value for duration of coccydynia was two years [36]. Seker et al. [37] compared manual treatment combined with steroid injections with steroid injection alone in persistent coccydynia and reported that the results of combined treatment were better and significantly reduced the recurrence rate. They emphasize that it is a safe and easy option before surgical treatment. Wei-Ting Wu et al. performed ultrasound-guided location and injection of the coccygeal nerve in a 54-year-old patient with a coccygeal fracture and published it as a video [38].

Surgery

Coccygectomy is performed in patients who have exhausted conservative treatment options for chronic refractory coccydynia. The etiology of coccygectomy was found to be traumatic in 68.75% of cases and idiopathic in 31.25%. Patients' symptoms typically lasted for two years before surgery. The patients' pain rating according to the visual analog scale (VAS) decreased from 9.62 preoperatively to 2.25 postoperatively and the positive outcome rate was 87.5% [39]. Treatment outcomes in adolescents

and adults appear to be similar. Injection therapy has a low long-term success rate. When injection treatment does not work, young people may consider surgery [40]. The long-term results of conservative treatment indicate that symptoms decrease over time but persist significantly in half of the cases at 36 months. It was emphasized that coccygectomy should be considered rapidly for patients with posterior coccyx dislocation [41]. In 38 coccygectomy patients with a mean follow-up period of 2 to 29 years, the VAS score decreased from 6.37 to 0.68, and postoperative complications were rare. Findings suggest that different coccyx types do not affect the clinical outcome, and coccygectomy offers safe, successful results in the long term. Coccygectomy is recommended in patients who do not respond to conservative treatment for six months [42]. In 112 coccygectomy patients with at least one year of follow-up, significant improvements were found in the VAS (0–100), Oswestry disability index (ODI), EuroQol five-dimensional questionnaire (EQ-5D), and both the physical component score (PCS) and mental component score (MCS) scales of the 36-item short-form health survey (SF-36); 70% of patients reported that they benefited from the treatment results [43]. Patients evaluated via questionnaire one year after coccygectomy reported a 71% success rate and 89% acceptance rate, even if patients knew the outcome in advance. A decrease in infection rates from 10% to 2% was reported when doctors increased the preo-

► **Table 1** Current radiologic studies on coccydynia.

Author	Year	Article	Type	Modality	Article Message
Maigne [10]	2020	Classification of fractures of the coccyx from a series of 104 patients	Original Research	Standard lateral radiography, CT and MRI scan	Three fracture mechanisms: <ul style="list-style-type: none"> ▪ Flexion (upper level), ▪ Compression (middle level) ▪ Extension (lower level, obstetrical)
Skalski [6]	2020	Imaging Coccygeal Trauma and Coccydynia	Review	Dynamic lateral radiography, CT and MRI scan	<ul style="list-style-type: none"> ▪ Dynamic structure of coccydynia ▪ Correct evaluation of anatomy and abnormalities ▪ Imaging algorithm: Dynamic radiography and CT (acute trauma) and MRI
Garg [7]	2021	Coccydynia-A comprehensive review on etiology, radiological features and management options	Review	Dynamic lateral radiography, CT and MRI scan	<ul style="list-style-type: none"> ▪ Comprehensive etiology research for accurate results ▪ Stepwise approach in treatment ▪ Coccygectomy in resistant and persistent cases
Guneri [24]	2021	Morphological Features of the Coccyx in the Turkish Population and Interrelationships Among the Parameters: A Computerized Tomography-Based Analysis	Original Research	CT scan	<ul style="list-style-type: none"> ▪ A relationship between coccyx types and sacro-coccygeal joint fusion, intercoccygeal joint fusion ▪ The importance of the type of coccyx ▪ Frequency of presence of coccygeal spicules 14.6 %
Yagi [25]	2021	Three-dimensional evaluation of the coccyx movement between supine and standing positions using conventional and upright computed tomography imaging	Original Research	CT scan	<ul style="list-style-type: none"> ▪ Initial three-dimensional reference data in the standing position on computed tomography ▪ Significant lengthening of the coccygeal straight length and sacrococcygeal straight length in the standing position ▪ Significant increase in sacrococcygeal angle and significant decrease in lumbosacral angle in standing position
König [27]	2022	A novel radiological classification for displaced os coccyx: the Benditz-König classification	Original Research	Dynamic lateral radiography	<ul style="list-style-type: none"> ▪ New radiologic classification with dynamic radiographs, ▪ To facilitate surgical decision making in patients with coccyx displacement ▪ Surgical predisposition in Type III and Type IV
Shams [26]	2023	Sacrococcygeal Morphologic and Morphometric Risk Factors for Idiopathic Coccydynia: A Magnetic Resonance Imaging Study	Original Research	MR scan	Idiopathic coccydynia associated; <ul style="list-style-type: none"> ▪ Type II morphologic coccyx, ▪ Subluxation of the intercoccygeal joint ▪ Presence of bony spicules

perative antibiotic prophylaxis from one day to two days, and it was argued that postoperative infection could be reduced in this way [44]. The results of coccygectomy in pediatric and adolescent patients were encouraging. Treatment success was 79.3 % (complete pain relief), hospital stay after coccygectomy was 1.44 ± 0.97 days, and return to normal activity was 24.68 ± 4.32 days. In the satisfaction questionnaire, 55 % of patients and parents were strongly satisfied, and 31 % were satisfied [45]. In the meta-analysis after coccygectomy for refractory coccydynia, trauma was the leading etiology (56 %), followed by idiopathic causes (33 %). Clinically significant change for pain was exceeded at each follow-up. The pooled complication incidence after coccygectomy was 8 % (95 % CI: 5 % to 12 %), and the pooled reoperation incidence was 3 % (95 % CI: 1 % to 5 %) [46].

The efficacy of current treatment options for patients with intractable coccydynia has been investigated in a systematic review. Andersen et al. [47] used the NRS (0–10) for pain in 1,980 pa-

tients. The treatments that best reduced pain scale scores were radiofrequency therapy (RFT, 5.11), extracorporeal shock wave therapy (ESWT, 5.06), coccygectomy (4.86), and injection (4.22). Despite improvement, the mean change was less for ganglion block (2.98), stretching or manipulation (2.19), and conservative or usual care (1.69).

Conclusion

Coccydynia is frequently overlooked in clinical practice, and its treatment is a stepwise process that begins with noninvasive techniques and ends with coccygectomy. Radiologists should not disregard the coccyx region and should be familiar with its morphologic appearance as well as the sacrococcygeal region's differential diagnosis.

Conflict of Interest

The authors declare that they have no conflict of interest.

References

- [1] White WD, Avery M, Jonely H et al. The interdisciplinary management of coccydynia: A narrative review. *Pm r* 2022; 14: 1143–1154. doi:10.1002/pmrj.12683
- [2] Lyon KA, Huang JH, Garrett D. Influence of psychiatric disorders and chronic pain on the surgical outcome in the patient with chronic coccydynia: a single institution's experience. *Neurol Res* 2020; 42: 789–794. doi:10.1080/01616412.2020.1775014
- [3] Neville CE, Carrubba AR, Li Z et al. Association of coccygodynia with pelvic floor symptoms in women with pelvic pain. *Pm r* 2022; 14: 1351–1359. doi:10.1002/pmrj.12706
- [4] Mabrouk A, Alloush A, Foye P. Coccyx Pain. In *StatPearls*. Treasure Island (FL): StatPearls Publishing Copyright © 2023, StatPearls Publishing LLC.; 2023
- [5] Jensen MM, Milosevic S, Andersen G et al. Factors associated with patient-reported outcomes following coccygectomy for chronic coccydynia. *Bone Jt Open* 2021; 2: 540–544. doi:10.1302/2633-1462.27.Bjo-2021-0018.R2
- [6] Skalski MR, Matcuk GR, Patel DB et al. Imaging Coccygeal Trauma and Coccydynia. *Radiographics* 2020; 40: 1090–1106. doi:10.1148/rg.2020190132
- [7] Garg B, Ahuja K. Coccydynia-A comprehensive review on etiology, radiological features and management options. *J Clin Orthop Trauma* 2021; 12: 123–129. doi:10.1016/j.jcot.2020.09.025
- [8] Foye PM, Abdelshahed DM, Kamrava E et al. Tailbone Pain from Coccyx Injuries on Water Slides: A Case Series. *J Emerg Med* 2018; 55: e33–e35. doi:10.1016/j.jemermed.2018.04.033
- [9] Foye PM, Singh R, Tangri V. Cerebrospinal fluid leak after fracture of the sacrum or coccyx. *Spine J* 2019; 19: 2044. doi:10.1016/j.spinee.2019.07.018
- [10] Maigne JY, Doursounian L, Jacquot F. Classification of fractures of the coccyx from a series of 104 patients. *Eur Spine J* 2020; 29: 2534–2542. doi:10.1007/s00586-019-06188-7
- [11] Panigrahi VP, Adsul N, Chahal RS et al. Traumatic posterior dislocation of sacrococcygeal joint: A case report and review of the literature. *Surg Neurol Int* 2020; 11: 197. doi:10.25259/sni_298_2020
- [12] Gupta V, Agarwal N, Baruah BP. Magnetic Resonance Measurements of Sacrococcygeal and Intercoccygeal Angles in Normal Participants and those with Idiopathic Coccydynia. *Indian J Orthop* 2018; 52: 353–357. doi:10.4103/ortho.IJOrtho_407_16
- [13] Ahadi T, Raissi GR, Hosseini M et al. A Randomized Clinical Trial on the Effect of Biofeedback on Pain and Quality of Life of Patients With Chronic Coccydynia. *Basic Clin Neurosci* 2020; 11: 753–763. doi:10.32598/bcn.11.6.1553.1
- [14] Guo F, Yang Z, Tang L et al. An intrapartum coccygeal fracture: An easily missed buttock pain. *Eur J Obstet Gynecol Reprod Biol* 2019; 236: 259–260. doi:10.1016/j.ajogrb.2019.03.027
- [15] Ranker A, Wegener B, Winkelmann A et al. [Undetected coccyx fracture in a woman with fibromyalgia]. *Schmerz* 2019; 33: 549–554. doi:10.1007/s00482-019-0392-0
- [16] Kumagai Y, Biyajima M, Shimizu I et al. Coccyx subluxation: Coccyx pain aggravated by the prone position. *J Gen Fam Med* 2022; 23: 409–410. doi:10.1002/jgf2.570
- [17] Anastasiadou S, Tekkis P, Kontovounisios C. An unusual rectal duplication cyst. *Surg Case Rep* 2019; 5: 75. doi:10.1186/s40792-019-0631-8
- [18] Mindaye ET, Kassahun M, Prager S et al. Adult case of giant sacrococcygeal teratoma: case report. *BMC Surg* 2020; 20: 295. doi:10.1186/s12893-020-00962-x
- [19] Porter ZR, Mejia-Munne JC, Krueger BM et al. Sacral Rheumatoid Nodule: An Unusual Indication for Coccygectomy. *Case Rep Surg* 2020; 2020: 2757625. doi:10.1155/2020/2757625
- [20] Rammos D, Chryssikos D, Giavopoulos P et al. Potential Anatomical Implications of Filum Terminale Paraganglioma on Coccygodynia: A Case Report. *Cureus* 2022; 14: e25308. doi:10.7759/cureus.25308
- [21] Dayawansa S, Garrett DJr., Wong M et al. Management of coccydynia in the absence of X-ray evidence: Case report. *Int J Surg Case Rep* 2019; 54: 63–65. doi:10.1016/j.ijscr.2018.11.043
- [22] Finsen V, Kalstad A, Knobloch RG. Normal Preoperative Images Do Not Indicate a Poor Outcome of Surgery for Coccydynia. *Spine (Phila Pa 1976)* 2020; 45: 1567–1571. doi:10.1097/brs.0000000000003642
- [23] Ersen O, Sir E, Eksert S et al. Pelvic Incidence as a Prognostic Factor in Coccydynia. *Turk Neurosurg* 2019; 29: 400–403. doi:10.5137/1019-5149.Jtn.24141-18.1
- [24] Guneri B, Gungor G. Morphological Features of the Coccyx in the Turkish Population and Interrelationships Among the Parameters: A Computerized Tomography-Based Analysis. *Cureus* 2021; 13: e19687. doi:10.7759/cureus.19687
- [25] Yagi F, Yamada Y, Yamada M et al. Three-dimensional evaluation of the coccyx movement between supine and standing positions using conventional and upright computed tomography imaging. *Scientific reports* 2021; 11: 6886. doi:10.1038/s41598-021-86312-0
- [26] Shams A, Gamal O, Mesregah MK. Sacrococcygeal Morphologic and Morphometric Risk Factors for Idiopathic Coccydynia: A Magnetic Resonance Imaging Study. *Global Spine J* 2023; 13: 140–148. doi:10.1177/2192568221993791
- [27] König MA, Grifka J, Benditz A. A novel radiological classification for displaced os coccyx: the Benditz-König classification. *Eur Spine J* 2022; 31: 10–17. doi:10.1007/s00586-021-06971-5
- [28] Ghai A, Jangra P, Wadhwa S et al. A prospective study to evaluate the efficacy of ultrasound-guided ganglion impar block in patients with chronic perineal pain. *Saudi J Anaesth* 2019; 13: 126–130. doi:10.4103/sja.SJA_667_18
- [29] Sencan S, Kenis-Coskun O, Demir FGU et al. Ganglion Impar block improves neuropathic pain in coccygodynia: A preliminary report. *Neurol Neurochir Pol* 2018; 52: 612–617. doi:10.1016/j.pjnns.2018.08.006
- [30] Kircelli A, Demirçay E, Özel Ö et al. Radiofrequency Thermocoagulation of the Ganglion Impar for Coccydynia Management: Long-Term Effects. *Pain Pract* 2019; 19: 9–15. doi:10.1111/papr.12698
- [31] Kuek DKC, Chung SL, Zishan US et al. Conus infarction after non-guided transcoccygeal ganglion impar block using particulate steroid for chronic coccydynia. *Spinal Cord Ser Cases* 2019; 5: 92. doi:10.1038/s41394-019-0237-1
- [32] Sencan S, Edipoglu IS, Ulku Demir FG et al. Are steroids required in the treatment of ganglion impar blockade in chronic coccydynia? a prospective double-blinded clinical trial. *Korean J Pain* 2019; 32: 301–306. doi:10.3344/kjp.2019.32.4.301
- [33] Choudhary R, Kunal K, Kumar D et al. Improvement in Pain Following Ganglion Impar Blocks and Radiofrequency Ablation in Coccygodynia Patients: A Systematic Review. *Revista brasileira de ortopedia* 2021; 56: 558–566. doi:10.1055/s-0041-1735829
- [34] Kim CS, Jang K, Leem JG et al. Factors associated with Successful Responses to Ganglion Impar Block: A Retrospective Study. *Int J Med Sci* 2021; 18: 2957–2963. doi:10.7150/ijms.60962
- [35] Malhotra N, Goyal S, Kumar A et al. Comparative evaluation of transsacrococcygeal and transcoccygeal approach of ganglion impar block for management of coccygodynia. *J Anaesthesiol Clin Pharmacol* 2021; 37: 90–96. doi:10.4103/joacp.JOACP_588_20

- [36] Celenlioglu AE, Sir E. Predictive factors affecting treatment success in ganglion impar block applied in chronic coccygodynia. *Reg Anesth Pain Med* 2022. doi:10.1136/rapm-2022-103582
- [37] Seker A, Sarikaya IA, Korkmaz O et al. Management of persistent coccydynia with transrectal manipulation: results of a combined procedure. *Eur Spine J* 2018; 27: 1166–1171. doi:10.1007/s00586-017-5399-6
- [38] Wu WT, Hsu YC, Chang KV et al. Ultrasound Imaging and Ultrasound-Guided Injection of the Coccygeal Nerve for Coccydynia. *Am J Phys Med Rehabil* 2022; 101: e108–e109. doi:10.1097/phm.0000000000001987
- [39] Sarmast AH, Kirmani AR, Bhat AR. Coccygectomy for Coccygodynia: A Single Center Experience Over 5 Years. *Asian J Neurosurg* 2018; 13: 277–282. doi:10.4103/1793-5482.228568
- [40] Kalstad AM, Knobloch RG, Finsen V. The treatment of coccydynia in adolescents: A case-control study. *Bone Jt Open* 2020; 1: 115–120. doi:10.1302/2633-1462.15.Bjo-2020-0017
- [41] Charrière S, Maigne JY, Couzi E et al. Conservative treatment for chronic coccydynia: a 36-month prospective observational study of 115 patients. *Eur Spine J* 2021; 30: 3009–3018. doi:10.1007/s00586-021-06911-3
- [42] Hochgatterer R, Gahleitner M, Allerstorfer J et al. Coccygectomy for coccygodynia: a cohort study with a long-term follow-up of up to 29 years. *Eur Spine J* 2021; 30: 1072–1076. doi:10.1007/s00586-020-06627-w
- [43] Milosevic S, Andersen G, Jensen MM et al. The efficacy of coccygectomy in patients with persistent coccydynia. *Bone Joint J* 2021; 103-b: 542–546. doi:10.1302/0301-620x.103b3.Bjj-2020-1045.R2
- [44] Kalstad AM, Knobloch RG, Finsen V. Coccygectomy in the Treatment of Chronic Coccydynia. *Spine (Phila Pa 1976)* 2022; 47: E442–E447. doi:10.1097/brs.0000000000004209
- [45] Shalaby MM. The Surgical Role in the Management of Persistent Coccygodynia in Adolescent and Pediatric Patients: A Retrospective Case Series. *Hss j* 2022; 18: 110–115. doi:10.1177/1556331621991498
- [46] Sagoo NS, Haider AS, Palmisciano P et al. Coccygectomy for refractory coccygodynia: a systematic review and meta-analysis. *Eur Spine J* 2022; 31: 176–189. doi:10.1007/s00586-021-07041-6
- [47] Andersen G, Milosevic S, Jensen MM et al. Coccydynia-The Efficacy of Available Treatment Options: A Systematic Review. *Global Spine J* 2022; 12: 1611–1623. doi:10.1177/21925682211065389