

# Management of Deep Vein Thrombosis: An Update Based on the Revised AWMF S2k Guideline

Birgit Linnemann<sup>1</sup> Jan Beyer-Westendorf<sup>2</sup> Christine Espinola-Klein<sup>1</sup> Katja S. Mühlberg<sup>3</sup>  
Oliver J. Müller<sup>4</sup> Robert Klamroth<sup>5</sup>

<sup>1</sup> Cardiology III – Angiology, Department of Cardiology, University Medical Center of the Johannes Gutenberg University Mainz, Mainz, Germany

<sup>2</sup> Thrombosis Research Unit, Division of Haematology, Department of Medicine I, Carl Gustav Carus University Hospital, University Hospital Carl-Gustav Carus, Dresden, Germany

<sup>3</sup> Department of Angiology, University Hospital Leipzig, Leipzig, Germany

<sup>4</sup> Department of Internal Medicine III, University Hospital Schleswig - Holstein, Campus Kiel, Kiel, Germany

<sup>5</sup> Department of Internal Medicine, Angiology and Haemostaseology, Vivantes Klinikum im Friedrichshain, Berlin, Germany

**Address for correspondence** Prof. Dr. med. Birgit Linnemann, Zentrum für Kardiologie, Kardiologie III – Angiologie, Universitätsmedizin der Johannes-Gutenberg-Universität Mainz, Langenbeckstraße 1, 55131 Mainz, +Deutschland (e-mail: Birgit.Linnemann@unimedizin-mainz.de).

Hamostaseologie 2024;44:97–110.

## Abstract

Deep vein thrombosis (DVT) and pulmonary embolism (PE) are the most common manifestations of venous thromboembolism (VTE). Most DVTs affect the lower-extremity veins. Since the symptoms of DVT are non-specific, a prompt and standardised diagnostic work-up is essential to minimise the risk of PE in the acute phase and to prevent thrombosis progression, post-thrombotic syndrome and VTE recurrence in the long-term. Only recently, the AWMF S2k guidelines on Diagnostics and Therapy of Venous Thrombosis and Pulmonary Embolism have been revised. In the present article, we summarize current evidence and guideline recommendations focusing on lower-extremity DVT (LEDVT). Depending on whether the diagnostic work-up is performed by a specialist in vascular medicine or by a primary care physician, different diagnostic algorithms are presented that combine clinical probability, D-dimer testing and diagnostic imaging. The diagnosis of ipsilateral recurrent DVT poses a particular challenge and is presented in a separate algorithm. Anticoagulant therapy is an essential part of therapy, with current guidelines clearly favouring regimens based on direct oral anticoagulants over the traditional sequential therapy of parenteral anticoagulants and vitamin K antagonists. For most DVTs, a duration of therapeutic-dose anticoagulation of at least 3 to 6 months is considered sufficient, and this raises the question of the risk of VTE recurrence after discontinuation of anticoagulation and the need for secondary prophylaxis in the long-term. Depending on the circumstances and trigger factors that have contributed to the occurrence of DVT, management strategies are presented that allow decision-making taking into account the individual bleeding risk and patient's preferences.

## Keywords

- ▶ anticoagulant therapy
- ▶ deep vein thrombosis
- ▶ secondary prophylaxis
- ▶ venous duplex ultrasonography
- ▶ venous thromboembolism

received  
August 20, 2023  
accepted after revision  
September 19, 2023

© 2024. Thieme. All rights reserved.  
Georg Thieme Verlag KG,  
Rüdigerstraße 14,  
70469 Stuttgart, Germany

DOI <https://doi.org/10.1055/a-2178-6574>.  
ISSN 0720-9355.

Deep vein thrombosis (DVT) and pulmonary embolism (PE) are the most common manifestations of the same disease entity – venous thromboembolism (VTE). In clinical practice, about two-thirds of VTE events manifest as DVT and one-third are detected when patients present with symptoms suggestive of PE. Autopsy studies, on the other hand, indicate that DVT and PE events occur with comparable frequency indicating that many PE events remain undiagnosed before death.<sup>1,2</sup>

Most DVTs affect the lower-extremity veins. From an anatomical and prognostic point of view, a distinction is made between thromboses affecting the deep veins and thromboses in the epifascial venous system (superficial vein thrombosis [SVT]). This review will focus on DVT, as its various forms are of particular clinical relevance. The different vein segments are involved in the thrombosis process with different frequencies. Thromboses that are limited to the distal or lower leg veins account for ~40% of cases, while the popliteal veins are affected in 16% and the femoral veins are involved in 20%. Thrombosis involving the iliac veins occurs in 4% of cases.<sup>3</sup>

After DVT, the affected veins often recanalise incompletely, leaving post-thrombotic residuals in 30 to 80% of cases, which are associated with venous valve insufficiencies and increase the risk of DVT recurrence. The clinical picture of post-thrombotic syndrome (PTS) develops in ~30% of cases.<sup>4</sup> This is especially true for extensive proximal thromboses involving the iliac veins. About 1 to 5% of all patients develop severe PTS or chronic venous leg ulcers after DVT.<sup>4,5</sup>

## Diagnostic Algorithms of Suspected DVT

Diagnostic procedures initiated immediately with the clinical suspicion of DVT are essential to confirm or exclude thrombosis and to lower the risk of complications in the acute phase and in the long term. Early initiation of anticoagulant therapy interrupts appositional thrombus growth, facilitates subsequent recanalisation and reduces the risk of embolisation. On the other hand, a falsely diagnosed thrombosis leads to unnecessary treatment with the associated (bleeding) risks. Since clinical symptoms and signs are unspecific and therefore uncertain, a validated diagnostic procedure is required. In recent years, diagnostic algorithms have been established for the diagnosis of DVT, which takes into account clinical pre-test probability, the results of D-dimer testing and diagnostic imaging.

According to the revised AWMF S2k guideline on “Diagnostics and Therapy of Venous Thrombosis and Pulmonary Embolism,” venous duplex ultrasonography (VDUS) is considered the method of first choice for the detection of DVT and should therefore – if timely available – primarily be used in cases of suspected DVT.<sup>6</sup> VDUS includes complete compression ultrasonography (CCUS) of the deep veins of the upper and lower leg and the derivation of a Doppler flow profile of the common femoral vein in side-by-side comparison – the latter to identify or exclude venous outflow obstruction in the iliac and caval veins (–Fig. 1). According to meta-analyses, the diagnostic failure rate of an ultrasound

examination as a standalone test is 0.3 to 1% when considering a follow-up period of 3 months.<sup>7–9</sup> The most important prerequisite for a meaningful ultrasonography is a careful, standardised examination including the veins of the lower leg by an appropriately trained and experienced examiner and the documentation of the findings in written and pictorial form. If DVT is proven in the symptomatic leg, the other leg should also be examined sonographically, as bilateral thromboses occur in ~5 to 10% of cases.<sup>6</sup>

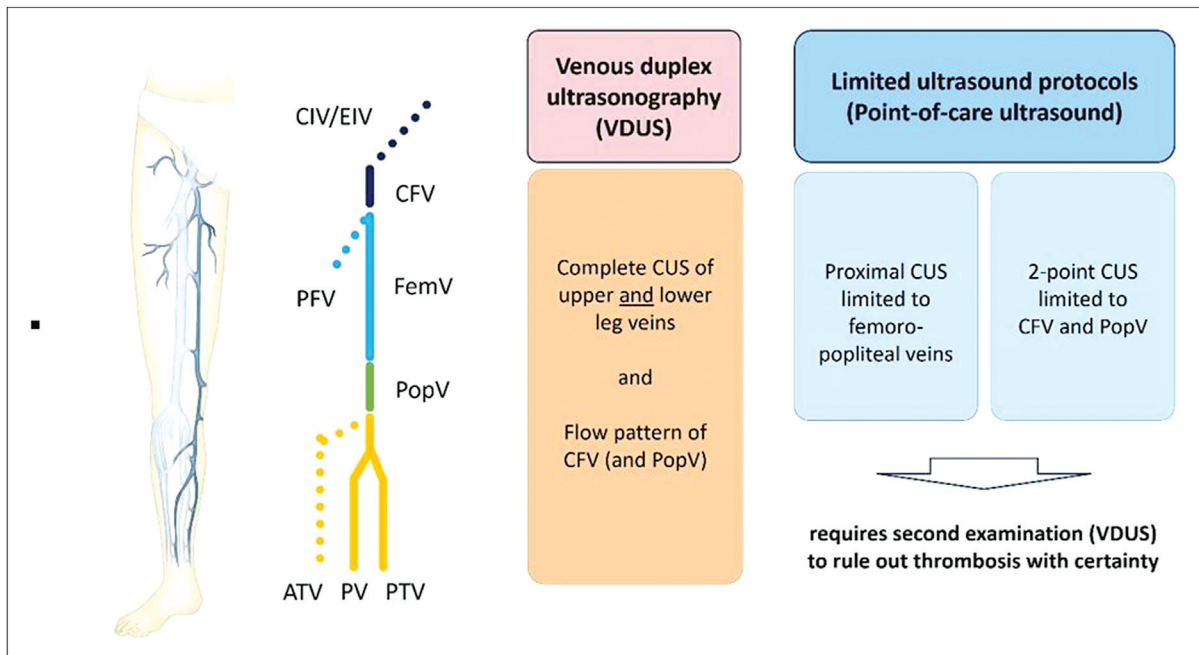
If the sonographic findings are unclear, a D-dimer test should be performed. If the D-dimers are normal, clinically relevant thrombosis requiring anticoagulant therapy can be ruled out. If, on the other hand, the D-dimers are elevated in the case of non-conclusive ultrasound findings, either a sonographic follow-up should be performed within the next 4 to 7 days or alternative imaging (e.g., MR or indirect CT venography) should be sought (–Fig. 2).

If a complete VDUS scan of the leg veins is not timely available or feasible, clinical probability (e.g., 2-stage Wells score), D-dimer testing and limited ultrasound protocols should be used as a first approach (–Fig. 3). In the context of a low clinical pre-test probability, the D-dimer test is able to identify patients who do not require diagnostic imaging. Normal D-dimers allow exclusion of DVT with a negative predictive value of more than 95%, when the clinical probability is low. A quantitative, high-sensitivity D-dimer test should be used whenever possible. For the majority of tests, a threshold value of 500 µg/L is used.<sup>10</sup> However, it should be noted that in rare cases, false-negative D-dimers can occur in low thrombus burden, in symptoms that have been present for weeks or months and in patients who have already been treated with anticoagulants.<sup>11</sup>

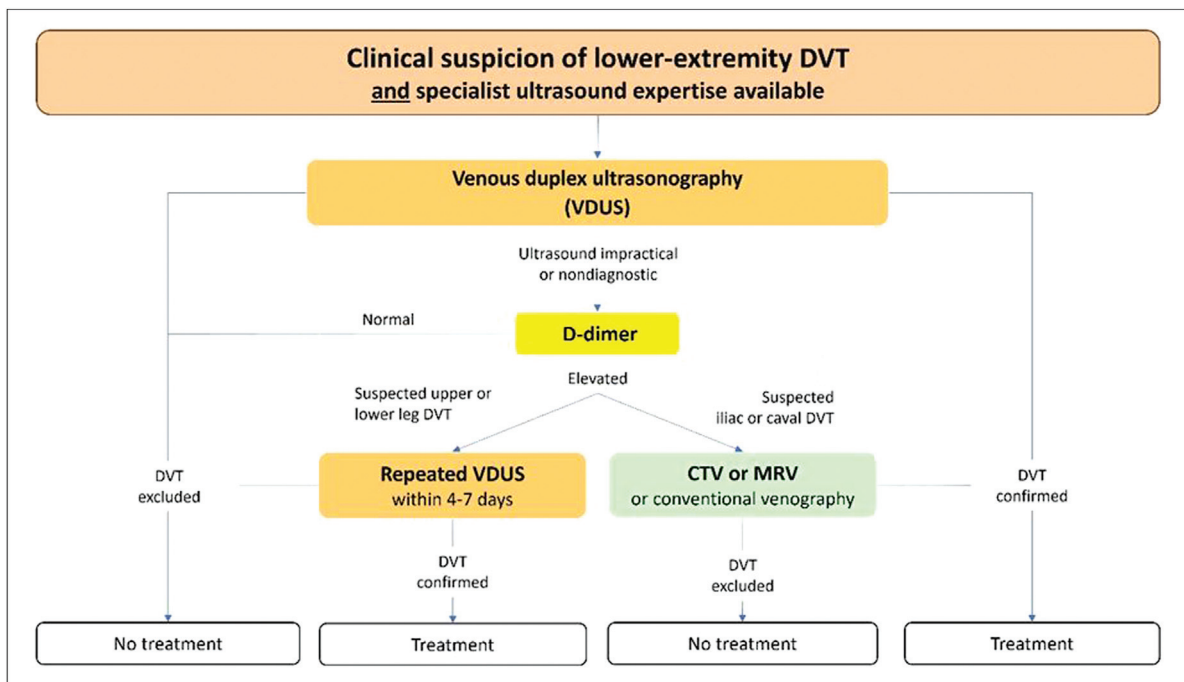
As the D-dimers physiologically increase with age, the use of an age-adjusted cut-off value in patients over the age of 50 (i.e., patient age × 10 µg/L) can limit the number of unnecessary ultrasound examinations.<sup>12</sup> Alternatively, the decision limits of D-dimer testing can be adjusted to the clinical probability.<sup>13</sup> The direct comparison of an age-adjusted D-dimer limit with a decision limit adjusted to the clinical probability resulted in a high negative predictive value (99.8%) for both methods. Relevant differences with regard to sensitivity or specificity could not be derived, so that the two interpretation strategies can be considered equally reliable.<sup>14</sup>

In patients with a high clinical pre-test probability, D-dimer testing is not useful, as imaging cannot be dispensed even if the D-dimers are normal. Therefore, if the clinical probability is high or if a non-specific increase in D-dimer is to be expected (e.g., previous surgery or trauma, underlying malignant disease, infection, inflammation or pregnancy), a sonographic examination should be the first diagnostic test. If VDUS is not available or feasible, a point-of-care ultrasound (POCUS) protocol limiting the examination to the femoropopliteal veins can be used (–Fig. 1). If DVT is detected, the patient is referred to appropriate therapy; if DVT is not proven, anticoagulation should be avoided and VDUS should be completed within the next 7 days (–Fig. 3).

The different approaches to diagnose or exclude DVT reflect the different situations in which patients with



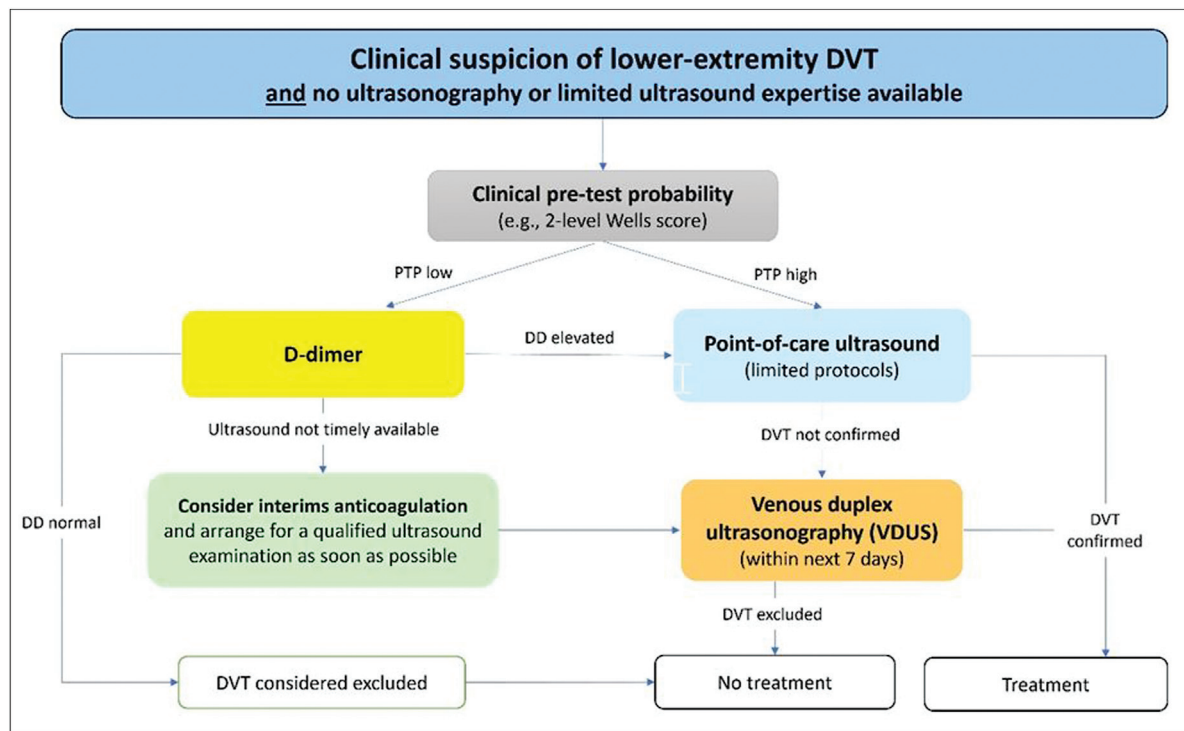
**Fig. 1** Ultrasound protocols for the diagnosis of lower-extremity DVT. ATV, anterior tibial vein; CUS, compression ultrasound; CFV, common femoral vein; CIV, common iliac vein; EIV, external iliac vein; FemV, femoral vein; PFV, profunda femoris vein; PopV, popliteal vein; PTV, posterior tibial vein; PV, peroneal vein; VDUS, venous duplex ultrasonography.



**Fig. 2** Diagnostic algorithm for suspected lower-extremity DVT. CTV, computed tomography venography; DVT, deep vein thrombosis; MRV, magnetic resonance venography; VDUS, venous duplex ultrasonography.

suspected DVT present. The initial assessment of clinical probability followed by D-dimer testing does not require ultrasound equipment or expertise and can mainly be applied by general practitioners or primary care physicians, whereas confirmation or exclusion of DVT using ultrasound techniques is usually performed by physicians specialized in vascular medicine or working in emergency departments.

Due to the potentially life-threatening complication of PE, any clinical suspicion of DVT must be clarified promptly to the extent that a safe therapeutic decision can be made. If ultrasound diagnostics cannot be performed promptly, the initiation of provisional therapeutic anticoagulation should be considered in cases of high clinical probability and/or elevated D-dimers until definitive clarification, provided the



**Fig. 3** Alternative diagnostic algorithm for suspected DVT when specialist ultrasound expertise is not immediately available. DD, D-dimer; DVT, deep vein thrombosis; PTP, pre-test probability; VDUS, venous duplex ultrasonography.

individual bleeding risk is acceptable and there are no contraindications.

### Diagnostic Approach in Suspected Recurrent DVT

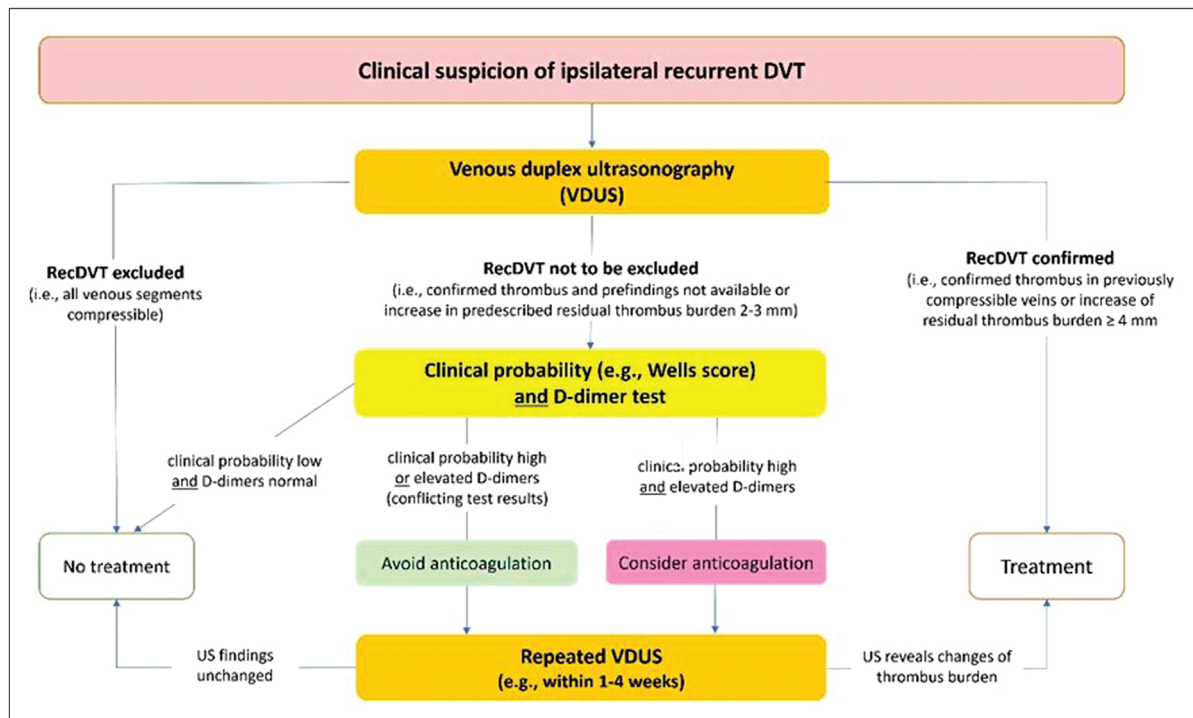
After discontinuation of anticoagulation for unprovoked VTE, ~25% of patients experience VTE recurrence within 5 years and 30 to 40% within 10 years.<sup>15</sup> Thus, the question of DVT recurrence arises frequently when unilateral leg swelling and/or leg pain occur again. After an initial VTE, residual thrombus burden, clinical symptoms of PTS and the patient's higher awareness of symptoms may often lead to the suspicion of recurrent DVT, necessitating a validated diagnostic approach to differentiate between residual venous obstruction and thrombosis recurrence.

Study data suggest that the classical diagnostic algorithm of pre-test probability and D-dimer testing may have insufficient certainty in cases with suspected recurrent DVT.<sup>16</sup> As previous VTE are included in the pre-test probability, the clinical probability will almost always be high. At the same time, post-thrombotic residuals impair the diagnostic reliability of ultrasound if ipsilateral recurrent DVT is suspected.<sup>17</sup> Of note, there are no sonographic criteria that can reliably distinguish between acute thrombosis and post-thrombotic residuals. A diagnosis of recurrent DVT solely on the basis of sonomorphological criteria or different echogenicity of non-compressible vein segments is therefore not allowed.<sup>18</sup>

However, a recurrence of DVT can be reliably diagnosed if thrombi are detected in venous vessel segments that were

not affected by the initial thrombosis or for which complete recanalisation was documented in the course after a previous DVT. If a previously documented residual thrombus has clearly increased in thickness, DVT recurrence can also be assumed.<sup>19,20</sup> The increase by  $\geq 4$  mm in the anterior-posterior diameter within the femoropopliteal veins also allows the diagnosis of recurrent DVT. In contrast, using an increase in residual thrombus burden of 2 to 3 mm, the diagnosis of recurrence was uncertain. In clinical practice, the problem often arises that well-documented previous findings are missing, which limits the significance of sonography. It should therefore be mandatory that all DVT patients undergo a follow-up ultrasound examination with detailed documentation of residual thrombus burden when anticoagulation is discontinued.

Due to the limitations of ultrasonography described above, D-dimer testing should be performed when recurrent DVT is suspected, regardless of the pre-test probability. Normal D-dimers and unchanged ultrasound findings compared with the previous examination make a recurrence of DVT unlikely. Elevated D-dimers do not prove thrombosis but can still help to assess the situation in the context of clinical and ultrasound findings.<sup>21,22</sup> If DVT recurrence cannot be confirmed, the initial findings should preferably remain untreated and a sonographic follow-up with repeated D-dimer determination should be performed within the next 4 to 7 days. In the case of acute recurrent DVT requiring anticoagulation, it can be expected that ultrasound findings and/or D-dimers change during this period, while stable findings in the follow-up make acute DVT unlikely. In justified individual cases (i.e., with high clinical suspicion and/or



**Fig. 4** Diagnostic algorithm for suspected recurrent ipsilateral lower extremity DVT. DVT, deep vein thrombosis; recDVT, recurrent deep vein thrombosis; US, ultrasound; VDUS, venous duplex ultrasonography.

suggestive sonographic findings and elevated D-dimers), it may, on the other hand, make sense to initially restart therapeutic anticoagulation for a limited period of time and to decide on the further course of action within the framework of a clinical, laboratory and sonographic follow-up (e.g., after 1–4 weeks; **Fig. 4**).<sup>6</sup>

Magnetic resonance (MR) examination techniques such as MR direct thrombus imaging can also be used to differentiate between acute ipsilateral recurrent thrombosis and residuals of a previous DVT.<sup>23</sup> However, this method has not yet been widely used.

## Treatment of Lower-Extremity DVT

### General Considerations

In recent decades, the treatment of DVT patients has increasingly shifted from inpatient to outpatient care. However, hospital admission and treatment is indicated if early revascularization is to be performed due to severe leg symptoms caused by extensive DVT involving the iliac veins or inferior vena cava. In cases of severe venous stasis symptoms, symptomatic PE, high risk of bleeding or active bleeding, severe renal or hepatic insufficiency and/or co-existing pregnancy, primary hospital treatment may also be appropriate. Thrombosis progression or the occurrence of DVT recurrence despite adequate anticoagulation can also be a reason for inpatient treatment. This is especially true if the patient is being treated with heparins and heparin-induced thrombocytopenia (HIT) is suspected.

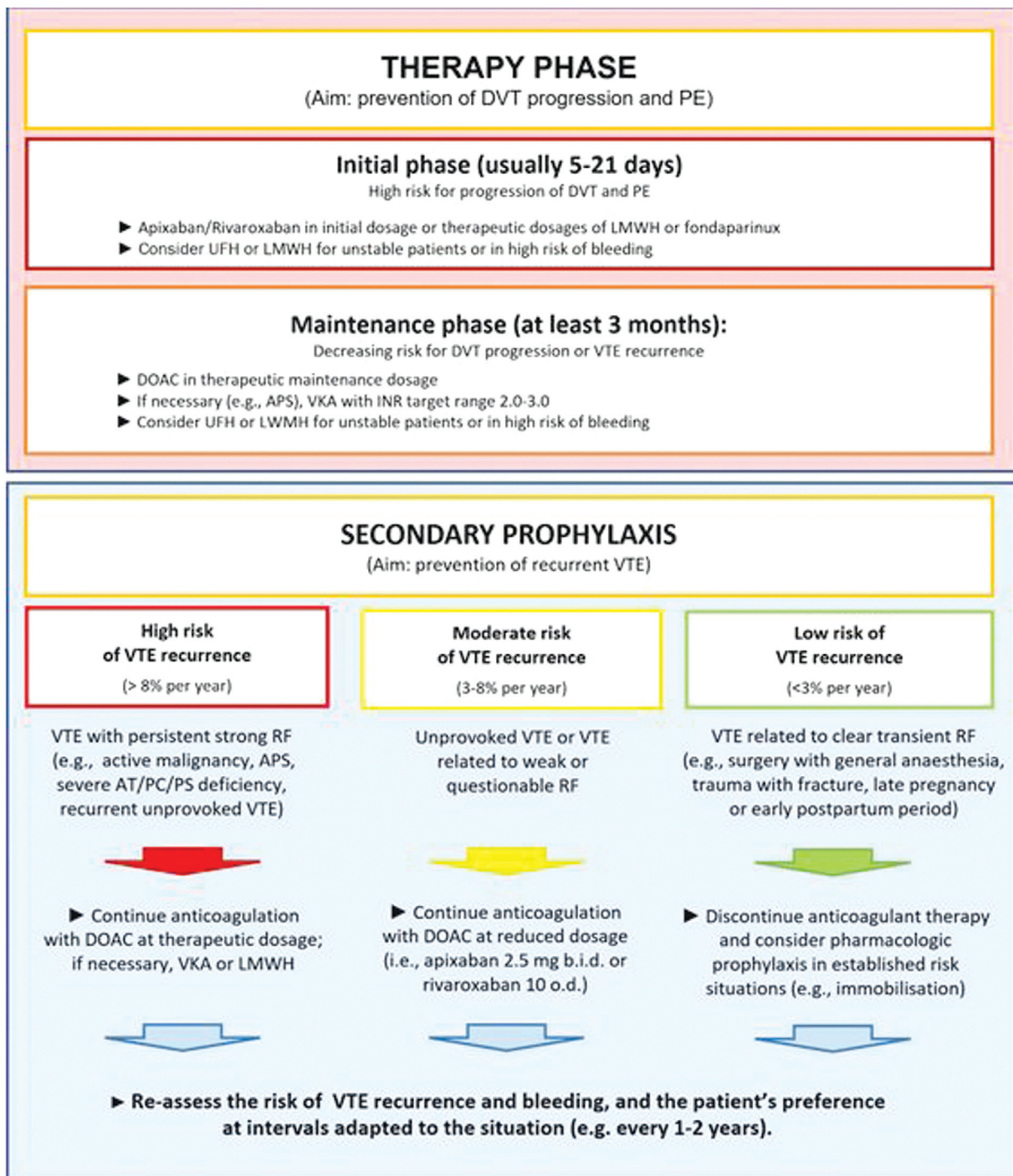
The primary objective of treatment in the acute phase of DVT is to prevent thrombus growth and to reduce the risk of

PE. With the initiation of anticoagulant therapy, the risk of PE and recurrent thrombosis decreases.<sup>24</sup> Early initiation of treatment also reduces the incidence and severity of PTS.<sup>25–27</sup> With the rapid onset of action of modern anticoagulants, many patients can be treated on an outpatient basis, reducing the need for hospital admissions to the few cases described above.

### Initial and Maintenance Anticoagulant Therapy

After the diagnosis of DVT has been confirmed, anticoagulation in therapeutic dosage should be initiated without delay. Of note, a distinction has to be made between initial and maintenance therapy (**Fig. 5**). This is due to the different approval situations of the individual anticoagulants. In the initial phase, which usually covers the first 5 to 21 days, parenteral anticoagulants or higher dosages of oral anticoagulants are used to counter-balance an excess complication risk in the acute phase of VTE. Thereafter, the therapeutic dosage for the maintenance phase is used for at least 3 to 6 months and can be prolonged in individual cases with high thrombus burden. Of note, the choice of anticoagulant for maintenance therapy determines the type, intensity and duration during the initial treatment phase. At the end of the maintenance phase, a decision must be made as to whether a continuation of anticoagulation – and if so, at what dosage – is necessary for the efficient prevention of recurrent VTE or whether anticoagulation can be discontinued.

The revised AWMF S2k guideline recommends that for the treatment of VTE, a regimen with a direct oral anticoagulant (DOAC) should be preferred over the traditional therapy with



**Fig. 5** Treatment phases of VTE and anticoagulant strategies. APS, antiphospholipid syndrome; AT, antithrombin; DOAC, direct oral anticoagulant; DVT, deep vein thrombosis; INR, international normalised ratio; LMWH, low-molecular-weight heparin; PE, pulmonary embolism; PC, protein C; PS, protein S; RF, risk factor; UFH, unfractionated heparin; VKA, vitamin K antagonist; VTE, venous thromboembolism.

a vitamin K antagonist (VKA), provided that there are no substance-specific contraindications (e.g., severe renal insufficiency, antiphospholipid syndrome, pregnancy).<sup>6</sup> Large randomized controlled trials (RCTs) showed non-inferiority for apixaban, dabigatran, edoxaban and rivaroxaban compared with traditional therapy with low-molecular-weight heparin (LMWH) or fondaparinux followed by VKA.<sup>28-33</sup> Meta-analyses confirmed a comparable efficacy in the prevention of VTE recurrences for the entire group of DOACs and

showed a significant reduction of major bleeding by ~40% compared with VKAs.<sup>34,35</sup>

If apixaban and rivaroxaban are selected for maintenance therapy, anticoagulation can be started directly orally, with higher doses being administered in the initial phase (▶ **Table 1**). If maintenance therapy with dabigatran, edoxaban or VKA is intended, initial treatment with parenteral anticoagulants, preferably LMWH or fondaparinux, is required. The use of unfractionated heparin (UFH) today is

**Table 1** Treatment of acute VTE with oral anticoagulants

	Initial therapy	Maintenance therapy	No need for dose adjustment for renal function required
<i>DOAC-based regimen</i>			
Apixaban	10 mg twice daily for 7 d	5 mg twice daily	GFR $\geq$ 15 mL/min
Dabigatran	LMWH, FDX, or UFH at therapeutic dosage for $\geq$ 5 d	150 mg twice daily	GFR $\geq$ 30 mL/min
Edoxaban	LMWH, FDX, or UFH at therapeutic dosage for $\geq$ 5 d	60 mg once daily	GFR $\geq$ 50 mL/min
Rivaroxaban	15 mg twice daily for 21 d	20 mg once daily	GFR $\geq$ 15 mL/min
<i>VKA-based regimen</i>			
Phenprocoumon	6 mg (2 tbl.) on days 1 and 2, overlapping LMWH, FDX, or UFH at therapeutic dosage up to INR $\geq$ 2	Individual dosage (INR target range 2.0–3.0)	Standard of care for CKD stages 4 and 5, although contraindicated in manifest renal failure according to the SmPC
Warfarin	2.5–5 mg on days 1 and 2, overlapping LMWH, FDX, or UFH at therapeutic dosage up to INR $\geq$ 2		

Abbreviations: DOAC, direct oral anticoagulant; FDX, fondaparinux; GFR, glomerular filtration rate; INR, international normalised ratio; LMWH, low-molecular-weight heparin; SmPC, summary of product characteristics; Tbl., tablet; UFH, unfractionated heparin; VTE, venous thromboembolism. Notes: The table is intended to provide guidance. In addition, the manufacturer's SmPCs must be observed, especially with regard to necessary dose reductions or contraindications in special risk groups.

almost exclusively limited to patients with severe renal failure, when LMWH, fondaparinux and most oral anticoagulants are contraindicated. UFH is also used when a short half-life anticoagulant is desirable (e.g., haemodynamically unstable patient, increased risk of bleeding).

### Compression Therapy

According to a Cochrane review, compression therapy reduces the incidence of PTS (relative risk [RR]: 0.62; 95% confidence interval [CI]: 0.38–1.01).<sup>25</sup> No reduction in severe PTS (RR: 0.78; 95% CI: 0.53–1.15) or in the risk of recurrent thrombosis (RR: 0.94; 95% CI: 0.69–1.28) could be demonstrated. However, the overall study quality is rated as low. In some RCTs, however, the incidence of PTS after proximal DVT was halved.<sup>26,36,37</sup> The prerequisite for the efficacy of compression is the early start of therapy immediately with the diagnosis of the DVT and the consistent application of the compression.<sup>26,38,39</sup>

Both medical compression stockings and compression bandages are used and, correctly applied, are considered equally effective. In patients with severe leg swelling in the acute phase, it may be advantageous to start compression therapy with bandages and fit a compression stocking after the swelling has subsided. Compression therapy is indicated exclusively for the leg affected by DVT. Compression of both legs after PE without evidence of DVT does not appear to be useful. Thigh-length compression stockings are no more effective than calf compression stockings in preventing PTS.<sup>40</sup> Therefore, if the swelling is limited to the lower leg, a calf compression stocking or the application of a compression bandage up to the knee is usually sufficient. After 3 to 6 months, the indication for continuing compression therapy

after DVT should be reviewed on the basis of clinical complaints. Multicentre RCTs have shown that an individualised compression duration, adapted to the patient's complaints, is not inferior to a fixed therapy duration of 2 years.<sup>41</sup>

### Endovenous or Surgical Revascularisation

Phlegmasia cerulea dolens is a very rare vascular emergency in which a massive thrombosis leads to a complete obstruction of the venous outflow of a leg with the risk of compartment syndrome, acute limb ischaemia and venous gangrene. In these cases, immediate venous recanalisation with the aim of limb preservation is clearly indicated.<sup>42</sup> The choice of procedure – endovascular or open surgery – should be made on an interdisciplinary basis and depends on the overall clinical situation and the specialist's expertise on site.

Endovascular recanalisation for acute DVT can also be considered in patients with proximal thrombosis involving the iliac veins who are at high risk for developing PTS.<sup>6</sup> This is particularly true for patients with descending iliofemoral DVT and severe venous stasis symptoms, provided the clinical symptoms do not persist for more than 14 days and the risk of bleeding is low.

However, available data do not indicate a reduction in mortality, risk of PE or recurrent VTE, or improvement in quality of life. A recent Cochrane review analysed data on catheter-directed thrombolysis with and without the use of other endovascular procedures from 19 trials with a total of 1,943 patients.<sup>43</sup> The use of thrombolytics resulted in a higher rate of complete recanalisation (RR: 2.42; 95% CI: 1.42–4.12), but the risk of bleeding complications was increased (6.7 vs. 2.2%; RR: 2.45; 95% CI: 1.58–3.78). Over an observation period of 6 months to 5 years, the difference

with regard to the development of a PTS was only small (49.6% with endovenous treatment and 52.8% with anticoagulation alone; RR: 0.78; 95% CI: 0.66–0.93). When only the three most recent RCTs (CaVenT, ATTRACT, CAVA) were pooled, there was no significant advantage for catheter-directed thrombolysis in combination with endovascular procedures with regard to the development of PTS or venous ulceration. Due to weaknesses in the study design, it is not possible to draw a final conclusion.

### Prognosis after DVT and Aftercare

In the first few weeks after initiating therapy, a clinical follow-up should be performed to review the patient's complaints and the implementation, effectiveness and safety of therapeutic measures. Sonographic control is necessary only if there is a clinical suspicion of thrombosis progression or in the absence of clinical improvement.<sup>6</sup>

At follow-up visits, a clinical examination should be performed to detect signs of venous insufficiency or PTS. If there is persistent swelling or an increase in the circumference of the limb, compression therapy should be continued or intensified if necessary. At the end of the maintenance phase, the question arises as to whether anticoagulation should be discontinued or – in the case of a high risk of recurrence – continued. As mentioned earlier, an ultrasound examination with documentation of residual thrombi should be mandatory if anticoagulation is discontinued.

If prolonged or indefinite anticoagulation is indicated for secondary prophylaxis, regular follow-up visits (e.g., every 1–2 years) should be planned for re-evaluation, which should include the question of recurrent thromboembolism, bleeding complications, comorbidities, co-medications and adherence to therapy. Regular monitoring of routine blood parameters (e.g., blood cell count, liver enzymes,

creatinine/glomerular filtration rate) under continued anticoagulation is recommended, especially in the elderly and in impaired renal function.

### Secondary Prophylaxis after VTE

In recent years, an anticoagulation duration of at least 3 months has been established in all relevant guidelines for patients with LEDVT as well as for patients with PE.<sup>6,44,45</sup> After 3 to 6 months, LEDVT and/or PE have usually been adequately treated, and thus the therapy phase – initial and maintenance therapy – is considered completed. Extensive VTE is often treated for longer (e.g., up to 12 months) in clinical practice, especially if a high residual thrombus burden is still detectable.<sup>17,46</sup>

The decision to continue or discontinue anticoagulant therapy beyond the maintenance phase depends largely on the estimated risk of VTE recurrence. If the decision is made for an indefinite therapy, the individual risk of bleeding under continued anticoagulation and the patient's preferences and concerns should also be taken into account.

### Risk of VTE Recurrence

In unselected VTE cohorts, the cumulative risk of recurrence after cessation of anticoagulation is 6.3% at 3 months, 8.0% at 6 months, 13% at 1 year, 23% at 5 years and 30% at 10 years.<sup>47</sup> Numerous factors influence the risk of recurrence to varying degrees (–Table 2). In addition to the patient's own risk factors (age, sex, thrombophilia), the characteristics of the previous VTE (localisation, extent, trigger, clinical course, long-term consequences), concomitant diseases (e.g., malignancy, infection, autoimmune disease) and co-medications (e.g., estrogens) must be taken into account. Furthermore, there may be additional risk-increasing concomitant circumstances (e.g., obesity, varicosis, frequent

**Table 2** Established risk factors for developing a first VTE stratified according to the extent of risk increase

Strong risk factors (OR ≥ 10)	Moderate risk factors (OR 2–9)	Weak risk factors (OR < 2)
<ul style="list-style-type: none"> <li>- Previous VTE</li> <li>- Trauma with leg fracture</li> <li>- Hip or knee replacement</li> <li>- Major trauma</li> <li>- Spinal cord injury</li> <li>- Myocardial infarction (in the previous 3 mo)</li> <li>- Hospitalisation for heart disease or atrial fibrillation/ flutter (in the previous 3 mo)</li> </ul>	<ul style="list-style-type: none"> <li>- Hormonal treatment containing estrogens (e.g., COC, HRT, IVF)</li> <li>- 3rd trimester pregnancy</li> <li>- Postpartum period</li> <li>- Active malignancy</li> <li>- Central venous catheters and devices</li> <li>- Chemotherapy</li> <li>- Autoimmune disorders</li> <li>- Inflammatory bowel disease</li> <li>- Systemic infection (e.g., pneumonia, urinary tract infection, HIV)</li> <li>- Heart failure or respiratory insufficiency</li> <li>- Stroke with paralysis</li> <li>- Arthroscopic knee surgery</li> <li>- Superficial venous thrombosis</li> <li>- Hereditary or acquired thrombophilia</li> <li>- Erythropoiesis-stimulating agents</li> </ul>	<ul style="list-style-type: none"> <li>- Bed rest ≥ 3 d</li> <li>- Diabetes mellitus</li> <li>- Arterial hypertension</li> <li>- Immobility due to sitting (e.g., long-distance travel)</li> <li>- Advanced age</li> <li>- Obesity</li> <li>- 1st- and 2nd-trimester pregnancy</li> <li>- Varicose veins</li> <li>- Laparoscopic surgery (e.g., cholecystectomy)</li> </ul>

Abbreviations: COC, combined oral contraceptives; HIV, human immunodeficiency virus; HRT, hormone-replacement therapy; IVF, in-vitro fertilisation; OR, odds ratio; VTE, venous thromboembolism.



travelling) which alone would not justify secondary prophylaxis with medication, but which should be included in the overall assessment. If several risk factors are present, it is difficult to estimate the possible additive, multiplicative or exponential effect on the risk of recurrence. However, it can be assumed that the risk of recurrence in the long term is lower after VTE related to a transient risk factor which is no longer present, and higher in the presence of persistent risk factors. The revised AWMF S2k guidelines recommend that for each VTE, the relevant risk factors that have contributed to the thrombotic event should be taken into consideration about type, intensity and duration of therapy and secondary prophylaxis.<sup>6</sup>

To date, there is a lack of clear scientific evidence demonstrating that knowledge of thrombophilia is beneficial in determining the secondary prevention strategy.<sup>48–50</sup> In clinical practice, patients with VTE manifestation at a young age, those with unprovoked events, recurrent VTE or atypical thrombosis localisation as well as patients with a positive family history are often referred for thrombophilia screening. Presenting details of the extent of screening, optimal timing and influence of anticoagulation on test results is beyond the aim of this article. Of note, there is agreement that thrombophilia screening should be performed only if therapeutic consequences arise from the test results. Screening can therefore be useful for individual patients in whom the decision for or against prolonged anticoagulation is unclear or in whom knowledge of a thrombophilia influences the duration and intensity of anticoagulation or the type of anticoagulant. If treatment decisions can be reliably made on the basis of established clinical factors, thrombophilia screening is unnecessary and should not be performed.<sup>6</sup>

Active malignant disease is a strong risk factor for VTE and VTE recurrence. Since the occurrence of acute VTE can be caused by previously occult malignancy, the recommended age- and gender-specific examinations for cancer screening should be reviewed and updated, especially if the etiology of the current VTE event remains unclear. Depending on the extent of diagnostics after the occurrence of a VTE, the probability of detecting a previously unknown malignancy is between 3 and 15% and is higher after unprovoked compared with risk-associated VTE and higher in older compared with younger people.<sup>51–54</sup>

### Risk of Major Bleeding

In a meta-analysis, the incidence of major bleeding for secondary prophylaxis with a DOAC regimen was 1.12 (95% CI: 0.72–1.62) compared with 1.74 (95% CI: 1.34–2.20) per 100 person-years with VKA.<sup>55</sup> The risk of dying from major bleeding was comparable for VKA and DOAC (case fatality rate: 8.3% [95% CI: 5.1–12.2%] vs. 9.7% [95% CI: 3.2–19.2%]). Under the additional aspect that efficient secondary prophylaxis is possible for many patients with low-dose apixaban or rivaroxaban, today's risk-benefit assessment shifts considerably toward an anticoagulation-based secondary prophylaxis.

Bleeding risk scores for VTE patients on anticoagulation have been developed (–Table 3) but have been poorly

validated and do not provide meaningful guidance in everyday clinical practice.<sup>56,57</sup> Therefore, as prospective management studies for VTE patients are currently lacking, a high bleeding score should not be used as a justification to withhold anticoagulation from patients with acute VTE, which is a clear indication for anticoagulation.

### Shared Decision-Making

The patient's preferences and concerns should always be included in the decision-making process, after an easily understandable explanation of the assumed risks and benefits of the treatment options under consideration has been given. At the end of the maintenance phase, many patients usually have sufficient insight into the clinical relevance of VTE, experienced several months of VTE therapy and developed a clear idea of the significance of a possible recurrence for their future life. An explicit and transparent shared decision-making with detailed documentation should be the standard of care.<sup>6</sup>

### Proximal DVT with or without PE

A therapy duration of 3 to 6 months is usually considered sufficient for the treatment of acute LEDVT and this also applies to proximal DVT with and without PE. After this time, the question arises whether anticoagulation can be stopped or continued due to an increased risk of VTE recurrence. It is a particular challenge to assess the risk of recurrent VTE in individual cases toward to make the safest possible decision on whether to discontinue or continue anticoagulant therapy. In recent years, a "traffic light system" has been established to provide decision support, in which clinical situations secondary prophylaxis after VTE should be carried out, considered or not carried out. The revised AWMF S2k guideline has modified this system and tried to establish practical recommendations for action.<sup>6</sup>

The main decisive factor is the classification of the risk factors contributing to the index VTE, whereby a distinction is made between strong and weak as well as persistent and transient factors. It is recommended to continue anticoagulation indefinitely in cases of high risk of recurrence (e.g., active malignancy, high-risk thrombophilia, recurrent unprovoked VTE), usually at the same dosage as recommended in the maintenance phase. In contrast, anticoagulation can be stopped after at least 3 months of therapy if the risk of recurrence is considered low. This is the case if the VTE occurred in association with a strong transient trigger (e.g., major surgery, trauma with fracture, bed rest for  $\geq 3$  days) that is no longer present or relevant toward the end of the therapy phase (–Fig. 5).

Decision-making for patients at moderate risk of recurrence is challenging, as discontinuation and continuation of anticoagulation may be considered equivalent options. This group includes patients with unprovoked VTE and those in whom the index event occurred in association with weak or questionable triggers. In these cases, continuation of anticoagulation is often reasonable, but the clinical benefit is less pronounced and must be weighed against the individual risk of bleeding taking into account the patient's preferences.

**Table 3** VTE-BLEED score to estimate the bleeding risk in VTE patients on long-term therapeutic anticoagulation

Factor	Score
Active neoplastic disease	2
Male patients with uncontrolled hypertension (SBP $\geq$ 140 mm Hg)	1
Anaemia ( $\sigma$ : Hb $<$ 13; $\text{♀}$ : Hb $<$ 12 g/dL)	1.5
Previous bleeding (MB or CRNMB)	1.5
Age $\geq$ 60 y	1.5
Renal insufficiency (eGFR $<$ 60 mL/min)	1.5
<i>Assessment of the bleeding risk:</i> $<$ 2 points: low bleeding risk; $\geq$ 2 points: high bleeding risk	

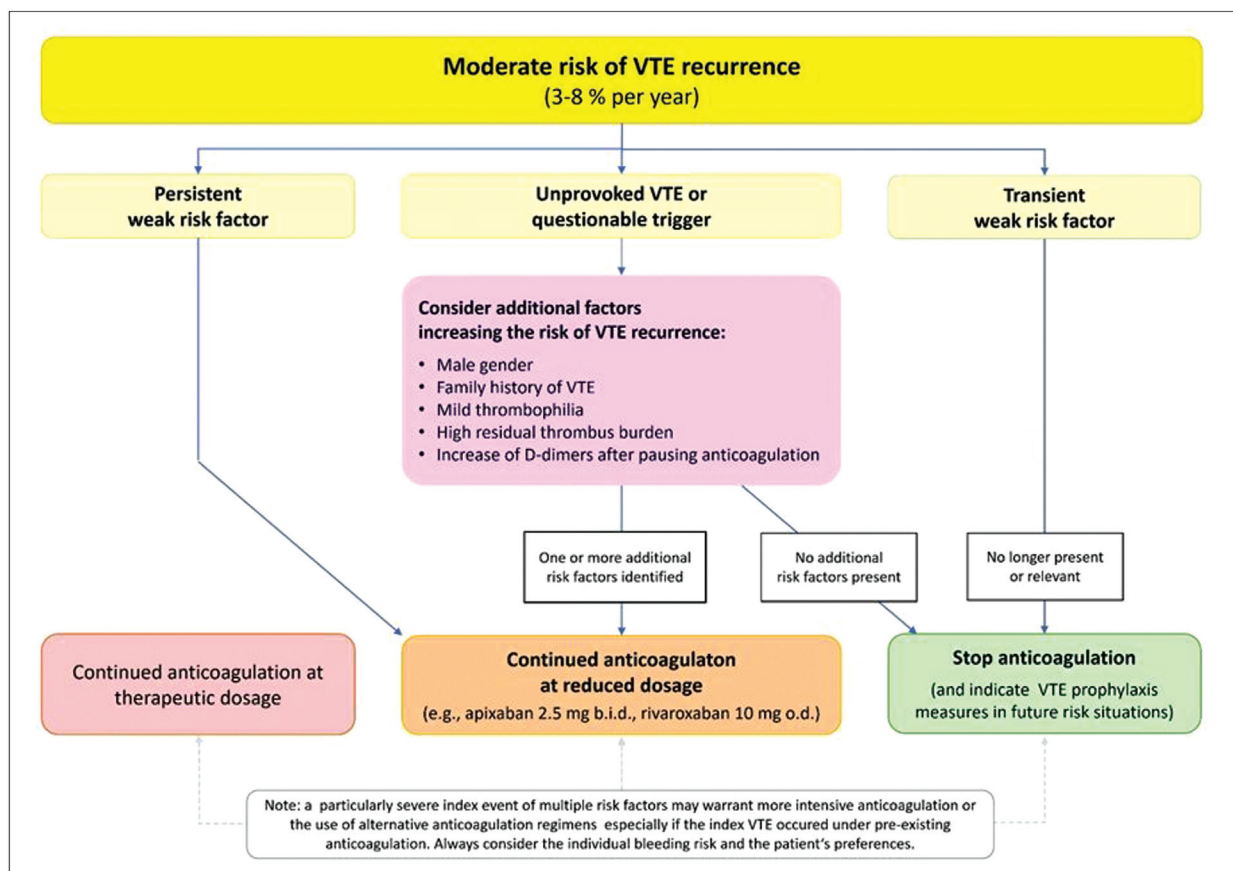
Abbreviations: CRNMB, clinical relevant non-major bleeding; eGFR, estimated glomerular filtration rate; Hb, haemoglobin; MB, major bleeding; SBP, systemic blood pressure.

Continuation of anticoagulation should also be considered if weak risk factors persist (e.g., inflammatory bowel disease) and if the risk of bleeding is low. If, on the other hand, the index VTE was triggered by a transient weak risk factor (e.g., estrogen therapy, pregnancy, long-term travel, leg injury without fracture) and there are no additional persistent risk factors, discontinuation of anticoagulation should be considered (→ Fig. 6). When the decision is made to continue anticoagulation in patients at moderate risk of VTE recurrence, the use of low-dose apixaban ( $2 \times 2.5$  mg per day) or rivaroxaban ( $1 \times 10$  mg per day) is an evidence-based option.<sup>33,58</sup> Of note, the low-dose concept is not applicable

to patients considered to be at high risk of recurrence due to high-risk thrombophilia, malignant disease or recurrent VTE despite anticoagulant therapy. In these patients, anticoagulation should be applied in therapeutic dosages.

### Residual Thrombus Burden and D-dimers to Guide Duration of Therapy

Patients who have a high residual thrombus burden after proximal DVT – usually defined as more than 40% obstruction of the vein cross-section – have a higher recurrence rate than patients with complete recanalisation of their originally thrombosed veins.<sup>59–61</sup> This is the case for ~50 to 60% of



**Fig. 6** Decision-making for secondary prophylaxis in patients at moderate risk of VTE recurrence. b.i.d., twice daily; o.d., once daily; VTE, venous thromboembolism.

patients after proximal DVT, and according to a meta-analysis, is associated with a 1.3-fold increased risk of VTE recurrence (95% CI: 1.06–1.65) making residual venous obstruction (RVO) a weak risk factor for VTE recurrence.<sup>46</sup> However, studies incorporating RVO into the decision on the duration of anticoagulant therapy found that a flexible duration of therapy up to 12 to 24 months was associated with a lower risk of VTE recurrence than a fixed duration of therapy of 3 to 6 months (adjusted HR 0.64; 95% CI: 0.39–0.99).<sup>62</sup>

It may also be useful to determine the D-dimers before the planned end of therapy, to pause anticoagulation if the D-dimers are normal, and to repeat D-dimer testing after 4 or 12 weeks.<sup>63,64</sup> Elevated D-dimer levels under anticoagulation, as well as an increase in D-dimers after cessation of anticoagulation, indicate an increased risk of recurrence<sup>65,66</sup> and identifies candidates who benefit from continuation or resumption of anticoagulant therapy.<sup>67–69</sup> However, it is important to remember that D-dimers are non-specific and can be elevated in a variety of situations (e.g., infection, inflammation, malignancy, pregnancy). Furthermore, men are at higher risk of recurrence than women. Based on the available evidence, it could therefore be argued that normal D-dimer levels after discontinuation of anticoagulation do not predict a sufficiently low recurrence in men.<sup>70</sup> In this respect, D-dimer testing may have an additive benefit in decision-making, but is not a suitable parameter to base the decision on secondary VTE prophylaxis solely on this biomarker.

Prospective management studies have shown that the combined approach of adapting the duration of therapy to the RVO and D-dimer test results can improve patient's outcomes by reducing the risk of VTE recurrence.<sup>68,71</sup> The annual recurrence rate was 3.0% when anticoagulation was stopped after a flexible duration of therapy and with normal D-dimers. With elevated D-dimers, the recommended resumption of anticoagulation resulted in a very low recurrence rate (< 1% per year). In contrast, patients who refused to resume anticoagulation despite elevated D-dimers had a substantially higher risk of recurrence ( $\approx$  9% per year).

### Assessing Additional Risk Factors for VTE Recurrence

There are other factors for which an increased risk of VTE recurrence has been demonstrated in cohort studies, without there being any clear scientific evidence to date that consideration of these factors for prolonged secondary prophylaxis results in a risk reduction. These include male gender, the presence of low-risk thrombophilias such as the heterozygous forms of the factor V Leiden mutation and prothrombin G20210A mutation, and a positive family history without evidence of a specific thrombophilia. The RR increase due to these factors is low (RR: 1.2–1.8), and none of these factors alone is decisive for determining the type and duration of secondary prophylaxis. However, in individual cases, the presence of several weak risk factors may change treatment decision, especially in the context of otherwise unexplained VTE (**→ Fig. 6**). Finally, patients in whom the index event manifested as a PE may also be candidates for

prolonged anticoagulation as evidence indicates that VTE recurrence is more likely to manifest as PE again.<sup>72</sup>

### Isolated Distal DVT and Isolated Muscle Vein Thrombosis

Between 30 and 60% of all LEDVTs affect solely the tibial and peroneal veins.<sup>73,74</sup> Isolated calf muscle vein thrombosis (iMVT) involving the veins of the gastrocnemius and soleus muscles must be distinguished from this. Compared with proximal DVT, the risk of PE in isolated distal DVT (idDVT) is significantly lower and varies between 1 to 2% and 10 to 15%, depending on whether symptomatic or asymptomatic PE is considered. Clinically relevant PTS after idDVT is rare. Recently, a Cochrane meta-analysis demonstrated that the risk of DVT recurrence after idDVT is reduced by more than 60% with the use of anticoagulants (3.1 vs. 9.1%, respectively, for patients with and without anticoagulation; RR: 0.34, 95% CI: 0.15–0.77), while the risk of PE was basically low (1.0 vs. 1.2%, respectively, for patients with and without anticoagulation).<sup>75</sup> For confirmed idDVT, a 3-month therapy is usually considered sufficient. This also applies for recurrent idDVT. If there is a strong and persistent risk factor for VTE recurrence (e.g., severe hereditary thrombophilia, antiphospholipid syndrome, active malignancy), prolonged anticoagulation for more than 3 months should be considered.<sup>76–78</sup>

Even though the data situation in the available cohort studies is very variable, the complication rates for isolated muscle vein thrombosis (iMVT) appear to be even lower than for idDVT.<sup>79</sup> However, if left untreated, these can grow into the deep vein system, with progression rates of 8 to 25% reported in the literature.<sup>80</sup> The extent to which anticoagulation is beneficial for iMVT patients is controversial. The revised AWMF S2k guideline recommends short-term anticoagulation of 7 to 10 days until symptoms have subsided and, in the case of persistent risk factors (e.g., prolonged immobility, active tumour disease), to extend the duration of therapy to 4 weeks.

If anticoagulation is not used because the risk–benefit ratio is considered questionable, detailed documentation of the extent of DVT should be performed and close clinical and sonographic monitoring should be offered. In cases of clinical deterioration or thrombosis progression at the follow-up date, anticoagulation should be initiated.

### Conclusions

Depending on the equipment and experience of the examiner, the diagnosis of DVT can be challenging. This is particularly true for patients with poor ultrasound conditions and non-conclusive sonographic findings and for those presenting with suspected ipsilateral recurrent DVT. A timely and structured diagnostic work-up and immediate initiation of therapy in cases of confirmed DVT are essential to minimise the risk of PE in the acute phase and of PTS and VTE recurrence in the long-term. According to the revised S2k guideline of the AWMF, the circumstances and trigger factors

that contributed to the occurrence of DVT, as well as the individual bleeding risk and the patient's preferences, should be taken into account when deciding on the type, intensity and duration of therapy and secondary prophylaxis.

#### Conflict of Interest

BL took participation on a Data Safety Monitoring Board or Advisory Board from Bayer Vital, Bristol-Myers Squibb, Lumira DX, Pfizer and Viartis. She got Payment or honoraria for lectures, presentations, speakers bureaus, manuscript writing or educational events from Bristol-Myers Squibb, Daiichi Sankyo, LEO Pharma, Pfizer, Sanofi and Viartis. She got consulting fees from Bayer Vital, Bristol-Myers Squibb, Lumira DX, Pfizer and Viartis.

#### References

- White RH. The epidemiology of venous thromboembolism. *Circulation* 2003;107(23, Suppl 1):I4–I8
- Wendelboe AM, Raskob GE. Global burden of thrombosis: epidemiologic aspects. *Circ Res* 2016;118(09):1340–1347
- Strijkers RHW, Cate-Hoek AJ, Bukkems SFFW, Wittens CH. Management of deep vein thrombosis and prevention of post-thrombotic syndrome. *BMJ* 2011;343:d5916
- Hach-Wunderle V, Bauersachs R, Gerlach HE, et al. Post-thrombotic syndrome 3 years after deep venous thrombosis in the Thrombosis and Pulmonary Embolism in Out-Patients (TULIPA) PLUS Registry. *J Vasc Surg Venous Lymphat Disord* 2013;1(01):5–12
- Rabinovich A, Kahn SR. How I treat the postthrombotic syndrome. *Blood* 2018;131(20):2215–2222
- Linnemann B, Blank W, Doenst T, et al. Diagnostics and Therapy of Venous Thrombosis and Pulmonary Embolism. The revised AWMF S2k Guideline. *Vasa*. 2023 Oct; 52(S111): 1–146. PMID: 37904504. DOI: 10.1024/0301-1526/a001089
- Schellong SM. Complete compression ultrasound for the diagnosis of venous thromboembolism. *Curr Opin Pulm Med* 2004;10(05):350–355
- Johnson SA, Stevens SM, Woller SC, et al. Risk of deep vein thrombosis following a single negative whole-leg compression ultrasound: a systematic review and meta-analysis. *JAMA* 2010;303(05):438–445
- Kraaijpoel N, Carrier M, Le Gal G, et al. Diagnostic accuracy of three ultrasonography strategies for deep vein thrombosis of the lower extremity: a systematic review and meta-analysis. *PLoS One* 2020;15(02):e0228788
- Riley RS, Gilbert AR, Dalton JB, Pai S, McPherson RA. Widely used types and clinical applications of D-dimer assay. *Lab Med* 2016;47(02):90–102
- Stricker H, Marchetti O, Haerberli A, Mombelli G. Hemostatic activation under anticoagulant treatment: a comparison of unfractionated heparin vs. nadroparin in the treatment of proximal deep vein thrombosis. *Thromb Haemost* 1999;82(04):1227–1231
- Nybo M, Hvas A-M. Age-adjusted D-dimer cut-off in the diagnostic strategy for deep vein thrombosis: a systematic review. *Scand J Clin Lab Invest* 2017;77(08):568–573
- van der Hulle T, Tan M, den Exter PL, et al. Selective D-dimer testing for the diagnosis of acute deep vein thrombosis: a validation study. *J Thromb Haemost* 2013;11(12):2184–2186
- Parpia S, Takach Lapner S, Schutgens R, Elf J, Geersing GJ, Kearon C. Clinical pre-test probability adjusted versus age-adjusted D-dimer interpretation strategy for DVT diagnosis: a diagnostic individual patient data meta-analysis. *J Thromb Haemost* 2020;18(03):669–675
- Kyrle PA, Kammer M, Eischer L, et al. The long-term recurrence risk of patients with unprovoked venous thromboembolism: an observational cohort study. *J Thromb Haemost* 2016;14(12):2402–2409
- van Dam LF, Gautam G, Dronkers CEA, et al. Safety of using the combination of the Wells rule and D-dimer test for excluding acute recurrent ipsilateral deep vein thrombosis. *J Thromb Haemost* 2020;18(09):2341–2348
- Carrier M, Rodger MA, Wells PS, Righini M, LE Gal G. Residual vein obstruction to predict the risk of recurrent venous thromboembolism in patients with deep vein thrombosis: a systematic review and meta-analysis. *J Thromb Haemost* 2011;9(06):1119–1125
- Linkins L-A, Stretton R, Probyn L, Kearon C. Interobserver agreement on ultrasound measurements of residual vein diameter, thrombus echogenicity and Doppler venous flow in patients with previous venous thrombosis. *Thromb Res* 2006;117(03):241–247
- Agno W, Squizzato A, Wells PS, Büller HR, Johnson G. The diagnosis of symptomatic recurrent pulmonary embolism and deep vein thrombosis: guidance from the SSC of the ISTH. *J Thromb Haemost* 2013;11(08):1597–1602
- Maufus M, Elias A, Barrellier M-T, Pernod G French Society for Vascular Medicine. Diagnosis of deep vein thrombosis recurrence: ultrasound criteria. *Thromb Res* 2018;161:78–83
- Aguilar C, del Villar V. Combined D-dimer and clinical probability are useful for exclusion of recurrent deep venous thrombosis. *Am J Hematol* 2007;82(01):41–44
- Prandoni P, Tormene D, Dalla Valle F, Concolato A, Pesavento R. D-dimer as an adjunct to compression ultrasonography in patients with suspected recurrent deep vein thrombosis. *J Thromb Haemost* 2007;5(05):1076–1077
- van Dam LF, Dronkers CEA, Gautam G, et al; Theia Study Group. Magnetic resonance imaging for diagnosis of recurrent ipsilateral deep vein thrombosis. *Blood* 2020;135(16):1377–1385
- Limone BL, Hernandez AV, Michalak D, Bookhart BK, Coleman CI. Timing of recurrent venous thromboembolism early after the index event: a meta-analysis of randomized controlled trials. *Thromb Res* 2013;132(04):420–426
- Appelen D, van Loo E, Prins MH, Neumann MH, Kolbach DN. Compression therapy for prevention of post-thrombotic syndrome. *Cochrane Database Syst Rev* 2017;9(09):CD004174
- Amin EE, Bistervels IM, Meijer K, et al. Reduced incidence of vein occlusion and postthrombotic syndrome after immediate compression for deep vein thrombosis. *Blood* 2018;132(21):2298–2304
- Kahn SR, Comerota AJ, Cushman M, et al; American Heart Association Council on Peripheral Vascular Disease, Council on Clinical Cardiology, and Council on Cardiovascular and Stroke Nursing. The postthrombotic syndrome: evidence-based prevention, diagnosis, and treatment strategies: a scientific statement from the American Heart Association. *Circulation* 2014;130(18):1636–1661
- Schulman S, Kearon C, Kakkar AK, et al; RE-COVER Study Group. Dabigatran versus warfarin in the treatment of acute venous thromboembolism. *N Engl J Med* 2009;361(24):2342–2352
- Schulman S, Kakkar AK, Goldhaber SZ, et al; RE-COVER II Trial Investigators. Treatment of acute venous thromboembolism with dabigatran or warfarin and pooled analysis. *Circulation* 2014;129(07):764–772
- Bauersachs R, Berkowitz SD, Brenner B, et al; EINSTEIN Investigators. Oral rivaroxaban for symptomatic venous thromboembolism. *N Engl J Med* 2010;363(26):2499–2510
- Büller HR, Décousus H, Grosso MA, et al; Hokusai-VTE Investigators. Edoxaban versus warfarin for the treatment of symptomatic venous thromboembolism. *N Engl J Med* 2013;369(15):1406–1415

- 32 Büller HR, Prins MH, Lensin AWA, et al; EINSTEIN-PE Investigators. Oral rivaroxaban for the treatment of symptomatic pulmonary embolism. *N Engl J Med* 2012;366(14):1287–1297
- 33 Agnelli G, Buller HR, Cohen A, et al; AMPLIFY-EXT Investigators. Apixaban for extended treatment of venous thromboembolism. *N Engl J Med* 2013;368(08):699–708
- 34 van der Hulle T, den Exter PL, Kooiman J, van der Hoeven JJM, Huisman MV, Klok FA. Meta-analysis of the efficacy and safety of new oral anticoagulants in patients with cancer-associated acute venous thromboembolism. *J Thromb Haemost* 2014;12(07):1116–1120
- 35 van Es N, Coppens M, Schulman S, Middeldorp S, Büller HR. Direct oral anticoagulants compared with vitamin K antagonists for acute venous thromboembolism: evidence from phase 3 trials. *Blood* 2014;124(12):1968–1975
- 36 Brandjes DPM, Büller HR, Heijboer H, et al. Randomised trial of effect of compression stockings in patients with symptomatic proximal-vein thrombosis. *Lancet* 1997;349(9054):759–762
- 37 Prandoni P, Lensing AWA, Prins MH, et al. Below-knee elastic compression stockings to prevent the post-thrombotic syndrome: a randomized, controlled trial. *Ann Intern Med* 2004;141(04):249–256
- 38 Jayaraj A, Meissner M. Impact of graduated compression stockings on the prevention of post-thrombotic syndrome - results of a randomized controlled trial. *Phlebology* 2015;30(08):541–548
- 39 Arpaia G, Cimminiello C, Mastrogiacomo O, de Gaudenzi E. Efficacy of elastic compression stockings used early or after resolution of the edema on recanalization after deep venous thrombosis: the COM.PRE Trial. *Blood Coagul Fibrinolysis* 2007;18(02):131–137
- 40 Prandoni P, Noventa F, Quintavalla R, et al; Canano Investigators. Thigh-length versus below-knee compression elastic stockings for prevention of the postthrombotic syndrome in patients with proximal-venous thrombosis: a randomized trial. *Blood* 2012;119(06):1561–1565
- 41 Ten Cate-Hoek AJ, Amin EE, Bouman AC, et al; IDEAL DVT Investigators. Individualised versus standard duration of elastic compression therapy for prevention of post-thrombotic syndrome (IDEAL DVT): a multicentre, randomised, single-blind, allocation-concealed, non-inferiority trial. *Lancet Haematol* 2018;5(01):e25–e33
- 42 Kakkos SK, Gohel M, Baekgaard N, et al; ESVS Guidelines Committee. Editor's Choice - European Society for Vascular Surgery (ESVS) 2021 Clinical Practice Guidelines on the Management of Venous Thrombosis. *Eur J Vasc Endovasc Surg* 2021;61(01):9–82
- 43 Broderick C, Watson L, Armon MP. Thrombolytic strategies versus standard anticoagulation for acute deep vein thrombosis of the lower limb. *Cochrane Database Syst Rev* 2021;1(01):CD002783
- 44 Stevens SM, Woller SC, Kreuziger LB, et al. Antithrombotic therapy for VTE disease: second update of the CHEST Guideline and Expert Panel Report. *Chest* 2021;160(06):e545–e608
- 45 Konstantinides SV, Meyer G, Becattini C, et al; ESC Scientific Document Group. 2019 ESC Guidelines for the diagnosis and management of acute pulmonary embolism developed in collaboration with the European Respiratory Society (ERS). *Eur Heart J* 2020;41(04):543–603
- 46 Donadini MP, Ageno W, Antonucci E, et al. Prognostic significance of residual venous obstruction in patients with treated unprovoked deep vein thrombosis: a patient-level meta-analysis. *Thromb Haemost* 2014;111(01):172–179
- 47 White RH. Identifying risk factors for venous thromboembolism. *Circulation* 2012;125(17):2051–2053
- 48 Coppens M, Reijnders JH, Middeldorp S, Doggen CJ, Rosendaal FR. Testing for inherited thrombophilia does not reduce the recurrence of venous thrombosis. *J Thromb Haemost* 2008;6(09):1474–1477
- 49 Stevens SM, Woller SC, Bauer KA, et al. Guidance for the evaluation and treatment of hereditary and acquired thrombophilia. *J Thromb Thrombolysis* 2016;41(01):154–164
- 50 Garcia-Horton A, Kovacs MJ, Abdulrehman J, Taylor JE, Sharma S, Lazo-Langner A. Impact of thrombophilia screening on venous thromboembolism management practices. *Thromb Res* 2017;149:76–80
- 51 Carrier M, Le Gal G, Wells PS, Fergusson D, Ramsay T, Rodger MA. Systematic review: the Trousseau syndrome revisited: should we screen extensively for cancer in patients with venous thromboembolism? *Ann Intern Med* 2008;149(05):323–333
- 52 van Es N, Le Gal G, Otten H-M, et al. Screening for occult cancer in patients with unprovoked venous thromboembolism: a systematic review and meta-analysis of individual patient data. *Ann Intern Med* 2017;167(06):410–417
- 53 Marks MA, Engels EA. Venous thromboembolism and cancer risk among elderly adults in the United States. *Cancer Epidemiol Biomarkers Prev* 2014;23(05):774–783
- 54 Rosell A, Lundström S, Mackman N, Wallén H, Thålin C. A clinical practice-based evaluation of the RIETE score in predicting occult cancer in patients with venous thromboembolism. *J Thromb Thrombolysis* 2019;48(01):111–118
- 55 Khan F, Tritschler T, Kimpton M, et al; MAJESTIC Collaborators. Long-term risk for major bleeding during extended oral anticoagulant therapy for first unprovoked venous thromboembolism: a systematic review and meta-analysis. *Ann Intern Med* 2021;174(10):1420–1429
- 56 Klok FA, Huisman MV. How I assess and manage the risk of bleeding in patients treated for venous thromboembolism. *Blood* 2020;135(10):724–734
- 57 Badescu MC, Ciocoiu M, Badulescu OV, et al. Prediction of bleeding events using the VTE-BLEED risk score in patients with venous thromboembolism receiving anticoagulant therapy. (Review) *Exp Ther Med* 2021;22(05):1344
- 58 Weitz JI, Lensing AWA, Prins MH, et al; EINSTEIN CHOICE Investigators. Rivaroxaban or aspirin for extended treatment of venous thromboembolism. *N Engl J Med* 2017;376(13):1211–1222
- 59 Prandoni P, Lensing AWA, Prins MH, et al. Residual venous thrombosis as a predictive factor of recurrent venous thromboembolism. *Ann Intern Med* 2002;137(12):955–960
- 60 Siragusa S, Malato A, Anastasio R, et al. Residual vein thrombosis to establish duration of anticoagulation after a first episode of deep vein thrombosis: the Duration of Anticoagulation based on Compression UltraSonography (DACUS) study. *Blood* 2008;112(03):511–515
- 61 Tan M, Mos ICM, Klok FA, Huisman MV. Residual venous thrombosis as predictive factor for recurrent venous thromboembolism in patients with proximal deep vein thrombosis: a systematic review. *Br J Haematol* 2011;153(02):168–178
- 62 Prandoni P, Prins MH, Lensing AWA, et al; AESOPUS Investigators. Residual thrombosis on ultrasonography to guide the duration of anticoagulation in patients with deep venous thrombosis: a randomized trial. *Ann Intern Med* 2009;150(09):577–585
- 63 Palareti G, Legnani C, Cosmi B, et al. Predictive value of D-dimer test for recurrent venous thromboembolism after anticoagulation withdrawal in subjects with a previous idiopathic event and in carriers of congenital thrombophilia. *Circulation* 2003;108(03):313–318
- 64 Cosmi B, Legnani C, Tosetto A, et al; PROLONG Investigators (on behalf of Italian Federation of Anticoagulation Clinics) Usefulness of repeated D-dimer testing after stopping anticoagulation for a first episode of unprovoked venous thromboembolism: the PROLONG II prospective study. *Blood* 2010;115(03):481–488
- 65 Verhovsek M, Douketis JD, Yi Q, et al. Systematic review: D-dimer to predict recurrent disease after stopping anticoagulant therapy for unprovoked venous thromboembolism. *Ann Intern Med* 2008;149(07):481–490, W94

- 66 Douketis J, Tosetto A, Marcucci M, et al. Patient-level meta-analysis: effect of measurement timing, threshold, and patient age on ability of D-dimer testing to assess recurrence risk after unprovoked venous thromboembolism. *Ann Intern Med* 2010; 153(08):523–531
- 67 Palareti G, Cosmi B, Legnani C, et al; PROLONG Investigators. D-dimer testing to determine the duration of anticoagulation therapy. *N Engl J Med* 2006;355(17):1780–1789
- 68 Palareti G, Cosmi B, Legnani C, et al; DULCIS (D-dimer and ULtrasonography in Combination Italian Study) Investigators. D-dimer to guide the duration of anticoagulation in patients with venous thromboembolism: a management study. *Blood* 2014;124(02):196–203
- 69 Palareti G, Poli D, Ageno W, et al. D-dimer and reduced-dose apixaban for extended treatment after unprovoked venous thromboembolism: the Apidulcis study. *Blood Adv* 2022;6(23):6005–6015
- 70 Kearon C, Kahn SR. Long-term treatment of venous thromboembolism. *Blood* 2020;135(05):317–325
- 71 Prandoni P, Vedovetto V, Ciammaichella M, et al; Morgagni Investigators. Residual vein thrombosis and serial D-dimer for the long-term management of patients with deep venous thrombosis. *Thromb Res* 2017;154:35–41
- 72 Mearns ES, Coleman CI, Patel D, et al. Index clinical manifestation of venous thromboembolism predicts early recurrence type and frequency: a meta-analysis of randomized controlled trials. *J Thromb Haemost* 2015;13(06):1043–1052
- 73 Palareti G, Legnani C, Antonucci E, et al. Management and outcomes of isolated distal deep vein thromboses: a questionable trend toward long-lasting anticoagulation treatment. results from the START-Register. *TH Open* 2021;5(03):e239–e250
- 74 Schellong S, Ageno W, Casella IB, et al. Profile of patients with isolated distal deep vein thrombosis versus proximal deep vein thrombosis or pulmonary embolism: RE-COVERY DVT/PE Study. *Semin Thromb Hemost* 2022;48(04):446–458
- 75 Kirkilesis G, Kakkos SK, Bicknell C, Salim S, Kakavia K. Treatment of distal deep vein thrombosis. *Cochrane Database Syst Rev* 2020; 4(04):CD013422
- 76 Dentali F, Pegoraro S, Barco S, et al. Clinical course of isolated distal deep vein thrombosis in patients with active cancer: a multicenter cohort study. *J Thromb Haemost* 2017;15(09):1757–1763
- 77 Dentali F, Barco S, Pegoraro S, et al. Residual vein obstruction in patients diagnosed with acute isolated distal deep vein thrombosis associated with active cancer. *J Thromb Thrombolysis* 2018;46(03):404–408
- 78 Galanaud J-P, Sevestre M-A, Pernod G, et al. Long-term outcomes of cancer-related isolated distal deep vein thrombosis: the OPTI-MEV study. *J Thromb Haemost* 2017;15(05):907–916
- 79 Kuczmik W, Wysokinski WE, Hesley GK, et al. Calf vein thrombosis comparison of outcomes for axial and muscular venous thrombosis. *Thromb Haemost* 2021;121(02):216–223
- 80 Henry JC, Satiani B. Calf muscle venous thrombosis: a review of the clinical implications and therapy. *Vasc Endovascular Surg* 2014;48(5-6):396–401