

High-Dose Rate Brachytherapy Combined with PD-1 Blockade as a Treatment for Metastatic Adrenocortical Carcinoma – A Single Center Case Series

Authors

Paul Schwarzmüller¹ , Stefanie Corradini² , Max Seidensticker³ , Petra Zimmermann⁴, Jochen Schreiner¹, Tanja Maier¹, Alexandra Triebig¹, Thomas Knösel⁵ , Montserrat Pazos², Thomas Pflüger⁶, Isabel Weigand¹ , Claus Belka², Jens Ricke³, Martin Reincke¹ , Ralf Schmidmaier¹, Matthias Kroiss¹ 

Affiliations

- 1 Department of Medicine IV, University Hospital, LMU Munich, Munich, Germany
- 2 Department of Radiation Oncology, University Hospital, LMU Munich, Munich, Germany
- 3 Department of Radiology, University Hospital, LMU Munich, Munich, Germany
- 4 Department of General, Visceral and Transplant Surgery, University Hospital, LMU Munich, Munich, Germany
- 5 Institute of Pathology, Faculty of Medicine, LMU Munich, Munich, Germany
- 6 Department of Nuclear Medicine, University Hospital, LMU Munich, Munich, Germany

Key words

adrenocortical carcinoma, cancer, immune checkpoint blockade, brachytherapy, pembrolizumab, abscopal effect

received 31.05.2023

accepted after revision 02.08.2023

published online 25.09.2023

Bibliography

Horm Metab Res 2024; 56: 30–37

DOI 10.1055/a-2150-3944

ISSN 0018-5043

© 2023. Thieme. All rights reserved.

Georg Thieme Verlag, Rüdigerstraße 14,
70469 Stuttgart, Germany

Correspondence

Prof. Matthias Kroiss

Department of Medicine IV

University Hospital Munich

LMU Munich

Ziemssenstraße 5

80336 Muenchen

Germany

Tel.: +49-89/4400-52221

Matthias.Kroiss@med.uni-muenchen.de

ABSTRACT

The response rate of advanced adrenocortical carcinoma (ACC) to standard chemotherapy with mitotane and etoposide/doxorubicin/cisplatin (EDP-M) is unsatisfactory, and benefit is frequently short lived. Immune checkpoint inhibitors (CPI) have been examined in patients' refractory to EDP-M, but objective response rates are only approximately 15%. High-dose rate brachytherapy (HDR-BT) is a catheter-based internal radiotherapy and expected to favorably combine with immunotherapies. Here we describe three cases of patients with advanced ACC who were treated with HDR-BT and the CPI pembrolizumab. None of the tumors were positive for established response markers to CPI. All patients were female, had progressed on EDP-M and received external beam radiation therapy for metastatic ACC. Pembrolizumab was initiated 7 or 23 months after brachytherapy in two cases and prior to brachytherapy in one case. Best response of lesions treated with brachytherapy was complete (n = 2) or partial response (n = 1) that was ongoing at last follow up after 23, 45 and 4 months, respectively. Considering all sites of tumor, response was complete and partial remission in the two patients with brachytherapy prior to pembrolizumab. The third patient developed progressive disease with severe Cushing's syndrome and died due to COVID-19. Immune-related adverse events of colitis (grade 3), gastro-duodenitis (grade 3), pneumonitis (grade 2) and thyroiditis (grade 1) occurred in the two patients with systemic response. HDR-BT controlled metastases locally. Sequential combination with CPI therapy may enhance an abscopal antitumoral effect in non-irradiated metastases in ACC. Systematic studies are required to confirm this preliminary experience and to understand underlying mechanisms.

Introduction

Etoposide, doxorubicin, and cisplatin (EDP) combined with mitotane (EDP-M) is the standard treatment for adrenocortical carcinoma (ACC) based on a randomized phase III clinical trial in 304 patients. Compared to streptozotocin and mitotane (Sz-M), patients treated with EDP-M showed a longer median progression-free survival of 5 months compared to 2.1 months with Sz-M [1]. Today, 10 years after the publication of this landmark trial, EDP-M is still the recommended first line therapy in advanced ACC with a median overall survival of 15 months in stage IV. New effective treatment options are urgently needed to improve patient outcomes. Checkpoint inhibitors (CPIs) have revolutionized the treatment of many cancer entities. In ACC, results of studies are heterogeneous and less promising. So far, five small clinical trials with a total of 121 patients have been published and reported an objective response in only 17 patients (13%) [2–6].

In none of these trials of immunotherapy, established response markers such as tumor mutational burden or microsatellite instability (MSI) have shown an association with response, although two patients in one study were affected by Lynch syndrome, a germ line predisposition syndrome leading to tumoral MSI [5]. Likewise, the expression of programmed cell death ligand 1 (PD-L1), a biomarker for response to CPI in some tumors such as non-small cell lung cancer, does not predict response in other entities [7]. Indeed, in ACC PD-L1 is expressed on less than 5% of tumor cells in 89% of tumors [8]. Accordingly, we did not find an association of response of ACC to immunotherapy with any established marker in a series of 54 patients treated with CPI on a compassionate use basis [9].

So far, the immunological mechanisms underlying the relative resistance to CPI have not been elucidated. Tumoral immune infiltration is comparably low in ACC and the glucocorticoid excess present in approximately 60% of ACC has been associated with even more sparse tumor infiltrating cells of the adaptive immune system [10]. Treatment-emergent resistance mechanisms may be relevant in ACC as indicated by the potentially adverse impact of mitotane treatment on response to CPI [9]. Importantly, immunogenic tumor antigens in ACC have not been identified. Insufficient immune cell priming may therefore contribute to CPI inefficacy.

Current international guidelines recommend the use of radiotherapy in advanced ACC for local tumor control [11]. However, irradiation of tumors can also lead to systemic responses. The term “abscopal effect” was first coined in 1953 and is now used to describe immune-mediated regression of non-treated metastasis after irradiation of a tumor [12, 13]. The effect is rare in humans with radiotherapy alone, but the advent of immunotherapies brought opportunities to boost the frequency and efficacy of abscopal responses [14, 15].

So far, only very limited data on the abscopal effect in ACC exist and to our knowledge there are no reports of the combination of high dose radiotherapy and immune checkpoint blockade for the treatment of this disease. Radiotherapy with low doses per fraction appears to lead to low immunogenicity [16]. Intriguingly, high-dose-rate brachytherapy (HDR-BT), a catheter-based internal radiotherapy, delivers a high dose of radiation per session, which may be beneficial for inducing immunogenic cell death and systemic antitumoral immune responses. Another advantage of brachytherapy might be the highly focused application of radiation, sparing

the tumor draining lymph nodes and possibly reducing radiation induced lymphocytopenia.

Here we review our experience with treatment of advanced ACC combining pembrolizumab and HDR-BT.

Patients and Methods

This report is a retrospective analysis of three cases at a single center. Data were retrieved from routine clinical records. Adverse events were graded according to the Common Terminology Criteria for Adverse Events Version 5.0.

Ethics Statement

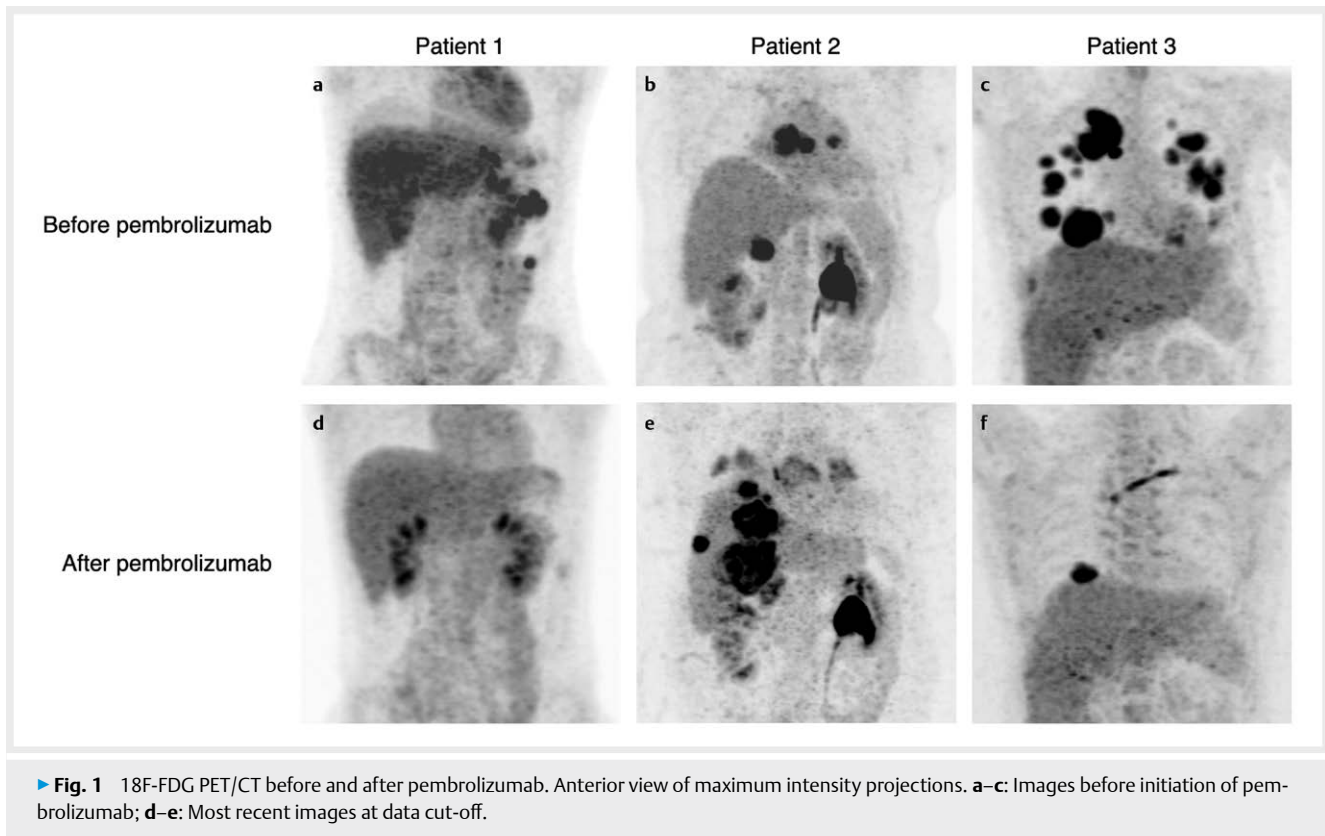
All patients were participants in the European Network for the Study of Adrenal Tumors (ENSAT) registry study which has been approved by the local ethics committee under approval number 379–10. All patients provided written consent. Cut-off for data collection was May 15, 2023.

Case 1

Patient 1 is female and was diagnosed with ENSAT stage III glucocorticoid and androgen producing adrenocortical carcinoma (pT3, pN1, L1, V1, Pn1) at 20 years of age. She underwent right sided adrenalectomy with lymphadenectomy shortly after initial diagnosis. Due to tumor stage and R1 resection status mitotane therapy was started 18 days postoperatively. Approximately two months after adrenalectomy the patient showed symptomatic disease progression with abdominal pain and acute abdominal hemorrhage from a new subphrenic metastasis involving the spleen. Emergency splenectomy was performed, and histopathology confirmed a metastasis of ACC. Systemic chemotherapy with etoposide, doxorubicin and cisplatin (EDP) was initiated. Restaging approximately one month after administration of the third cycle of EDP with continued mitotane (EDP-M) showed progressive disease with two new liver metastases while there was no evidence of peritoneal seeding. We performed HDR-BT of both liver lesions to a tumor enclosing dose of 25 Gy using ¹⁹²Ir.

After six weeks, no metabolic activity of the irradiated liver metastases was demonstrated in 18F-FDG PET/CT (¹⁸F-fluorodeoxyglucose Positron Emission Tomography combined with Computed Tomography) imaging but new metastases were documented intraperitoneally in contact with the large curvature of the stomach, caudal to the left kidney, and in the liver. EDP-M was reinitiated for four further cycles, but the subsequent PET/CT showed progressive disease again. The decision was made to treat the third liver metastasis with HDR-BT (25 Gy) and the peritoneal metastasis with magnetic resonance imaging (MRI)-guided external stereotactic body radiation therapy (5 × 6 Gy, 65% isodose). After a total of seven cycles, EDP-M was discontinued with disease progression of hepatic and peritoneal metastases (► Fig. 1a).

Fourteen months after initial diagnosis of ACC and seven months after the first HDR-BT, off label immunotherapy with pembrolizumab (200 mg q3w) was started and mitotane was discontinued. Restaging after six cycles of CPI therapy revealed regression of all metastases but still showed FDG uptake in a pararenal tumor. After two more cycles of pembrolizumab, a third HDR-BT was performed. 20 Gy were applied to the left sided pararenal metastasis. The following



► **Fig. 1** 18F-FDG PET/CT before and after pembrolizumab. Anterior view of maximum intensity projections. **a–c:** Images before initiation of pembrolizumab; **d–e:** Most recent images at data cut-off.

restaging visits showed continuing marked regression of systemic tumor burden.

After 14 cycles of pembrolizumab, the patient presented with hyperkalemia and was diagnosed with new onset hypoaldosteronism. Fludrocortisone replacement was started, and serum potassium normalized. After the 23rd cycle of pembrolizumab, the patient showed signs of autoimmune thyroiditis (grade 1) with transiently lowered TSH, which normalized over time without specific treatment. She also developed gastroduodenitis (grade 3) that required hospitalization. The etiology remained unclear but systemic CPI therapy and/or prior radiotherapy were deemed possible causes. After treatment with systemic glucocorticoids, symptoms improved. At the latest oncologic follow up 2.5 years after initial diagnosis of ACC, the patient did not show any metabolically active tumor on 18F-FDG PET/CT imaging (► **Fig. 1d**).

Case 2

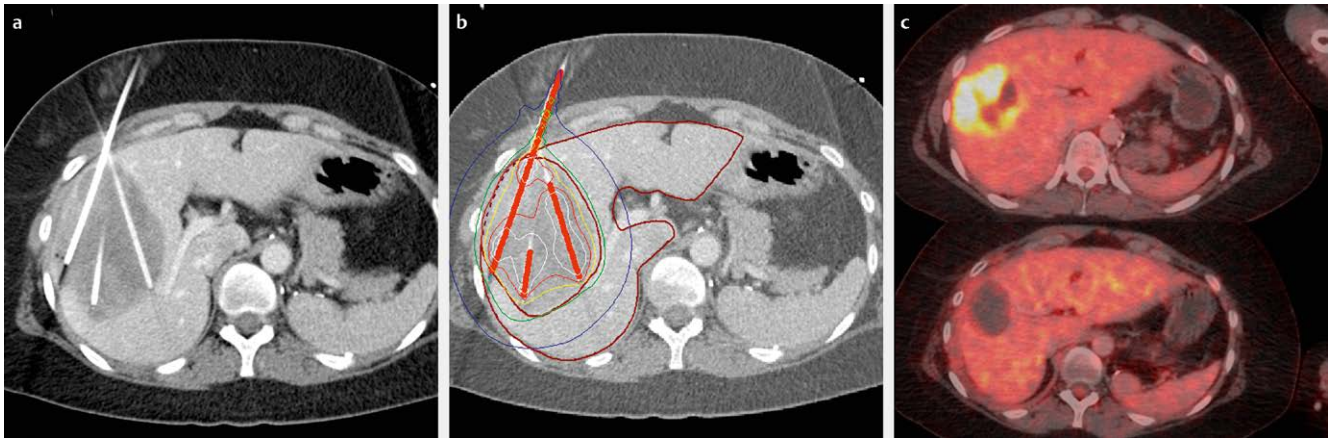
Patient 2, a 53-year-old woman with resistant hypertension underwent laparoscopic adrenalectomy for suspected pheochromocytoma of 5.1 cm detected on MRI. Postoperative histopathology revealed ENSAT stage III adrenocortical carcinoma.

Shortly after the initial surgery, a second-look radical retroperitoneal lymphadenectomy was performed and could exclude lymph node metastases. Mitotane treatment was started postoperatively. Four months after surgery, there was no evidence of remaining ACC on 18F-FDG PET/CT. Due to side effects including fatigue, confusion, tremor, and impaired vision mitotane was discontinued after six months. One year after diagnosis, PET/CT showed local re-

currence and metastases in both lungs as well as mediastinal and hilar lymph node metastases. Therefore, chemotherapy with EDP was started. After six cycles of EDP (the last three of which combined with mitotane, EDP-M), restaging demonstrated a good response to treatment with significant regression of tumor burden. Mitotane monotherapy was continued but after three months, marked progression was observed. Severe polyneuropathy precluded a rechallenge with EDP, so the patient received streptozotocin instead. After the first cycle of streptozotocin, moderately hypofractionated intensity modulated radiotherapy of the local recurrence with 5×3 Gy per week to a total dose of 42 Gy using 6 MV photons was performed. The same radiation regimen was applied to the mediastinal lymph node metastases.

Under therapy with streptozotocin, progressive disease was evident with progression of pulmonary metastases and a new metastasis adjacent to the left kidney. The irradiated local recurrence only showed slight regression while the mediastinal lymph nodes responded well to radiation therapy. The decision was made to perform video assisted thoracoscopic surgery on one of the pulmonary metastases to obtain material for molecular analysis of the tumor. Mitotane was discontinued and EDP restarted again after improvement of polyneuropathy.

After another two cycles of EDP (total of eight cycles of EDP), 18F-FDG PET/CT showed further disease progression of virtually all non-irradiated metastases (► **Fig. 1b**). In light of this, we decided to start off-label treatment with 200 mg pembrolizumab q3w. Restaging after four cycles of pembrolizumab revealed progressive disease with new liver metastases. We decided to continue pembrolizumab beyond progression. Imaging after five months of pembrolizumab



► **Fig. 2** First HDR brachytherapy of patient 3. **a:** CT of three brachytherapy catheters placed into a liver metastasis; **b:** Calculated isodoses for brachytherapy of the same metastasis; **c:** 18F-FDG PET/CT before (top), and after (bottom) brachytherapy but before initiation of pembrolizumab.

demonstrated regression of most metastases, however the liver metastases increased in size and FDG uptake. Because of this, HDR-BT of three liver metastases using ^{192}Ir was performed to a dose of 20 Gy. Four months later, PET/CT showed a good local response to brachytherapy but overall, only a mixed response. We proceeded with HDR-BT of the newly developed liver metastases and a tumor of the left renal pelvis. 15 Gy and 16 Gy were applied, respectively. During this hospital stay, the patient suffered from severe hypertension and hypokalemia. Biochemically, she showed marked hypercortisolism so an adrenostatic therapy with metyrapone was initiated. One week later, HDR-BT with 20 Gy of one more liver lesion, the local recurrence and a pararenal tumor was performed.

At restaging after one month, the patient presented with progressive disease (► **Fig. 1e**) and overt Cushing's syndrome. She was admitted for medical treatment of the cortisol excess. During this stay she developed severe COVID-19. Despite antiviral therapy with remdesivir and molnupiravir, she developed deep vein thrombosis and pulmonary embolism (PE) as well as COVID-19 pneumonia. The patient died 2.5 years after the initial diagnosis of ACC from respiratory failure as a complication of COVID-19 with PE.

Case 3

Female patient 3 was diagnosed with adrenocortical carcinoma at the age of 27 years. Initially, she presented with adrenal Cushing's syndrome and a left sided adrenal tumor. Biochemically, she showed cortisol and androgen excess. She underwent left sided adrenalectomy, nephrectomy, ureterectomy and retroperitoneal lymphadenectomy. Histopathology revealed ENSAT stage III ACC. Mitotane was started shortly after surgery. Lung metastases appeared seven months later. The patient declined chemotherapy with EDP at that point. Instead, the mitotane dose was increased due to subtherapeutic plasma levels.

At the next visit three months later, imaging revealed progressive pulmonary metastases. The decision was made to start EDP-M. Two days after the second cycle, the patient presented to our emergency department with an influenza A infection and moderately severe adrenal crisis, which had to be treated with i. v. hydrocortisone. Staging after the third cycle of EDP-M demonstrated sta-

ble disease and we chose to continue therapy with another three cycles of EDP-M. PET/CT after six cycles of chemotherapy continued to show stable disease, so we decided to surgically remove the two pulmonary metastases. Additional radical thoracic lymphadenectomy did not show any affected lymph nodes. At the next two follow up visits after surgery, imaging showed no remaining tumor.

The following restaging revealed a new lesion of the right lung that progressed consecutively. Thirty-nine months after initial diagnosis, there was evidence of a large liver metastasis as well as progressive pulmonary metastases. The single liver metastasis was treated with two sessions of HDR-BT with doses of 20 Gy each (► **Fig. 2**). Seven months after brachytherapy, the liver metastasis showed further regression, but pulmonary metastases had progressed significantly. Second line chemotherapy with streptozotocin was initiated but followed by progressive disease after four cycles with continued mitotane. Due to further progression of pulmonary metastases, we decided to start treatment with temozolomide. 18F-FDG PET/CT after three cycles demonstrated marked progression of pulmonary metastatic burden (► **Fig. 1c**) before CPI therapy with 200 mg of pembrolizumab q3w was started. The first evaluation after four cycles of pembrolizumab revealed a mixed response with mainly regressive pulmonary metastases, so immunotherapy was continued. After the fifth cycle, the patient developed a grade 3 CPI-induced colitis which required hospital admission and i. v. prednisolone. Pembrolizumab was paused for one month. Following re-initiation of pembrolizumab, grade 3 CPI-induced colitis recurred. After a four month pause of pembrolizumab and starting infliximab therapy, immune checkpoint blockade was resumed.

Staging after ten cycles of pembrolizumab demonstrated a pronounced partial remission with significant reduction of pulmonary metastatic burden and no new metastases. Immunotherapy had to be halted due to grade 2 pneumonitis. Imaging following five months without antitumoral therapy showed stable disease. One month later, the patient presented to our emergency department with headache, vomiting and incomplete left hemianopsia due to a large parietooccipital metastasis of the right hemisphere with perifocal edema and a midline shift. The tumor was resected, and

► **Table 1** Patient characteristics.

	Patient 1	Patient 2	Patient 3
Sex	female	female	female
Age at diagnosis (years)	20	53	27
ENSAT Stage at diagnosis	III	III	III
Ki67 expression of primary tumor	30 %	20 %	15 %
MMR protein expression	intact	intact	intact
PD-L1 expression	TPS 1%, IC score 0%, CPS 1	no expression	no expression
Steroid excess	A, G	A, G	A, G
Mitotane	yes	yes	yes
EDP (cycles)	7	8	6
Streptozotocin (cycles)	–	4	4
Temozolomide (cycles)	–	–	3
Metastases	liver, pararenal, subphrenic, intraperitoneal	liver, pararenal, lungs, mediastinal LN	liver, lungs, brain
Status at data collection cut-off	complete remission	deceased	partial remission

MMR: Mismatch repair (MLH1, MSH2, MSH6, PMS2); A: Androgens; G: Glucocorticoids; TPS: Tumor proportion score; IC: Immune cell; CPS: Combined positive score.

the resection cavity was stereotactically irradiated with 5 × 5 Gy to 25 Gy, 80 % isodose. At the latest follow up, four months after diagnosis of the brain metastasis and seven years after initial diagnosis of ACC, the 18F-FDG PET/CT showed only a single metabolically active metastasis in the right lung (► **Fig. 1f**). This lesion was treated with stereotactic radiotherapy in 3 fractions of 13.5 Gy, 65 % isodose.

Discussion

Here we present three cases of female patients with metastatic adrenocortical carcinoma and progressive disease after standard chemotherapy regimens (► **Table 1**). All of them received HDR-BT of metastases as well as CPI therapy with pembrolizumab (► **Table 2**). The two patients who underwent brachytherapy before CPI initiation (Cases 1 and 3) demonstrated marked therapy response but also suffered from grade 3 immune-related adverse events (irAE). The third patient (Case 2) was started on pembrolizumab prior to brachytherapy and developed uncontrolled glucocorticoid excess. She did not experience irAE but also did not respond to CPI treatment. At the latest follow up, one patient was in complete remission, one patient had a pronounced treatment response with only one metabolically active metastasis remaining on 18F-FDG PET/CT and one patient had died.

Currently, only very limited therapeutic options for advanced ACC exist [11, 17]. Beyond mitotane, which has a response rate of approximately 20 % in monotherapy [18], EDP-M is the only treatment with strong evidence for efficacy. Immune checkpoint blockade has been used successfully in a wide range of different malignancies and presents a promising therapeutic option for rare cancers. In ACC, a limited number of mostly small prospective trials

with CPI therapy have been performed. These studies demonstrated relatively low efficacy [2–6]. The largest and most recent retrospective analysis reported objective response rates of 13.5 % to immune checkpoint blockade in ACC [9].

Low effectiveness of active immunotherapies like CPI in ACC may in part be due to the immunosuppressive microenvironment of cortisol-producing tumors. Landwehr et al. demonstrated that glucocorticoid excess correlates with reduced T cell infiltration and worse prognosis in ACC [10]. In accordance with this hypothesis, in patient 2, who showed overt cortisol excess despite high dose medical treatment, initial response of some metastases to checkpoint blockade could not be sustained. Looking into this potential mechanism as a treatment strategy, there is currently an active trial investigating a combination therapy of pembrolizumab and relacorilant, a glucocorticoid receptor antagonist (NCT04373265). Patients 1 and 3, who had a pronounced systemic response to CPI treatment, were on hydrocortisone replacement during immunotherapy and did not show signs of hypercortisolism.

Radiotherapy plays an increasing role in the treatment of ACC. It can be beneficial both adjuvantly, in patients at high risk of recurrence [19], but also in the management of metastases [20–22]. Radiotherapy is therefore recommended by current guidelines for the control of imminent complications or oligometastatic disease [23]. Additionally, there is preliminary evidence that peptide receptor radionuclide therapy may be beneficial in some patients with ACC [24].

While evidence is accumulating for the use of locoregional therapies such as cryoablation [25] or radiofrequency ablation [26] in oligometastatic ACC, experience with HDR-BT in ACC has not been reported to our knowledge. Our case series demonstrates the favorable local outcome of this interventional method with complete

► **Table 2** Summary of CPI treatments and radiotherapies.

	Patient 1	Patient 2	Patient 3
Pembrolizumab (cycles)	23	15	10
irAE	thyroiditis grade 1, gastroduodenitis grade 3	–	colitis grade 3, pneumonitis grade 2
EBRT	retroperitoneal soft tissue	local recurrence, mediastinum	brain, lung
Total dose, isodose and fractions	30 Gy, 65% isodose, 5 fractions	42 Gy each, ICRU, 14 fractions	brain: 25 Gy, 80% isodose, 5 fractions lung: 40.5 Gy, 65% isodose, 3 fractions
Time from diagnosis to first brachytherapy (years)	0.6	2.9	3.4
Brachytherapy #1 location	liver	liver	liver
Dose	25 Gy each (2 lesions)	20 Gy & 19 Gy (2 lesions)	20 Gy each (3 lesions)
Brachytherapy #2 location	liver	liver, renal	liver
Dose	25 Gy	15 Gy & 16 Gy (2 lesions)	20 Gy
Brachytherapy #3 location	pararenal	liver, pararenal, adrenal	–
Dose	20 Gy each (2 lesions)	20 Gy each (3 lesions)	–
Best response local	CR	PR	PR
Best response systemic	CR	PR	PR

EDP: Etoposide, doxorubicin, cisplatin; irAE: Immune-related adverse events; EBRT: External beam radiation therapy; ICRU: International Commission on Radiation Units and Measurements; CR: Complete remission; PR: Partial remission.

or partial remission observed in all treated metastases. Of note, two of the patients presented in this study not only benefited from ablation of liver metastases through brachytherapy but also received successful ablative treatment of retroperitoneal metastases supporting the feasibility of HDR-BT in the treatment of multiple tumoral locations.

It is important to note that beyond local tumor control, two of the patients experienced profound remissions of their advanced ACC. Indeed, the marked morphological and metabolic response of pulmonary and abdominal metastases, which were not treated with HDR-BT, is suggestive of an abscopal effect. Radiotherapy leads to the release of antigens from tumor cells in combination with damage associated molecular patterns [27]. This immunogenic cell death caused by ionizing radiation can induce T cell priming and is thought to be a key mechanism behind the abscopal effect. The addition of radiotherapy to CPI treatment can lead to an improved systemic antitumoral immune response [28]. However, using low doses per fraction appears to come with reduced immunogenicity [16]. Intriguingly, brachytherapy delivers a high dose of radiation per session, which may be beneficial for inducing immunogenic cell death and a systemic antitumoral immune response. Another advantage of combining brachytherapy with immunotherapy might be the highly focused application of radiation sparing the tumor draining lymph nodes, which play an important role in the generation of an abscopal effect [29].

Preclinical data show that the timing of checkpoint blockade in relation to radiotherapy matters and that CPI application after irradiation can lead to an enhancement of the abscopal effect as compared to the inverse sequence of treatments [30, 31]. The two patients in this series who responded well to CPI treatment under-

went brachytherapy prior to pembrolizumab. The patient who received brachytherapy after initiation of pembrolizumab demonstrated a limited systemic response even though it must be considered that she had been treated with image-guided radiation therapy of the lung hilus seven months prior to initiation of CPI.

It has to be noted, that one of the responders experienced a symptomatic brain metastasis after CPI treatment, which is an extremely rare occurrence in ACC otherwise. It is possible that the therapeutic pressure of immune checkpoint blockade favored escape in the immunologically privileged central nervous system. Brain imaging should therefore be considered in patients with ACC who respond to immunotherapy.

Several important limitations apply to this report. First, this is a very small retrospective case series in a single center setting with pronounced heterogeneity of patient characteristics and both prior and concurrent therapies (► **Table 1**). It must be noted that all patients had previously received but discontinued mitotane at the time of immunotherapy and demonstrated subtherapeutic plasma concentrations (8.87 mg/l, 7.36 mg/l, 6.6 mg/l in patients 1–3, respectively) before initiation of pembrolizumab. The two patients who showed a pronounced systemic response to immunotherapy were taking mitotane during their initial brachytherapies. Presently, the immunological impact of mitotane is unknown. There are open questions whether mitotane can induce immunogenic cell death and if synchronous combination of mitotane with CPI may adversely impact the antitumoral immune response. Of note, mitotane treatment was permitted in some but excluded in other published trials of immunotherapy in ACC [2–6]. However, this did not explain the different outcomes. In a large retrospective case series, mitotane treatment appeared to be associated with shorter pro-

gression-free and overall survival in patients treated with pembrolizumab and nivolumab [9].

Additionally, all patients had tumors characterized by androgen and cortisol secretion. Effects of this treatment approach on non-secreting tumor could not be assessed in study.

Finally, in many reference centers HDR-BT is not available due to the specialized infrastructure and expertise required in both interventional radiology and radiation oncology.

Conclusion

In conclusion, these cases highlight the opportunities of combining immune checkpoint blockade with HDR-BT in advanced adrenocortical carcinoma. Our observations provide a rationale for future prospective observational trials evaluating the efficacy of combination treatments and highlight the potential relevance of insufficient T cell priming in ACC.

Contribution to Authorship

P.S., S.C., M.S., P.Z., J.S., T.M., A.T., T.K., M.P., T.P., I.W., R.S. and M.K. contributed data and tissue specimens. P.S., M.K. analyzed data. T.K. analyzed tissue specimens. M.K. designed the study. C.B., J.R., M.R., R.S. and M.K. supervised the research. P.S. and M.K. wrote the initial draft of the manuscript; all authors contributed to the correction of the manuscript and approved it in its final form.

Funding Information

Rare Important Syndromes in Endocrinology (RISE) — Eva Luise und Horst Köhler Stiftung & Else Kröner-Fresenius-Stiftung; German Research Foundation (DFG), collaborative research center 205 "The adrenal: central relay in health and disease" (project number 314061271).

Acknowledgements

We would like to thank Isabella Kinker and Petra Rank for the processing and management of biosamples.

Conflict of Interest

The authors declare that they have no conflict of interest.

References

- Fassnacht M, Terzolo M, Allolio B et al. Combination chemotherapy in advanced adrenocortical carcinoma. *N Engl J Med* 2012; 366: 2189–2197
- Le Tourneau C, Hoimes C, Zarwan C et al. Avelumab in patients with previously treated metastatic adrenocortical carcinoma: phase 1b results from the JAVELIN solid tumor trial. *J Immunother Cancer* 2018; 6: 111
- Carneiro BA, Konda B, Costa RB et al. Nivolumab in metastatic adrenocortical carcinoma: results of a phase 2 trial. *J Clin Endocrinol Metab* 2019; 104: 6193–6200
- Habra MA, Stephen B, Campbell M et al. Phase II clinical trial of pembrolizumab efficacy and safety in advanced adrenocortical carcinoma. *J Immunother Cancer* 2019; 7: 253
- Raj N, Zheng Y, Kelly V et al. PD-1 Blockade in advanced adrenocortical carcinoma. *J Clin Oncol* 2020; 38: 71–80
- Klein O, Senko C, Carlino MS et al. Combination immunotherapy with ipilimumab and nivolumab in patients with advanced adrenocortical carcinoma: a subgroup analysis of CA209-538. *Oncoimmunology* 2021; 10: 1908771
- Maleki Vareki S, Garrigos C, Duran I. Biomarkers of response to PD-1/PD-L1 inhibition. *Crit Rev Oncol Hematol* 2017; 116: 116–124
- Fay AP, Signoretti S, Callea M et al. Programmed death ligand-1 expression in adrenocortical carcinoma: an exploratory biomarker study. *J Immunother Cancer* 2015; 3: 3
- Remde H, Schmidt-Pennington L, Reuter M et al. Outcome of immunotherapy in adrenocortical carcinoma: a retrospective cohort study. *Eur J Endocrinol* 2023; 188: 485–493
- Landwehr LS, Altieri B, Schreiner J et al. Interplay between glucocorticoids and tumor-infiltrating lymphocytes on the prognosis of adrenocortical carcinoma. *J Immunother Cancer* 2020; 8:
- Fassnacht M, Assie G, Baudin E et al. Adrenocortical carcinomas and malignant pheochromocytomas: ESMO-EURACAN clinical practice guidelines for diagnosis, treatment and follow-up. *Ann Oncol* 2020; 31: 1476–1490
- Demaria S, Ng B, Devitt ML et al. Ionizing radiation inhibition of distant untreated tumors (abscopal effect) is immune mediated. *Int J Radiat Oncol Biol Phys* 2004; 58: 862–870
- Mole RH. Whole body irradiation; radiobiology or medicine? *Br J Radiol* 1953; 26: 234–241
- Abuodeh Y, Venkat P, Kim S. Systematic review of case reports on the abscopal effect. *Curr Probl Cancer* 2016; 40: 25–37
- Twyman-Saint Victor C, Rech AJ, Maity A et al. Radiation and dual checkpoint blockade activate non-redundant immune mechanisms in cancer. *Nature* 2015; 520: 373–377
- Reijnen E, De Mey S, De Mey W et al. Fractionated radiation severely reduces the number of CD8+ T cells and mature antigen presenting cells within lung tumors. *Int J Radiat Oncol Biol Phys* 2021; 111: 272–283
- Megerle F, Kroiss M, Hahner S et al. Advanced adrenocortical carcinoma – what to do when first-line therapy fails? *Exp Clin Endocrinol Diabetes* 2019; 127: 109–116
- Megerle F, Herrmann W, Schloetelburg W et al. Mitotane monotherapy in patients with advanced adrenocortical carcinoma. *J Clin Endocrinol Metab* 2018; 103: 1686–1695
- Fassnacht M, Hahner S, Polat B et al. Efficacy of adjuvant radiotherapy of the tumor bed on local recurrence of adrenocortical carcinoma. *J Clin Endocrinol Metab* 2006; 91: 4501–4504
- Khosla D, Kapoor R, Singla AK et al. Treatment outcomes of adjuvant radiotherapy in adrenocortical carcinoma – a 13-years experience from a tertiary care centre. *Rare Tumors* 2023; 15: 20363613231160699
- Kimpel O, Schindler P, Schmidt-Pennington L et al. Efficacy and safety of radiation therapy in advanced adrenocortical carcinoma. *Br J Cancer* 2023; 128: 586–593
- Polat B, Fassnacht M, Pfreundner L et al. Radiotherapy in adrenocortical carcinoma. *Cancer* 2009; 115: 2816–2823
- Fassnacht M, Dekkers OM, Else T et al. European society of endocrinology clinical practice guidelines on the management of adrenocortical carcinoma in adults, in collaboration with the European network for the study of adrenal tumors. *Eur J Endocrinol* 2018; 179: G1–G46

- [24] Grisanti S, Filice A, Basile V et al. Treatment with 90Y/177Lu-DOTATOC in patients with metastatic adrenocortical carcinoma expressing somatostatin receptors. *J Clin Endocrinol Metab* 2020; 105:
- [25] Lin TY, Lin KY, Kuo HY et al. Yttrium-90 selective internal radiation therapy plus cryoablation for recurrent adrenocortical carcinoma with liver metastases. *J Endocr Soc* 2022; 6: bvac091
- [26] Roux C, Boileve A, Faron M et al. Loco-regional therapies in oligometastatic adrenocortical carcinoma. *Cancers (Basel)* 2022; 14
- [27] Hannon G, Lesch ML, Gerber SA. Harnessing the immunological effects of radiation to improve immunotherapies in cancer. *Int J Mol Sci* 2023; 24:
- [28] Theelen W, Chen D, Verma V et al. Pembrolizumab with or without radiotherapy for metastatic non-small-cell lung cancer: a pooled analysis of two randomised trials. *Lancet Respir Med* 2021; 9: 467–475
- [29] Buchwald ZS, Nasti TH, Lee J et al. Tumor-draining lymph node is important for a robust abscopal effect stimulated by radiotherapy. *J Immunother Cancer* 2020; 8: doi: 10.1136/jitc-2020-000867
- [30] Wei J, Montalvo-Ortiz W, Yu L et al. Sequence of alphaPD-1 relative to local tumor irradiation determines the induction of abscopal antitumor immune responses. *Sci Immunol* 2021; 6: doi: 10.1126/sciimmunol.abg0117
- [31] Young KH, Baird JR, Savage T et al. Optimizing timing of immunotherapy improves control of tumors by hypofractionated radiation therapy. *PLoS One* 2016; 11: e0157164