

Management of congenital urogenital and perineal vascular malformations: correlation of clinical findings with diagnostic imaging for treatment decision

Management von kongenitalen Gefäßmalformationen des Urogenitaltraktes und der Perinealregion: Korrelation von Klinik und diagnostischer Bildgebung für eine adäquate Therapieentscheidung

Authors

Nadja Grill¹, Felix Struebing², Christel Weiss³, Stefan O Schönberg¹, Maliha Sadick¹

Affiliations

- 1 Clinic for Radiology and Nuclear Medicine, University Medical Centre Mannheim, Germany
- 2 Department of Hand, Plastic and Reconstructive Surgery, Burn Center, BG Trauma Centre Ludwigshafen, Germany
- 3 Department of Medical Statistics, Biomathematics and Information Processing, Medical Faculty Mannheim, Ruprecht-Karls-University of Heidelberg, Heidelberg, Mannheim, Germany

Key words

vascular, interventional procedures, vascular malformations

received 25.09.2022

accepted 28.06.2023

published online 03.11.2023

Bibliography

Fortschr Röntgenstr 2024; 196: 186–194

DOI 10.1055/a-2127-4132

ISSN 1438-9029

© 2023. Thieme. All rights reserved.

Georg Thieme Verlag KG, Rüdigerstraße 14,
70469 Stuttgart, Germany

Correspondence

Nadja Grill

Clinic for Radiology and Nuclear Medicine, University Medical Centre Mannheim, Theodor-Kutzer-Ufer 1–3,
68135 Mannheim, Germany
Tel.: +49/6 21/3 83 22 76
nadja.grill@umm.de

ABSTRACT

Purpose Analysis of clinical and diagnostic findings in rare urogenital and perineal vascular malformations only occurring in 2–3 % of vascular anomalies with regard to clinical symptoms and treatment decisions.

Materials and Methods All 25 out of 537 patients presenting with congenital urogenital and perineal vascular malformations at our institution from 2014 to 2021 were included. Vascular anomaly classification, anatomical location, clinical

symptoms at presentation, diagnostic imaging, and pain intensity were retrospectively assessed from the patient record and therapy management was evaluated.

Results In total, 25 patients (10 females (40 %), 15 males (60 %)), aged 6 to 77 years were included. Diagnoses were: 10 (40 %) venous malformations (VMs), 5 (20 %) lymphatic malformations (LMs) and 10 (40 %) arteriovenous malformations (AVMs). Malformation manifestations were: 12 (32 %) lesser pelvis, 12 (32 %) external genitalia, and 13 (34 %) perineal/gluteal region. One AVM was located in the kidney. The leading clinical symptom was pain. The mean intensity was 6.0/10 for LM, 5.7/10 for VM, and 4.5/10 for AVM. Further major symptoms included physical impairment, local swelling, and skin discoloration. Bleeding complications or sexual dysfunction were rare findings. Patients with VM reported significantly more symptoms than patients with AVM ($p = 0.0129$). In 13 patients (52 %) minimally invasive therapy was indicated: 10 (77 %) sclerotherapies and 3 (23 %) transcatheter embolization procedures. Complete symptomatic remission was achieved in 9 (69 %) patients, partial response in 3 (23 %) patients, and 1 patient showed no clinical response to therapy. Follow-up appointments without the need for immediate minimally invasive therapy were significantly more common in patients with AVMs than in patients with VMs ($p = 0.0198$).

Conclusion To create a higher awareness of congenital urogenital and perineal vascular malformations. Awareness of this rare condition avoids misdiagnosis. Therapy decisions should be symptom-oriented. Emergency intervention is rarely required, even in fast-flow vascular malformations.

Key Points:

- Venous malformations cause more symptoms with higher pain intensity than arteriovenous malformations.
- Diagnosis and adequate treatment can be hampered by a lack of awareness of the clinical presentation.
- Bleeding complications are rare, even in high-flow vascular malformations.
- Pain and physical impairment are the most commonly observed symptoms in these patients.

ZUSAMMENFASSUNG

Ziel Ziel dieser Arbeit ist die Analyse des Zusammenhangs von klinischen Befunden, Symptomen und bildgebenden Informationen bei seltenen urogenitalen und perinealen Gefäßmalformationen, die mit einer Häufigkeit von lediglich 2–3 % vorkommen, zwecks Optimierung der therapeutischen Entscheidungsfindung.

Material und Methoden Zwischen 2014 und 2021 stellten sich 25 von insgesamt 537 Patienten mit einer Gefäßanomalie des Urogenitaltraktes oder der Perinealregion in unserem Interdisziplinären Gefäßanomaliezentrum vor. Es erfolgte eine retrospektive Erhebung der Gefäßanomalieklassifikation, der anatomischen Lokalisation, der klinischen Symptome zum Zeitpunkt der Erstvorstellung, Informationen der diagnostischen Bildgebung und Schmerzintensität aus der Patientenakte und deren Analyse.

Ergebnisse Es wurden 25 Patienten, davon 10 Frauen (40 %) und 15 Männer (60 %), im Alter von 6 bis 77 Jahre eingeschlossen. Diagnostiziert wurden 10 (40 %) venöse Malformationen, 5 (20 %) lymphatische Malformationen und 10 (40 %) arteriovenöse Malformationen, wovon 12 (32 %) Malformationen im kleinen Becken, 12 (32 %) an den äußeren Genitalien und 13 (34 %) in der Perineal-/Glutealregion lokalisiert waren. Eine arteriovenöse Malformation befand sich in der Niere. Das führende klinische Symptom war Schmerz mit einer durchschnittlichen Intensität von 6,0/10 bei lymphatischen Malformationen, 5,7/10 bei venösen Malformationen und 4,5/10 bei arteriovenösen Malformationen. Weitere häufige Symptome waren eine körperliche Beeinträchtigung, lokale Schwellung und Hautdiskolorationen. Blutungskomplikationen oder sexuelle Dysfunktion traten selten auf. Patienten mit venösen Malformationen berichteten von signifikant häufigeren Symptomen als Patienten mit einer arteriovenösen

Malformation ($p = 0,0129$). Bei 13 (52 %) Patienten bestand die Indikation zur minimal-invasiven Therapie. Es wurden 10 (77 %) Sklerotherapien und 3 (23 %) Embolisationen mit symptomatisch 69 % kompletter und 23 % partieller Remission durchgeführt. 1 Patient profitierte klinisch nicht von der durchgeführten Sklerotherapie. Ambulante Kontrollvorstellungen ohne die Notwendigkeit einer zeitnahen minimal-invasiven Therapie waren bei Patienten mit einer arteriovenösen Malformation signifikant häufiger möglich als bei Patienten mit einer venösen Malformation ($p = 0,0198$).

Schlussfolgerung Eine interdisziplinäre Sensibilisierung für diese seltene Erkrankung, insbesondere für urogenitale und perineale Gefäßmalformationen ist notwendig, um eine adäquate, symptomorientierte Therapieentscheidung treffen zu können. Notfalleingriffe sind selten notwendig, auch nicht bei fast-flow-Malformationen.

Kernaussagen:

- Venöse Malformationen verursachen mehr Symptome und eine höhere Schmerzintensität als arteriovenöse Malformationen.
- Unwissenheit für die klinische Präsentation führt zu Verzögerung von Diagnose und Therapie.
- Blutungskomplikationen sind selten, auch in fast-flow-Malformationen.
- Schmerz und körperliche Beeinträchtigung sind die häufigsten Symptome in diesem Patientenkollektiv.

Zitierweise

- Grill N, Struebing F, Weiss C et al. Management of congenital urogenital and perineal vascular malformations: correlation of clinical findings with diagnostic imaging for treatment decision. *Fortschr Röntgenstr* 2024; 196: 186–194

Introduction

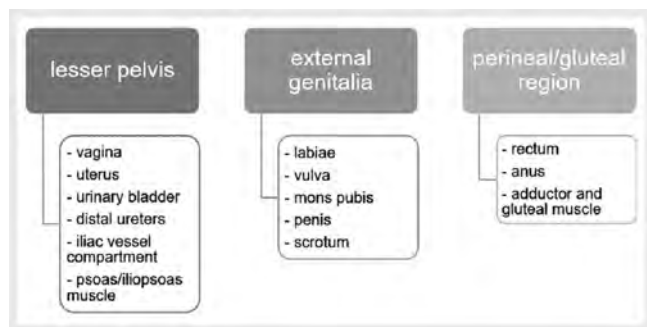
Vascular anomalies (VAs) are a rare disease. According to the classification of the International Society for the Study of Vascular Anomalies (ISSVA), as proposed by Mulliken and Glowacki in 1982 [1], they can be divided into two main groups: vascular tumors and vascular malformations [2]. Vascular malformations arise from dysmorphogenesis and mostly occur sporadically but also may be based on germinal mutation [3]. They are also classified by their rheological characteristics as slow-flow and fast-flow lesions [4]. Slow-flow lesions include capillary, lymphatic, and venous malformations, while arteriovenous malformations, for example, are fast-flow lesions [3].

Simple slow-flow vascular anomalies, including venous malformations (VM) and lymphatic malformations (LM), are usually present at birth and do not regress spontaneously. They can affect multiple tissue levels (cutaneous, subcutaneous, intramuscular, fatty tissue, and bone) [3, 5, 6]. Skin discoloration and swelling are main clinical symptoms [5–7]. While superficial VMs are often accompanied by a prominent blue skin discoloration, LMs can

show a red or brown skin color [6]. Especially VMs tend to grow during childhood and puberty [3, 8]. In the case of thrombophlebitis and muscular or articular involvement, VMs can cause pain [8]. The primary treatment is sclerotherapy [3, 8–10]. For peripheral VMs involving extremities, compression garments are a main pillar of conservative treatment [10, 11].

Arteriovenous malformations (AVMs) are mainly congenital like VMs and LMs and seldom acquired on a secondary basis, like uterine AVMs after caesarean section or trauma [12, 13]. Blushed skin, local warmth, and bruit are typical clinical findings of AVMs but their clinical detection is often hampered in the urogenital and perineal region. Complications, in the case of progression, can include ulceration or bleeding and cardiac insufficiency. AVMs need close monitoring. Indication for intervention is the prevention of local ulceration with infection and cardiopulmonary insufficiency [3, 9].

Urogenital and perineal vascular anomalies are very rare. In the literature there is very little data on overall incidence. In general, they account for 2–3 % of all VAs [14–17]. Diagnosis may be delayed because of the rather inconspicuous manifestation site or



► **Fig. 1** Overview of the classification of anatomical regions.

► **Abb. 1** Überblick über die Einteilung der anatomischen Regionen.

the patients' inability to disclose clinical and sexual symptoms to the treating physician. The spectrum of findings can vary from cosmetic concerns to deformities [15, 18], including local swelling with physical impairment such as difficulty walking or exercising [12]. Furthermore, hematuria or rectal bleeding may increase local discomfort when the urinary tract or the rectum wall is involved [13].

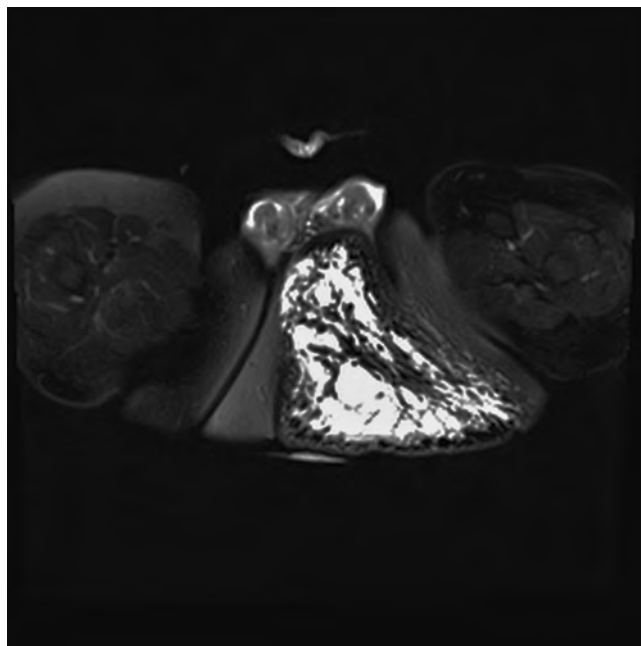
Awareness of vascular anomalies of the urogenital tract and perineal region with their pattern of spread, organ manifestation, and complications is therefore indispensable for adequate diagnosis and treatment.

Methods and Materials

Out of all patients with vascular anomalies who presented to our Interdisciplinary Center of Vascular Anomalies from 2014 to 2021, patients with vascular malformations of the pelvis and urogenital tract were identified and included in this retrospective analysis. For all patients consulted and treated in our Vascular Anomaly Center (VAC), an informed consent sheet signed by the patient was mandatory and an ethical approval decision from the local ethic committee was present. The clinical information, including classification of the vascular malformation, anatomical location, symptoms, pain intensity, imaging modalities, therapies prior to admission to the VAC and following treatment, was taken from the clinical record. Venous malformations were classified according to their Puig stage [19] and arteriovenous malformations by their Schobinger stage [20].

Depending on their anatomical site, the vascular anomalies were subdivided into three major groups (► **Fig. 1**).

The clinical symptoms were categorized into seven main groups: pain, swelling, bleeding, physical impairment, sexual dysfunction, discoloration of the skin, and bruit/pulsation. Sexual dysfunction included not only physical but also psychological problems like self-consciousness. Pain intensity was classified on a numeric scale ranging from 0 to 10 for adults and on a visual scale for children. Imaging modalities for the vascular anomalies included ultrasound, X-ray, computed tomography scan (CT), magnetic resonance imaging (MRI), and transcatheter angiography. Finally, treatment options were classified into three major categories: "no treatment at all", "treatment" (sclerotherapy,



► **Fig. 2** Venous malformation of the left scrotum and the perineal and gluteal area. Axial T2 TIRM (Turbo Inversion Recovery Magnitude) MRI sequence in a male patient with hyperintense clusters of venous malformations.

► **Abb. 2** Venöse Malformation des Skrotums sowie der Perineal- und Glutealregion links. Axiale T2-TIRM (Turbo Inversion Recovery Magnitude)-Sequenz im MRT eines männlichen Patienten mit hyperintensiven Cluster einer venösen Malformation.

embolization, conservative therapy with compression garments, surgery) and "other procedures" (diagnostic biopsy and follow-up appointments).

We compared and evaluated the differences between VMs and AVMs regarding variability and number of symptoms and pain intensity. In a second step we assessed diagnostic imaging tools and extracted treatment indication, based on the entire clinical information available.

For the statistical analysis the Fisher's exact test, Wilcoxon-Mann-Whitney-test, and the Cochran-Armitage test for trend were used.

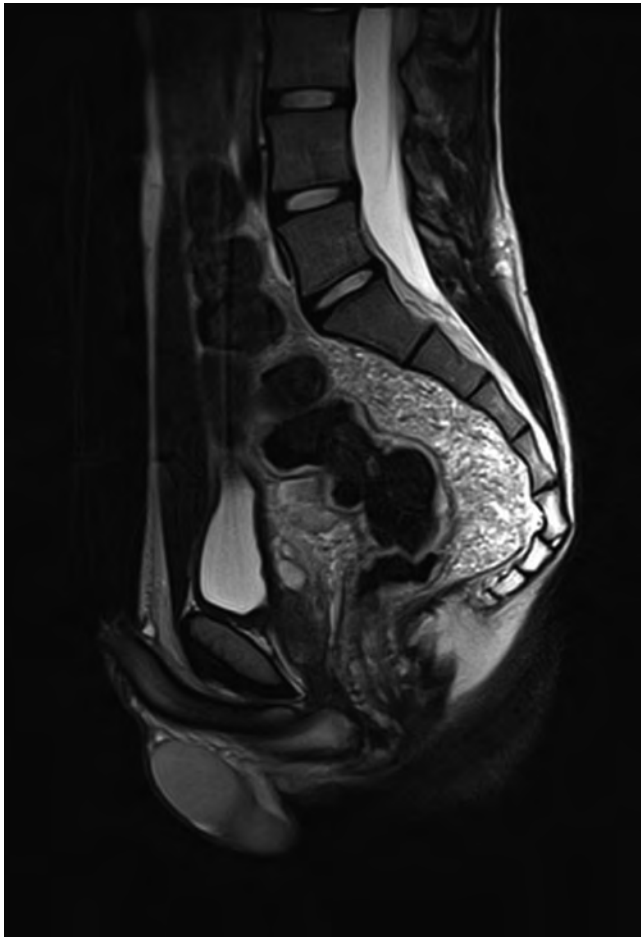Results

Patients

Out of 537 patients, all 25 with congenital vascular malformations of the pelvis and urogenital tract were included in the retrospective analysis: 10 female (40%) and 15 male (60%) patients with a mean age of 37.6 (ranging from 6 to 77 years).

Malformation Characteristics

The diagnosis was venous malformation in 10 (40%) patients (► **Fig. 2–4**), lymphatic malformation in 5 (20%) patients (► **Fig. 5**), and arteriovenous malformation in 10 (40%) patients



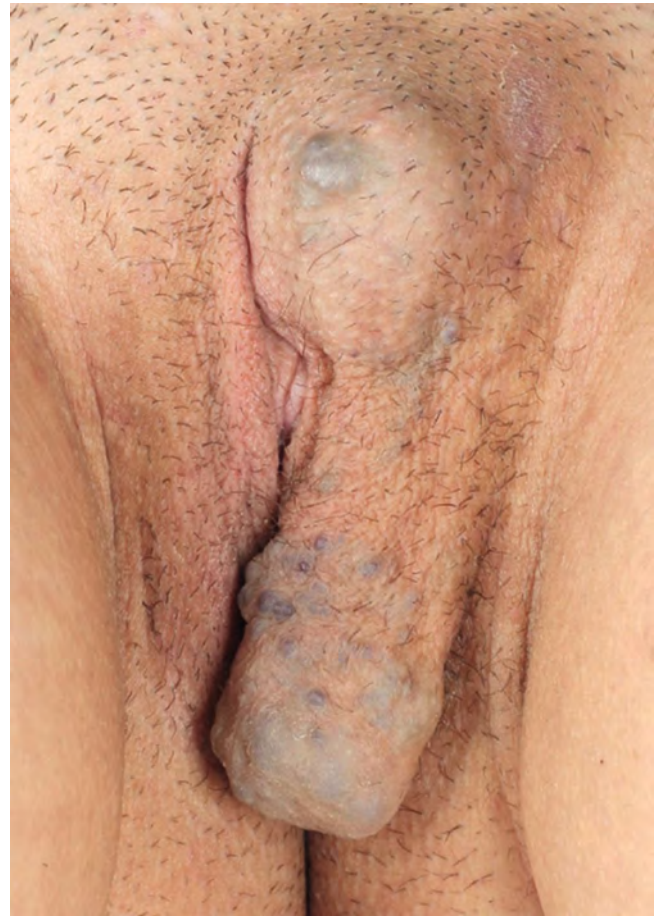► **Fig. 3** Retroperitoneal venous malformation with encasement of the rectum in a male patient on a sagittal T2 TSE (Turbo Spin Echo) MRI image. Compact hyperintense mass anterior and posterior to the rectal fossa.

► **Abb. 3** retroperitoneale venöse Malformation mit Ummauerung des Rektums bei einem männlichen Patienten in einem sagittalen T2-TSE (Turbo Spin Echo)-MRT-Bild. Kompakte hyperintense Masse ventral und dorsal im perirektalen Raum.

► **Fig. 6**). 34 % of malformations were located in the perineal/gluteal region, while 32 % involved the lesser pelvis and the external genitalia each. One AVM (2 %) was located in the kidney.

The external genitalia were more often affected by VMs (58 %). In a sub-analysis comparing AVMs to VMs, there was a significant difference ($p = 0.0198$) in the involvement of the external genitalia, which was present in 7 VMs, whereas only one AVM demonstrated involvement of this specific region. There was a slight predominance of the left side of the body. 9 AVMs were classified as Schobinger stage II and one AVM was assigned to stage I. Four VMs were classified into Puig stage I, three were assigned to stage II, and another three were classified as stage III.

The distribution of anatomical location was almost homogeneous between the lesser pelvis, external genitalia, and perineal/gluteal region (► **Table 1**). In the lesser pelvis and perineal/gluteal region, the distribution between VM and AVM was almost equal



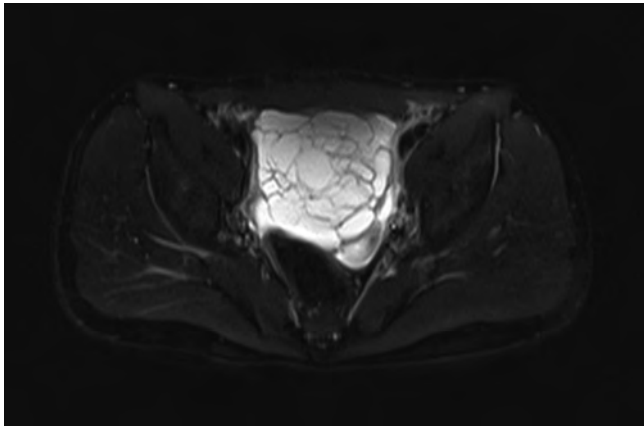
► **Fig. 4** Adolescent female patient with a venous malformation of the left labia majora and the mons pubis.

► **Abb. 4** venöse Malformation der Labia majora links und des Mons pubis bei einer jugendlichen Patientin.

with 6 AVMs vs. 5 VMs and 5 AVMs vs. 4 VMs. An overview of the cohort characteristics is available in ► **Table 1**.

Clinical Symptoms

The main clinical symptom in our patient cohort was pain (96 %). All of these patients complained of continuous episodes of pain which were problematic and resulted in consultation at our VAC. Patients with VMs and LMs suffered from a higher subjective pain level, their mean intensity was 5.7/10 (VM) and 6.0/10 (LM), compared to patients with AVMs who experienced an average pain level of 4.5/10. Physical impairment (76 %) and local swelling (72 %) were also very common symptoms. Physical impairment included difficulty or inability to walk an appropriate distance (more than 500 meters), to stand for a prolonged period, to be seated in a vertical position, or to exercise without pain. Less common symptoms included skin discoloration, bleeding complications of the vascular malformation, bruit and pulsation, and sexual dysfunction. There were no documented events of altered cardiac output or heart failure in connection with an AVM, based on echocardiography examination results. ► **Table 2** gives an overview of the clinical symptoms per vascular malformation.



► **Fig. 5** Lymphatic malformation in the lesser pelvis of a male patient on an axial T2 TIRM (Turbo Inversion Recovery Magnitude) MRI view with multiple hyperintense, partially septate parts of an LM.

► **Abb. 5** lymphatische Malformation im kleinen Becken eines männlichen Patienten auf einer T2-TIRM (Turbo Inversion Recovery Magnitude)-Sequenz im MRT mit Darstellung einer hyperintensiven, multiseptierten Malformation.

A sub-analysis comparing AVMs to VMs showed a significant difference in the number of symptoms per patient (mean 3.0 (VM) vs. 1.7 (AVM); trend test $p=0.0129$). Patients with VMs complained of overall more symptoms compared to patients with fast-flow vascular anomalies. According to the pathophysiological characteristics, solely patients with AVMs described local bruit and pulsation as a clinical symptom.

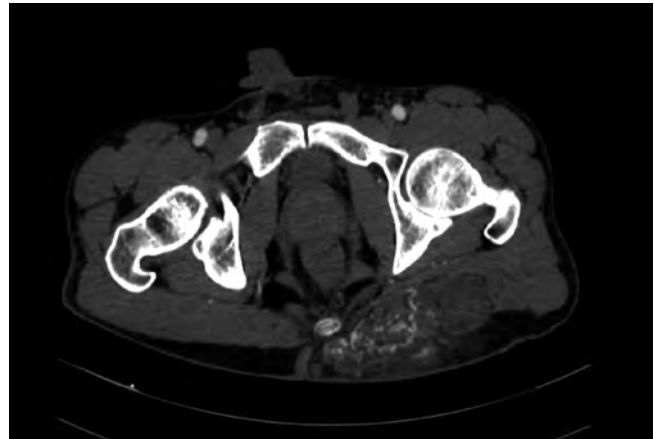
Imaging Modalities

The most commonly used imaging modality was MRI in 24 (96%) patients receiving cross-sectional examination followed by ultrasound which was performed in 20 (80%) patients. CT and transcatheter angiography were significantly less common. None of the patients underwent conventional X-ray as a diagnostic tool. Several patients presented at our VAC with imaging studies that had not been performed in-house. These findings correlate with the existing recommendation for imaging of vascular anomalies which has been established and published previously [10, 21–23].

Treatments

Before admission to the VAC, 12 external treatments were found in the records of our patient population: 6 surgical interventions (3 VMs, 3 LMs), 1 sclerotherapy (VM), 3 transcatheter embolization procedures (AVMs) and 2 diagnostic biopsies (1 VM, 1 AVM). 14 (56%) patients had not received any treatment previously.

After consulting the VAC, 14 (56%) patients were conservatively managed or underwent minimally invasive therapy. 5 of these patients had been treated for their vascular malformation before at another institution, 4 with different therapeutic approaches. At the VAC, 10 (40%) patients underwent sclerotherapy



► **Fig. 6** Arteriovenous malformation of the left gluteal area in a male patient with subcutaneous and muscular involvement and mass aspect on an arterial phase CT scan after application of intra-venous contrast agent.

► **Abb. 6** Darstellung einer arteriovenösen Malformation der Glutealregion links mit subkutaner und intramuskulärer Ausdehnung bei einem männlichen Patienten in einer Computertomografie mit arterieller Kontrastmittelfase.

► **Table 1** Overview of cohort characteristics.

► **Tab. 1** Überblick der Kohorten-Charakteristika.

	Total	AVM (n = 10)	VM (n = 10)	LM (n = 5)
Sex	n = 25			
Male	15 (60 %)	6 (40 %)	5 (33 %)	4 (27 %)
Female	10 (40 %)	4 (40 %)	5 (50 %)	1 (10 %)
Imaging	n = 61			
MRI	24 (39 %)	10 (42 %)	9 (38 %)	5 (21 %)
Ultrasound	20 (33 %)	5 (25 %)	10 (50 %)	5 (25 %)
CT	12 (20 %)	7 (58 %)	5 (42 %)	0
Diagnostic Angiography	5 (8 %)	4 (80 %)	1 (20 %)	0
Location	n = 38			
Lesser pelvis	12 (32 %)	6 (50 %)	5 (42 %)	1 (8 %)
External genitalia	12 (32 %)	1 (8 %)	7 (58 %)	4 (33 %)
Perineal/ gluteal Area	13 (34 %)	5 (38 %)	4 (31 %)	4 (31 %)
Others	1 (3 %)	1 (100 %)	0	0

► **Table 2** Overview of clinical symptoms.

► **Tab. 2** Überblick klinischer Symptome.

Symptom	Total	AVM (n = 10)	VM (n = 10)	LM (n = 5)
Pain	24 (96%)	10 (100%)	10 (100%)	4 (80%)
Swelling	18 (72%)	5 (50%)	9 (90%)	4 (80%)
Bleeding	4 (16%)	1 (10%)	3 (30%)	0
Physical impairment	19 (76%)	8 (80%)	9 (90%)	2 (40%)
Sexual dysfunction	4 (16%)	1 (10%)	3 (30%)	0
Skin discoloration	10 (40%)	2 (20%)	6 (60%)	2 (40%)
Bruit/pulsation	4 (16%)	4 (40%)	0	0

(► **Fig. 7**), 3 (12%) received transcatheter embolization, and 1 (4%) patient was managed conservatively. Follow-up appointments were scheduled for 11 (44%) patients who did not require immediate treatment. Overall, there were 5 patients who had not undergone therapy for their vascular malformation prior to consultation at the VAC and did not have any indication for therapy, according to the VAC consultation.

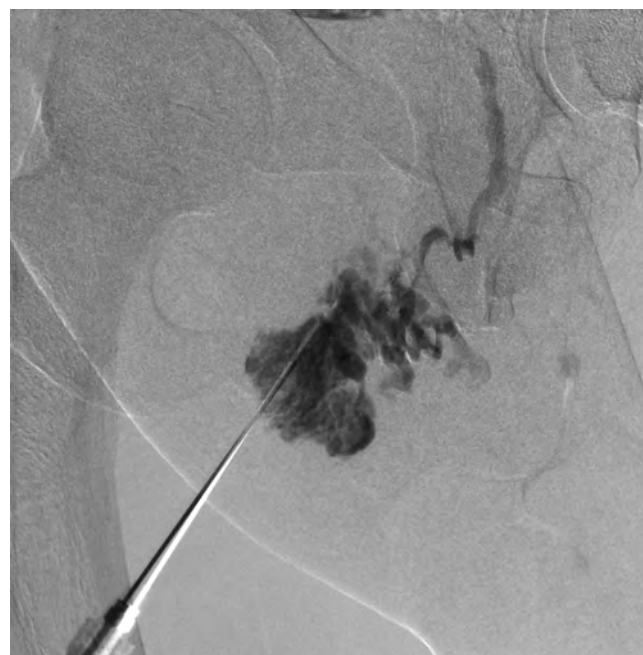Complete therapeutic response after minimally invasive therapy, transcatheter embolization for AVMs and sclerotherapy for VMs and LMs, was achieved in 9 (69%) patients. In 3 (23%) patients a partial response was documented. Only 1 patient with a VM reported no clinical response to sclerotherapy. Clinical outcome was evaluated according to patient findings and diagnostic findings during follow-up appointments, which had been documented in the patient records.

The overview of the patients' entire treatment history is provided in ► **Table 3**.

In the sub-analysis comparing AVMs to VMs, follow-up appointments instead of immediate minimally invasive therapy were significantly ($p = 0.0198$) more common in patients with AVMs compared to patients with VMs. Therapy of VMs compared to AVMs required frequent therapeutic sessions with a maximum of 4 sclerotherapy sessions compared to 1 embolization treatment session for AVMs ($p = 0.0055$).

Discussion

With an incidence of 1.5%, vascular malformations represent a rare disease [24], and the involvement of the urogenital tract and perineal region is even less common with an incidence of only 2–3% of vascular anomalies overall [15–17]. Over a period of 6 years, only 25 of 537 patients were diagnosed with a vascular malformation of the pelvis or urogenital tract at our institution. Yet, one has to assume that the number of undiagnosed urogenital vascular anomalies is much higher due to the number of pa-



► **Fig. 7** Periinterventional phlebography of a labial venous malformation of a female patient prior to sclerotherapy.

► **Abb. 7** periinterventionelle Phlebographie einer venösen Malformation der rechten Labie.

tients that remain undetected in the general clinical workflow, unless they present at a dedicated center. Comparable data from Vogel et al. [17] describe 60 vascular malformations of the female external genitalia among 3186 female patients with vascular anomalies, collected over 10 years via a database search. Kulungowski et al. [16] report 105 vascular malformations of the male genitalia among 3889 male patients over 15 years, also collected with a database search. In comparison to the literature, our data was not extracted by a database search but is based on clinically symptomatic patients that consulted our VAC.

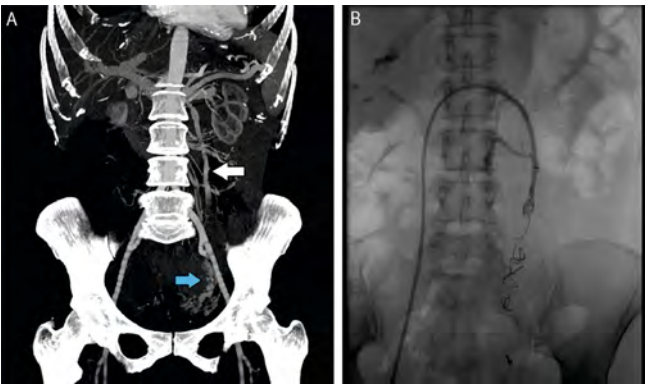
The reported symptoms of our patient cohort are similar to the cohort of Willihganz-Lawson et al. [15], who analyzed patients with genitourinary and perineal vascular malformations and also reported functional problems and pain as the most common and leading symptoms. Other than in our cohort, their mean age was 28 months with a predominance of the female gender. Their cohort included patients under the age of 18 from the multidisciplinary Vascular Anomalies Program at Seattle Children's Hospital.

Clinical symptoms of urogenital and perineal vascular malformations include those of other vascular anomalies but are often accompanied by increased physical and sexual impairment which may lead to deterioration of the patient's life quality. In female patients, menses and pregnancy can worsen clinical symptoms [13]. In fact, in females with uterine vascular malformations, not only abnormal bleeding but also pregnancy loss and fertility issues may be encountered [25, 26]. This requires dedicated interdisciplinary management of women with vascular malformations, especially during and after pregnancy. Unfortunately, there is hardly any literature to be found on multicenter analysis of this

► Table 3 Overview of treatment history.				
► Tab. 3 Überblick der therapeutischen Maßnahmen.				
	Total	AVM (n = 10)	VM (n = 10)	LM (n = 5)
Treatment before VAC n = 26				
None	14 (54 %)	6 (43 %)	6 (43 %)	2 (14 %)
Sclerotherapy	1 (4 %)	0	1 (100 %)	0
Embolization	3 (12 %)	3 (100 %)	0	0
Surgery	6 (23 %)	0	3 (50 %)	3 (50 %)
Diagnostic biopsy	2 (8 %)	1 (50 %)	1 (50 %)	0
Treatment in VAC n = 25				
Sclerotherapy	10 (40 %)	0	8 (80 %)	2 (20 %)
Embolization	3 (12 %)	3 (100 %)	0	0
Conservative	1 (4 %)	0	1 (100 %)	0
Follow-up	11 (44 %)	7 (64 %)	1 (9 %)	3 (27 %)
Results after therapy in VAC n = 25				
Complete regression	9 (36 %)	3 (33 %)	4 (44 %)	2 (22 %)
Partial regression	3 (12 %)	0	3 (100 %)	0
No response	1 (4 %)	0	1 (100 %)	0
Recurrence	0	0	0	0
No follow-up possible	1 (4 %)	0	1 (100 %)	0
No treatment in VAC	11 (44 %)	7 (64 %)	1 (9 %)	3 (27 %)

patient population. A case report by Serrano et al. indicates higher miscarriage rates in pregnant females with venous anomalies due to higher coagulation activity in the form of localized intravascular coagulopathy (LIC) which may progress to life-threatening disseminated intravascular coagulation (DIC) [27]. However, with dedicated multidisciplinary management and close monitoring, successful pregnancy outcomes can be achieved [28, 29].

An interesting observation in our patient cohort was the significant difference in the number of symptoms associated with the vascular malformations. Patients with VMs suffered from at least 3 various symptoms, unlike patients with AVMs (clinical symptoms overview in ► **Table 2**). A possible explanation could be the distribution of anatomic manifestation. Most likely, symptoms are more extensive when the vascular malformation is localized at the cutaneous or subcutaneous tissue level rather than intrapelvic. The external genitalia were more often involved in the case of VMs than AVMs. Also, localized thrombosis and thrombophlebitis, commonly observed by us in VMs, and infections in LMs, created recurrent painful episodes whereas in AVMs, due to the high-flow



► **Fig. 8** Example of a female patient with clinical pelvic congestion syndrome. **A** Coronal venous contrast phase CT scan showing a dilated left ovarian vein [white arrow] and dilated uterine venous plexus [blue arrow]. **B** Fluoroscopy after embolization of the left ovarian vein with coils.

► **Abb. 8** Beispiel einer Patientin mit einem Pelvic-Congestion-Syndrom. **A** Coronare Abbildung einer venösen Kontrastmitteldarstellung in der Computertomographie mit Darstellung der dilatierten linken Ovarialvene [weißer Pfeil] und einem dilatierten parauterinen Venenplexus links [blauer Pfeil]. **B** Fluoroskopie nach Embolisierung der linken Ovarialvene mit Coils.

characteristics, clinical symptoms were hardly found in these patients.

A similar clinical symptom complex can be observed in patients with chronic pelvic pain (CPP). There are several underlying causes of CPP. The spectrum of clinical findings based on the underlying etiology has been published extensively [30, 31]. One example of a vascular disorder not associated with vascular malformations leading to CPP is the pelvic congestion syndrome (► **Fig. 8**) in female patients. Although similar in clinical presentation, VMs and pelvic congestion syndrome represent two fundamentally different entities. The underlying causes of CPP must be differentiated from congenital vascular malformations because of the different clinical management and therapeutic approach.

The clinical assessment of pelvic vascular anomalies can be hampered by the fact that urogenital symptoms are not immediately evident compared to vascular anomalies in other regions of the body. Regarding the therapeutic spectrum, compression garments, as a mainstay for the treatment of peripheral VMs, can be difficult. Indication for minimally invasive treatment with sclerotherapy for VMs and LMs as well as transcatheter embolization for AVMs also depends on the extent of clinical symptoms and the experience of the treating interventional radiologist. The primary indication for treatment in our study group was pain and physical impairment. Bleeding complications were hardly encountered in our cohort. Overall, only 4 of 25 patients had a history of bleeding complication related to the vascular malformation. Therefore, minimally invasive therapies are usually performed in an elective setting. Vital indication for intervention is very rare.

To ensure the right management of urogenital and perineal vascular malformations, it is essential to detect the underlying vascular anomaly early and provide adequate therapy. Management should be performed in a dedicated center. According to the extent and location of the vascular malformation and the patient's age and condition, the integral therapy should include interdisciplinary teamwork with gynecologists, urologists, hematologists, and interventional radiologists [32].

Despite the rarity of these vascular anomalies, underassessment should be avoided and focused diagnosis and treatment should be initiated in a combined clinical effort.

Conclusion

In conclusion, our study gives an overview of a rare condition and the clinical presentation of patients with vascular malformation of the pelvis and urogenital tract in order to improve knowledge and patient management. Despite the fact that vascular malformations of the perineal area and urogenital tract are a rare disease, especially urologists and gynecologists might be confronted with VA patients in their daily clinical work. Delayed diagnosis often leads to deterioration of clinical symptoms as well as inadequate treatment resulting in progression of the vascular malformation. Nonetheless, it is important to rule out inflammatory and tumorous causes. Subsequently, VA patients should be referred to a VAC for management and adequate treatment.

Conflict of Interest

The authors declare that they have no conflict of interest.

References

- [1] Mulliken JB, Glowacki J. Hemangiomas and Vascular Malformations in Infants and Children. *Plast Reconstr Surg* 1982; 69: 412–420. doi:10.1097/00006534-198203000-00002
- [2] ISSVA Classification of Vascular Anomalies © 2018 International Society for the Study of Vascular Anomalies Available at "issva.org/classification". <https://www.issva.org/classification>
- [3] Mulliken JB, Fishman SJ, Burrows PE. Vascular anomalies. *Curr Probl Surg* 2000; 37: 517–584. doi:10.1016/S0011-3840(00)80013-1
- [4] Jackson IT, Carreño R, Potparic Z et al. Hemangiomas, Vascular Malformations, and Lymphovenous Malformations. *Plast Reconstr Surg* 1993; 91: 1216–1230. doi:10.1097/00006534-199306000-00006
- [5] Wassef M, Blei F, Adams D et al. Vascular Anomalies Classification: Recommendations From the International Society for the Study of Vascular Anomalies. *Pediatrics* 2015; 136: e203–e214. doi:10.1542/peds.2014-3673
- [6] Sadick M, Müller-Wille R, Wildgruber M et al. Vascular Anomalies (Part I): Classification and Diagnostics of Vascular Anomalies. *Fortschr Röntgenstr* 2018; 190: 825–835. doi:10.1055/a-0620-8925
- [7] Mazoyer E, Enjolras O, Bisdorff A et al. Coagulation disorders in patients with venous malformation of the limbs and trunk: A case series of 118 patients. *Arch Dermatol* 2008; 144: 861–867. doi:10.1001/archderm.144.7.861
- [8] Puig S, Casati B, Staudenherz A et al. Vascular low-flow malformations in children: Current concepts for classification, diagnosis and therapy. *Eur J Radiol* 2005; 53: 35–45. doi:10.1016/j.ejrad.2004.07.023
- [9] Fishman SJ, Mulliken JB. Vascular anomalies: A primer for pediatricians. *Pediatr Clin North Am* 1998; 45: 1455–1477. doi:10.1016/S0031-3955(05)70099-7
- [10] McCafferty IJ, Jones RG. Imaging and management of vascular malformations. *Clin Radiol* 2011; 66: 1208–1218. doi:10.1016/j.crad.2011.06.014
- [11] Cooke-Barber J, Kreimer S, Patel M et al. Venous malformations. *Semin Pediatr Surg* 2020; 29: 150976. doi:10.1016/j.semped-surg.2020.150976
- [12] Annam A. Female Pelvic Vascular Malformations. *Semin Intervent Radiol* 2018; 35: 062–068. doi:10.1055/s-0038-1636524
- [13] Burrows P. Vascular Malformations Involving the Female Pelvis. *Semin Intervent Radiol* 2008; 25: 347–360. doi:10.1055/s-0028-1102993
- [14] Wang S, Lang JH, Zhou HM. Venous malformations of the female lower genital tract. *Eur J Obstet Gynecol Reprod Biol* 2009; 145: 205–208. doi:10.1016/j.ejogrb.2009.05.017
- [15] Willihnganz-Lawson K, Gordon J, Perkins J et al. Genitourinary and perineal vascular anomalies in children: A Seattle children's experience. *J Pediatr Urol* 2015; 11: 227.e1–227.e6. doi:10.1016/j.jpuirol.2015.03.019
- [16] Kulungowski AM, Schook CC, Alomari AI et al. Vascular anomalies of the male genitalia. *J Pediatr Surg* 2011; 46: 1214–1221. doi:10.1016/j.jpedsurg.2011.03.056
- [17] Vogel AM, Alesbury JM, Burrows PE et al. Vascular anomalies of the female external genitalia. *J Pediatr Surg* 2006; 41: 993–999. doi:10.1016/j.jpedsurg.2005.12.069
- [18] Greene AK, Liu AS, Mulliken JB et al. Vascular anomalies in 5621 patients: Guidelines for referral. *J Pediatr Surg* 2011; 46: 1784–1789. doi:10.1016/j.jpedsurg.2011.05.006
- [19] Puig S, Aref H, Chigot V et al. Classification of venous malformations in children and implications for sclerotherapy. *Pediatr Radiol* 2003; 33: 99–103. doi:10.1007/s00247-002-0838-9
- [20] Kohout MP, Hansen M, Pribaz JJ et al. Arteriovenous Malformations of the Head and Neck: Natural History and Management. *Plast Reconstr Surg* 1998; 102: 643–654. doi:10.1097/00006534-199809030-00006
- [21] Sadick M, Overhoff D, Baessler B et al. Peripheral Vascular Anomalies – Essentials in Perinterventional Imaging. *Fortschr Röntgenstr* 2020; 192: 150–162. doi:10.1055/a-0998-4300
- [22] Grill N, Struebing F, Krebs L et al. Diagnostic radiology findings and spectrum of therapeutic interventions in gynaecological and urogenital vascular anomalies. *Br J Radiol* 2021; 94: 20210246. doi:10.1259/bjr.20210246
- [23] Schmidt VF, Masthoff M, Czihal M et al. Imaging of peripheral vascular malformations – current concepts and future perspectives. *Mol Cell Pediatr* 2021; 8: 19. doi:10.1186/s40348-021-00132-w
- [24] Eifert S, Villavicencio JL, Kao T-C et al. Prevalence of deep venous anomalies in congenital vascular malformations of venous predominance. *J Vasc Surg* 2000; 31: 462–471. doi:10.1016/S0741-5214(00)90306-9
- [25] Grivell RM, Reid KM, Mellor A. Uterine arteriovenous malformations: A review of the current literature. *Obstet Gynecol Surv* 2005; 60: 761–767. doi:10.1097/01.ogx.0000183684.67656.ba
- [26] Poncelet C, Aissaoui F. Malformations utérines et reproduction. *Gynecol Obstet Fertil* 2007; 35: 821–825. doi:10.1016/j.gyobfe.2007.08.001
- [27] Serrano F, Bisdorff-Bresson A, Sroussi J et al. Giant intrahepatic venous malformation with localized intravascular coagulopathy. Follow-up and treatment during pregnancy. *JMV-Journal Med Vasc* 2020; 45: 309–315. doi:10.1016/j.jdmv.2020.10.121
- [28] Rebarber A, Roman AS, Roshan D et al. Obstetric Management of Klippel-Trenaunay Syndrome. *Obstet Gynecol* 2004; 104: 1205–1208. doi:10.1097/01.AOG.0000141649.11305.4b

- [29] Yara N, Masamoto H, Iraha Y et al. Diffuse Venous Malformation of the Uterus in a Pregnant Woman with Klippel-Trénaunay Syndrome Diagnosed by DCE-MRI. *Case Rep Obstet Gynecol* 2016; 2016: 1–5. doi:10.1155/2016/4328450
- [30] Engeler D, Baranowski AP, Berghmans B et al. EAU Guidelines on Chronic Pelvic Pain. Arnhem, The Netherlands: EAU Guidelines Office; 2022. ISBN: 978-94-92671-16-5
- [31] Phillips D, Deipolyi AR, Hesketh RL et al. Pelvic Congestion Syndrome: Etiology of Pain, Diagnosis, and Clinical Management. *J Vasc Interv Radiol* 2014; 25: 725–733. doi:10.1016/j.jvir.2014.01.030
- [32] Wassef M, Vanwijck R, Clapuyt P et al. Tumeurs et malformations vasculaires, classification anatomopathologique et imagerie. *Ann Chir Plast Esthétique* 2006; 51: 263–281. doi:10.1016/j.anplas.2006.07.017