

# Initial experience of transpapillary gallbladder biopsy using newly designed device delivery system

**OPEN  
ACCESS**

## Authors

Kei Yane<sup>1</sup> , Yusuke Tomita<sup>1</sup>, Masahiro Yoshida<sup>1</sup>, Kou Sasaki<sup>1</sup>, Takayuki Imagawa<sup>1</sup>, Kotaro Morita<sup>1</sup>, Hideyuki Ihara<sup>1</sup>, Takeyoshi Minagawa<sup>1</sup>, Yutaka Okagawa<sup>1</sup>, Michiaki Hirayama<sup>1</sup>, Tetsuya Sumiyoshi<sup>1</sup>, Hitoshi Kondo<sup>1</sup>

## Institutions

1 Department of Gastroenterology, Tonan Hospital, Sapporo, Japan

submitted 23.12.2022

accepted after revision 8.5.2023

accepted manuscript online 16.5.2023

## Bibliography

Endosc Int Open 2023; 11: E613–E617

DOI 10.1055/a-2095-0098

ISSN 2364-3722

© 2023. The Author(s).

This is an open access article published by Thieme under the terms of the Creative Commons Attribution-NonDerivative-NonCommercial License, permitting copying and reproduction so long as the original work is given appropriate credit. Contents may not be used for commercial purposes, or adapted, remixed, transformed or built upon. (<https://creativecommons.org/licenses/by-nc-nd/4.0/>)

Georg Thieme Verlag KG, Rüdigerstraße 14, 70469 Stuttgart, Germany

## Corresponding author

Dr. Kei Yane, Tonan Hospital, Department of Gastroenterology, Sapporo, Japan  
k.yane3@gmail.com  
yanekei@vesta.dti.ne.jp

## ABSTRACT

Transpapillary gallbladder biopsy has been reported for the diagnosis of gallbladder disease, and this procedure requires special biopsy forceps or a large-diameter pusher catheter. We retrospectively examined consecutive patients who underwent transpapillary gallbladder biopsy using a newly designed device delivery system (Endosheather; Piolax Medical Device, Kanagawa, Japan). We evaluated 11 patients (median age, 71 years [28]–[85]) who underwent transpapillary gallbladder biopsy from June 2021 to July 2022. The selective gallbladder cannulation and delivery system insertion success rate was 90.9% (10/11). The target lesion biopsy success rate was 63.6% (7/11). The biopsy time (i. e., time to completion of biopsy after successful guidewire placement) was 8.7 (5.4–32.7) min. In 1 patient in whom all 6 gallbladder bile juice cytology results were benign, the biopsy result was suspicious of adenocarcinoma. The final diagnosis for this patient was gallbladder cancer. Adverse events occurred in 2 patients. In 1 patient, acute cholecystitis occurred and required emergency surgery. Transpapillary gallbladder biopsy using the Endosheather is a potential option for the diagnosis of gallbladder disease. A good indication for this technique is considered to be wall thickening at the gallbladder fundus, where it is difficult to differentiate between benign and malignant lesions by imaging modalities such as ultrasonography or endoscopic ultrasound. The addition of transpapillary gallbladder biopsy may be advantageous when performing bile juice cytology using a nasogallbladder drainage tube for the diagnosis of gallbladder disease.

## Introduction

Differentiating benign from malignant gallbladder disease is difficult by imaging diagnosis alone. Pathological evaluation is ideal for treatment decision making, but it is not easy for anatomical reasons. As a potential pathologic diagnostic method, the usefulness of gallbladder bile cytology using a drainage tube placed transpapillary into the gallbladder has been reported [1,2]. In addition, transpapillary gallbladder biopsy has also been described. However, this procedure requires specially de-

signed biopsy forceps, a large-diameter pusher catheter, or a cholangioscope [3,4,5,6,7]. Recently, a novel device delivery system has been developed and reported to be useful for bile duct biopsy during endoscopic retrograde cholangiopancreatography (ERCP) [8]. Gallbladder biopsies applying this method have also been reported [9,10]. The aim of the present study was to evaluate the feasibility of transpapillary gallbladder biopsy using this novel device delivery system in consecutive patients for the diagnosis of gallbladder disease.



► **Fig. 1** Device delivery system and biopsy forceps. **a** Novel device delivery system (Endosheather; Piolax Medical Device, Kanagawa, Japan) composed of an inner catheter and an outer sheath. **b** Outer sheath. **c** Biopsy forceps inserted into the outer sheath of the device delivery system.

## Patients and methods

### Study design

This retrospective observational study was conducted at Tonan Hospital, Sapporo, Hokkaido, Japan. The study protocol was approved by the ethics committee of our hospital (institutional ID: 2022-1-2-1). All participants provided written informed consent before undergoing the procedure.

### Patients

Eleven consecutive patients who underwent transpapillary gallbladder biopsy using a newly designed device delivery system at our institution from June 2021 to July 2022 were evaluated.

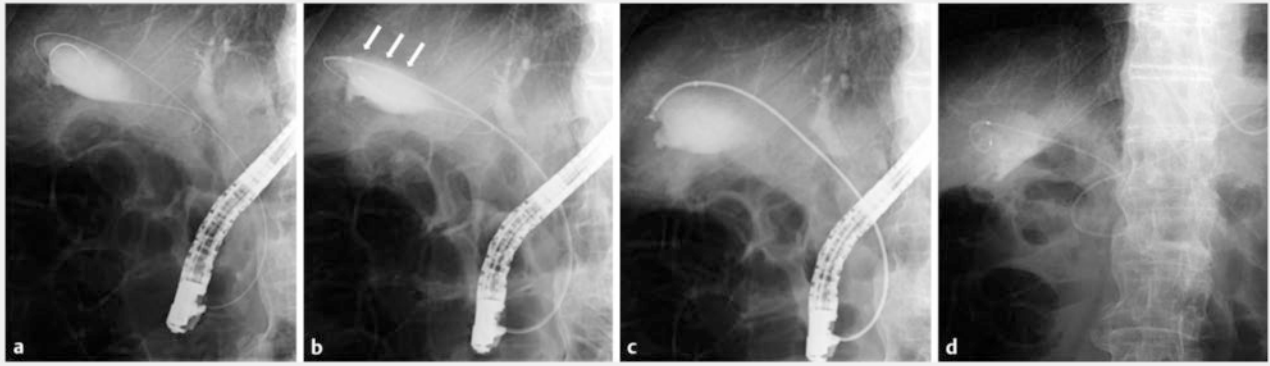
Age, sex, indications of gallbladder biopsy, presence of pancreaticobiliary maljunction, main target sites (gallbladder neck/body/fundus), presence of sphincterotomy, gallbladder cannulation success rate, device delivery system insertion success rate, target lesion biopsy success rate, adequate specimen collection rate, gallbladder bile juice cytology results, biopsy procedure time, total procedure time, and adverse event (AE) rates were analyzed. Data associated with the endoscopic procedure were evaluated using ERCP database, endoscopy reports, and video records.

### Definitions

Gallbladder cannulation success was defined as successful insertion of a guidewire and an ERCP catheter into the gallbladder. System insertion success was defined as successful insertion of a device delivery system into the gallbladder. Target biopsy success was defined as successful biopsy of a targeted gallbladder lesion (e. g., lesion in the gallbladder fundus, body, or neck). Biopsy procedure time was defined as the time to completion of biopsy after successful guidewire placement in the gallbladder. Total procedure time was defined as the time from scope insertion to removal.

### Equipment and endoscopic procedures

Endoscopic procedures were performed or supervised by physicians with extensive experience in ERCP using a side-viewing duodenoscope (TJF-260V or TJF-290V; Olympus Medical Systems, Tokyo, Japan) and a catheter (ERCP-Katheter; MTW Endoskopie, Wesel, Germany). Biliary sphincterotomy was performed in necessary cases. Following cholangiography, a 0.032-inch hydrophilic guidewire (Radifocus; Terumo, Tokyo, Japan) was advanced into the gallbladder via the cystic duct. Subsequently, the catheter was advanced to the cystic duct following the guidewire. Following successful gallbladder cannulation, the hydrophilic guidewire was replaced with a stiff type guidewire (EndoSelector, Boston Scientific, Natick, Massachusetts, United States; or VisiGlide2, Olympus Medical Systems). After withdrawing the catheter, a device delivery system (Endosheather; Piolax Medical Device, Kanagawa, Japan) was inserted into the gallbladder. This delivery system has a 2.44-mm (7.2F) diameter outer sheath and allows the insertion of devices up to 1.9 mm (5.7F) in diameter (► **Fig. 1**). After the delivery system was inserted into the target site, multiple biopsies were performed using 1.8-mm-diameter pediatric biopsy forceps (Radial Jaw 4P; Boston Scientific). Combinations of pushing and pulling of the biopsy forceps, and opening and closing of the tip were performed to guide the forceps to the target site (► **Video. 1**). In principle, the number of biopsies was at least five. Additional biopsies were performed if the specimen was deemed grossly inadequate. Finally, a pigtail-shaped nasogallbladder drainage tube was placed in the gallbladder for bile juice cytology (► **Fig. 2**). Clinical symptoms and physical findings were recorded after the procedure. Laboratory data were also assessed the following day. After the planned number of cytology specimens was collected (6 times in principle), the drainage tube was removed. After the endoscopic procedures, surgery was performed in all 11 cases, and the biopsy results and final pathological diagnosis were compared.



► **Fig. 2** Fluoroscopic images of the gallbladder biopsy procedure. **a** After bile duct cannulation, the guidewire was coiled in the gallbladder. **b** The device delivery system was then inserted into the gallbladder (arrows). **c** Thereafter, biopsy forceps was inserted into the delivery system and biopsy was performed. The procedure was repeated until grossly sufficient specimens have been obtained. **d** Finally, a nasobiliary drainage tube was placed into the gallbladder.

## Results

The clinical characteristics of the assessed 11 patients are summarized in ► **Table 1**. The indications for gallbladder biopsy were gallbladder wall thickness (10/11, 90.9%) and a gallbladder protruding lesion (1/11, 9.1%). The main target sites were the gallbladder fundus (9/11, 81.8%), body (1/11, 9.1%), and neck (1/11, 9.1%). Gallbladder cannulation success and system insertion success were achieved in 10 patients (90.9%). In one patient with a protruding lesion in the gallbladder body, guidewire insertion into the gallbladder was unsuccessful, owing to cystic duct deformation. In one patient, the delivery system did not follow the 0.025-inch guidewire initially used and had to be replaced with a 0.035-inch hard-type guidewire. Target biopsy success was achieved in seven patients (63.6%). In two patients, insertion of the system into the target site (i.e., gallbladder fundus) was difficult and the biopsy was performed in the gallbladder body. In one patient with gallbladder neck wall thickness, the gallbladder anatomy made it difficult to accurately assess whether a biopsy could be performed from the target site. The median number of biopsies was 5.5 (range, 3–8). Appropriate evaluable specimens were obtained in all 10 patients in which biopsies were taken from the gallbladder. Gallbladder bile juice cytology was performed in nine patients (81.8%). The biopsy procedure time was 8.7 minutes (range, 5.4–32.7). The total procedure time was 47 minutes (range, 28–89). Details of the endoscopic procedures are summarized in ► **Table 2**. Biopsy results, cytology results, and final diagnosis are shown in ► **Table 3**. In one patient in whom all six gallbladder bile juice cytology results were benign, the biopsy result was suspicious of adenocarcinoma (► **Fig. 3**). The patient's final diagnosis was gallbladder cancer.

AEs occurred in two patients (i.e., cholecystitis 1, self-limiting hematoma 1). In the patient with cholecystitis, there was stenosis in the cystic duct that appeared to be due to inflammation; after balloon dilation, a delivery system was inserted and a gallbladder biopsy was performed. The patient was fine the day

► **Table 1** Clinical characteristics of the 11 assessed patients.

Age, median (range), years	71 (28–85)
Sex (male/female)	3/8
Indications of gallbladder biopsy, n (%)	
▪ Gallbladder wall thickness	10 (90.9)
▪ Protruding lesion	1 (9.1)
▪ Pancreaticobiliary maljunction, n (%)	2 (18.2)
Main target sites, n (%)	
▪ Fundus	9 (81.8)
▪ Body	1 (9.1)
▪ Neck	1 (9.1)

after the procedure, but developed acute cholecystitis after removal of the drainage tube placed for bile cytology. An emergency cholecystectomy was performed in this patient.

## Discussion

Of the 11 patients in whom transpapillary gallbladder biopsy was attempted during the study period using a newly designed device delivery system, 10 patients in whom guidewire placement into the gallbladder was possible had successful device insertion. When delivery system insertion into the gallbladder is difficult, replacement with a 0.035-inch hard-type guidewire or the use of a double guidewire technique may be effective. In one patient, the delivery system could be introduced by changing the 0.025-inch guidewire to a 0.035-inch hard-type guidewire. However, two of these 10 patients had unsuccessful advancement of the device delivery system to the target site (i.e., gallbladder fundus). In one patient with gallbladder neck wall thickness, it was difficult to rigorously assess whether a

► **Table 2** Details of the endoscopic procedures.

Sphincterotomy, n (%)	8 (1 prior) (72.7)
Gallbladder cannulation success, n (%)	10 (90.9)
Device insertion success, n (%)	10 (90.9)
Adequate specimen collection, n (%)	10 (90.9)
Target lesion biopsy success, n (%)	7 (63.6)
Number of biopsies, median, n (range)	5.5 (3–8)
Performing gallbladder bile cytology, n (%)	9 (81.8)
Cytology results	
▪ Malignant	1
▪ Suspicious	1
▪ Benign or indeterminate	7
Biopsy time, min (range)	8.7 (5.4–32.7)
Total procedure time, min (range)	47 (28–89)

biopsy could be taken from this site. Therefore, seven cases (63.6%) had successful targeted biopsies from the main target site.

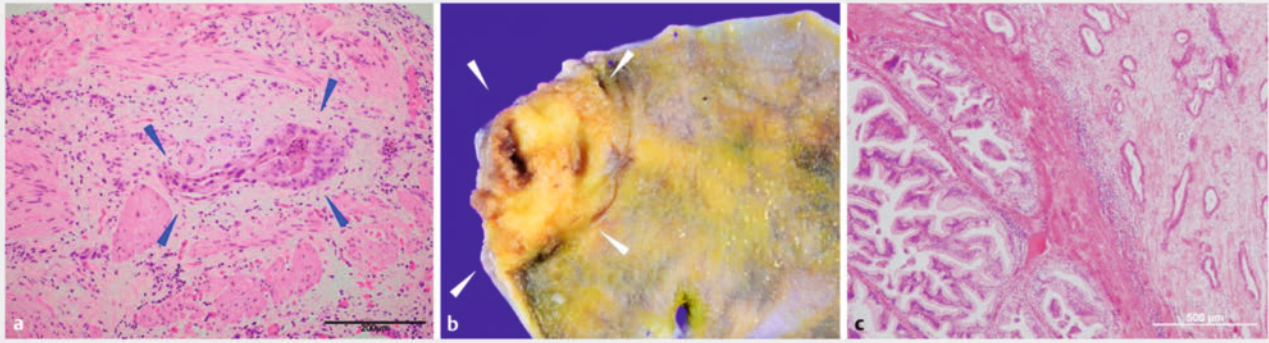
In terms of advantages, transpapillary gallbladder biopsy using a newly designed device delivery system can be performed using commercially available devices, and multiple specimens can be easily collected once the delivery system is inserted. In addition, device insertion and biopsy could be performed in all cases in which guidewire insertion into the gallbladder was possible. Transpapillary gallbladder biopsy is simpler than previously reported gallbladder biopsy methods that require specially developed devices and complex procedures [4, 5, 6, 7]. The usefulness of gallbladder bile cytology using a nasogallbladder drainage tube has already been reported [1, 2]. Because transpapillary gallbladder biopsy can be performed in addition to gallbladder bile cytology, its use in close exami-

nation of gallbladder lesions is worth considering. In cases of a tortuous, thin cystic duct and failed cases of gallbladder cannulation, this method is either not possible or very difficult. For anatomical reasons, it was difficult to rigorously assess whether a biopsy from the target site could be obtained from lesions in the neck or body of the gallbladder, or in elevated lesions of the gallbladder. For this reason, a good indication for this technique is considered to be wall thickening at the fundus of the gallbladder, where it is difficult to differentiate between benign and malignant lesions by imaging diagnosis such as ultrasonography or endoscopic ultrasonography. Furthermore, a problem we encountered was that in some patients, the delivery system could not be inserted into the gallbladder fundus. If a more flexible and smaller outer diameter delivery system with the same inner diameter and controllable biopsy forceps with the same specimen collection performance are developed, transpapillary gallbladder biopsy could become even more useful. In terms of risks, AEs such as perforation of the cystic duct or gallbladder, and bleeding and infection may occur during the procedure, which requires careful attention and delicate manipulation. When we performed transpapillary gallbladder biopsy after balloon dilation in a patient with a stenosed cystic duct, we experienced acute cholecystitis possibly caused by cystic duct edema after removal of the gallbladder drainage tube. In such a situation, we should have considered not inserting the delivery system or leaving a stent in place for gallbladder drainage.

For study limitations, this was a single-center retrospective study with a small number of cases. At this stage, the small number of patients with gallbladder cancer included in this cohort limits any definitive statements regarding the diagnostic accuracy of transpapillary gallbladder biopsy. Larger studies should allow the selection of patients who would benefit from this procedure.

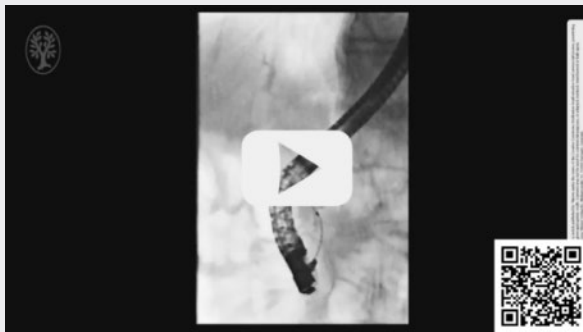
► **Table 3** Biopsy results and surgical outcomes.

No.	Biopsy result	Cytology result	Final diagnosis
1	No neoplastic lesion	Benign (6/6)	No neoplastic lesion
2	No neoplastic lesion	Benign (6/6)	Chronic cholecystitis
3	No neoplastic lesion	Benign (6/6)	Adenomyomatosis
4	No neoplastic lesion	Benign (6/6)	Adenomyomatosis
5	No neoplastic lesion	Cytology not performed	Atypical epithelium (BillIN2)
6	Granuloma	Benign (7/7)	Chronic cholecystitis
7	Xanthogranulomatous reaction	Suspicious (1/6), Indeterminate (5/6)	Xanthogranulomatous cholecystitis
8	Atypical glands	Indeterminate (6/6)	Gallbladder cancer (Tis, Stage 0)
9	Atypical glands	Malignant (6/6)	Gallbladder cancer (T2bN2M0, Stage IVb)
10	Suspicious of adenocarcinoma	Benign (6/6)	Gallbladder cancer (T3aN0M0, Stage IIIa)



► **Fig. 3** Biopsy and excised specimens. **a** An atypical epithelium is confirmed suggestive of adenocarcinoma (arrowheads). **b** The excised specimen showed SS depth, Stage IIIa (UICC 7th) gallbladder cancer (arrowheads). **c** Adenocarcinoma was histopathologically confirmed from the microscopic image.

#### VIDEO



► **Video 1** A guidewire was initially placed in the gallbladder, then the device delivery system was inserted into the gallbladder using an over the wire method, and finally biopsy was performed. To perform adequate biopsy of the target site, the forceps tip position was changed by pushing and pulling the delivery system and opening and closing the forceps tip as necessary.

## Conclusions

Transpapillary gallbladder biopsy using a newly designed device delivery system is a potential option for the diagnosis of gallbladder disease. The addition of transpapillary gallbladder biopsy may be advantageous when performing bile juice cytology using a nasogallbladder drainage tube for the diagnosis of gallbladder disease.

## Acknowledgement

Acknowledgements We thank Dr. Edward Barroga (<https://orcid.org/0000-0002-8920-2607>), Medical Editor, Professor of Medical Education at Showa University School of Medicine, Japan, and Adjunct Faculty of Academic Writing at St. Luke's International University, Japan, for editing the manuscript.

## Conflict of Interest

The authors declare that they have no conflict of interest.

## References

- [1] Itoi T, Sofuni A, Itokawa F et al. Preoperative diagnosis and management of thick-walled gallbladder based on bile cytology obtained by endoscopic transpapillary gallbladder drainage tube. *Gastrointest Endosc* 2006; 64: 512–519
- [2] Kawahara S, Tomoda T, Kato H et al. Accuracy of endoscopic transpapillary gallbladder drainage with liquid-based cytology for gallbladder disease. *Digestion* 2022; 103: 116–125
- [3] Inui K, Yoshino J, Miyoshi H. Diagnosis of gallbladder tumors. *Internal Med* 2011; 50: 1133–1136 doi:10.2169/internalmedicine.50.5255
- [4] Kuriyama S, Uchida N, Tsutsui K et al. Endoscopic transpapillary catheterization into the gallbladder for diagnosis of gallbladder carcinoma. *Dig Endosc* 2006; 18: 84–87
- [5] Watanabe Y, Goto H, Hirooka Y et al. Transpapillary biopsy in gallbladder disease. *Gastrointest Endosc* 2000; 51: 76–79 doi:10.1016/s0016-5107(00)70392-0
- [6] Matsumori T, Uza N, Okada H et al. A novel technique for performing gallbladder tumor biopsy using a stent delivery system and biopsy forceps. *Endoscopy* 2020; 52: E415–E417 doi:10.1055/a-1149-8625
- [7] Kobayashi K, Kobara H, Masaki T. Novel cholangioscopy-guided targeted biopsy for diagnosing gallbladder carcinoma. *Dig Endosc* 2021; 33: e51–e53 doi:10.1111/den.13925
- [8] Matsumori T, Uza N, Shiokawa M et al. Clinical impact of a novel device delivery system in the diagnosis of bile duct lesions: A single-center experience. *J Gastroenterol Hepatol* 2022; 37: 1360–1366 doi:10.1111/jgh.15866
- [9] Mandai K, Inoue T, Uno K et al. Transferring a naso-gallbladder drainage tube to the mouth for re-examination of a gallbladder lesion. *J Hepatobiliary Pancreat Sci* 2022; 29: e77–e78 doi:10.1002/jhbp.1147
- [10] Yane K, Sumiyoshi T, Kondo H. Transpapillary gallbladder biopsy using newly designed endoscopic sheath. *Dig Endosc* 2021; 33: e146–e147 doi:10.1111/den.14095