








Curriculum for training in endoscopic mucosal resection in the colon: European Society of Gastrointestinal Endoscopy (ESGE) Position Statement



Authors

David J. Tate^{1,2}, Maria Eva Argenziano³, John Anderson⁴ , Pradeep Bhandari⁵, Ivo Boškoski⁶, Marek Bugajski⁷, Lobke Desomer⁸, Steven J. Heitman⁹, Hiroshi Kashida¹⁰, Vladimir Kriazhov^{11, *}, Ralph R. T. Lee¹², Ivan Lyutakov¹³ , Pedro Pimentel-Nunes^{14, 15, 16} , Liseth Rivero-Sánchez^{17, 18} , Siwan Thomas-Gibson¹⁹ , Henrik Thorlacius²⁰, Michael J. Bourke^{21, 22}, Tony C. Tham²³ , Raf Bisschops²⁴ 

Institutions

- 1 Department of Gastroenterology and Hepatology, University Hospital of Ghent, Ghent, Belgium
- 2 Faculty of Medicine, University of Ghent, Ghent, Belgium
- 3 Clinic of Gastroenterology, Hepatology and Emergency Digestive Endoscopy, Università Politecnica delle Marche, Ancona, Italy
- 4 Cheltenham General Hospital, Gloucestershire Hospitals Foundation Trust, Cheltenham, UK
- 5 Endoscopy Department, Portsmouth Hospitals University NHS Trust, Portsmouth, UK
- 6 Digestive Endoscopy Unit, Fondazione Policlinico Universitario Agostino Gemelli IRCCS, Rome, Italy
- 7 Department of Gastroenterology, Luxmed Oncology, Warsaw, Poland
- 8 AZ Delta Roeselare, University Hospital Ghent, Ghent, Belgium
- 9 Division of Gastroenterology and Hepatology, Departments of Medicine and Community Health Sciences, Cumming School of Medicine, University of Calgary, Calgary, Canada
- 10 Department of Gastroenterology and Hepatology, Kindai University, Faculty of Medicine, Osaka, Japan
- 11 Endoscopy Department, Nizhny Novgorod Regional Clinical Oncology Center, Nizhny Novgorod, Russia Federation
- 12 The Ottawa Hospital - Civic Campus, University of Ottawa, Ottawa, Canada
- 13 University Hospital Tsaritsa Yoanna-ISUL, Medical University Sofia, Sofia, Bulgaria
- 14 Gastroenterology Department, Portuguese Oncology Institute of Porto, Porto, Portugal
- 15 Center for Research in Health Technologies and Information Systems (CINTESIS), Faculty of Medicine, University of Porto, Porto, Portugal
- 16 Surgery and Physiology Department, Faculty of Medicine of the University of Porto, Porto, Portugal
- 17 Gastroenterology Department, Hospital Clínic de Barcelona, Barcelona, Spain
- 18 Centro de Investigacion Biomedica en Red de Enfermedades Hepaticas y Digestivas (CIBERehd), Institut d'Investigacions Biomediques August Pi i Sunyer (IDIBAPS), Universitat de Barcelona, Barcelona, Spain
- 19 St. Mark's Hospital, London and Imperial College London, London, UK
- 20 Department of Surgery, Lund University, Malmö, Sweden
- 21 Department of Gastroenterology, Westmead Hospital, Sydney, Australia
- 22 University of Sydney, Sydney, Australia
- 23 Division of Gastroenterology, Ulster Hospital, Dundonald, Belfast, Northern Ireland
- 24 Department of Gastroenterology and Hepatology, University Hospitals Leuven, TARGID, KU Leuven, Leuven, Belgium

published online 7.6.2023

Bibliography

Endoscopy 2023; 55: 645–679

DOI 10.1055/a-2077-0497

ISSN 0013-726X


© 2023. European Society of Gastrointestinal Endoscopy

All rights reserved.

This article is published by Thieme.

Georg Thieme Verlag KG, Rüdigerstraße 14,
70469 Stuttgart, Germany

* Although both ESGE and the Thieme Group adhere to a policy prohibiting publications by Russian authors in *Endoscopy* at this time, an exception has been made to include Dr. Kriazhov owing to the fact that his significant contribution to this Position Statement was made before Russia's invasion of Ukraine.

 **Supplementary material**
Supplementary material is available under
<https://doi.org/10.1055/a-2077-0497>

Corresponding author

David J. Tate, MBBS, PhD, University Hospital of Ghent,
C Heymanslaan 10, 9000 Ghent, Belgium
david.tate@uzgent.be

MAIN RECOMMENDATIONS

Endoscopic mucosal resection (EMR) is the standard of care for the complete removal of large (≥ 10 mm) nonpedunculated colorectal polyps (LNPCPs). Increased detection of LNCPs owing to screening colonoscopy, plus high observed rates of incomplete resection and need for surgery call for a standardized approach to training in EMR.

1 Trainees in EMR should have achieved basic competence in diagnostic colonoscopy, <10-mm polypectomy, pedunculated polypectomy, and common methods of gastrointestinal endoscopic hemostasis. The role of formal training courses is emphasized. Training may then commence in vivo under the direct supervision of a trainer.

2 Endoscopy units training endoscopists in EMR should have specific processes in place to support and facilitate training.

3 A trained EMR practitioner should have mastered theoretical knowledge including how to assess an LNCP for risk of submucosal invasion, how to interpret the potential difficulty of a particular EMR procedure, how to decide whether to remove a particular LNCP en bloc or piecemeal, whether the risks of electrocautery energy can be avoided for a particular LNCP, the different devices required for EMR, management of adverse events, and interpretation of reports provided by histopathologists.

4 Trained EMR practitioners should be familiar with the patient consent process for EMR.

5 The development of endoscopic non-technical skills (ENTS) and team interaction are important for trainees in EMR.

6 Differences in recommended technique exist between EMR performed with and without electrocautery energy. Common to both is a standardized technique based upon dynamic injection, controlled and precise snare placement, safety checks prior to the application of tissue transection (cold snare) or electrocautery energy (hot snare), and interpretation of the post-EMR resection defect.

7 A trained EMR practitioner must be able to manage adverse events associated with EMR including intraprocedural bleeding and perforation, and post-procedural bleeding. Delayed perforation should be avoided by correct interpretation of the post-EMR defect and treatment of deep mural injury.

8 A trained EMR practitioner must be able to communicate EMR procedural findings to patients and provide them with a plan in case of adverse events after discharge and a follow-up plan.

9 A trained EMR practitioner must be able to detect and interrogate a post-endoscopic resection scar for residual or recurrent adenoma and apply treatment if necessary.

10 Prior to independent practice, a minimum of 30 EMR procedures should be performed, culminating in a trainer-guided assessment of competency using a validated assessment tool, taking account of procedural difficulty (e.g. using the SMSA polyp score).

11 Trained practitioners should log their key performance indicators (KPIs) of polypectomy during independent practice. A guide for target KPIs is provided in this document.

SCOPE AND PURPOSE

This manuscript represents the outcome of a formal Delphi process resulting in an official Position Statement of the ESGE and provides a framework to develop and maintain skills in EMR. This curriculum is set out in terms of the prerequisites for training, the theoretical knowledge and practical skills required for completion of training, and how competence should be defined and evidenced prior to independent practice.

ABBREVIATIONS

CT	computed tomography	LNPCP	large (≥ 10 mm) nonpedunculated colorectal polyp
DMI	deep mural injury	MDT	multidisciplinary team
EMR	endoscopic mucosal resection	NICE	Narrow-band imaging International Colorectal Endoscopic classification
ENTS	endoscopic non-technical skills	SMI	submucosal invasion
ESGE	European Society of Gastrointestinal Endoscopy	SMIC	submucosal invasive cancer
GI	gastrointestinal	SMSA	size, morphology, site, and access
GPAT	Global Polypectomy Assessment Tool	SSL	sessile serrated lesion
GRADE	Grading of Recommendations Assessment, Development and Evaluation	STSC	snare-tip soft coagulation through the scope
JNET	Japan NBI (narrow-band imaging) Expert Team	TTS	
KPI	key performance indicator		

Definitions

Cold snare polypectomy	Colorectal polypectomy without the use of electrosurgical energy
Competency framework	A set of statements specifying the standards required of a practitioner deemed competent in the specified technique
Competent EMR practitioner	A fully trained practitioner of EMR as per the competencies defined in this curriculum
Practitioner credentialing	Process of defining that a particular endoscopic practitioner has the knowledge and technical expertise to perform (specific levels of) colorectal polypectomy
Delayed perforation	A clinical syndrome of pain and raised inflammatory markers after polypectomy suggesting perforation and confirmed by imaging
Demarcated area	An area within an LNPCP where a regular pit/vascular pattern becomes disordered
Electrosurgical unit	A generator capable of delivering electrosurgical energy
EMR	Colorectal polypectomy of an LNPCP using a submucosal injectate and a snare
Hot snare polypectomy	Colorectal polypectomy using electrosurgical energy
Intraprocedural bleeding	Bleeding during an EMR procedure which requires endoscopic control methods
Intraprocedural perforation	Target sign (Sydney DMI type III) or actual hole (Sydney DMI type IV/V) detected during a polypectomy procedure
Low risk submucosal invasive cancer (histologic diagnosis)	< 1000- μ m depth of invasion measured from the muscularis mucosae, well or moderately differentiated, no tumor budding, no lymphovascular invasion
Post-resection defect	The area of exposed submucosa remaining after EMR
Snare pivot technique	(Starting with an open snare) using the tip of the snare to push the mucosa away allowing the open snare to be directed over the polyp tissue even if not positioned at 6 o'clock

Introduction

Endoscopic mucosal resection (EMR) was first referred to by Dehyle in 1973 as a technique to remove rectal polyps transanally [1] and later, in Japan, as a method for removing early gastric cancer [2]. It describes any diathermic resection of a gastrointestinal (GI) lesion using a snare with prior submucosal injection [3, 4] (hot snare EMR). Over the years this definition was broadened to involve polyp resections that did not require electrosurgical energy (cold snare EMR) [5].

EMR is the preferred technique to remove flat and sessile ≥ 10 -mm polyps in the colon. It is safe and effective [4, 6], with significantly lower cost [7], morbidity, and mortality [8] compared with surgical resection. In expert hands, more than 98% of colorectal polyps can be removed completely using EMR [4, 6, 9, 10], without resorting to more resource-intensive endoscopic [11, 12] or surgical techniques.

Despite its widespread applicability, training in EMR is often experiential, unstructured, and dependent on trainers without conscious competence in the technique [13]. Compounding this, there is no curriculum for how to train in the procedure and differing published best practice advice on how to perform high quality procedures.

Aims

With this curriculum, the European Society of Gastrointestinal Endoscopy (ESGE) aims to promote a standardized evidence-based approach to the practice of EMR, including training. Of course, there are many ways to approach any clinical problem and neither curricula nor guidelines should ever be a substitute for clinical judgement.

The curriculum is split into pre-adoption and endoscopy unit requirements for the performance of EMR; minimum required theoretical knowledge; techniques and approach before, during, and after EMR; and potential key performance indicators (KPIs) for lifelong learning. A competency framework for training (the Global Polypectomy Assessment Tool [GPAT]) is proposed at the end of this document in an attempt to standardize both the language used in polypectomy training and the assessment of competency.

Methods

This curriculum was developed through a Delphi consensus process amongst international experts in EMR [14]. As chair of the ESGE curricula working group, R.B. invited D.J.T. to be the section chair for the EMR training curriculum. After a call for participants in January 2020, R.B. and D.J.T. selected the members, based on the planned curriculum, and their EMR experience and publications, in March 2020.

The term “endoscopic mucosal resection” in this curriculum relates exclusively to the endoscopic resection of large (≥ 10 mm) or laterally spreading nonpedunculated colorectal polyps (LNPCPs) using a snare with prior submucosal injection, with or without electrosurgical energy.

Because the topic of the curriculum pertains to an area with very little published evidence, an initial Delphi consensus was first undertaken to define a structure for the curriculum based on three questions [15].

A What are the pre-adoption requirements to start EMR training?

B What are the training/learning steps to achieve competence in EMR?

C What are the assessment criteria for EMR proficiency (being competent and maintaining competence)?

A total of 11 international expert practitioners of EMR were invited to participate, based upon their international reputation (for training in EMR and hosting internationally recognized training courses in EMR), publications, and personal motivation (see Acknowledgments). The experts were asked to provide open-ended responses to 35 questions covering the following domains regarding training in EMR (pre-adoption requirements, endoscopy unit requirements, theoretical knowledge, pre-procedure requirements, competencies during EMR, post-EMR requirements, requirements for completion of training, and lifelong KPIs) (the original questions are detailed in **Appendix 1s**, see online-only Supplementary material). Experts formulated responses to these initial questions using the PICO approach (where P stands for population/patient/problem, I for intervention/indicator, C for comparator/control, and O for outcome).

A first round of anonymous online voting on the categorized statements was performed by the experts before the first meeting of the taskforce in May 2020. All rounds of voting were based on a 7-point Likert scale ranging from “Strongly disagree” (1) to “Strongly agree” (7). During the first taskforce meeting, all members were given the chance to discuss and adapt the responses. The group was split into four sub-taskforces each required to cover two of the above domains.

During the adaptation phase, taskforce members conducted systematic literature searches based on the PubMed database up until May 2020 using search terms derived from the statements. Where evidence was found, it was used to adapt the statements and the strength of evidence rated using the Grading of Recommendations Assessment, Development and Evaluation (GRADE) system for grading evidence levels and recommendation strengths [16]. Where no evidence was found, the statements were maintained in the form drafted by experts.

Written adaptations were made by the sub-taskforce leader after the first meeting and submitted to D.J.T., who collated them. The evolution and adaptation of the clinical statements during the Delphi process was documented.

The second round of voting followed the dissemination of adapted statements. Afterwards, at a second virtual meeting, statements that did not achieve 80% consensus were discarded and further modifications were made to those remaining. At this stage, the GPAT and the criteria for assessing proficiency at EMR were added and discussed. After the second meeting, formatting of the statements and further referencing was performed by the sub-taskforces. A third round of voting decided on those statements that remain in this final document (at least 80% agreement).

Important: All the statements in this guideline should be interpreted in the context of the expectations of a fully competent EMR practitioner after completion of a period of dedicated training.

1 Preadoption requirements

EMR of large nonpedunculated colorectal polyps (LNPCPs) is a complex skill and requires dedication, a significant time investment, and case experience to reach competency.

1 COMPETENCIES PRIOR TO EMR TRAINING

ESGE recommends that the competencies listed below are accomplished prior to in vivo EMR training under direct supervision.

Best practice recommendation, no evidence available.

(i) Competency in diagnostic colonoscopy (as defined by local protocols).

Level of agreement 97%.

(ii) Commencement of acquiring theoretical knowledge, such as lesion assessment and decision-making.

Level of agreement 96%.

(iii) Competency in <10-mm polypectomy (with and without electrosurgical energy), pedunculated polypectomy, and common methods of GI endoscopic hemostasis [17] (as defined by local protocols).

Level of agreement 97%.

2 STANDARDS FOR ENDOSCOPY UNITS OFFERING EMR TRAINING

ESGE recommends the minimum desirable standards detailed in the following list be met by endoscopy units offering training in EMR.

Best practice recommendation, no evidence available.

(i) Written and/or electronic pre-procedure pathways should exist to facilitate the assessment of patients with co-morbidity prior to EMR.

Level of agreement 90%.

(ii) Written local pre-procedure pathways should exist to direct the correct dosing of anticoagulants for patients prior to EMR based on international consensus guidelines.

Level of agreement 95%.

(iii) Formal procedures should exist, either via written information, remote consultation, or face-to-face discussion, to communicate specific information to the patient prior to the procedure, particularly to facilitate excellent bowel preparation.

Level of agreement 96%.

(iv) Administrative staff booking complex EMR procedures must have guidance to ensure adequate time and personnel are allocated for the scheduled procedure relative to its predicted complexity, perhaps using a validated score, such as the size, morphology, site, and access (SMSA) polyp score [18] for guidance. Extra time should be allocated if training is foreseen.

Level of agreement 96%.

(v) Units should have a mechanism in place for the training of nursing staff in the techniques and equipment required for EMR and in how to assist the proceduralist.

Level of agreement 96%.

(vi) There should be a dedicated anesthesia-supported list in the unit performing EMR for complex and/or predicted protracted EMR cases (e.g. very large resections, predicted difficult location etc.).

Level of agreement 90%.

(vii) All necessary equipment should be available prior to starting an EMR procedure. Equipment checklists should be available and used within the unit to ensure this is the case.

Level of agreement 96%.

(viii) Image and/or video capture equipment for EMR procedures and the ability to record these in electronic reporting systems should be available.

Level of agreement 95%.

(ix) There should be immediate on-site access to support services (including interventional radiology and surgery) in the event of a significant bleed or other complication (e.g. perforation), or a pathway should exist for rapid transfer to a specialist center.

Level of agreement 90%.

(x) There should be a dedicated recovery room in the unit able to monitor patients at a high level for an extended period of time and allow admission to hospital if necessary.

Level of agreement 94%.

(xi) Written emergency pathways should exist for the swift detection and resolution of adverse events after EMR.

Level of agreement 97%.

(xii) There should be access to specialist GI pathologists with an interest in GI neoplasia.

Level of agreement 96%.

2 Theoretical knowledge required for a competent EMR practitioner

3 ASSESSMENT OF LNPCPS FOR SUBMUCOSAL INVASION

ESGE recommends use of the algorithm shown in ► **Fig. 1** and summarized below to risk assess LNPCPs for submucosal invasion (SMI) prior to EMR.

Level of agreement 89%.

Strong recommendation, moderate quality of evidence.

(i) Obtain an overall impression of the LNPCP by assessing its full extent.

Consider surrogate markers of SMI including tethering of folds, friability, and ulceration [19, 20].

(ii) Search for a demarcated area.

A demarcated area is a circumscribed area within a colorectal polyp where there is a definite change from one pit/vascular pattern to another. If detected perform closer assessment of the pit/vascular pattern within such an area [21] (risk of overt SMI). If disordered (NICE III [22, 23], JNET 2B/3 [24, 25], Kudo V [26]) consider the lesion at very high risk of SMI.

(iii) If there is no demarcated area detectable (or the demarcated area is not disordered in pit/vascular pattern), perform a morphologic assessment (Paris classification [27], location, size, granularity) to assess the risk of covert SMI [28].

In general, larger nongranular lesions in the rectum with large nodular components are at the highest risk of covert SMI.

Comment Practitioners who wish to train in EMR should also train in optical diagnosis of colorectal lesions [29]. Discrimination of the cancer risk of a given LNPCP is critical to guide accurate decision-making regarding treatment and to avoid adverse patient outcomes. LNPCPs at low risk of cancer can be treated safely and effectively with EMR [4, 6]. LNPCPs at higher risk of cancer may require more resource-intensive endoscopic resection techniques [12, 30] or surgery [31].

An estimate of the specific per-polyp risk of SMI can be obtained using referenced online scoring systems [32]. The threshold of acceptable SMI risk, especially covert risk, which itself determines the appropriate technique for resection, depends upon multidisciplinary discussion, local expertise, resource availability, and a discussion between the patient and physician [33].

4 FEATURES PROMPTING CONSIDERATION OF EN BLOC RESECTION OR SURGERY

ESGE recommends the endoscopic features of an LNPCP detailed in the following list should prompt consideration of en bloc resection or surgery rather than a piecemeal approach with EMR (► **Table 1**).

Strong recommendation, moderate quality of evidence.

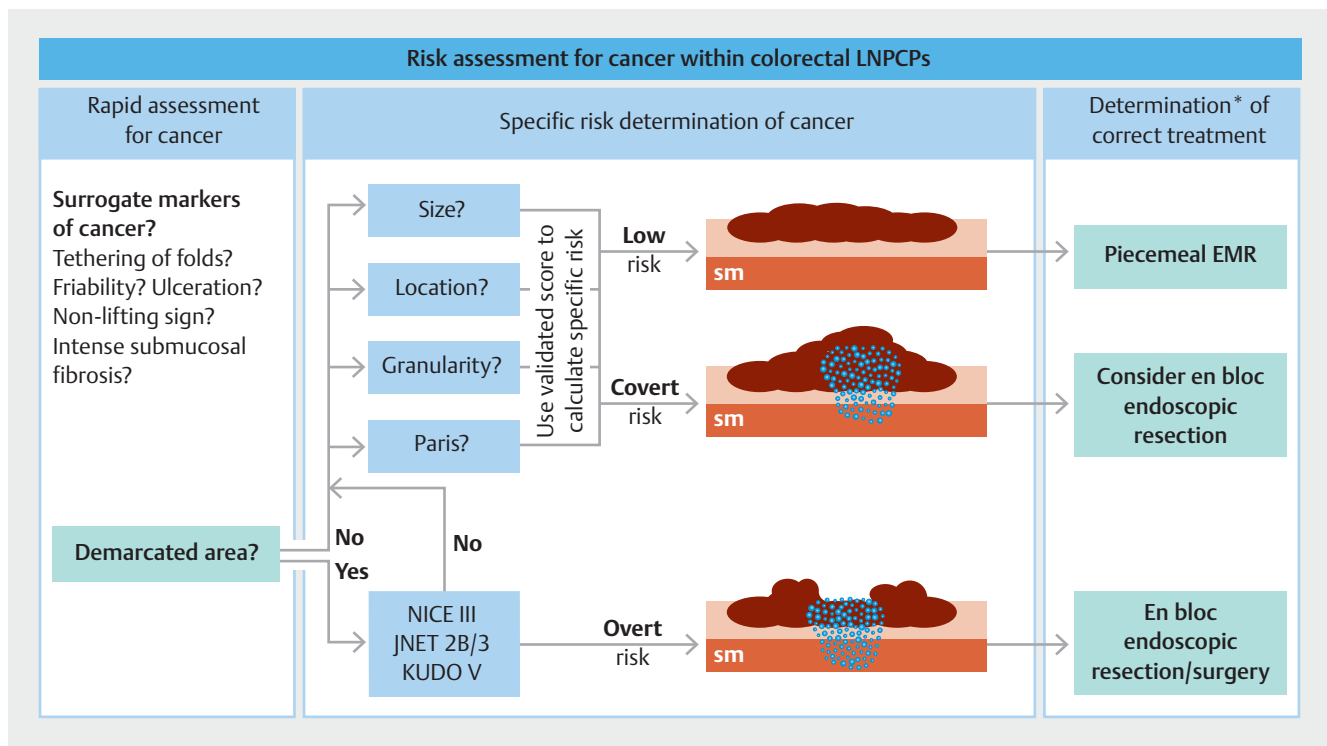


Fig. 1 Illustration of the proposed stepwise approach to cancer detection within colorectal polyps. First look for surrogate markers of cancer and the presence of a demarcated area. A demarcated area with a disordered vascular pattern implies the lesion is at very high or overt risk of cancer and should be considered for en bloc endoscopic resection or surgery (multidisciplinary decision). If there is no demarcated area or the demarcated area contains no disordered vascular pattern, the four parameters of covert cancer risk should be determined to identify the covert risk of cancer and need for en bloc endoscopic resection.

LNPCP, large non-pedunculated colorectal polyp; EMR, endoscopic mucosal resection; Paris, Paris classification; sm, submucosa; NICE, Narrow-band imaging International Colorectal Endoscopic classification; JNET, Japan NBI Expert Team.

* Requires a multidisciplinary approach.

(i) Endoscopic imaging features suggesting low risk superficial SMI (en bloc endoscopic resection) or deep SMI (surgery) [28].
Level of agreement 93%.

(ii) Any bulky (Is, IIa+Is with nodule > 10 mm) lesion in the rectum or at the rectosigmoid junction (high risk for covert SMI) without endoscopic imaging features suggesting overt SMI (en bloc endoscopic resection) [33].
Level of agreement 85%.

(iii) Any LNPCP with Kudo Vi/JNET 2B pit/vascular pattern where en bloc resection is not possible with EMR (en bloc endoscopic resection).
Level of agreement 88%.

(iv) Any LNPCP with Kudo Vn/JNET 3/NICE III pit/vascular pattern (surgery).
Level of agreement 92%.

(v) Any LNPCP with Paris 0-IIa+c or 0-III morphology and ulceration (surgery).
Level of agreement 91%.

(vi) Periappendiceal LNPCPs invading deeply into the appendiceal orifice (defined by the inability to visualize the entire circumferential margin of the lesion) without prior appendectomy (full-thickness resection/surgery) [34].
Level of agreement 84%.

(vii) Inadequate endoscopic access to the target lesion for EMR even by an expert in the technique [35] (laparoscopically assisted EMR or surgery) [36].
Level of agreement 84%.

Comment In general, risk of SMI is the only evidence-based factor that should prompt a decision for en bloc resection in place of piecemeal EMR. Residual or recurrent adenoma, given the efficacy of thermal ablation of the post-EMR margin [37, 38], should not be the sole reason to prefer an en bloc approach. It is also possible to perform piecemeal EMR despite non-lifting (whether in a treatment-naïve or previously attempted/biopsied LNPCP [9]), as long as the risk of cancer (Recommendation 3) is regarded as low.

5 EQUIPMENT/MATERIALS FOR EMR

ESGE recommends familiarity with the equipment/materials required for EMR given in the following list.
Weak recommendation, moderate quality evidence.

(i) Reasons for the use of carbon dioxide as opposed to air [39].
Level of agreement 96%.

► **Table 1** Situations in which en bloc endoscopic resection or surgery may be preferred over a piecemeal endoscopic mucosal resection (EMR).

En bloc resection (endoscopy) preferred	Surgery preferred	Piecemeal EMR standard of care alternative
Endoscopic imaging suggests superficial submucosal invasive cancer (Kudo Vi, JNET 2B) (see Recommendation 3)	Endoscopic imaging suggests risk of deep submucosal invasive cancer (Kudo Vn / JNET 3/ NICE III) (see Recommendation 3)	All other cases
Bulky LNPCP (Is, IIa + Is with nodule > 10 mm) in the rectum (risk of covert SMI)	LNPCPs with Paris 0-IIa + c morphology without ulceration	
	LNPCPs invading deeply into the appendiceal orifice (also consider FTR)	
	Inadequate endoscopic access even by an expert	

LNPCP, large nonpedunculated colorectal polyp; FTR, full thickness resection; covert SMI, invasive cancer not visible on the surface of the polyp.

(ii) Different endoscopes, including pediatric colonoscopes and gastroscopes, and when to consider their use.

Level of agreement 92%.

(iii) Electrosurgical unit, including a clear understanding of the benefits of different cut and coagulation settings [40].

Level of agreement 90%.

(iv) Different types of transparent distal attachment caps and their uses.

Level of agreement 90%.

(v) Waterjet system and endoscope flushing pump.

Level of agreement 96%.

(vi) Injection solutions [41], colloid vs. crystalloid [42,43], use of adrenaline (at a preferred dilution of 1:100 000 or less) [6], and how to prepare them.

Level of agreement 96%.

(vii) Different chromic dyes [44] and their properties.

Level of agreement 93%.

(viii) A variety of different snares and their uses (different lesions and circumstances).

Level of agreement 93%.

(ix) Coagulation forceps [45] and their uses.

Level of agreement 92%.

(x) Different types of endoscopic clips, including different sizes, brands, and rotatability.

Level of agreement 94%.

(xi) Endoscopic tattoo, including technique for placement [46].

Level of agreement 94%.

(xii) Endoscopic retrieval nets.

Level of agreement 93%.

6 MINIMUM REPORTING REQUIREMENTS

ESGE recommends the minimum reporting requirements detailed in the following list for EMR procedures.

Strong recommendation, moderate quality of evidence.

(i) Demographics: name of the patient, date of birth, and one other identifier.

Level of agreement 97%.

(ii) Demographics: name of the staff involved, name of the trainee if involved.

Level of agreement 95%.

(iii) Demographics: indication for the procedure (including original indication if referral or procedure with intent of lesion resection).

Level of agreement 96%.

(iv) Procedure: drugs used including sedation, anesthesia, antibiotics, and/or antispasmodics.

Level of agreement 98%.

(v) Procedure: bowel preparation quality [47–49].

Level of agreement 96%.

(vi) Procedure: completeness of the colonoscopy [48, 50].

Level of agreement 98%.

(vii) Procedure: comfort score if procedure with sedation [48, 51, 52].

Level of agreement 87%.

(viii) Procedure: photodocumentation of the lesion and defect as a minimum [53].

Level of agreement 96%.

(ix) Procedure: type of endoscope and specific electrosurgical device (snare/knife etc.) used.

Level of agreement 89%.

(x) Lesion specific (for each lesion/EMR performed): lesion location and size.

Level of agreement 98%.

(xi) Lesion specific: ease of access and positioning.

Level of agreement 95%.

(xii) Lesion specific: an estimate of position using landmarks, scope tracking, or distance from the anus during withdrawal with a straight scope.

Level of agreement 93%.

(xiii) Lesion specific: description including size, Paris [27], granularity [45], Kudo pit pattern [54]/NICE classification [23]/JNET [55] if magnification is available.

Level of agreement 99%.

(xiv) Lesion specific: previous histology if available.

Level of agreement 95%.

(xv) Technical points: injectate used and description of lifting.

Level of agreement 80%.

(xvi) Technical points: en bloc resection versus piecemeal resection; if a piecemeal resection is performed, record 2–4 pieces versus ≥ 5 pieces [56].

Level of agreement 82%.

(xvii) Technical points: duration of the procedure.

Level of agreement 84%.

(xviii) Technical points: difficulties encountered including intraprocedural complications (perforation, bleeding), if any, and how they were managed.

Level of agreement 96%.

(xix) Technical points: description of the mucosal defect at the end of the procedure [57] and if any adjunctive treatment was performed (for instance snare-tip soft coagulation [STSC] to the margins).

Level of agreement 97%.

(xx) Technical points: was the mucosal defect closed with endoscopic clips? And for which indication – bleeding/perforation?

Level of agreement 97%.

(xxi) Technical points: was the defect marked with a tattoo to aid future localization?

Level of agreement 97%.

(xxii) Technical points: additional lesions present that were not removed and will need to be located and resected later.

Level of agreement 98%.

(xxiii) Technical points: samples retrieved.

Level of agreement 96%.

(xxiv) Fasting instructions and timing of recommencement of clear fluids then normal diet.

Level of agreement 96%.

(xxv) Follow-up plan: immediate aftercare, post-procedural medications, and timing for resumption of anticoagulants.

Level of agreement 96%.

(xxvi) Follow-up plan: suggested surveillance interval [58] (if pathology results indicate benign disease).

Level of agreement 95%.

(xxvii) Follow-up plan: planned further procedures.

Level of agreement 89%.

(xxviii) Follow-up plan: any further tests/investigations required.

Level of agreement 88%.

(i) General histologic category of the lesion: carcinoma, adenoma – tubular or tubulovillous, villous adenoma, traditional serrated adenoma, sessile serrated lesion (SSL), hyperplastic polyp. Level of agreement 97%.

(ii) Degree of cytologic dysplasia – no, low grade or high grade (WHO [62]/Vienna classification [63]).

Level of agreement 96%.

(iii) Horizontal and deep margin free of polyp (completeness of excision [relevant only for en bloc resection]).

Level of agreement 96%.

(iv) Understand that neither “carcinoma in situ” nor “intramucosal cancer” [63] stated in pathology reporting are indications for earlier follow-up or surgery, both being comparable to high grade dysplasia. Both terms should be interpreted as high grade dysplasia and managed endoscopically.

Level of agreement 93%.

(v) Completeness of piecemeal EMR is a judgement made endoscopically at the time of the index procedure in conjunction with the results of histopathology. It is confirmed at surveillance procedures via the endoscopic and/or histologic assessment of the resection scar.

Level of agreement 94%.

(vi) Differentiation of submucosal invasive cancer (SMIC): well, moderately, or poorly differentiated.

Level of agreement 94%.

For all LNPCPs containing SMIC

(vii) Depth of invasion from the muscularis mucosae ($< 1000 \mu\text{m}$ vs. $\geq 1000 \mu\text{m}$; sessile polyp) [64, 65].

Level of agreement 90%.

(viii) Presence of lymphovascular invasion [59–61].

Level of agreement 94%.

(ix) Presence of tumor budding [66, 67].

Level of agreement 94%.

Comment For LNPCPs, the depth of submucosal invasion has been classified using the level system [68, 69], which divides the submucosal layer into sm1, sm2, and sm3. The classification cannot however be applied when lesions have been resected endoscopically, as the full thickness of the submucosal layer is not usually included. Using a measurement of the distance of invasion from the muscularis mucosae was proposed as an alternative [64]. Endoscopically resected LNPCPs containing SMIC with a depth of invasion from the muscularis mucosae $< 1000 \mu\text{m}$ without any other histologic risk factors can usually be followed up without additional surgery, including lymphadenectomy, as the risk of metastasis is almost nil in such cases [65].

7 INTERPRETATION OF PATHOLOGY REPORTS

ESGE recommends that the features of the pathologic report concerning the specimen retrieved after EMR that are detailed in the following list be fully interpretable by a competent EMR practitioner.

Strong recommendation, moderate quality of evidence.

Correct interpretation of histopathology reports is critical to a complete understanding of EMR. A practitioner trained in EMR must understand the features of a pathology report described below because these are important to determine the indication for earlier follow-up or surgery [59–61].

8 ATTENDANCE AT MULTIDISCIPLINARY MEETINGS

ESGE recommends that trainees in EMR regularly attend a multidisciplinary meeting.

Level of agreement 93%.

Strong recommendation, moderate quality of evidence.

Comment Multidisciplinary team (MDT) meetings have become the standard of care in the field of oncology. Such meetings usually comprise of a surgeon, oncologist, radiotherapy specialist, radiologist, and histopathologist. There is a substantial body of evidence to support the efficacy of such MDT meetings in terms of important outcomes for colorectal cancer patients (including patient survival) [70–73]. An MDT approach can also facilitate appropriate case selection of early colorectal cancer for endoscopic treatment, including EMR [74].

Trainee inclusion in an MDT is recommended if they are routinely practicing endoscopic resection in the lower GI tract, both to identify lesions that can be handled endoscopically and to understand the referral, pre-assessment, and treatment pathways for the complete range of lesions that may present to them.

3 Before EMR

9 GROUND RULES PRIOR TO STARTING EMR TRAINING

ESGE recommends that, prior to starting training and the establishment of a trainee–trainer relationship, the ground rules listed below should be established. Best practice recommendation, low quality evidence.

(i) Endoscopists who provide training in EMR (EMR trainers) should have fulfilled the requirements in this competency

framework (Recommendation 37), be aware of their own outcomes, and follow them up (Recommendation 38).

Level of agreement 86%.

(ii) Trainees in EMR should first undertake a period of observation: watching experts perform procedures and verbalizing thoughts on lesions and the approach to their resection. The number of procedures is not specified and should be agreed during discussion between the trainee and the trainer.

Level of agreement 92%.

(iii) During this observation period, the relevant literature on endoscopic resection should be thoroughly reviewed (including the content of Recommendations 3–7).

Level of agreement 91%.

(iv) Training in EMR to become competent (as defined in this curriculum) is best accomplished during a dedicated fellowship of >6 months.

Level of agreement 88%.

(v) During any fellowship, trainees should not initially expect to fully complete all cases (establishing ground rules is critical). Recommendation 28 may form a structure for discussing the ground rules of training.

Level of agreement 96%.

(vi) The SMSA and SMSA+ scores may be helpful to guide which lesions are suitable for initial training (► **Table 2**) [36].

Level of agreement 92%.

(vii) Training should be competency based, rather than based on specific numbers of procedures, perhaps focusing on a

► **Table 2a** Scoring system for the SMSA (size, morphology, site, and access) score¹.

Size, cm	Points	Morphology	Points	Site	Points	Access	Points
<1 cm	1	Pedunculated	1	Left colon	1	Easy	1
1–1.9	3	Sessile	2	Right colon	2	Difficult	3
2–2.9	5	Flat	3				
3–3.9	7						
>4	9						
SMSA score	1	2	3	4			
Total points	4–5	6–9	9–12	>12			

¹ The SMSA score [36] is composed of four domains, which are allocated points; adding the points for each domain results in a score of 1–4.

► **Table 2b** Scoring system for the SMSA+ score¹.

Size, cm	Points	Difficult location ²	Points	Non-lifting/ previous attempt	Points	Granularity	Points
<4	0	No	0	No	0	Granular	0
≥4	1	Yes	1	Yes	1	Non-granular ≥20 mm	1
SMSA+ score	Positive	Negative					
Total points	≥1	<1					

¹ The SMSA+ score (combines references [75, 76]) is binary, either positive or negative. The score is positive if any of the components are present (and therefore if a score of ≥1 is obtained).

² Difficult location includes direct involvement of the ileocecal valve, or involvement of a diverticulum, the anorectal junction, the appendiceal orifice, or a flexure.

particular skill per lesion; for example, lesion assessment, injection technique, snare selection, and placement technique etc. in the manner outlined in the following sections.

Level of agreement 96%.

(viii) Training should commence on lesions of <30 mm in standard colonic locations (not those described in the SMSA+ score) and progress to larger lesions, difficult locations/difficult access etc. as skills develop.

Level of agreement 99%.

(ix) EMR trainers should ideally have attended a course on the theory of training and how it applies to training in endoscopy (train-the-trainers course).

Level of agreement 86%.

10 PROCESS FOR PATIENT CONSENT

ESGE recommends that the aspects of patient consent detailed in the following list be discussed by a competent EMR practitioner prior to the procedure.

This information should be given to the patient in written format prior to the procedure, with an opportunity for discussion before commencing bowel preparation.

Strong recommendation, moderate quality of evidence.

(i) Adequate time should be planned to fully discuss the following risks and benefits with the patient and allow them to ask questions prior to EMR.

Level of agreement 93%.

(ii) Patients should be made aware that, while a significant number of LNPCPs will undergo malignant transformation [77, 78], the timescale of this cannot be predicted. This is particularly relevant if the patient has a shortened life-expectancy owing to advanced age or co-morbidity.

Level of agreement 94%.

(iii) Patients should be made aware of the main advantages and drawbacks of the proposed endoscopic procedure and its duration. This should be highlighted in the context particularly of multiple lesions (which may require multiple procedures) and predicted early malignant lesions [79–81].

Level of agreement 93%.

(iv) Patients should be made aware that the alternatives to EMR are other endoscopic therapies (e.g. endoscopic submucosal dissection), surgery, and endoscopic monitoring, and should be made aware of the risks/benefits of these.

Level of agreement 99%.

(v) Patients should be aware that, while it is commonly possible to perform EMR as a day-case procedure, there is a small chance that admission may be required for recovery from sedation (if living alone for example) or an adverse event [6].

Level of agreement 94%.

(vi) Patients should be aware that there is a small (<1%) risk of unrecognized or unresolvable perforation during EMR and that this may necessitate emergency surgery if it cannot be managed endoscopically [79].

Level of agreement 96%.

(vii) Patients should understand that there are some risks associated with the sedation/anesthesia for their endoscopic procedure. Such risks are generally small for patients who are well but may be higher for those with substantial co-morbidity.

Level of agreement 97%.

(viii) Patients should understand that there is a risk of incomplete resection of their lesion using EMR. They may therefore need more than one procedure, or even surgery, to completely remove their lesion [6].

Level of agreement 96%.

(ix) Patients should be informed that there is an approximately 3%–12% risk (primarily dependent on lesion size, location, and the use of anticoagulants) of significant bleeding requiring hospitalization or reintervention after EMR, and that this risk can be reduced, but not fully mitigated, by adjuvant endoscopic techniques such as clipping [6, 82, 83].

Level of agreement 93%.

(x) The risk of bleeding associated with anticoagulants should be personalized and a plan to manage an individual's anticoagulation communicated in advance of the procedure, in discussion with other healthcare professionals involved in the individual's care and in concordance with published guidance [84].

Level of agreement 95%.

(xi) Patients should be informed that there is an approximately 0.7% risk of delayed perforation requiring surgical intervention after EMR at expert centers [6].

Level of agreement 92%.

(xii) Patients should be aware that, despite best endoscopic prediction, 5%–7% of LNPCPs that are predicted to be benign from endoscopic pit pattern assessment will contain occult SMI and further treatment may be required after EMR [4, 28].

Level of agreement 92%.

(xiii) Patients should be aware that LNPCPs that have undergone previous resection attempts, including those marked with carbon particle suspension beneath the lesion or previously biopsied, have a lower rate of successful resection [9, 85] and a higher risk of adverse events [9] than those that have not undergone previous attempts.

Level of agreement 90%.

(xiv) Personal and center-based metrics for EMR (see Recommendation 38) should be available to patients if available and if requested.

Level of agreement 81%.

(xv) Postoperative instructions should be clearly communicated to patients including what to expect, when to call for help, and a point of contact if problems occur.

Level of agreement 96%.

(xvi) Patients should be aware that there is a risk of polyp recurrence after endoscopic resection, which may require further treatment [6, 86, 87].

Level of agreement 95%.

(xvii) Patients should therefore be aware of the need for long-term scheduled surveillance procedures after EMR to detect and treat recurrent polyps and or metachronous lesions [88, 89].

Level of agreement 95%.

Comment Informed two-stage consent is a crucial part of patient care. The historical approach of informed consent focusing solely on safety is no longer sufficient. Consent should include all aspects of the procedure, including other treatment modalities, post-procedure recovery, future procedures/surveillance dependent on histopathology result etc. Furthermore, patients should be aware of the precise risk estimation of complications and other medical outcomes, based on the current literature and the individual center's experience. Consent should be obtained by competent EMR practitioners or those in training who have had their consent process observed.

11 PATIENT/LESION WORK-UP PRIOR TO EMR

ESGE recommends the patient/lesion work-up detailed in the following list should be conducted by a competent EMR practitioner prior to the procedure.
Weak recommendation, moderate quality of evidence.

- (i) Informed patient consent.
Level of agreement 97%.
- (ii) The appropriateness of the procedure and the risk of adverse events should be considered in the context of patient comorbidities and life expectancy.
Level of agreement 96%.
- (iii) Relevant specialty review of co-morbid conditions is only needed in specific cases; most patients do not require a specialist consultation prior to EMR.
Level of agreement 92%.
- (iv) Anticoagulant and antiplatelet use should be assessed and a plan for adjustment should be discussed with the patient prior to EMR [84, 90].
Level of agreement 96%.
- (v) The need for prophylactic antibiotics in relation to underlying health conditions should be determined as per published guidance [91, 92].
Level of agreement 89%.
- (vi) Local guidelines should be followed in preparing patients with an implantable cardioverter-defibrillator, spinal stimulator, or deep-brain stimulator to undergo EMR.
Level of agreement 93%.
- (vii) (If the procedure is to be performed under monitored anesthesia care) anesthetist/perioperative physician review should be arranged as per local guidance.
Level of agreement 85%.
- (viii) Social factors that may warrant an overnight stay should be assessed prior to booking the procedure. Alternatively, frail patients living on their own can be asked to stay with family members, given that overnight hospital stays may not always be practical owing to local hospital bed constraints.
Level of agreement 92%.
- (ix) The quality of previous bowel preparation should be discussed when this was previously poor and the importance of good bowel preparation should be emphasized [93, 94].
Level of agreement 95%.

(x) Prior radiographic imaging findings relevant to the lesion for resection should be reviewed by the proceduralist when available; however, radiographic imaging is generally not required prior to EMR.

Level of agreement 92%.

(xi) Patients should be advised not to plan any travel (without emergent access to hospital emergency services) in the 14 days after EMR.

Level of agreement 82%.

12 DETERMINING WHETHER A TRAINEE SHOULD START AN EMR PROCEDURE

ESGE recommends that the criteria given in the following list should be considered when determining when/if EMR procedures should be started by a trainee.
Best practice recommendation, low quality of evidence.

- (i) From the outset, certain lesions are unsuitable for hands-on training and this should be recognized by the supervising practitioner (e.g. complex location, very large lesions, previously attempted lesions, unstable or very co-morbid patient).
Level of agreement 97%.
- (ii) Prior knowledge of the SMSA and SMSA+ scores (► **Table 2**) of the target lesion for EMR can be useful to predict the possibilities for training [36, 75, 76].
Level of agreement 93%.
- (iii) A trainee in EMR should not be paired with a nursing or other colleague training in assisting at EMR.
Level of agreement 88%.

13 DETERMINING THE RESECTABILITY OF LNPCPS

ESGE recommends that the points given in the following list regarding the resectability of LNPCPs are considered by a competent practitioner in EMR.
Best practice recommendation, low quality of evidence.

- (i) The endoscopist should make a full and comprehensive assessment of the LNPCP to be resected including high definition white-light endoscopy, virtual chromoendoscopy, and use of magnification if available (see Recommendations 3 and 4).
Level of agreement 95%.
- (ii) LNPCPs suspected of containing deep SMIC are not suitable for attempted EMR.
Level of agreement 94%.
- (iii) Only SSLs without dysplasia [5, 95, 96] are suitable for piecemeal cold snare polypectomy (within the scope of this competency framework).
Level of agreement 92%.
- (iv) Photodocumentation of the lesion is strongly recommended prior to starting the endoscopic resection procedure.
Level of agreement 96%.

14 CONSIDERATIONS BEFORE EMR OF AN LNPCP

ESGE recommends that the points given in the following list should be considered by a competent EMR practitioner prior to EMR once an LNPCP has been judged endoscopically resectable.

Best practice recommendation, low quality evidence.

(i) Adequate colon cleanliness according to the Boston Bowel Preparation scale (BBPS) [97] or another similar scale. BBPS < 2 in the colonic segment containing the LNPCP for resection suggests inadequate preparation for EMR and an increased risk of failure and complications [58].

Level of agreement 86 %.

(ii) LNPCPs with endoscopic imaging suggestive of overt superficial SMI or those with high risk of covert SMI [28] should be considered for en bloc resection (see Recommendation 4).

Level of agreement 95 %.

(iii) An alternative option for large nodules or small areas within LNPCPs suspicious for SMI is piecemeal resection with en bloc resection of the suspicious area for better pathology reporting.

Level of agreement 84 %.

(iv) En bloc EMR for LNPCPs ≥ 15 mm (right colon) and ≥ 20 mm (left colon) should not always be pursued at all costs when there is no overt and low covert risk of SMI, owing to the increased risk of intraprocedural complications (e.g. intraprocedural perforation [98]) without benefit in terms of adenoma recurrence [37, 38].

Level of agreement 89 %.

(v) The endoscopist should consider their own capacity to complete the procedure on that occasion. Credentialling (see Recommendation 37) and the SMSA score (► **Table 2**) can help in this determination. If there is doubt as to the competency of the endoscopist, or that the lesion can be fully resected in a single session, and the potential adverse events of such a resection managed, the endoscopist should not attempt resection and should consider referring the patient to an EMR specialist.

Level of agreement 96 %.

(vi) The endoscopist must be able to obtain optimal endoscopic access to the LNPCP under consideration for EMR (short scope position without looping, allowing one-to-one movement).

Level of agreement 94 %.

(vii) A plan should be devised for a systematic approach to resection of the LNPCP under consideration for EMR.

Level of agreement 94 %.

15 ENDOSCOPIC NON-TECHNICAL SKILLS

ESGE recommends that a practitioner competent in EMR has developed strong endoscopic non-technical skills as detailed in the following list.

Best practice recommendation, low quality evidence.

Endoscopic non-technical skills (ENTS) [99] concern non-technical, non-theoretical aspects of EMR that are nevertheless critical for patient outcomes and the well-being of all staff involved in endoscopy procedures. They can be graded from 1 (poor) to 4 (good) and are described for a competent practitioner of EMR.

Communication and teamwork

(i) Exchanging information: gives and receives knowledge and information in a clear and timely fashion.

Level of agreement 89 %.

(ii) Maintaining a shared understanding: ensures that both the team and the endoscopist are working together from the same information and understand the “big picture” of the case.

Level of agreement 89 %.

(iii) Maintaining a patient-centered approach: ensures that the patient is at the center of the procedure, emphasizing safety and comfort, and giving information in a clear and understandable fashion.

Level of agreement 89 %.

Situational awareness

(iv) Preparation: ensures that the patient is fit, the procedure is appropriate, and that it is being performed by an endoscopist with the necessary skills, equipment, and assistants for safe and successful completion (adequate work-up performed as per prior Recommendations).

Level of agreement 92 %.

(v) Continuous assessment: maintains a continuous evaluation of the patient’s condition and updates the shared understanding to identify any mismatch between the current situation and expected state.

Level of agreement 92 %.

(vi) Problem recognition: recognizes a mismatch between the current situation and the expected state and anticipates what may happen as a result of possible actions, interventions, or non-intervention.

Level of agreement 92 %.

(vii) Focus: ensures a lack of distractions and maintains concentration, particularly during difficult situations.

Level of agreement 92 %.

Leadership

(viii) Supporting others: provides emotional and cognitive support to team members and trainees by tailoring leadership and teaching style appropriately.

Level of agreement 91 %.

(ix) Maintaining standards: supports safety and quality by adhering to current protocols and codes of clinical practice.

Level of agreement 93 %.

(x) Dealing with problems: adopts a calm and controlled demeanor when under pressure, utilizing all resources to maintain control of the situation, and taking responsibility for patient outcome.

Level of agreement 92 %.

Judgement and decision-making

(xi) Considering others: generates possible courses of action to solve an issue or problem, including assessment of risk and benefit.

Level of agreement 89 %.

(xii) Making decisions: chooses a solution to a problem, communicating this to team members and implementing it.

Level of agreement 89%.

(xiii) Reviewing the situation: reviews the outcomes of the procedure or options for dealing with problems, reflecting on issues and instituting changes to improve practice.

Level of agreement 88%.

4 Recommendations during EMR

This section should be read alongside Section 7 Completion of training, which describes an assessment tool for technique during the performance of EMR. An electronic version of this curriculum is available at: www.gieqs.com/emr-curriculum-esge. This version contains multiple video demonstrations of the techniques described.

Sections 4.1 and 4.2 are similar, describing the technical approaches to cold and hot snare polypectomy. Differences are highlighted where present in ► **Table 3**. ► **Fig. 2** depicts best practice and poor practice from a number of the recommendations below.

4.1 Best practice technique for EMR (cold snare)

Meticulous and systematic cold snare polypectomy technique is essential to achieve complete removal of colonic adenomas [5, 95, 96, 109]. A recent systematic review and meta-analysis found incomplete resection rates of 17.3% (95%CI 14.3%–20.3%) for ≤10-mm polyps removed by cold snare polypectomy [97]. Moreover, a pooled multicohort retrospective analysis of eight North American studies estimated that 19% of interval colorectal cancers were due to incomplete resection of a previously noninvasive lesion [110].

16 SUBMUCOSAL INJECTION TECHNIQUE

ESGE recommends the best practice submucosal injection technique described below for cold snare EMR.

Weak recommendation, low quality of evidence.

(i) Use injection to improve lesion access and visualization (► **Fig. 2**, image B2).

Level of agreement 86%.

(ii) Ensure air is expelled from the injection catheter prior to first injection (priming).

Level of agreement 88%.

(iii) Injection through clearly benign lesions is acceptable if necessary. Caution should be exercised when attempting injection through LNPCPs suspected of containing SMIC because of the risk of malignant seeding [111].

Level of agreement 88%.

(iv) Injection should be performed dynamically. The injection is started (short stab, tangential to the mucosa) as the tissue is being punctured and then the catheter is pulled back and lifted up/away in the desired direction [112].

Level of agreement 87%.

(v) Avoid intramucosal blebs (► **Fig. 2**, image B4). If these occur, puncture them and re-attempt submucosal injection [113].

Level of agreement 87%.

(vi) Stop the injection if no lifting is noted (likely transmural/intraperitoneal injection).

Level of agreement 88%.

(vii) Obtain an appropriate and sustained lifting of the lesion (► **Fig. 2**, image B2).

Level of agreement 86%.

(viii) Do not over-lift, especially in narrow segments (e.g. sigmoid colon) or at flexures.

Level of agreement 85%.

17 SNARE PLACEMENT, CAPTURE, AND CLOSURE

ESGE recommends the best practice snare placement, capture, and closure technique described below for cold snare EMR.

Best practice recommendation, low quality evidence.

(i) Use of a dedicated, thin-wire (0.3-mm wire diameter) cold snare is strongly recommended when performing piecemeal cold snare polypectomy.

Level of agreement 90%.

(ii) A maximum snare diameter of 10 mm is recommended for piecemeal cold snare polypectomy as tissue transection of pieces >10 mm regularly leads to stalling of snare transection.

Level of agreement 91%.

(iii) Ensure the lesion is positioned as close to the 6-o'clock position as possible (or is transformed to 6 o'clock using the snare pivot technique).

Level of agreement 91%.

(iv) Start at the edge of the lesion.

Level of agreement 92%.

(v) Aim to capture a rim of 1–3 mm of normal mucosa (► **Fig. 2**, images A4 and C1). This is critical in cold snare polypectomy owing to the absence of electrosurgical energy.

Level of agreement 94%.

(vi) Ideally the long axis of the snare should be placed parallel to the polyp base.

Level of agreement 93%.

(vii) The V of the snare (► **Fig. 2**, images C1 and C2) should be extended just beyond the tip of the snare catheter prior to snare placement.

Level of agreement 92%.

(viii) Use aspiration of luminal gas and firm downward pressure with the tip of the endoscope whilst closing the snare to aid tissue capture. For cold snaring, using a dedicated thin-wire snare and pushing the snare against the colonic wall is also effective to maximize tissue capture.

Level of agreement 92%.

(ix) Placement of the snare should be under direct visualization and aligned precisely with the advancing edge of the mucosal defect (if piecemeal) (► **Fig. 2**, image C2).

Level of agreement 93%.

► **Table 3** Differences highlighted in this curriculum between the best practice technique for cold versus hot snare endoscopic mucosal resection (EMR)¹.

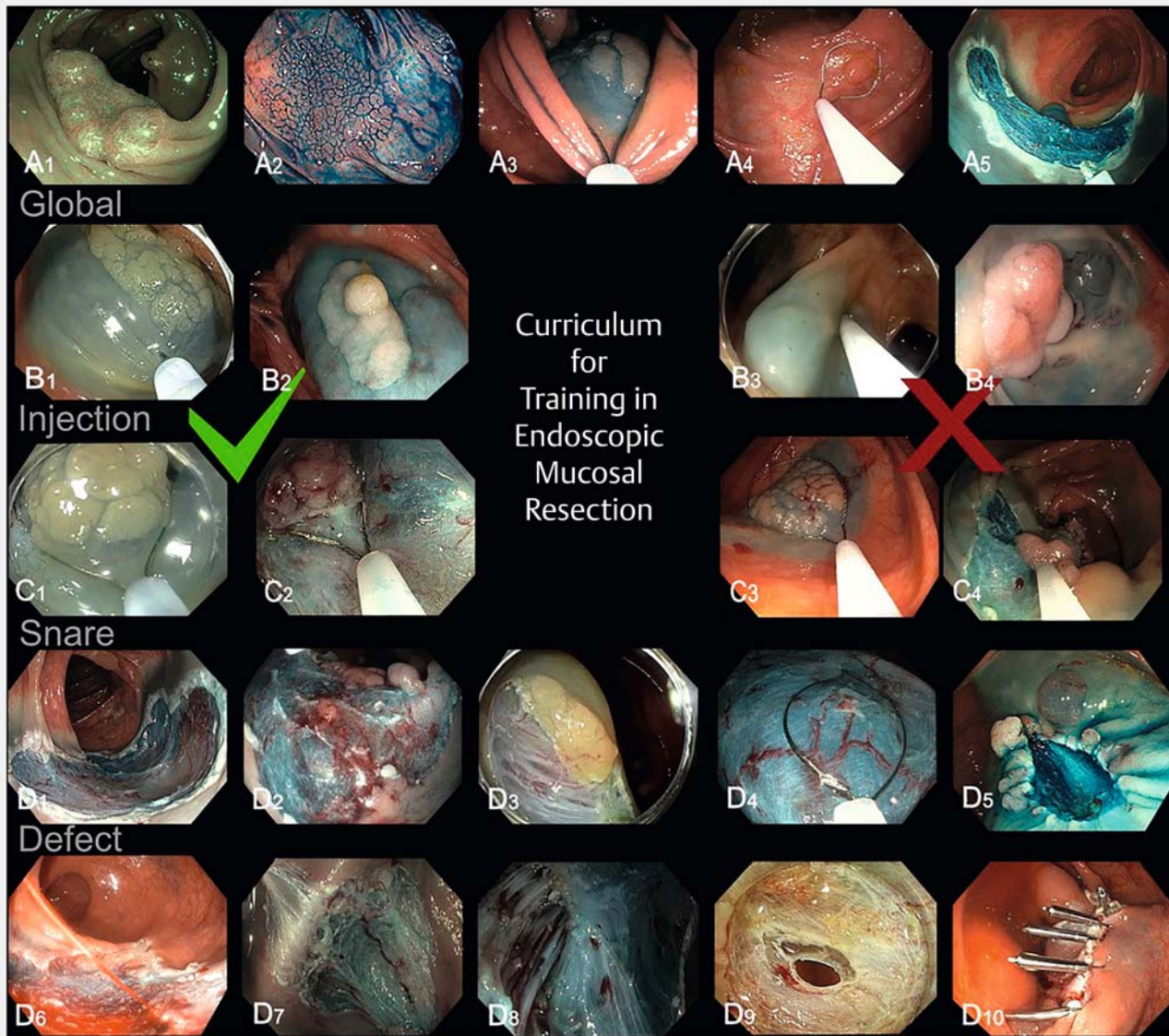
Domain	Cold EMR statement	Hot EMR statement	Rationale
Injection technique			
Approach to lesion lifting	Use injection to improve lesion access and visualization; Recommendation 16(i)	Do not attempt to lift the whole lesion at once. Start by lifting only the part you will start to resect. Then follow a process of sequential inject and resect for larger lesions; Recommendation 19(i)	Injection is not required for cold snare EMR; if it is used it is to aid polyp access or to better define margins. Over-injection can increase the tension in the colonic mucosa and prevent tissue capture during hot snare EMR. Because dedicated cold snares capture tissue more easily and target lesions for cold snare EMR are often smaller, the importance of this is reduced
Snare placement technique			
Snare type	Use a dedicated cold snare; Recommendation 17(i)	Use an appropriate snare for the lesion and situation; Recommendation 20(i)	For cold snare EMR, crisper resection margins which are easier to examine for residual tissue can be achieved using a dedicated cold snare. This is especially important for piecemeal cold snare polypectomy. In hot snare polypectomy, electro-surgical energy ensures interpretable resection margins. Different snares may be required in different situations; see curriculum text, Recommendation 20(i)
Snare size	A maximum snare diameter of 10 mm is recommended for piecemeal cold snare polypectomy; Recommendation 17(ii)	Use of an appropriate size snare for the lesion (maximum 15 mm snare for the right colon and 20 mm for the left colon); Recommendation 20(ii)	Snare sizes > 10 mm do not tend to reliably transect tissue without electro-surgical energy. The snare sizes denoted in the recommendation are those recommended for hot snare EMR to ensure safety [116]
Maximizing tissue capture	For cold snare using a dedicated thin-wire snare pushing the snare against the colonic wall is also effective to maximize tissue capture; Recommendation 17(viii)	Use aspiration of luminal gas and firm downward pressure with the tip of the endoscope whilst closing the snare to aid tissue capture; Recommendation 20(viii)	Use of a dedicated thin-wire snare for cold snare EMR often allows more reliable capture of tissue without requiring the maneuvers described in Recommendation 20(viii) which are useful when using a thicker wire snare for hot snare EMR
Snare closure	The endoscopist issues an instruction to cut the tissue and the assistant closes the snare fully or the endoscopist takes the snare themselves and cuts the tissue. The assistant should not re-open the snare unless instructed to do so by the endoscopist; Recommendation 17(xiii)	At this stage the endoscopist may take the snare and close the handle such that approximately 1 cm remains between the fingers holding the snare handle and the thumb. Tactile feedback helps the endoscopist to detect entrapped muscularis propria and therefore minimizes the risk of perforation; Recommendation 20(xiii). (Alternative) Placing a marker on the handle of the snare at the position where (during closure outside the patient) the tip of the snare is seen to enter the sheath may be an alternative to assess the extent of closure, such that the snare may remain with the assistant; Recommendation 20(xiv)	Transection during cold snare EMR is usually with the assistant. Unlike hot snare EMR, the assistant fully closes their hand until the tissue transects because the technique is dependent upon mechanical pressure of the snare wire on the captured tissue. During hot snare EMR, full closure of the snare is not desirable, thereby allowing electro-surgical energy to transect the tissue

► **Table 3** (Continuation)

Domain	Cold EMR statement	Hot EMR statement	Rationale
Failed transection	<p>If the tissue does not transect after 5 seconds, the endoscopist should pull gently on the snare catheter such that the tissue abuts the tip of the endoscope (guillotine technique) [107]; Recommendation 17(xiv).</p> <p>If the tissue still does not cut despite attempting use of the guillotine technique, ask the assistant to slowly open the snare, while continuing gentle traction on the polyp. This usually leads to the mucosa specimen sliding over a submucosal protrusion; Recommendation 17(xv).</p> <p>If the tissue still does not transect the snare should be re-opened and the procedure repeated; Recommendation 17(xvi).</p> <p>We recommend against the addition of electro-surgical energy in the situation where complete closure of the snare during cold snare resection does not transect despite the above measures as this risks muscularis propria injury; Recommendation 17(xvii)</p>	<p>Check the mobility of captured tissue with the snare closed ensuring it moves independently to the muscularis propria of the colon; Recommendation 20(xv)</p>	<p>Failed transection in cold snare EMR often describes the situation where too much submucosa has been captured. In this case gentle traction on the endoscope tip can solve the problem (guillotine technique). It is possible to capture the muscularis propria during cold snare EMR so excessive force or adding electro-surgical energy should be strongly discouraged. In this situation the snare should be re-opened and the positioning revised. In hot snare EMR, the intention is to capture submucosa. Here safety checks should be made to ensure the muscularis propria is not captured as described in the recommendations</p>
Inspection of the post-EMR defect			
Detection of residual adenoma	<p>Topical application of a chromic dye (or the injectate if it contains a chromic dye) can be helpful for assessing the defect and the margin after cold snare polypectomy for residual adenoma [108]; Recommendation 18(ii)</p>	<p>Topical application of the injectate (containing a chromic dye) can be helpful for areas of the defect where there is uncertainty as to the presence of muscularis propria injury (► Fig. 2, images D7 and D8). If the defect stains blue this area represents submucosa and the muscularis propria is uninjured [108, 120]; Recommendation 22(x)</p>	<p>Topical application of a chromic dye can be extremely useful to check for residual at the margin of a cold/hot snare defect. Muscularis propria injury is extremely rare in cold snare EMR but in hot snare it should be routinely sought; a chromic dye makes the delineation between submucosa and muscularis clear</p>
Treatment of bleeding	<p>Bleeding from within a cold snare polypectomy defect does not need treatment unless pulsatile; Recommendation 18(iv)</p>	<p>The submucosa of the defect should be further inspected for bleeding vessels. These should be coagulated [118]; Recommendation 22(v)</p>	<p>Persistent active bleeding in hot snare EMR suggests a large, transected blood vessel which should be cauterized (techniques described in Recommendation 29). Immediate oozing bleeding is common after cold snare EMR but always stops spontaneously if non-pulsatile</p>
Perforation	<p>Be aware that perforation of the muscularis propria after cold snare polypectomy is extremely rare and described only in case reports [109, 110]. This should be treated appropriately if it occurs; Recommendation 18(v)</p>	<p>The muscularis propria should be inspected if visible and described using the Sydney Classification of Deep Mural Injury [57] (► Fig. 2, images D7–D9). Any areas suspicious or uncertain for injury to the muscularis propria (DMI types II–V) should be closed with an endoscopic closure method; Recommendation 22(ix)</p>	<p>Injury to the muscularis propria during cold snare EMR is rare. If muscularis propria is caught in a snare closed without electro-surgical energy, the snare will not transect. Gentle traction against the tip of the instrument is acceptable as this will not injure the muscularis propria. Excessive force should be avoided, as should the use of electro-surgical energy, because this situation could allow transection of the muscularis propria. In hot snare EMR, defect inspection for injury to the muscularis propria is critical and should always be performed as described in Recommendation 22(ix)</p>

EMR, endoscopic mucosal resection; DMI, deep mural injury; MP, muscularis propria.

¹ The resection plane in cold snare EMR is through the muscularis mucosae; in hot snare, it is the mid-submucosa [122, 123]. This explains the differences in required technique and potential adverse events described above.



▶ Fig. 2 Example images illustrating best practice techniques (with **B3,4** and **C3,4**, poor practice examples) in endoscopic mucosal resection for: **A** global competencies; **B** injection technique; **C** snare placement technique; **D** defect assessment technique; showing: **A1,2** full appreciation/demonstration of the extent of the polyp to be resected; **A3** best positioning with respect to the polyp (at 6 o'clock, close to the colonoscope); **A4** selection of the appropriate technique for the polyp to be resected (e. g. correct decision for en bloc cold snare polypectomy in this example); **A5** tip control (controlled stable and purposeful, resulting in uniform application of snare-tip soft coagulation); **B1,2** injection performed in the correct plane, facilitating access to the lesion; **B3** transmural non-dynamic injection (poor practice); **B4** non-lifting, with repeated and failed submucosal injection resulting in intramucosal blebs (poor practice); **C1** the snare oriented near to 6 o'clock, visualization of the snare V during closure, with the snare near to the colonoscope; **C2** use of the transected tissue edge as a guide (within the defect), and visualization of the snare V during closure, with the snare close to the colonoscope; **C3** the snare positioned far from the colonoscope, with too much snare extended from the sheath and no margin of normal tissue (poor practice); **C4** poor tissue capture and too far from the colonoscope (likely to result in scraping of polyp tissue and incomplete mucosal layer excision; poor practice); **D1** complete margin ablation, following systematic application with entire margin ablation achieved; **D2,4** incomplete mucosal layer excision with evidence of residual polyp tissue on islands of muscularis mucosae; **D3** residual polyp tissue at the resection margin; **D5** evidence of deep mural injury (DMI) type I, with residual polyp tissue at the defect edge, and failed submucosal injection resulting in an intramucosal bleb; **D6** intraprocedural bleeding; **D7** DMI type I; **D8** DMI type III associated with an area of fibrosis; **D9** DMI type IV; **D10** complete closure of a post-endoscopic mucosal resection (EMR) mucosal defect to prevent post-EMR bleeding.

(x) The tip of the snare catheter (and the V of the snare just beyond its tip) should be close to the endoscope during closure and constantly visualized during closure if possible (► Fig. 2, image C2).

Level of agreement 93%.

(xi) The assistant is asked to close the snare and to stop closure, issuing a verbal alert to the endoscopist, when resistance is felt. Level of agreement 90%.

(xii) At this point, the endoscopist determines whether the captured tissue is what was desired.

Level of agreement 90%.

(xiii) The endoscopist issues an instruction to cut the tissue and the assistant closes the snare fully or the endoscopist takes the snare themselves and cuts the tissue. The assistant should not reopen the snare unless instructed to do so by the endoscopist. Level of agreement 91%.

(xiv) If the tissue is not transected after 5 seconds, the endoscopist should pull gently on the snare catheter so that the tissue abuts the tip of the endoscope (guillotine technique) [101]. Level of agreement 87%.

(xv) If the tissue still does not cut despite attempted use of the guillotine technique, the assistant is asked to slowly open the snare, while continuing gentle traction on the polyp. This usually leads to the mucosal specimen sliding over a submucosal protrusion.

Level of agreement 90%.

(xvi) If the tissue still is not transected, the snare should be reopened and the procedure repeated.

Level of agreement 86%.

(xvii) We recommend against the addition of electrosurgical energy in the situation where complete closure of the snare during cold snare resection has not led to transection in spite of the above measures as this risks injury to the muscularis propria.

Level of agreement 94%.

(xviii) Work sequentially across the lesion when performing piecemeal resection, aligning the snare with the edge of the advancing mucosal defect (to avoid islands).

Level of agreement 91%.

Comment Use of a dedicated snare allows for clean tissue transection and better analysis of the expanding mucosal defect. Evidence of increased efficacy is however conflicting. In a prospective randomized controlled trial examining the removal of polyps ≤ 10 mm by cold snare polypectomy, use of dedicated cold snares was associated with a significantly greater complete resection rate than traditional cold snares (91% vs. 79%; $P=0.02$) [114]. Conversely, in a recent international multicenter randomized trial, use of dedicated cold snares was not associated with improved complete resection rates [115].

18 INSPECTION OF THE POST-EMR DEFECT

ESGE recommends the best practice technique detailed below for inspecting the post-EMR defect following cold snare EMR.

Best practice recommendation, low quality evidence.

(i) Spend an appropriate amount of time inspecting the entire mucosal defect, particularly the margins, for residual polyp tissue (► Fig. 2, images D2–D5). If there are small areas of residual tissue within the defect, cold snare avulsion can be used to remove these.

Level of agreement 94%.

(ii) Topical application of a chromic dye (or the injectate if it contains a chromic dye) can be helpful for assessing the defect and the margin for residual adenoma after cold snare polypectomy [102] (► Fig. 2, images D4 and D5).

Level of agreement 84%.

(iii) The use of virtual chromoendoscopy and magnification can be helpful to detect residual polyp tissue at the defect margin. Level of agreement 86%.

(iv) Bleeding from within a cold snare polypectomy defect does not need treatment unless pulsatile.

Level of agreement 90%.

(v) Be aware that perforation of the muscularis propria after cold snare polypectomy is extremely rare and described only in case reports [105, 106]. This should be treated appropriately if it occurs.

Level of agreement 89%.

(vi) Photodocumentation of all areas of the post-EMR defect (► Fig. 2, images D1–D5) helps to assess the completeness of the resection. It may also be useful for medicolegal purposes.

Level of agreement 89%.

4.2 Best practice technique for EMR (hot snare)

The following references pertain to Recommendations 19, 20, and 21 [45, 53, 81, 116–120].

The submucosal injection technique for hot snare EMR is similar to that for cold snare EMR; however, endoscopists should avoid attempting to raise the entire lesion at the outset, especially for large lesions. Instead, a sequential inject-and-resect technique should be adopted, where only a portion of the lesion is raised, with each submucosal injection immediately followed by transection of that area.

19 SUBMUCOSAL INJECTION TECHNIQUE

ESGE recommends the best practice submucosal injection technique described below for hot snare EMR.

Best practice recommendation, low quality evidence.

(i) Do not attempt to lift the whole lesion at once. Start by lifting only the part you will start to resect, then follow a process of sequential injection and resection for larger lesions.

Level of agreement 91%.

(ii) Use injection to improve lesion access and visualization (► Fig. 2, image B2).

Level of agreement 91%.

(iii) Ensure air is expelled from the injection catheter prior to the first injection (priming).

Level of agreement 91%.

(iv) Injection through clearly benign lesions is acceptable if necessary (► Fig. 2, image B1). Caution should be exercised when

attempting injection through lesions suspected of containing SMIC because of the risk of malignant seeding [111].

Level of agreement 92%.

(v) Injection should be performed dynamically. The injection is started (short stab, tangential to the mucosa) as the tissue is being punctured and then the catheter is pulled back and lifted up/away in the desired direction [112].

Level of agreement 94%.

(vi) Avoid intramucosal blebs (intramucosal injection) (► Fig. 2, image B4). If these occur, puncture them and re-attempt submucosal injection [113].

Level of agreement 89%.

(vii) Stop the injection if no lifting is noted (likely transmural/intraperitoneal injection).

Level of agreement 91%.

(viii) Obtain an appropriate and sustained lifting of the lesion (► Fig. 2, image B2).

Level of agreement 91%.

(ix) Do not over-lift, especially in narrow segments (e.g. sigmoid colon) or at flexures.

Level of agreement 90%.

20 SNARE PLACEMENT, CAPTURE, AND CLOSURE

ESGE recommends the best practice snare placement, capture, and closure technique described below for hot snare EMR.

Best practice recommendation, low quality of evidence.

As with cold snare polypectomy, a meticulous and systematic approach to snare resection is essential to ensure complete resection of colorectal lesions by hot snare EMR. The differences between the hot snare and cold snare techniques include the recommended use of a thick-wire snare (wire diameter >0.4 mm) for hot snare EMR. This further dictates modifications in the technique owing to the poorer tissue capture properties of these snares.

(i) Use of an appropriate snare type for the lesion and situation (e.g. standard thick-wire snare [wire diameter >0.4 mm] for hot snare polypectomy).

Level of agreement 92%.

(ii) Use of an appropriate size snare for the lesion. Avoid large snares for large lesions [100], with suggested maximums of a 15-mm snare for the right colon and a 20-mm snare for the left colon (distal to splenic flexure).

Level of agreement 86%.

(iii) Ensure the lesion is positioned as close to the 6-o'clock position as possible (► Fig. 2, image C1) (by rotation of the endoscope or transformation to 6 o'clock using the snare pivot technique).

Level of agreement 91%.

(iv) Start at the edge of the lesion.

Level of agreement 96%.

(v) Aim to capture a rim of 2–3 mm of normal mucosa (► Fig. 2, image C1).

Level of agreement 96%.

(vi) Where possible, the long axis of the snare should be aligned parallel to the polyp base.

Level of agreement 89%.

(vii) The V of the snare (► Fig. 2, images C1 and C2) should be extended just beyond the tip of the snare catheter prior to snare placement.

Level of agreement 89%.

(viii) Use aspiration of luminal gas and firm downward pressure with the tip of the endoscope whilst closing the snare to aid tissue capture.

Level of agreement 94%.

(ix) Placement of the snare should be under direct visualization and aligned precisely with the advancing edge of the mucosal defect (if piecemeal) (► Fig. 2, image C2).

Level of agreement 94%.

(x) Placement of the snare should be under direct visualization ensuring a rim of 1–3 mm of normal tissue (► Fig. 2, image C1) completely surrounding the target lesion (if en bloc).

Level of agreement 95%.

(xi) The tip of the snare catheter (the V of the snare just beyond its tip) should be near to the endoscope during closure and constantly visualized during closure (► Fig. 2, images C1 and C2) if possible.

Level of agreement 92%.

(xii) The assistant is asked to close the snare and to stop closure, issuing a verbal alert to the endoscopist, when resistance is felt.

Level of agreement 91%.

(xiii) At this stage, the endoscopist may take the snare and close the handle so that approximately 1 cm remains between the fingers holding the snare handle and the thumb. Tactile feedback helps the endoscopist to detect entrapped muscularis propria and therefore minimizes the risk of perforation.

Level of agreement 88%.

(xiv) Placing a marker on the handle of the snare at the position where (during closure outside the patient) the tip of the snare is seen to enter the sheath may be an alternative to assess the extent of closure, so that the snare may remain with the assistant.

Level of agreement 86%.

(xv) Check the mobility of the captured tissue with the snare closed, ensuring it moves independently to the muscularis propria of the colon.

Level of agreement 96%.

(xvi) Release and reclose the snare if there is concern over capture of the muscularis propria (assistant or endoscopist suggests too much tissue captured).

Level of agreement 96%.

(xvii) Work sequentially across the lesion when performing piecemeal resection, aligning the snare with the edge of the advancing mucosal defect to avoid islands.

Level of agreement 96%.

21 SAFETY CHECKS BEFORE APPLYING ELECTROSURGICAL ENERGY

ESGE recommends the safety checks detailed below be made prior to the application of electrosurgical energy during hot snare EMR.

Moderately strong recommendation, low quality evidence.

(i) Use a modern microprocessor controlled electrosurgical unit capable of delivering a range of currents, including fractionated current [121].

Level of agreement 94%.

(ii) Ensure the correct settings are used on the electrosurgical unit. It is particularly important to recheck during longer procedures, especially after each instrument change or change in patient position.

Level of agreement 93%.

(iii) For monopolar devices, ensure that the patient has an electrosurgical plate on and that the generator is ready to deliver thermal energy.

Level of agreement 93%.

(iv) Ensure a stable colonoscope position: if necessary an assistant should support the scope shaft.

Level of agreement 93%.

(v) Ensure hemostatic options are available immediately afterwards if required (e.g. clips and hemostatic forceps).

Level of agreement 94%.

(vi) The lumen should subsequently be inflated to visualize the captured tissue and snare placement.

Level of agreement 91%.

(vii) The endoscopist should perform a mobility check of the captured tissue to ensure that the muscularis propria is not entrapped.

Level of agreement 90%.

(viii) (If the endoscopist is handling the snare) the endoscopist uses tactile feedback to assess the amount of tissue captured and revises if necessary.

Level of agreement 90%.

(ix) (If the assistant is handling the snare) ensure the assistant knows the sequence of commands on application of electrosurgical energy (e.g. close snare in a controlled manner to the mark).

Level of agreement 83%.

(x) Tent the tissue for resection away from the deeper structures. Apply electrosurgical energy allowing the energy delivered through the snare to transect the tissue rather than using hand pressure to avoid cold snare resection. The snare handle should not snap closed.

Level of agreement 96%.

(xi) During the application of fractionated current, beware if the tissue is not transected within three cycles. Stop further electrosurgical energy application and assess the situation.

Level of agreement 93%.

(xii) Stop the application of electrosurgical energy as soon as the tissue is transected.

Level of agreement 94%.

22 INSPECTION OF THE POST-EMR DEFECT

ESGE recommends the best practice technique detailed below for inspecting the post-EMR defect after hot snare EMR.

Strong recommendation, moderate quality evidence.

(i) Spend an appropriate amount of time inspecting the entire mucosal defect (► Fig. 2, images D2–D5), particularly the margins, for residual polyp tissue [37, 38].

Level of agreement 95%.

(ii) The use of virtual chromoendoscopy and magnification can be helpful to detect residual polyp tissue at the defect margin.

Level of agreement 90%.

(iii) If removal of the snare is difficult, visible polyp tissue should not be coagulated, instead it should be removed using a different snare (► Fig. 2, image D4) or an avulsion technique prior to considering ablation.

Level of agreement 95%.

(iv) After any visible polyp has been removed from the defect margin, a thermal ablation technique (e.g. STSC; ERBE soft coagulation effect 4, 80W) should be applied to the entire margin ensuring a rim of 1–3 mm of complete mucosal ablation. The thermal ablation technique should only be applied to tissue with a prior submucosal injection to ensure safety (► Fig. 2, image A5).

Level of agreement 88%.

(v) The submucosa of the defect should be further inspected for bleeding vessels (► Fig. 2, image D6). These should be coagulated [104] (see Recommendation 29).

Level of agreement 90%.

(vi) The submucosa of the defect should be further inspected for large herniating vessels. The weight of available evidence suggests that, if vessels are not bleeding, they do not need to be coagulated [122].

Level of agreement 88%.

(vii) Significant fibrosis in the submucosal plane should be noted. This may represent a benign cause such as prolapse, may be an intrinsic feature of a nongranular LNPCP, or may represent evidence of submucosal invasion [9].

Level of agreement 94%.

(viii) It should be recognized that no feature (other than bleeding vessels) of the submucosa of the defect has been shown to predict important outcomes after EMR [104].

Level of agreement 90%.

(ix) The muscularis propria should be inspected if visible and described using the Sydney classification of deep mural injury (DMI) [57] (► Fig. 2, images D7–D9).

Level of agreement 90%.

(x) Topical application of the injectate (containing a chromic dye) can be helpful for areas of the defect where there is uncertainty as to the presence of muscularis propria injury (► Fig. 2,

images D7 and D8). If the defect stains blue, this area represents submucosa and the muscularis propria is uninjured [102, 103]. Level of agreement 90%.

(xi) Any areas suspicious or uncertain for injury to the muscularis propria (DMI types II–V) (► Fig. 2, images D8 and D9) should be closed with an endoscopic closure method (► Fig. 2, image D10), as described in the statement regarding intra-procedural perforation [57].

Level of agreement 95%.

(xii) Use of a transparent distal colonoscope attachment can be helpful to fully visualize a mucosal defect over a fold or at a flexure.

Level of agreement 88%.

(xiii) Photodocumentation of all areas of the post-EMR defect helps to assess completeness of resection (► Fig. 2, image D1) and facilitates learning if an adverse event occurs later. It may also be useful for medicolegal purposes.

Level of agreement 92%.

23 APPLICATION OF THERMAL ENERGY TO THE DEFECT MARGIN

ESGE recommends the best practice technique detailed below when applying thermal energy to the defect margin after EMR to reduce adenoma recurrence. Strong recommendation, high quality evidence.

(i) The technique for STSC of the post-EMR margin is as follows:

- extend the tip of the snare 2–3 mm beyond the catheter sheath
- use the scope and the snare tip as one device, do not move the catheter in and out of the channel
- apply pulses of soft coagulation using a light-touch technique to the margin of the defect, ideally over injected tissue
- aim for a rim of 2–3 mm of ablated tissue at the margin
- ensure that the margin is ablated around the full circumference without gaps.

Confirmation of the technique is visual identification of the white appearance of the mucosa after application (► Fig. 2, image A5).

Level of agreement 96%.

Comment Evidence from several randomized studies suggests that thermal ablation of the defect margin after EMR significantly reduces recurrence at first surveillance colonoscopy, by approximately 4-fold in expert hands [37]. Prospective observational studies [38] and meta-analyses [123, 124] have confirmed this finding.

24 ALTERNATIVE METHODS FOR REMOVAL OF NON-LIFTING RESIDUAL ADENOMATOUS TISSUE

ESGE recommends that, other than snare resection (EMR), the following techniques are alternative methods for removing non-lifting residual adenomatous tissue. Strong recommendation, moderate quality evidence.

(i) Cold avulsion (using a standard biopsy forceps), then thermal ablation using soft coagulation (ERBE effect 4, 80 W) to the avulsion bed using the snare tip. Non-lifting tissue should be completely removed prior to application of soft coagulation [9].

Level of agreement 84%.

Comment There are many other published techniques to manage residual adenomatous tissue. Such techniques include, but are not restricted to, hot avulsion [125], forced argon plasma coagulation [126], and more resource-intensive techniques, such as endoscopic submucosal dissection [127–129] or full-thickness resection [12]. These techniques are outside of the scope of this curriculum and are often not cost-effective in this situation.

4.3 Best practice for retrieval of polyp tissue after EMR

25 RETRIEVAL OF POLYP TISSUE

ESGE recommends the best practice technique described below for retrieval of polyp tissue after EMR. Weak recommendation, low quality evidence.

General statements

(i) Use of an endoscopic retrieval net is recommended when performing piecemeal polypectomy.

Level of agreement 92%.

(ii) If performing en bloc resection, the snare can be used to retrieve the resected polyp tissue.

Level of agreement 88%.

(iii) (If using a snare) care should be taken to ensure the snare does not cut through the lesion and that the scope is used to protect the specimen at retrieval through the anus by pulling the specimen up against the scope tip.

Level of agreement 86%.

(iv) Suction of transected tissue through the endoscope channel for retrieval may interfere with histologic interpretation.

Level of agreement 84%.

Technique of retrieval using an endoscopic retrieval net

(v) The retrieval device should be positioned at 6 o'clock (when using a colonoscope).

Level of agreement 89%.

(vi) Pieces should be captured using a sequential place, close, compact, and open approach.

Level of agreement 92%.

(vii) All pieces should be captured.

Level of agreement 94%.

(viii) Pinning the polyp tissue to a corkboard after en bloc resection is useful, but this is not useful after piecemeal resection (apart from when a large piece suspicious for SMI is resected). Level of agreement 88%.

4.4 Maximizing the chances of EMR success in difficult cases

26 STRATEGIES FOR DIFFICULT TO ACCESS LNPCPS

ESGE recommends that the strategies detailed below could be employed to facilitate access to the target LNPCP where this is difficult.

Moderately strong recommendation, low quality of evidence.

Patient factors

(i) Change patient position to respect the influence of gravity on fluid/blood (away from the lesion) and to optimize views.

Level of agreement 96%.

(ii) Optimize patient sedation.

Level of agreement 94%.

(iii) Administration of antispasmodics.

Level of agreement 93%.

Insertion challenges

(iv) Excellent basic colonoscopy technique to arrive at the lesion without looping.

Level of agreement 96%.

(v) Use of external pressure to prevent loop formation during insertion.

Level of agreement 86%.

(vi) Use of different endoscopes with different lengths, stiffness, and tip-bending properties etc. (e.g. pediatric colonoscopy, gastroscope, balloon-enteroscopy).

Level of agreement 93%.

Poor stability of the endoscope tip

(vii) Ask assistant/nurse to hold the endoscope as needed.

Level of agreement 90%.

(viii) Position the lesion at 5–6 o'clock.

Level of agreement 94%.

(ix) Use retroflexion where possible and appropriate.

Level of agreement 91%.

(x) Use luminal insufflation and desufflation.

Level of agreement 94%.

Difficult access

(xi) Use of a transparent distal attachment (e.g. for flexures, ileocecal valve, or dentate line).

Level of agreement 91%.

Polyp characteristics: inadequate lifting or poor snare capture

(xii) Resection technique: commence resection in a way that facilitates access to the most difficult part of the lesion early in the procedure to optimize the chance of complete resection.

Level of agreement 85%.

(xiii) Resection technique: use submucosal lifting to promote access to the required part of the lesion.

Level of agreement 94%.

(xiv) Resection technique: use snare resection of the surrounding lifting mucosa to create a step for snare placement on difficult-to-capture tissue.

Level of agreement 92%.

(xv) Resection technique: create a step into the submucosal plane to assist snare placement (hybrid-EMR).

Level of agreement 85%.

(xvi) Resection technique: use an avulsion technique such as cold avulsion.

Level of agreement 85%.

Suboptimal or incorrect technique

(xvii) Consider asking for a second opinion from a more experienced colleague at the time or before a second attempt. Consider that you may not be the best person to perform the second attempt.

Level of agreement 95%.

(xviii) Try a second attempt at EMR prior to surgery (two-stage EMR) [10].

Level of agreement 85%.

Several factors can result in a polypectomy being regarded as "difficult." These can be divided into the following seven categories.

Patient factors

In addition to compliance, the subsequent quality of the bowel preparation may also be affected by patient medication or underlying medical conditions that can affect GI motility. Poor cognition, obesity, or decreased mobility can limit patient movements. This may also adversely impact on the decision regarding when to turn a patient to facilitate reaching or optimizing access to an LNPCP. This may result in a slower and more challenging resection. Bowel motility and spasm can impair insertion, but also visualization and access.

Insertion challenges

An endoscopist must first be able to reach the LNPCP before resection can be attempted. Insertion challenges can result from: fixed segments of colon; long mobile colons with complex loop formation; patients with a hypersensitive colon and poor tolerance of any distension or colonic stretch stimulation; or previous abdominal/pelvic surgery. A range of endoscopic instruments may help mitigate some of these problems (e.g. a slimmer flexible instrument in a fixed or narrowed colon, a stiffer or longer scope in redundant loopy colons). The underwater insertion technique is another option for improving successful intubation, helping to reduce distension and patient discomfort, improving control of loops and improving lubrication.

Poor stability of the endoscope tip

During resection of an LNPCP, tip control is a key requirement to ensure safe effective resection. The colonic mucosa should be pleated over the colonoscope to enable a short and stable position. Ideally the patient should be positioned so that gravity does not adversely affect stability, whilst maintaining an optimal view of the lesion or resection field. Endoscopists must employ optimal basic colonoscopy technique during insertion

to reach the lesion, to minimize any potential problems with tip control during the resection. Assistance may be needed in difficult situations.

Difficult access

LNPCPs can occur anywhere in the colon. Difficult access is associated with flexures, folds, the ileocecal valve, terminal ileum, or being located in the orifices of the appendix or a diverticulum. Changing the patient's position (often multiple times) or using a distal tip attachment may help improve access to the lesion. Some lesions may be best visualized or resected in part or entirely in a retroverted view.

Inadequate lifting or poor snare capture

The presence of fibrosis secondary to disease or previous intervention can increase the difficulty of resection. Pre-resection biopsy can also contribute to submucosal fibrosis [130]). Additionally, the presence of submucosal fat can add to the technical challenges of resection in the submucosal plane. This is particularly noticeable for lesions in the right colon, around the ileocecal valve.

Polyp characteristics

Specific types of LNPCPs can have an increased association with fibrosis, in particular nongranular LNPCPs [9]. A larger exophytic component of a lesion is associated with an increased size in feeding vessels. The distal rectum is also a highly vascular area and increased care to ensure hemostasis during resection is needed for polyps in this location.

Suboptimal or incorrect technique

Resection technique needs to ensure safety, with resection being oriented through the submucosal plane and parallel to the underlying muscular propria. If there is inadequate lifting or poor orientation, the risk of damage to the muscular propria increases. Incorrect electrosurgical energy application can result in a risk of immediate or delayed perforation and/or bleeding. To ensure complete resection, a normal cuff of mucosa should be removed with the edge of the lesion and any tissue bridges should be avoided. Adjuvant post-resection techniques should be employed, where appropriate, to reduce the potential for complications, including recurrence.

27 STRATEGIES FOR EMR IN SPECIFIC LOCATIONS

ESGE recommends the strategies or maneuvers described below be used to assist in EMR of lesions in specific locations.

Strong recommendation, moderate quality of evidence.

(i) The position of the patient is critical, using gravity to maximize the luminal view and access to the lesion. Consider the right lateral position for lesions in the sigmoid, descending colon, splenic flexure, and cecal pole; the left lateral position for lesions in the hepatic flexure and ascending colon; the supine position for lesions in the transverse colon; and the prone posi-

tion if other positions are difficult in a patient with a long redundant colon, particularly for lesions in the rectosigmoid [131].

Level of agreement 88%.

(ii) Ileocecal valve: use a distal attachment. Assess the lesion carefully prior to resection. Be aware that risk factors for failed endoscopic resection are: deep ingrowth into the ileum and circumferential involvement of the ileocecal valve lips. Start by using dynamic injection to encourage the ileal margin of the lesion into the colonic lumen. Start resection from this margin. A small stiff snare often helps at this location [132].

Level of agreement 92%.

(iii) Appendiceal orifice: lesion assessment is critical. Risk factors for failure of endoscopic resection include invasion of the lesion beyond the endoscopic view into the appendiceal orifice and >50% circumferential involvement of the appendiceal orifice. A small stiff snare often helps in this location [34], as may use of the underwater technique [133].

Level of agreement 92%.

(iv) Rectosigmoid: consider use of a gastroscope, which will offer the ability for retroflexion.

Level of agreement 92%.

(v) Flexures: use of distal attachments may help.

Level of agreement 93%.

(vi) Anorectal junction: use a distal attachment. Use a small snare to commence resection at the anal verge, allowing expansion of the mucosal defect into the rectum and facilitating further resection. Use local anesthetic as part of the injectate in this area to provide analgesia after the procedure [92, 134].

Level of agreement 91%.

4.5 Training aspects related to EMR procedures

28 DETERMINING WHETHER EMR PROCEDURES SHOULD BE TAKEN OVER BY THE SUPERVISING PRACTITIONER

ESGE recommends the criteria listed below should be considered when determining when/if trainee EMR procedures should be taken over by their supervising practitioner.

Best practice recommendation, low quality evidence.

The following statements assume the supervisor has insight into the trainee's knowledge and skills. It may be very difficult to apply this approach for a trainee not known to the trainer.

Global factors

(i) Trainee is unable to carry out the instructions of the trainer despite comprehending them.

Level of agreement 95%.

(ii) Lack of adequate progress due to any reason relevant to the level of training or competency.

Level of agreement 94%.

Patient factors

(iii) Patient withdraws consent for a training procedure to be performed.

Level of agreement 90%.

(iv) Patient is in significant discomfort and this is thought to be due to the involvement of a trainee.

Level of agreement 93%.

(v) Patient becomes medically unstable.

Level of agreement 94%.

Technical factors

(vi) Suspicion of area(s) of SMI within the lesion for EMR, which are deemed not to have been sufficiently/adequately interrogated prior to the EMR or by the trainee, and/or where a precise en bloc resection is required that may not be achievable by the trainee.

Level of agreement 95%.

(vii) Unstable colonoscope position, with the trainee not able to maintain the optimal position on the lesion for snare placement (5–6 o'clock) despite input from the trainer.

Level of agreement 94%.

(viii) Trainee unable to obtain adequate submucosal lift.

Level of agreement 93%.

(ix) Trainee repeatedly cold snares the target lesion or resections lead only to superficial scraping of polyp tissue and incomplete excision of the mucosal layer.

Level of agreement 94%.

Adverse events

(x) Severe intraprocedural bleeding if the trainee is not competent/able to address this.

Level of agreement 94%.

(xi) Perforation if the trainee is not competent/able to address this.

Level of agreement 95%.

(xii) Trainee requests that the supervisor takes over the procedure.

Level of agreement 92%.

Time pressure

(xiii) Time constraints – when the endoscopy procedure, program, or unit is running significantly behind schedule, and the training episode is likely to be contributing to this.

Level of agreement 96%.

Comment Safe and complete LNPCP resection will increase the duration of a procedure. Even if the LNPCP resection is the only planned activity, adequate time is necessary to both enable the resection to be completed and to deal with any associated problems or complications. The allocation of time for procedures can be complex, and will be influenced by the experience of the endoscopist, the other factors listed above, and whether the case is being used for training purposes. Failure of the system to ensure the patient arrives promptly, with the correct bowel preparation administered, and that the correct time has been allocated will have an impact on the procedure. Time pressure is perceived differently between individuals; however, time pressure generally impairs performance because it places constraints on the capacity for thought and action that limit exploration and increases reliance on well-learned or heuristic strategies. The resulting time pressure increases speed at the expense of quality. The outcome of this can be incomplete resection, or a suboptimal technique with a higher likelihood of recurrence or complications.

4.6 Techniques to manage adverse events related to EMR

29 MANAGEMENT OF INTRAPROCEDURAL BLEEDING

ESGE recommends the best practice technique described below for the management of intraprocedural bleeding during EMR.

Best practice recommendation, low quality evidence.

(i) Use the endoscope flushing pump to identify the exact place where bleeding is occurring within the mucosal defect.

Level of agreement 95%.

(ii) Re-injection may help to isolate/make the bleeding vessel visible.

Level of agreement 90%.

(iii) Consider the use of image-enhancement techniques (e.g. red dichromatic imaging [RDI] [135, 136]) to identify the bleeding vessel.

Level of agreement 83%.

(iv) Ensure the patient position is optimal so that blood flows away from the resection site to improve visualization (use gravity).

Level of agreement 93%.

(v) If significant bleeding occurs, tamponade of the vessel with the endoscope cap or any instrument may be useful until the required device is available and may help to identify the source of bleeding.

Level of agreement 95%.

(vi) For mild/moderate bleeding, start with STSC [137] (e.g. ERBE soft coagulation effect 4, 80W). The technique is as follows:

- use the tip of the snare to apply light pressure precisely over the bleeding point (confirmed by cessation of bleeding)
- apply electrosurgical energy for 1–2 seconds, then lift the snare and re-assess bleeding.

Level of agreement 91%.

(vii) If STSC is ineffective after application of the correctly applied technique (as above), switch instrument to a coagulation forceps.

Level of agreement 87%.

(viii) For severe bleeding, start with a coagulation forceps.

Level of agreement 92%.

(ix) Use of the coagulation forceps should proceed as follows:

- the suspected vessel is captured with the forceps
- cessation of bleeding confirms correct forceps placement
- the vessel is then gently tented away from the deeper structures and electrosurgical energy is applied (using the same settings for the electrosurgical unit as for STSC [e.g. ERBE soft coagulation effect 4, 80W]) until a visible cautery effect is observed
- the tissue is released and the endoscope flushing pump is used to confirm cessation of bleeding.

Level of agreement 94%.

(x) In exceptional circumstances, where thermal energy does not control intraprocedural bleeding, mechanical control with

clips may be required. This may however interfere with progression of the resection. A clip should be closed on a site of bleeding and only fired if cessation of bleeding is confirmed. Level of agreement 91%.

(xi) Consider the use of a topical hemostatic agent [138] if there is diffuse intraprocedural bleeding that cannot be controlled using the other methods discussed.

Level of agreement 86%.

(xii) The injection of adrenaline (1:10 000) may reduce the rate of bleeding in difficult circumstances.

Level of agreement 87%.

30 MANAGEMENT OF INTRAPROCEDURAL PERFORATION

ESGE recommends the best practice technique described below for the management of intraprocedural perforation.

Best practice recommendation, low quality evidence.

(i) The suspected perforation should be classified according to the Sydney DMI score [57]. DMI types II–V should be closed endoscopically.

Level of agreement 95%.

(ii) The endoscopist should first consider completing the resection, or at least clear the polyp tissue surrounding the perforation, if it is safe/appropriate to do so.

Level of agreement 95%.

(iii) In the context of an observed DMI type IV or V with abdominal distension and patient instability, a 16G or larger bore needle should be inserted into the peritoneum to decompress a capnoperitoneum [139].

Level of agreement 83%.

(iv) The safety and appropriateness of completing the resection (prior to managing the perforation) depends on: the bowel preparation, competence of the endoscopist, size of the perforation, stage of the resection, whether peritoneal contamination is imminent, and patient stability.

Level of agreement 95%.

(v) Through-the-scope (TTS) endoscopic clips should be the first-line choice to close a perforation during EMR.

Level of agreement 95%.

(vi) Clip placement should consider the effect of gravity. Start on the same side of the wound as the fluid pool, so the clip stem falls away from the wound, allowing further clip placement. Start on an area of normal tissue if possible (not directly on the perforation) and proceed along the axis of the perforation to achieve a zipper-type closure.

Level of agreement 96%.

(vii) Maximum tissue capture with TTS clipping can be achieved using rotation of the clip shaft and suction of luminal gas prior to closure.

Level of agreement 95%.

(viii) If at this point, closure is not possible consider consulting a more experienced colleague/trainer if possible.

Level of agreement 89%.

(ix) If closure is not possible using TTS endoscopic clips, other techniques available include: over-the-scope (OTS) clips, nylon poly-loop plus clips, or endoscopic suturing. These techniques are outside the remit of this competency framework.

Level of agreement 92%.

(x) Administer intravenous antibiotics in the case of intraprocedural perforation, considering any medication allergies/interactions.

Level of agreement 92%.

(xi) Post-procedure, consider a computed tomography (CT) scan if there is persistent pain despite intravenous analgesia following the procedure.

Level of agreement 82%.

(xii) Post-procedure, consider review by a surgeon. Base the need for referral to surgery on the degree of observed fecal contamination, presence/absence of persistent post-procedural pain, and CT scan appearances.

Level of agreement 92%.

31 MANAGEMENT OF POST-EMR BLEEDING

ESGE recommends the measures given in the list below be considered best practice management of clinically significant post-EMR bleeding.

Strong recommendation, moderate quality evidence.

(i) Pre-intervention: resuscitation of patient with fluids and blood products if required.

Level of agreement 96%.

(ii) Pre-intervention: address any coagulopathy.

Level of agreement 96%.

(iii) Pre-intervention: perform close monitoring after initial resuscitation.

Level of agreement 96%.

(iv) Decision for intervention: use the frequency of hematochezia, American Society of Anesthesiologists (ASA) score, and need for transfusion as a guide to which patients require repeat colonoscopy and hemostatic measures [140]. Most patients do not require re-intervention.

Level of agreement 96%.

Procedural techniques after a decision to intervene

(v) Locate the resection defect and use the endoscope flushing pump to irrigate it.

Level of agreement 96%.

(vi) There is usually a single large vessel responsible for delayed bleeding after EMR. This vessel is often identified by an adherent clot. Any clot adherent to the defect after EMR should be removed using a cold snare and therapy should be directed at the underlying vessel.

Level of agreement 96%.

(vii) Hemostatic forceps should be used following the above technique to cauterize the causative vessel. The technique is described in Recommendation 29 (ix).

Level of agreement 93%.

(viii) Clips can be placed as primary therapy but are often more useful as security after control is achieved using coagulation forceps.

Level of agreement 95%.

(ix) A topical hemostatic agent can be useful, but is often only a temporary measure to control bleeding.

Level of agreement 90%.

(x) In rare cases, where endoscopic therapy fails, consider interventional radiology [141] as the next step. Leaving a clip on/near the causative vessel may allow the radiologist to visualize the causative vessel more easily in this situation.

Level of agreement 96%.

(xi) If endoscopic therapy fails and interventional radiology either fails or is unavailable, consider surgery.

Level of agreement 96%.

5 After EMR

32 ALARM FEATURES SUGGESTING AN ADVERSE EVENT POST-EMR

ESGE recommends that the symptoms/signs in the following list be considered alarm features post-EMR suggesting an adverse event relating to the procedure.

Best practice recommendation, low quality evidence.

(i) Persistent abdominal pain despite simple analgesics [142, 143].

Level of agreement 97%.

(ii) Persistent abdominal distension associated with abdominal pain.

Level of agreement 96%.

(iii) Hemodynamic instability/shock (fever, tachycardia, hypoxia etc.).

Level of agreement 97%.

(iv) Peritonism on clinical examination.

Level of agreement 97%.

(v) Persistent large-volume rectal bleeding.

Level of agreement 97%.

33 POST-PROCEDURE DISCUSSION WITH PATIENTS

ESGE recommends the topics given in the following list (representing the minimum content for a competent practitioner to achieve a safe discharge of the patient into the community) should be covered with a patient in the post-EMR conversation.

Best practice recommendation, low quality evidence.

(i) Give information about which adverse events could still occur after the procedure (bleeding, serositis, delayed perforation).

Level of agreement 96%.

(ii) The criteria for seeking medical attention should be discussed with the patient. As a minimum, the patient should be in-

structed to seek medical attention (perhaps at the institution where the resection was performed, with specific contact details given) if they experience: persistent abdominal pain that does not respond to simple analgesics; frequent hematochezia, with an explicit threshold regarding when to seek medical attention (perhaps blood in the stool every 30 minutes or less).

Level of agreement 94%.

(iii) Give an explanation about post-procedural diet. After standard EMR, this could be clear fluids overnight and standard diet the day after, but this should be modified depending on the complexity and radicality of the procedure.

Level of agreement 87%.

(iv) Individualized advice should be given about the timing of restarting antiplatelet/anticoagulant medication based on the published evidence and in consultation with the prescribing specialists.

Level of agreement 96%.

(v) A follow-up plan to discuss pathology results and potential outcomes should be made. Discuss the expected time until histopathology results are known.

Level of agreement 96%.

(vi) The need for surveillance colonoscopy based on the size and histology should be estimated. It should be explained that this will be confirmed once the histopathology results are known.

Level of agreement 93%.

(vii) If the colonoscopy identifies malignancy, an LNCP in a young patient, or a suspicion of a hereditary syndrome, screening of family members following established guidelines should be recommended [144].

Level of agreement 93%.

(viii) If the procedure was not completed, the reasons why and the next steps in management should be discussed.

Level of agreement 96%.

(ix) The importance of not travelling to remote areas (without access to emergency medical care) for a minimum of 14 days should be discussed.

Level of agreement 83%.

34 SITUATIONS REQUIRING ADMISSION TO HOSPITAL

ESGE recommends consideration of admission to hospital immediately after EMR in the situations given in the following list.

Best practice recommendation, low quality evidence.

(i) A highly co-morbid patient.

Level of agreement 88%.

(ii) A patient who is elderly and/or lives alone without support (especially if sedation has been used).

Level of agreement 93%.

(iii) A patient requiring early re-introduction of anticoagulation (e.g. metal mitral valve).

Level of agreement 83%.

(iv) Intraprocedural perforation with observed fecal peritoneal contamination or incomplete confidence of closure.

Level of agreement 96%.

(v) Significant periprocedural bleeding, even if controlled.

Level of agreement 96%.

(vi) Abdominal pain that does not resolve with simple analgesics (e.g. intravenous paracetamol).

Level of agreement 95%.

(vii) Unexplained fever/tachycardia.

Level of agreement 95%.

6 Surveillance procedures after EMR

35 ESSENTIAL FEATURES DURING SURVEILLANCE COLONOSCOPY

After endoscopic resection, ESGE recommends the features detailed in the following list should be confirmed and documented during a surveillance colonoscopy. Strong recommendation, high quality evidence.

(i) Assessment of quality of bowel preparation.

Level of agreement 95%.

(ii) Completeness of the colonoscopy.

Level of agreement 96%.

(iii) Recognition of the EMR scar, extensive imaging (high definition, virtual chromoendoscopy, +/- chromoendoscopy, near-focus/magnification) and photodocumentation [87, 145].

Level of agreement 95%.

(iv) Presence of any residual or recurrent adenoma recognized by a transition in pit/vascular pattern (e.g. NICE I to NICE II; Kudo I to Kudo III/IV) (► Fig. 3).

Level of agreement 96%.

(v) The presence of clip artifact [146, 147]. Recognize that clip artifact itself does not need treatment, but, where there is doubt, treatment is safe and prevents unnecessary further procedures for patients.

Level of agreement 96%.

(vi) Targeted biopsies and endoscopic treatment of any potential residual or recurrent adenoma should be performed.

Level of agreement 96%.

(vii) Additional polyps/LNPCPs should be noted and removed if feasible or a plan for their removal made.

Level of agreement 99%.

(viii) Need/timing for further surveillance [58].

Level of agreement 93%.

36 TREATMENT OF LNPCP RECURRENCE AT AN EMR SCAR

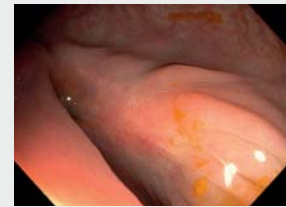
ESGE recommends the techniques in the following list be considered best practice for the treatment of LNPCP recurrence at an EMR scar.

Trainees should aspire to develop competency in these techniques to treat adenoma recurrence.

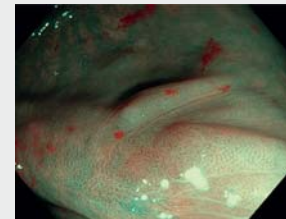
Best practice recommendation, low quality evidence.

Scar assessment after endoscopic mucosal resection

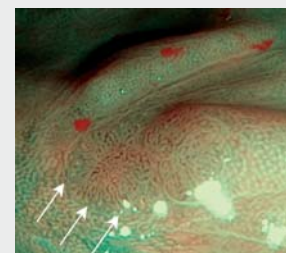
Interrogate the edges of the scar and work towards the center in high definition white light



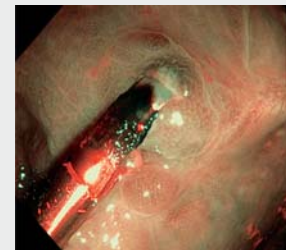
Repeat the same routine under virtual chromoendoscopy if available, apply optical zoom or magnification



Search for a transition point where a non-neoplastic vascular pattern changes to a neoplastic vascular pattern



Within a scar, raised areas where the original resection was clipped that do not have a neoplastic vascular pattern should be considered suspicious for clip artifact



► Fig. 3 Images showing a standardized approach to scar assessment after endoscopic mucosal resection.

Small (<5 mm) residual

(i) Cold or hot snare polypectomy.

Level of agreement 91%.

(ii) Cold avulsion (Recommendation 24) followed by STSC [9].

Level of agreement 88%.

(iii) Injecting a scar containing a small residual often creates a canyon effect and should therefore be avoided.

Level of agreement 83%.

Large (≥5 mm) residual

(iv) Standard injection and snare technique. This should be performed resecting a margin of normal tissue to isolate the central non-lifting component for snare resection. Consideration should be given to using an underwater technique [148].

Level of agreement 89%.

(v) Other techniques exist to treat residual or recurrent adenoma at an EMR scar (e.g. full-thickness resection, endoscopic submucosal dissection, hot avulsion, forced argon plasma coagulation, and underwater EMR [149]). They have not been

subjected to systematic controlled study in this context and are outside the scope of this competency framework (see also Recommendation 24).
Level of agreement 88%.

7 Completion of training: sign off and initial credentialing

37 COMPLETION OF TRAINING IN EMR

ESGE recommends the requirements detailed below for completion of training and initial credentialing in EMR.
Best practice recommendation, low quality evidence.

(i) At least 30 EMR procedures performed independently over a minimum period of 6 months are required. Beyond this, achievement of specific competencies (below), rather than procedure number, should determine whether an individual is deemed competent to perform EMR.

Level of agreement 83%.

(ii) It is not a requirement to achieve competency in all complexities of LNPCP to be able to perform any EMR.

Credentialing can perhaps provide a guide as to the ceiling of complexity that is appropriate for a given practitioner of EMR. In the absence of an evidence-based tool to assess a given EMR, the trainer should give an idea of the potential SMSA range that the trainee leaving training should attempt independently.

Level of agreement 89%.

(iii) Practicing endoscopists should avoid attempting LNPCPs outside their competency (SMSA score) unless within the context of a training scheme.

Level of agreement 91%.

(iv) Conversely, attempting EMR of an LNPCP one threshold above competency (SMSA score) within a structured training environment may be entirely appropriate to further the skills of the trainee.

Level of agreement 89%.

Comment We have included a tool to assess the quality of polypectomy in this document – the GPAT (► Table 4). The components of the GPAT that are mandatory depend on whether hot or cold snare polypectomy is being described. The score for each component can be between 1 and 5. Mandatory components are always included in the denominator; non-mandatory components only contribute to the denominator if scored. The GPAT is calculated alongside the SMSA and SMSA+ scores but does not include them in the calculation.

The GPAT score is generated as follows:

$$\frac{\text{total score for all components}}{(\text{number of components answered} \times 5)} \times 100\%$$

The GPAT is a work in progress. It will undergo prospective evaluation to ensure that it performs at least as well as the other instruments available.

Key benefits of the GPAT include:

- applicability to a video
- structured approach to feedback in polypectomy
- directly based upon the recommendations in this competency framework.

GPAT is associated with an online logbook that can be used to track progress in polypectomy. The online tool can be accessed at: www.gieqs.com/gpat-form.

7.1 Priorities for further research into credentialing and potential future statements to test in a research setting

The SMSA score is the best evidence-based tool available to assess the complexity of EMR; however, it does not assess the quality of a given polypectomy. Nor do other existing systems to assess polypectomy (e.g. DOPyS [150]) either: (i) allow objective assessment with good interobserver agreement amongst raters; (ii) provide the ability to assess and deconstruct a video after the event; (iii) provide an online portfolio to collect data and report outcomes; or (iv) provide an objective assessment of technique as per the latest evidence in this competency framework.

Therefore, we believe the future of credentialing lies in a tool that can reliably assess technique amongst raters. The GPAT was developed for this purpose. We have included research priorities based upon it below. We envisage updating this section, as required, as people start to use the score.

There are two potential future points for Recommendation 37. (v) A single specific GPAT threshold (yet to be determined) attained over a minimum of 30 procedures (considering only the last 3 months of data) should be obtained at the end of training and allows credentialing for all difficulties of EMR.

(vi) After a period of training where a specific GPAT threshold is obtained, a further training period may be undertaken (minimum 3 months, 30 procedures) in an attempt to augment the attained threshold. This should only be undertaken in the context of a training scheme (► Table 5).

8 Lifelong key performance indicators (quality assurance)

The following recommendations can also be used to assess the quality of an EMR service and should be available to patients should they request them. An online tool to prospectively collect these indicators is in development and will be attached here once it is available.

38 QUALITY INDICATORS OF EMR

Essential quality indicators of EMR that should be prospectively monitored, recorded, and acted upon if deficiencies are identified are those detailed in ► Table 6.
Strong recommendation, low quality evidence.

► **Table 4** Components of the Global Polypectomy Assessment Tool (GPAT).

Component	Possible responses and scoring		Mandatory		Recommendation number
			Hot snare	Cold snare	
Global competencies					
Tip control	1 Very poor	Uncontrolled, shaky, and undirected	x	x	None
	5 Very good	Controlled, stable and purposeful			
Fully appreciates/demonstrates extent of the polyp to be resected	1 Very poor	Focuses on one area, does not demonstrate appreciation of the entire polyp	x	x	3(i), 3(ii), 3(iii)
	5 Very good	Clearly appreciates entire extent of the polyp; approach and resection reflect this			
Positioning with respect to the polyp	1 Very poor	Lesion not at 6 o'clock, far from the colonoscope, fluid covering lesion (poor use of gravity)	x	x	17(iii), 20(iii)
	5 Very good	Lesion at or near 6 o'clock, close to the colonoscope, fluid lies away from lesion (good use of gravity)			
Technique selected is appropriate for the polyp resected	1 Very poor	No clear need for en bloc resection if selected, lesion unsuitable for cold snare, hot snare for polyp < 10 mm	x	x	4 [53]
	5 Very good	Correct decision for en bloc vs. piecemeal resection, hot vs. cold appropriate for the polyp			
Injection technique					
Injection is performed in the correct plane	1 Very poor	Injection infrequently results in sustained submucosal lifting (transmural / intramucosal injection)	x		16(iv), 16(v), 16(vi), 16(vii) (cold snare) 19(v), 19(vi), 19(vii), 19(viii) (hot snare)
	5 Very good	The submucosal plane is quickly found and injection rapidly results in sustained mucosal lifting (needle in submucosa)			
Injection is performed dynamically	1 Very poor	Once the needle is situated in the submucosa, there is no movement of the needle away from the muscularis toward the center of the lumen	x		16(iv) (cold snare) 19(v) (hot snare)
	5 Very good	Once the needle is in the submucosa, there is graduated movement of the needle away from the muscularis towards the center of the lumen			
Injection is used to improve lesion access	1 Very poor	Injection does not facilitate access to the target lesion	x		16(i), 16(viii) (cold snare) 19(i), 19(ii), 19(ix) (hot snare)
	5 Very good	Injection clearly facilitates access to the target lesion			
Snare placement technique					
Appropriate snare size/type selected	1 Very poor	Snare clearly too large/small and of incorrect type (thin wire vs. thick wire) for the polyp	x	x	17(i), 17(ii) 20(i), 20(ii)
	5 Very good	Snare of appropriate size and type for the polyp			
Stable position with lesion at 6 o'clock OR transformed to 6 o'clock	1 Very poor	Snare position is not consistently maintained at 6 o'clock and/or the position is unstable	x	x	17(iii) 20(iii)
	5 Very good	Snare position is consistently maintained at 6 o'clock and the position is stable			

► **Table 4** (Continuation)

Component	Possible responses and scoring		Mandatory		Recommendation number
			Hot snare	Cold snare	
Maximizing snare capture	1 Very poor	Poor capture of tissue/scrapes the surface of the polyp/no use of downward pressure/no use of gas aspiration/may result in incomplete mucosal layer excision	x	x	17(viii) 20(viii)
	5 Very good	Good capture of polyp tissue within snare/use of downward pressure/use of gas aspiration resulting in complete capture of adequate target tissue			
Snare precisely visualized during placement and closure (V of the snare)	1 Very poor	Snare V at intersection with snare catheter not visualized during closure and far from the colonoscope	x	x	17(vii), 17(ix), 17(x) 20(vii), 20(ix), 20(x), 20(xi)
	5 Very good	Snare V visualized consistently during closure and near to the colonoscope			
Residual tissue islands avoided if piecemeal resection or macroscopically complete if en bloc resection attempted	1 Very poor	Snare placement does not include normal margin (at edge) or does not use transected tissue edge (within lesion) as a guide resulting in tissue islands/incomplete en bloc resection	x	x	17(xxviii) 20(xxvii)
	5 Very good	Snare placement includes > 2–3 mm normal margin (at edge) of tissue or uses transected tissue edge as a guide (within defect) resulting in no tissue islands/complete en bloc			
Safety checks prior to resection (hot snare only)					
Moves the closed snare to confirm independent movement from deeper structures	1 Very poor	Does not check tissue mobility prior to transection with respect to deeper structures	x		20(xv), 20(xvi)
	5 Very good	Checks mobility prior to transection with respect to deeper structures			
Lifts the snare away from the muscularis propria prior to application of electro-surgical energy	1 Very poor	Does not lift the snare prior to applying electro-surgical energy	x		20(xx)
	5 Very good	Lifts the snare away from the muscularis prior to the application of electro-surgical energy			
Defect assessment after resection					
Mucosa: looks for, detects, and removes residual adenomatous tissue at margin and within defect	1 Very poor	Does not ostensibly and systematically check for residual adenomatous tissue at the defect margin or within the defect, and/or does not remove successfully	x	x	22(i), 22(ii), 22(iii), 22(iv)
	5 Very good	Ostensibly and systematically checks for residual adenomatous tissue within the defect and at the defect margin, and removes it successfully			
Thermal ablation of the post-EMR margin	1 Very poor	Unsteady application, results in areas of incomplete ablation, ablates visible polyp tissue, messy result			
	5 Very good	Steady systematic application, does not ablate visible polyp tissue, complete ablation of the entire margin achieved			
Submucosa: looks for, detects, and treats any bleeding vessels within the defect	1 Very poor	Neither detects nor treats bleeding vessels in submucosa; treats benign submucosal appearances	x		22(v), 22(vi), 22(vii), 22(viii)
	5 Very good	Detects and treats bleeding vessels in the submucosa; does not treat other submucosal appearances including herniating vessels			

► **Table 4** (Continuation)

Component	Possible responses and scoring		Mandatory		Recommendation number
			Hot snare	Cold snare	
Muscularis: looks for, detects, and treats deep mural injury \geq II (Sydney classification)	1 Very poor	Misses signs of deep mural injury (types II–V) which require clip closure	x		22(ix), 22(x), 22(xi)
	5 Very good	Detects and treats types II–V deep mural injury or confirms they are not present			
Accessory techniques in polypectomy					
Placement of through-the-scope clips	1 Very poor	Poor tissue capture, poor use of suction and positioning to maximize correct orientation and amount of tissue captured			29(x) 30(iv), 30(v), 30(vi)
	5 Very good	Good use of suction, positioning, and rotation to capture required tissue and achieves secure appearing closure			
Use of polyp retrieval device	1 Very poor	Poor positioning, does not capture all pieces, does not use sequential place and retrieve technique			25(i)
	5 Very good	6 o'clock position, sequential place and retrieve technique applied, captures all pieces successfully			
Use of coagulation grasper	1 Very poor	Does not use water, does not wait for cessation of bleeding after forceps closure prior to application of electro-surgical energy, does not tent vessel away from the muscularis to apply electro-surgical energy			29(ix)
	5 Very good	Uses water to identify the causative vessel, confirms correct placement with cessation of bleeding after closure, tents vessel away from the muscularis to apply electro-surgical energy			

► **Table 5** Possible conversion of GPAT thresholds to SMSA scores for increasing difficulty of polypectomy, allowing for potential accreditation of specific difficulties of polypectomy.

Possible GPAT threshold for accreditation ¹	SMSA score
0.13 (0–0.25)	2
0.38 (0.26–0.5)	3
0.63 (0.51–0.75)	4
0.88 (0.76–1.0)	+

GPAT, Global Polypectomy Assessment Tool; SMSA, size, morphology, site, and access.

¹ These numbers need further validation in large-scale prospective study. Minimum of 30 procedures required.

Disclaimer

ESGE Position Statements represent a consensus of best practice based on the available evidence at the time of preparation. This is NOT a guideline but a proposal for training in EMR. The statements may not apply in all situations and should be interpreted in the light of specific clinical situations and resource availability. Further controlled clinical studies may be needed to clarify aspects of these statements, and revision may be nec-

essary as new data appear. Clinical considerations may justify a course of action at variance with these recommendations. This ESGE Position Statement is intended to be an educational device to provide information that may assist endoscopists in providing care to patients. The recommendations are not rules and should not be construed as establishing a legal standard of care or as encouraging, advocating, requiring, or discouraging any particular treatment. The legal disclaimer for ESGE guidelines applies to the present position statement.

Acknowledgments

The authors would like to thank the additional experts who contributed to the original Delphi consensus for their expertise and input. These experts were Drs. Gregor Brown, Spiro Raftopoulos, Rajvinder Singh, Paul Fockens, Evelien Dekker, Maria Pellise, John Anderson, Brian Saunders, Sachin Wani, and Sunil Dolwani. The authors would also like to thank Dr. Daniel Wheatley for his categorization of the original Delphi responses, Dr. Nika Dewilde for her assistance with the same, and Drs. Lynn Debels and Sander Smeets for their assistance with referencing and manuscript preparation.

► **Table 6** Essential quality indicators of EMR that should be prospectively monitored, recorded, and acted upon if deficiencies are identified.

Recommendation 38	Origin	Origin data, % (95%CI)	Desired standard ¹	Minimum standard	Consensus ²
(i) Practitioners of EMR should be aware of their own outcomes and follow them up	Delphi	–	–	–	90%
(ii) Number of procedures performed independently per year (lesions ≥ 20 mm)	Delphi	–	70 procedures	–	86%
(iii) Pre-procedure: Clear documentation of patient consent discussion re: risks, benefits, and alternatives (see recommendation 10)	Delphi	–	95%	90%	90%
(iv) LNPCP attempted for EMR (vs. those deemed endoscopically unresectable for technical reasons or due to risk of submucosal invasion)	iACE	94.6% (93.9%–95.2%)	95%	90%	82%
(v) LNPCP successfully resected in a single session using EMR	iACE	91.4% (90.6%–92.2%)	91%	86%	89%
(vi) Rate of intraprocedural bleeding	iACE	13.6% (12.5%–14.7%)	14%	19%	83%
(vii) Rate of intraprocedural perforation	iACE	3.3% (2.7%–3.9%)	3.5%	5%	85%
(viii) Rate of complete perforation closure	Delphi	–	95%	90%	88%
(ix) Rate of clinically significant post-EMR bleeding	iACE	5.9% (5.3%–6.6%)	6.0%	8.5%	88%
(x) Rate of delayed perforation	iACE	0.7% (0.48%–0.94%)	1.0%	1.5%	89%
(xi) Rate of unplanned hospitalization/readmission	iACE	3.0% (2.6%–3.5%)	3.0%	4.5%	89%
(xii) Rate of surgery for incomplete EMR, adverse event, or malignant histology (patient does not enter surveillance)	iACE	4.1% (3.6%–4.7%)	4.1%	6.2%	81%
(xiii) Patients returning for surveillance examinations	Delphi	–	90%	80%	90%
(xiv) Rate of adenoma recurrence at first surveillance (endoscopically determined), overall	iACE	13.9% (12.2%–15.7%)	14%	16%	80%
(xv) Rate of adenoma recurrence at first surveillance (endoscopically determined), if complete thermal ablation used at index procedure [38]	iACE	1.4% (0.8%–2.6%)	1.5%	2.6%	89%
(xvi) Rate of adenoma recurrence able to be treated endoscopically	iACE	96.0% (92.4%–98.0%)	96%	92%	88%
(xvii) Rate of surgery for inability to resect recurrence	iACE	1.2% (0.3%–4.4%)	1.2%	4.4%	79%
(xviii) Patient satisfaction recorded including comfort scores	Delphi	–	90%	80%	81%

EMR, endoscopic mucosal resection; iACE, international ACE study³.

¹ Desired standard is based on the published expert rate (iACE) data or the Delphi consensus if not available; it refers to the minimum standard or a modification of the iACE standard agreed by Delphi consensus.

² Consensus refers to the agreement on the described statement during the voting rounds that led to this position statement.

³ The international ACE study refers to a prospective database of >5000 EMR procedures, which is the largest study in colonic EMR [4]; it is based in Australia but now includes four international centers. Data are correct as of 18 October 2021.

Competing Interests

P. Bhandari's department received research grants from Boston Scientific (2021) and Fujifilm (2018). R. Bisschops has received grants/research support, and speaker's fees/honoraria from Pentax, Fujifilm, Medtronic, Cook, and Boston Scientific (2019 to present). D.J. Tate has received financial support from Olympus for research support (2019 to present). J. Anderson, M.E. Argenziano, I. Boškoski, M.J. Bourke, M. Bugajski, L. Desomer, S.J. Heitman, H. Kashida, V. Kriazhov, R.R.T. Lee, I. Lyutakov, P. Pimentel-Nunes, L. Rivero-Sánchez, T. C. Tham, S. Thomas-Gibson, H. Thorlacius declare that they have no conflict of interest.

References

- [1] Deyhle P, Jenny S, Fumagalli I. [Endoscopic polypectomy in the proximal colon. A diagnostic, therapeutic (and preventive?) intervention]. *Dtsch Med Wochenschr* 1973; 98: 219–220
- [2] Tada M, Karita M, Yanai H et al. [Endoscopic therapy of early gastric cancer by strip biopsy]. *Gan To Kagaku Ryoho* 1988; 15: 1460–1465
- [3] Bourke MJ. Endoscopic resection for mucosal neoplasia: Pushing the boundaries, confronting the reality. *J Gastroenterol Hepatol* 2011; 26: 1582–1584
- [4] Moss A, Bourke MJ, Williams SJ et al. Endoscopic mucosal resection outcomes and prediction of submucosal cancer from advanced colonic mucosal neoplasia. *Gastroenterology* 2011; 140: 1909–1918
- [5] van Hattem WA, Shahidi N, Vosko S et al. Piecemeal cold snare polypectomy versus conventional endoscopic mucosal resection for large sessile serrated lesions: a retrospective comparison across two successive periods. *Gut* 2021; 70: 1691–1697
- [6] Moss A, Williams SJ, Hourigan LF et al. Long-term adenoma recurrence following wide-field endoscopic mucosal resection (WF-EMR) for advanced colonic mucosal neoplasia is infrequent: results and risk factors in 1000 cases from the Australian Colonic EMR (ACE) study. *Gut* 2015; 64: 57–65
- [7] Jayanna M, Burgess NG, Singh R et al. Cost analysis of endoscopic mucosal resection vs surgery for large laterally spreading colorectal lesions. *Clin Gastroenterol Hepatol* 2016; 14: 271–272
- [8] Ahlenstiel G, Hourigan LF, Brown G et al. Actual endoscopic versus predicted surgical mortality for treatment of advanced mucosal neoplasia of the colon. *Gastrointest Endosc* 2014; 80: 668–676
- [9] Tate DJ, Bahin FF, Desomer L et al. Cold-forceps avulsion with adjunct snare-tip soft coagulation (CAST) is an effective and safe strategy for the management of non-lifting large laterally spreading colonic lesions. *Endoscopy* 2018; 50: 52–62
- [10] Tate DJ, Desomer L, Hourigan LF et al. Two-stage endoscopic mucosal resection is a safe and effective salvage therapy after a failed single-session approach. *Endoscopy* 2017; 49: 888–898
- [11] Suzuki H, Oda I, Abe S et al. High rate of 5-year survival among patients with early gastric cancer undergoing curative endoscopic submucosal dissection. *Gastric Cancer* 2016; 19: 198–205
- [12] Zwager LW, Bastiaansen BAJ, Bronzwaer MES et al. Endoscopic full-thickness resection (eFTR) of colorectal lesions: Results from the Dutch colorectal eFTR registry. *Endoscopy* 2020; 52: 1014–1023
- [13] Lee R, Heitman SJ, Bourke MJ. Training and competency in endoscopic mucosal resection. *Tech Gastrointest Endosc* 2017; 19: 125–136
- [14] Dumonceau JM, Hassan C, Riphaus A et al. European Society of Gastrointestinal Endoscopy (ESGE) Guideline Development Policy. *Endoscopy* 2012; 44: 626–629
- [15] Bisschops R, Dekker E, East JE et al. European Society of Gastrointestinal Endoscopy (ESGE) curricula development for postgraduate training in advanced endoscopic procedures: rationale and methodology. *Endoscopy* 2019; 51: 976–979
- [16] Atkins D, Best D, Briss PA et al. Grading quality of evidence and strength of recommendations. *BMJ* 2004; 328: 1490
- [17] Gralnek IM, Stanley AJ, Morris AJ et al. Endoscopic diagnosis and management of nonvariceal upper gastrointestinal hemorrhage (NVUGIH): European Society of Gastrointestinal Endoscopy (ESGE) Guideline – Update 2021. *Endoscopy* 2021; 53: 300–332
- [18] Sidhu M, Tate DJ, Desomer L et al. The size, morphology, site, and access score predicts critical outcomes of endoscopic mucosal resection in the colon. *Endoscopy* 2018; 50: 684–692
- [19] Puig I, Mármol C, Bustamante M. Endoscopic imaging techniques for detecting early colorectal cancer. *Curr Opin Gastroenterol* 2019; 35: 432–439
- [20] da Costa-Seixas JP, López-Cerón M, Arnau A et al. Compound endoscopic morphological features for identifying non-pedunculated lesions ≥ 20 mm with intramucosal neoplasia. *Cancers (Basel)* 2021; 13: 5302
- [21] Matsuda T, Fujii T, Saito Y et al. Efficacy of the invasive/non-invasive pattern by magnifying chromoendoscopy to estimate the depth of invasion of early colorectal neoplasms. *Am J Gastroenterol* 2008; 103: 2700–2706
- [22] Hewett DG, Kaltenbach T, Sano Y et al. Validation of a simple classification system for endoscopic diagnosis of small colorectal polyps using narrow-band imaging. *Gastroenterology* 2012; 143: 599–607 e591
- [23] Hayashi N, Tanaka S, Hewett DG et al. Endoscopic prediction of deep submucosal invasive carcinoma: validation of the Narrow-Band Imaging International Colorectal Endoscopic (NICE) classification. *Gastrointest Endosc* 2013; 78: 625–632
- [24] Kobayashi S, Yamada M, Takamaru H et al. Diagnostic yield of the Japan NBI Expert Team (JNET) classification for endoscopic diagnosis of superficial colorectal neoplasms in a large-scale clinical practice database. *United European Gastroenterol J* 2019; 7: 914–923
- [25] Sano Y, Tanaka S, Kudo SE et al. Narrow-band imaging (NBI) magnifying endoscopic classification of colorectal tumors proposed by the Japan NBI Expert Team. *Dig Endosc* 2016; 28: 526–533
- [26] Kudo S, Hirota S, Nakajima T et al. Colorectal tumours and pit pattern. *J Clin Pathol* 1994; 47: 880–885
- [27] The Paris endoscopic classification of superficial neoplastic lesions: esophagus, stomach, and colon: November 30 to December 1, 2002. *Gastrointest Endosc* 2003; 58: S3–S43
- [28] Burgess NG, Hourigan LF, Zanati SA et al. Risk stratification for covert invasive cancer among patients referred for colonic endoscopic mucosal resection: a large multicenter cohort. *Gastroenterology* 2017; 153: 732–742.e731
- [29] Dekker E, Houwen B, Puig I et al. Curriculum for optical diagnosis training in Europe: European Society of Gastrointestinal Endoscopy (ESGE) Position Statement. *Endoscopy* 2020; 52: 899–923
- [30] Saito Y, Uraoka T, Yamaguchi Y et al. A prospective, multicenter study of 1111 colorectal endoscopic submucosal dissections (with video). *Gastrointest Endosc* 2010; 72: 1217–1225
- [31] Pimentel-Nunes P, Libânio D, Bastiaansen BAJ et al. Endoscopic submucosal dissection for superficial gastrointestinal lesions: European Society of Gastrointestinal Endoscopy (ESGE) Guideline – Update 2022. *Endoscopy* 2022; 54: 591–622
- [32] Tate DJ. GIEQs online: Risk of submucosal invasion calculator. Accessed: 30 March 2023 www.gieqs.com/smic
- [33] Bourke MJ, Neuhaus H, Bergman JJ. Endoscopic submucosal dissection: indications and application in Western endoscopy practice. *Gastroenterology* 2018; 154: 1887–1900.e1885
- [34] Tate DJ, Desomer L, Awadie H et al. EMR of laterally spreading lesions around or involving the appendiceal orifice: technique, risk

- factors for failure, and outcomes of a tertiary referral cohort (with video). *Gastrointest Endosc* 2018; 87: 1279–1288.e1272
- [35] Placek SB, Nelson J. Combined endoscopic laparoscopic surgery procedures for colorectal surgery. *Clin Colon Rectal Surg* 2017; 30: 145–150
- [36] Gupta S, Miskovic D, Bhandari P et al. A novel method for determining the difficulty of colonoscopic polypectomy. *Frontline Gastroenterol* 2013; 4: 244–248
- [37] Klein A, Tate DJ, Jayasekera V et al. Thermal ablation of mucosal defect margins reduces adenoma recurrence after colonic endoscopic mucosal resection. *Gastroenterology* 2019; 156: 604–613.e603
- [38] Sidhu M, Shahidi N, Gupta S et al. Outcomes of thermal ablation of the mucosal defect margin after endoscopic mucosal resection: a prospective, international, multicenter trial of 1000 large nonpedunculated colorectal polyps. *Gastroenterology* 2021; 161: 163–170.e163
- [39] Bassan MS, Holt B, Moss A et al. Carbon dioxide insufflation reduces number of postprocedure admissions after endoscopic resection of large colonic lesions: a prospective cohort study. *Gastrointest Endosc* 2013; 77: 90–95
- [40] Marín-Gabriel JC, Romito R, Guarner-Argente C et al. Use of electro-surgical units in the endoscopic resection of gastrointestinal tumors. *Gastroenterol Hepatol* 2019; 42: 512–523
- [41] Castro R, Libânio D, Pita I et al. Solutions for submucosal injection: What to choose and how to do it. *World J Gastroenterol* 2019; 25: 777–788
- [42] Moss A, Bourke MJ, Kwan V et al. Succinylated gelatin substantially increases en bloc resection size in colonic EMR: a randomized, blinded trial in a porcine model. *Gastrointest Endosc* 2010; 71: 589–595
- [43] Yandrapu H, Desai M, Siddique S et al. Normal saline solution versus other viscous solutions for submucosal injection during endoscopic mucosal resection: a systematic review and meta-analysis. *Gastrointest Endosc* 2017; 85: 693–699
- [44] Rivero-Sánchez L, Ortiz O, Pellisé M. Chromoendoscopy techniques in imaging of colorectal polyps and cancer: overview and practical applications for detection and characterization. *Tech Innov Gastrointest Endosc* 2021; 23: 30–41
- [45] Tate DJ, Bourke MJ. Advanced colorectal polyps and early cancer. Wallace MB, Fockens P, Sung JJ. *Gastroenterological Endoscopy*. Stuttgart: Thieme; 2018: 293–308
- [46] Medina-Prado L, Hassan C, Dekker E et al. When and how to use endoscopic tattooing in the colon: an international Delphi agreement. *Clin Gastroenterol Hepatol* 2021; 19: 1038–1050
- [47] Zawaly K, Rumbolt C, Abou-Setta AM et al. The efficacy of split-dose bowel preparations for polyp detection: a systematic review and meta-analysis. *Am J Gastroenterol* 2019; 114: 884–892
- [48] Rees CJ, Thomas Gibson S, Rutter MD et al. UK key performance indicators and quality assurance standards for colonoscopy. *Gut* 2016; 65: 1923–1929
- [49] Kastenberg D, Bertiger G, Brogadir S. Bowel preparation quality scales for colonoscopy. *World J Gastroenterol* 2018; 24: 2833–2843
- [50] Thuraisingam AI, Brown JL, Anderson JT. What are the sensitivity and specificity of endoscopic photographs in determining completion of colonoscopy? Results from an online questionnaire. *Eur J Gastroenterol Hepatol* 2008; 20: 567–571
- [51] Brown S, Bevan R, Rubin G et al. Patient-derived measures of GI endoscopy: a meta-narrative review of the literature. *Gastrointest Endosc* 2015; 81: 1130–1140.e1131-1139
- [52] Telford J, Tavakoli I, Takach O et al. Validation of the St. Paul's Endoscopy Comfort Scale (SPECS) for colonoscopy. *J Can Assoc Gastroenterol* 2020; 3: 91–95
- [53] Ferlitsch M, Moss A, Hassan C et al. Colorectal polypectomy and endoscopic mucosal resection (EMR): European Society of Gastrointestinal Endoscopy (ESGE) Clinical Guideline. *Endoscopy* 2017; 49: 270–297
- [54] Kudo SE, Kashida H. Flat and depressed lesions of the colorectum. *Clin Gastroenterol Hepatol* 2005; 3: S33–S36
- [55] Sharma P, Bergman JJGHM, Goda K et al. Development and validation of a classification system to identify high-grade dysplasia and esophageal adenocarcinoma in Barrett's esophagus using narrow-band imaging. *Gastroenterology* 2016; 150: 591–598
- [56] Moss A, Bourke MJ, Metz AJ. A randomized, double-blind trial of succinylated gelatin submucosal injection for endoscopic resection of large sessile polyps of the colon. *Am J Gastroenterol* 2010; 105: 2375–2382
- [57] Burgess NG, Bassan MS, McLeod D et al. Deep mural injury and perforation after colonic endoscopic mucosal resection: a new classification and analysis of risk factors. *Gut* 2017; 66: 1779–1789
- [58] Hassan C, Antonelli G, Dumonceau J-M et al. Post-polypectomy colonoscopy surveillance: European Society of Gastrointestinal Endoscopy (ESGE) Guideline – Update 2020. *Endoscopy* 2020; 52: 687–700
- [59] Mou S, Soetikno R, Shimoda T. Pathologic predictive factors for lymph node metastasis in submucosal invasive (T1) colorectal cancer: a systematic review and meta-analysis. *Surg Endosc* 2013; 27: 2692–2703
- [60] Beaton C, Twine CP, Williams GL et al. Systematic review and meta-analysis of histopathological factors influencing the risk of lymph node metastasis in early colorectal cancer. *Colorectal Dis* 2013; 15: 788–797
- [61] Wada H, Shiozawa M, Katayama K et al. Systematic review and meta-analysis of histopathological predictive factors for lymph node metastasis in T1 colorectal cancer. *J Gastroenterol* 2015; 50: 727–734
- [62] Nagtegaal ID, Odze RD, Klimstra D et al. The 2019 WHO classification of tumours of the digestive system. *Histopathology* 2020; 76: 182–188
- [63] Schlemper RJ, Riddell RH, Kato Y et al. The Vienna classification of gastrointestinal epithelial neoplasia. *Gut* 2000; 47: 251–255
- [64] Kitajima K, Fujimori T, Fujii S et al. Correlations between lymph node metastasis and depth of submucosal invasion in submucosal invasive colorectal carcinoma: a Japanese collaborative study. *J Gastroenterol* 2004; 39: 534–543
- [65] Watanabe T, Muro K, Ajioka Y et al. Japanese Society for Cancer of the Colon and Rectum (JSCCR) guidelines 2016 for the treatment of colorectal cancer. *Int J Clin Oncol* 2018; 23: 1–34
- [66] Ueno H, Mochizuki H, Hashiguchi Y et al. Risk factors for an adverse outcome in early invasive colorectal carcinoma. *Gastroenterology* 2004; 127: 385–394
- [67] Lugli A, Kirsch R, Ajioka Y et al. Recommendations for reporting tumor budding in colorectal cancer based on the International Tumor Budding Consensus Conference (ITBCC) 2016. *Mod Pathol* 2017; 30: 1299–1311
- [68] Kudo S. Endoscopic mucosal resection of flat and depressed types of early colorectal cancer. *Endoscopy* 1993; 25: 455–461
- [69] Kikuchi R, Takano M, Takagi K et al. Management of early invasive colorectal cancer. Risk of recurrence and clinical guidelines. *Dis Colon Rectum* 1995; 38: 1286–1295
- [70] Wood JJ, Metcalfe C, Paes A et al. An evaluation of treatment decisions at a colorectal cancer multi-disciplinary team. *Colorectal Dis* 2008; 10: 769–772
- [71] Vaughan-Shaw PG, Wheeler JM, Borley NR. The impact of a dedicated multidisciplinary team on the management of early rectal cancer. *Colorectal Dis* 2015; 17: 704–709

- [72] Rosander E, Holm T, Sjövall A et al. Preoperative multidisciplinary team assessment is associated with improved survival in patients with locally advanced colon cancer; a nationwide cohort study in 3157 patients. *Eur J Surg Oncol* 2021; 47: 2398–2404
- [73] Abukar AA, Ramsanahie A, Martin-Lumbard K et al. Availability and feasibility of structured, routine collection of comorbidity data in a colorectal cancer multi-disciplinary team (MDT) setting. *Int J Colorectal Dis* 2018; 33: 1057–1061
- [74] Witjes CDM, Patel AS, Shenoy A et al. Oncological outcome after local treatment for early stage rectal cancer. *Surg Endosc* 2022; 36: 489–497
- [75] Sidhu M, Tate DJ, Desomer L et al. Mo1662. SMSA-EMR score is a novel endoscopic risk assessment tool for predicting critical endoscopic mucosal resection outcomes. *Gastrointest Endosc* 2018; 87: AB467–AB468
- [76] Anderson J, Lockett M. Training in therapeutic endoscopy: meeting present and future challenges. *Frontline Gastroenterol* 2019; 10: 135–140
- [77] Kahi CJ. Reviewing the evidence that polypectomy prevents cancer. *Gastrointest Endosc Clin N Am* 2019; 29: 577–585
- [78] O'Brien MJ, Gibbons D. The adenoma-carcinoma sequence in colorectal neoplasia. *Surg Oncol Clin N Am* 1996; 5: 513–530
- [79] Hassan C, Repici A, Sharma P et al. Efficacy and safety of endoscopic resection of large colorectal polyps: a systematic review and meta-analysis. *Gut* 2015; 65: 806–820
- [80] Holt BA, Bourke MJ. Wide field endoscopic resection for advanced colonic mucosal neoplasia: current status and future directions. *Clin Gastroenterol Hepatol* 2012; 10: 969–979
- [81] Klein A, Bourke MJ. Advanced polypectomy and resection techniques. *Gastrointest Endosc Clin N Am* 2015; 25: 303–333
- [82] Burgess NG, Metz AJ, Williams SJ et al. Risk factors for intraprocedural and clinically significant delayed bleeding after wide-field endoscopic mucosal resection of large colonic lesions. *Clin Gastroenterol Hepatol* 2014; 12: 651–653
- [83] Metz AJ, Bourke MJ, Moss A et al. Factors that predict bleeding following endoscopic mucosal resection of large colonic lesions. *Endoscopy* 2011; 43: 506–511
- [84] Veitch A, Vanbiervliet G, Gershlick A et al. Endoscopy in patients on antiplatelet or anticoagulant therapy, including direct oral anticoagulants: British Society of Gastroenterology (BSG) and European Society of Gastrointestinal Endoscopy (ESGE) guidelines. *Endoscopy* 2016; 48: 385–402
- [85] Shahidi N, Vosko S, Gupta S et al. Previously attempted large non-pedunculated colorectal polyps are effectively managed by endoscopic mucosal resection. *Am J Gastroenterol* 2021; 116: 958–966
- [86] Tate DJ, Desomer L, Klein A et al. Adenoma recurrence after piecemeal colonic EMR is predictable: the Sydney EMR recurrence tool. *Gastrointest Endosc* 2017; 85: 647–656.e646
- [87] Kandel P, Brand EC, Pelt J et al. Endoscopic scar assessment after colorectal endoscopic mucosal resection scars: when is biopsy necessary (EMR Scar Assessment Project for Endoscope (ESCAPE) trial). *Gut* 2019; 68: 1633–1641
- [88] Komeda Y, Watanabe T, Sakurai T et al. Risk factors for local recurrence and appropriate surveillance interval after endoscopic resection. *World J Gastroenterol* 2019; 25: 1502–1512
- [89] Bick BL, Ponugoti PL, Rex DK. High yield of synchronous lesions in referred patients with large lateral spreading colorectal tumors. *Gastrointest Endosc* 2017; 85: 228–233
- [90] Baron TH, Kamath PS, McBane RD. New anticoagulant and antiplatelet agents: a primer for the gastroenterologist. *Clin Gastroenterol Hepatol* 2014; 12: 187–195
- [91] Khashab MA, Chithadi KV, Acosta RD et al. Antibiotic prophylaxis for GI endoscopy. *Gastrointest Endosc* 2015; 81: 81–89
- [92] Shahidi N, Sidhu M, Vosko S et al. Endoscopic mucosal resection is effective for laterally spreading lesions at the anorectal junction. *Gut* 2020; 69: 673–680
- [93] Clark BT, Rustagi T, Laine L. What level of bowel prep quality requires early repeat colonoscopy: systematic review and meta-analysis of the impact of preparation quality on adenoma detection rate. *Am J Gastroenterol* 2014; 109: 1714–1723
- [94] Wong MCS, Ching JYL, Chan VCW et al. Determinants of bowel preparation quality and its association with adenoma detection. *Medicine* 2016; 95: e2251
- [95] Tutticci NJ, Hewett DG. Cold EMR of large sessile serrated polyps at colonoscopy (with video). *Gastrointest Endosc* 2018; 87: 837–842
- [96] Tate DJ, Awadie H, Bahin FF et al. Wide-field piecemeal cold snare polypectomy of large sessile serrated polyps without a submucosal injection is safe. *Endoscopy* 2018; 50: 248–252
- [97] Lai EJ, Calderwood AH, Doros G et al. The Boston bowel preparation scale: a valid and reliable instrument for colonoscopy-oriented research. *Gastrointest Endosc* 2009; 69: 620–625
- [98] Tate DJ, Sidhu M, Bar-Yishay I et al. Impact of en bloc resection on long-term outcomes after endoscopic mucosal resection: a matched cohort study. *Gastrointest Endosc* 2020; 91: 1155–1163.e1
- [99] Matharoo M. Endoscopic non-technical skills team training: The next step in quality assurance of endoscopy training. *World J Gastroenterol* 2014; 20: 17507–17507
- [100] Moss A, Bourke MJ, Tran K et al. Lesion isolation by circumferential submucosal incision prior to endoscopic mucosal resection (CSI-EMR) substantially improves en bloc resection rates for 40-mm colonic lesions. *Endoscopy* 2010; 42: 400–404
- [101] Kimoto Y, Sakai E, Inamoto R et al. Safety and efficacy of cold snare polypectomy without submucosal injection for large sessile serrated lesions: a prospective study. *Clin Gastroenterol Hepatol* 2022; 20: e132–e138
- [102] Holt BA, Jayasekera V, Sonson R et al. Topical submucosal chromoendoscopy defines the level of resection in colonic EMR and may improve procedural safety (with video). *Gastrointest Endosc* 2013; 77: 949–953
- [103] Tutticci N, Bourke MJ. Interventional chromoendoscopy: specific aspects for the colon. *Gastrointest Endosc* 2014; 79: 536–538
- [104] Desomer L, Tate DJ, Bahin FF et al. A systematic description of the post-EMR defect to identify risk factors for clinically significant post-EMR bleeding in the colon. *Gastrointest Endosc* 2019; 89: 614–624
- [105] Rodríguez Sánchez J, Sánchez Alonso M, Pellisé Urquiza M. The bubble sign: A novel way to detect a perforation after cold snare polypectomy. *Endoscopy* 2019; 51: 796–797
- [106] Nogales Rincón Ó, García J, Ortega Lobete O et al. The "double string" sign: a warning image after cold endoscopic mucosal resection. *Endoscopy* 2021; 53: E71–E72
- [107] Toyosawa J, Yamasaki Y, Fujimoto T et al. Resection depth for small colorectal polyps comparing cold snare polypectomy, hot snare polypectomy and underwater endoscopic mucosal resection. *Endosc Int Open* 2022; 10: E602–E608
- [108] Suzuki S, Gotoda T, Kusano C et al. Width and depth of resection for small colorectal polyps: hot versus cold snare polypectomy. *Gastrointest Endosc* 2018; 87: 1095–1103
- [109] Bourke MJ. Top tips for cold snare polypectomy (with video). *Gastrointest Endosc* 2022; 95: 1226–1232
- [110] Robertson DJ, Lieberman DA, Winawer SJ et al. Colorectal cancers soon after colonoscopy: a pooled multicohort analysis. *Gut* 2014; 63: 949–956
- [111] Backes Y, Seerden TCJ, van Gestel R et al. Tumor seeding during colonoscopy as a possible cause for metachronous colorectal cancer. *Gastroenterology* 2019; 157: 1222–1232.e1224
- [112] Soetikno R, Kaltenbach T. Dynamic submucosal injection technique. *Gastrointest Endosc Clin N Am* 2010; 20: 497–502

- [113] Nanda KS, Sonson RJ, Bourke MJ. Intramucosal injection: part of the spectrum of outcomes from submucosal injection during endoscopic resection. *Gastrointest Endosc* 2014; 80: 733–735
- [114] Horiuchi A, Hosoi K, Kajiyama M et al. Prospective, randomized comparison of 2 methods of cold snare polypectomy for small colorectal polyps. *Gastrointest Endosc* 2015; 82: 686–692
- [115] Sidhu M, Forbes N, Tate DJ et al. A randomized controlled trial of cold snare polypectomy technique: technique matters more than snare wire diameter. *Am J Gastroenterol* 2022; 117: 100
- [116] Klein A, Bourke MJ. How to perform high-quality endoscopic mucosal resection during colonoscopy. *Gastroenterology* 2017; 152: 466–471
- [117] Heitman SJ, Tate DJ, Bourke MJ. Optimizing resection of large colorectal polyps. *Curr Treat Options Gastroenterol* 2017; 15: 213–229
- [118] Tutticci N, Bourke MJ. Advanced endoscopic resection in the colon: recent innovations, current limitations and future directions. *Expert Rev Gastroenterol Hepatology* 2014; 8: 161–177
- [119] Bourke M. Endoscopic mucosal resection in the colon: A practical guide. *Tech Gastrointest Endosc* 2011; 13: 35–49
- [120] Tate DJ, Klein A, Bourke MJ. Endoscopic Mucosal Resection - A Comprehensive Tool (DV071) [Video]. ASGE; 2016. Accessed:11 April 2023 <https://learn.asge.org/Listing/Endoscopic-Mucosal-Resection-A-Comprehensive-Tool-DV071-228>
- [121] Rey JF, Beilenhoff U, Neumann CS et al. European Society of Gastrointestinal Endoscopy (ESGE) guideline: the use of electro-surgical units. *Endoscopy* 2010; 42: 764–772
- [122] Bahin FF, Naidoo M, Williams SJ et al. Prophylactic endoscopic coagulation to prevent bleeding after wide-field endoscopic mucosal resection of large sessile colon polyps. *Clin Gastroenterol Hepatol* 2015; 13: 722–724
- [123] Meulen LWT, Bogie RMM, Winkens B et al. Thermal ablation of mucosal defect margins to prevent local recurrence of large colorectal polyps: a systematic review and meta-analysis. *Endosc Int Open* 2022; 10: E1127–E1135
- [124] Chandan S, Facciorusso A, Ramai D et al. Snare tip soft coagulation (STSC) after endoscopic mucosal resection (EMR) of large (>20 mm) non pedunculated colorectal polyps: a systematic review and meta-analysis. *Endosc Int Open* 2022; 10: E74–E81
- [125] Kumar V, Broadley H, Rex DK. Safety and efficacy of hot avulsion as an adjunct to EMR (with videos). *Gastrointest Endosc* 2019; 89: 999–1004
- [126] Tsiamoulos ZP, Bourikas LA, Saunders BP. Endoscopic mucosal ablation: a new argon plasma coagulation/injection technique to assist complete resection of recurrent, fibrotic colon polyps (with video). *Gastrointest Endosc* 2012; 75: 400–404
- [127] Sakamoto T, Saito Y, Matsuda T et al. Treatment strategy for recurrent or residual colorectal tumors after endoscopic resection. *Surg Endosc* 2011; 25: 255–260
- [128] Azzolini F, Camellini L, Sassatelli R et al. Endoscopic submucosal dissection of scar-embedded rectal polyps: a prospective study (ESD in scar-embedded rectal polyps). *Clin Res Hepatol Gastroenterol* 2011; 35: 572–579
- [129] Kuroki Y, Hoteya S, Mitani T et al. Endoscopic submucosal dissection for residual/locally recurrent lesions after endoscopic therapy for colorectal tumors. *J Gastroenterol Hepatol* 2010; 25: 1747–1753
- [130] Ma MX, Tate DJ, Sidhu M et al. Effect of pre-resection biopsy on detection of advanced dysplasia in large nonpedunculated colorectal polyps undergoing endoscopic mucosal resection. *Endoscopy* 2023; 55: 267–273
- [131] Nutalapati V, Desai M, Thoguluva-Chandrasekar VS et al. Effect of dynamic position changes on adenoma detection rate during colonoscopy withdrawal: systematic review and meta-analysis. *Endosc Int Open* 2020; 08: E1842–E1849
- [132] Nanda KS, Tutticci N, Burgess NG et al. Endoscopic mucosal resection of laterally spreading lesions involving the ileocecal valve: technique, risk factors for failure, and outcomes. *Endoscopy* 2015; 47: 710–718
- [133] Uchima H, Colan-Hernandez J, Caballero N et al. Underwater endoscopic mucosal resection of an adenomatous lesion with deep extension into the appendiceal orifice. *Endoscopy* 2021; 53: 334–335
- [134] Holt BA, Bassan MS, Sexton A et al. Advanced mucosal neoplasia of the anorectal junction: endoscopic resection technique and outcomes (with videos). *Gastrointest Endosc* 2014; 79: 119–126
- [135] Fujimoto A, Saito Y, Abe S et al. Clinical usefulness of red dichromatic imaging in hemostatic treatment during endoscopic submucosal dissection: First report from a multicenter, open-label, randomized controlled trial. *Dig Endosc* 2022; 34: 379–390
- [136] Kita A, Kuribayashi S, Itoi Y et al. Efficacy of using red dichromatic imaging throughout endoscopic submucosal dissection procedure. *Surg Endosc* 2023; 37: 503–509
- [137] Fahrthash-Bahin F, Holt BA, Jayasekaran V et al. Snare tip soft coagulation achieves effective and safe endoscopic hemostasis during wide-field endoscopic resection of large colonic lesions (with videos). *Gastrointest Endosc* 2013; 78: 158–163 e151
- [138] Facciorusso A, Bertini M, Bertoni M et al. Effectiveness of hemostatic powders in lower gastrointestinal bleeding: a systematic review and meta-analysis. *Endosc Int Open* 2021; 9: E1283–E1290
- [139] Chiapponi C, Stocker U, Körner M et al. Emergency percutaneous needle decompression for tension pneumoperitoneum. *BMC Gastroenterol* 2011; 11: 48
- [140] Burgess NG, Williams SJ, Hourigan LF et al. A management algorithm based on delayed bleeding after wide-field endoscopic mucosal resection of large colonic lesions. *Clin Gastroenterol Hepatol* 2014; 12: 1525–1533
- [141] Li S, Oshea B, Sun S. Special considerations in the management of lower GI bleed by interventional radiology. *J Interv Med* 2019; 2: 101–105
- [142] Desomer L, Tate DJ, Awadie H et al. Mo1085 Persistent pain after colonic endoscopic mucosal resection: predictors, a management algorithm and outcomes. *Gastrointest Endosc* 2017; 85: AB421
- [143] Desomer L, Tate DJ, Pillay L et al. Intravenous paracetamol for persistent pain after endoscopic mucosal resection discriminates patients at risk of adverse events and those who can be safely discharged. *Endoscopy* 2023; doi:10.1055/a-2022-6530
- [144] Stjepanovic N, Moreira L, Carneiro F et al. Hereditary gastrointestinal cancers: ESMO Clinical Practice Guidelines for diagnosis, treatment and follow-up†. *Ann Oncol* 2019; 30: 1558–1571
- [145] Desomer L, Tutticci N, Tate DJ et al. A standardized imaging protocol is accurate in detecting recurrence after EMR. *Gastrointest Endosc* 2017; 85: 518–526
- [146] Pellise M, Desomer L, Burgess NG et al. The influence of clips on scars after EMR: clip artifact. *Gastrointest Endosc* 2015; 83: 1–9
- [147] Sreepati G, Vemulapalli KC, Rex DK. Clip artifact after closure of large colorectal EMR sites: incidence and recognition. *Gastrointest Endosc* 2015; 82: 344–349
- [148] Kim HG, Thosani N, Banerjee S et al. Underwater endoscopic mucosal resection for recurrences after previous piecemeal resection of colorectal polyps (with video). *Gastrointest Endosc* 2014; 80: 1094–1102
- [149] Tsiamoulos ZP, Rameshshanker R, Gupta S et al. Augmented endoscopic resection for fibrotic or recurrent colonic polyps using an ablation and cold avulsion technique. *Endoscopy* 2016; 48: (Suppl. 01): E248–E249
- [150] Gupta S, Bassett P, Man R et al. Validation of a novel method for assessing competency in polypectomy. *Gastrointest Endosc* 2012; 75: 568–575