



Modified Trans-Sinusal Transglabellar Approach for Anterior Cranial Fossa Meningiomas: Technical Note and Literature Review

Bruno Lobo Mota de Siqueira¹ Luiz Euripedes Almondes Santana Lemos¹

Maysa Gomes Ferreira de Araújo² Rhuann Pontes dos Santos Silva³  Mayle Gomes Ferreira de Araújo¹

Fabiola Gissel Cortez¹ Hildo Rocha Cirne de Azevedo Filho¹

¹Department of Neurosurgery, Medical Residency Program, University of Pernambuco, Hospital da Restauração, Recife, Brazil

²University of Pernambuco, Pernambuco, Brazil

³Catholic University of Pernambuco, Pernambuco, Brazil

Address for correspondence Rhuann Pontes dos Santos Silva, MD
Catholic University of Pernambuco, Pernambuco, Brazil
(e-mail: rhuannpontes02@gmail.com).

J Neurol Surg Rep 2023;84:e40–e45.

Abstract

Introduction Currently, skull base surgery faces the dilemma of achieving the maximum possible tumor resection through less aggressive approaches and with minimal retraction of brain tissue. The objective of this work is to report a minimally invasive step-by-step approach to anterior cranial fossa tumors and to perform a literature review.

Methods In our work, we describe a step-by-step approach, with images, which is a variation of the transglabellar approach.

Results In all cases, we achieved maximum total resection of the lesion. There were no postoperative complications related to the surgery. In one case, we used the access to remove a foreign body in the frontal lobe.

Conclusion The frontal trans-sinusal transglabellar access allows direct access to anterior cranial fossa tumors and other frontal lobe lesions close to the floor of the anterior fossa, without the need for brain retraction, allowing early devascularization of the tumor. However, this access is not recommended for all types of tumors, and is being improved for more anteriorly located lesions.

Keywords

- ▶ trans-sinusal approach
- ▶ transglabellar approach
- ▶ anterior cranial fossa meningiomas
- ▶ neuro-oncology

Introduction

The first reported case of successful surgical removal of an olfactory groove meningioma is attributed to the Italian surgeon Francesco Durante in 1885. In 1938, Cushing published a series of 28 patients operated on through unilateral frontal craniotomy and subfrontal access, through a bicoronal incision.¹

Currently, there are three main ways to access the meningioma of the anterior fossa: (1) the unilateral frontal

access of Cushing, (2) the bifrontal access with bilateral removal of the orbital roof, and (3) the unilateral pterional access on the side where the tumor insinuates more laterally, proposed by Kempe.²

Each approach has its advantages and disadvantages. Frontal accesses allow early exposure of the ethmoidal arteries, which allows early devascularization of the tumor. On the other hand, they have worse cosmetics results in addition to a high risk of cerebrospinal fluid (CSF) leak. The

received
July 5, 2022
accepted

October 20, 2022
accepted manuscript online
March 22, 2023

DOI <https://doi.org/10.1055/a-2060-5534>
ISSN 2193-6366.

© 2023. The Author(s).

This is an open access article published by Thieme under the terms of the Creative Commons Attribution-NonDerivative-NonCommercial-License, permitting copying and reproduction so long as the original work is given appropriate credit. Contents may not be used for commercial purposes, or adapted, remixed, transformed or built upon. (<https://creativecommons.org/licenses/by-nc-nd/4.0/>)

Georg Thieme Verlag KG, Rüdigerstraße 14, 70469 Stuttgart, Germany

pterional route allows access to the posterior pole of the tumor, allowing dissection of the optic nerves and arterial vessels. However, devascularization of the lesion becomes less likely.³

Currently, skull base surgery faces the dilemma of achieving the maximum possible tumor resection through less aggressive approaches and with minimal retraction of brain tissue.⁴

Hallacq et al described a trans-sinusal approach for resection of six tumors in the anterior cranial fossa in patients between the ages of 39 and 76 years. The incision adopted was the bicoronal as described by Souttar, extending from one tragus to the other.²

In 1988, Raveh et al described a subcranial approach through a transglabellar incision to approach traumatic lesions of the face.⁵ Kleiber et al⁴ was the first to describe the Hallacq trans-sinusal technique combined with a transglabellar incision, as proposed by Raveh et al.⁵

The objective of this work is to report a minimally invasive step-by-step approach to anterior cranial fossa tumors through a combination and modification of the approaches described by Hallacq et al,² Kleiber et al,⁴ and Raveh et al.⁵

Materials and Methods

- **Ethical standards:** All the patients gave oral and written consent, through a consent form, to participate in this study.
- **Positioning:** All the patients were initially submitted to general anesthesia. They were placed in the dorsal decubitus position, with the head fixed by a three-pin Mayfield in the neutral position (►Fig. 1). A slight cervical extension was performed so that the frontal lobe moved away from the orbital roof, minimizing the need for retraction. The head was elevated above the level of the heart to facilitate venous return and reduce cerebral edema. In all the patients, the abdomen was properly prepared for fat removal to be used in dural closure.
- **Skin insertion:** We marked the supraorbital foramina, and then made a symmetrical incision between the two eyebrows, with the foramina being the lateral limit. The

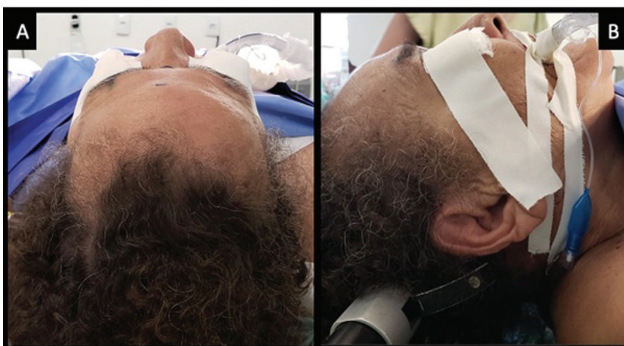

Fig. 1 (A,B) Positioning the patient. Observe the head in neutral rotation, fixed in Mayfield, and with slight extension, to facilitate the retraction of the frontal lobe by the action of gravity.

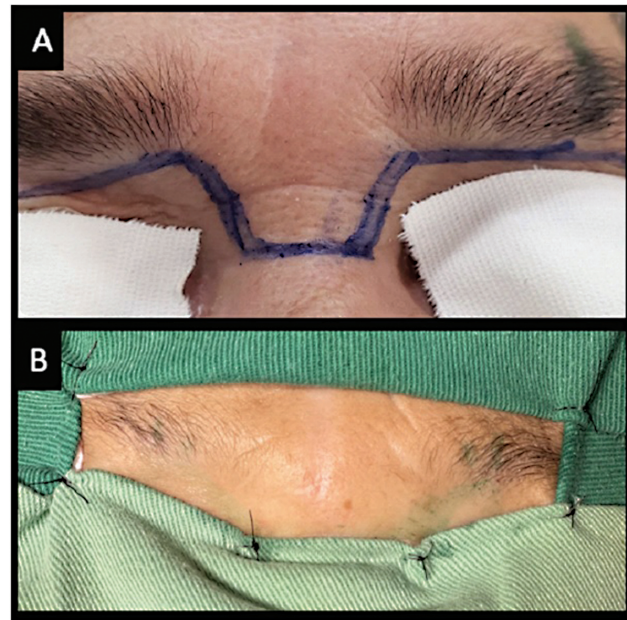


Fig. 2 (A) Marking of the skin incision, ideally below the eyebrow, with the lateral limit as the supraorbital foramina. (B) Operative aspect with the sterile drapes set up.

incision followed a curve through the glabella, following over the nasion (►Fig. 2).

- **Soft-tissue dissection:** The subcutaneous tissues and the periosteum are initially incised with a no. 15 scalpel blade, and then using a monopolar with a colored tip the tissues were dissected and mobilized as a single flap, and then fixed using cotton thread and surgical elastics (►Fig. 3).
- **Craniotomy:** This was performed in three parts.

Initially, the anterior wall of the frontal sinus was removed through a single small burr hole, and then sawn, drawing the extension of the frontal sinus (►Fig. 4A).

Next, the frontal sinus is treated and cranialization is done with removal of the entire mucosa, coagulation of the walls,

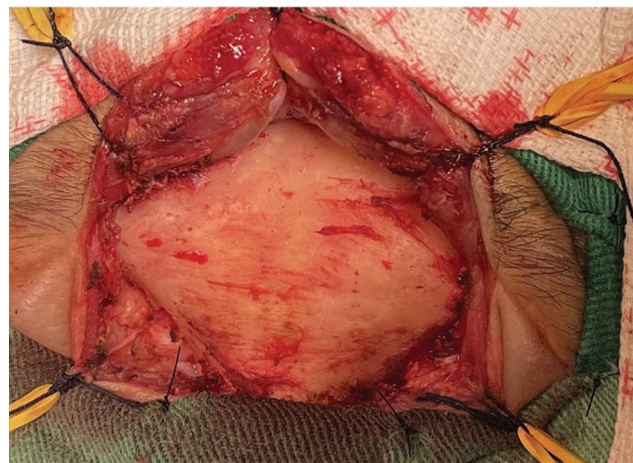


Fig. 3 Exposing the external table of the frontal sinus. Skin flap folded in a single layer previously and fixed with cotton threads and surgical elastics.

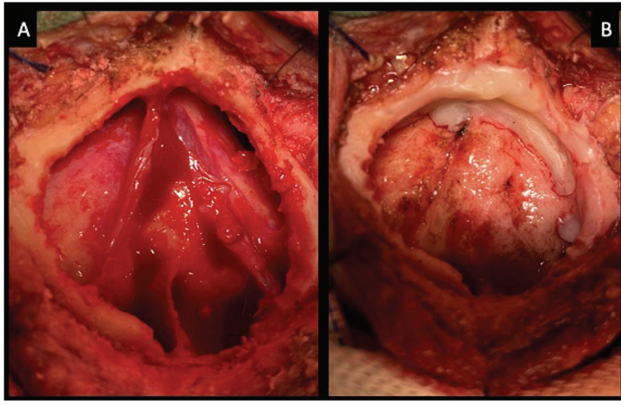


Fig. 4 (A) After removal of the frontal sinus outer table, showing the mucosa of the sinus. (B) After cranialization of the sinus, and occlusion of the frontonasal duct with bone wax.

drilling with a diamond burr, and tamponade of the fronto-nasal ducts, initially with bone wax, and later, during the closure of the access, with a fat patch and fibrin glue (►Fig. 4B).

Finally, craniectomy of the posterior wall of the frontal sinus was done. Initially, we made a burr hole and then the frontal dura was dissected. Then with the use of a Kerrison punch, the entire bone surface was removed, exposing the dura of the anterior fossa (►Fig. 5).

- **Durotomy:** Before opening the dura, dissection of the anterior fossa and identification and coagulation of the anterior ethmoidal arteries were done (►Fig. 6B), in addition to coagulation of the entire dural insertion base of the tumor, allowing complete devascularization, which meant a clean resection field with minimal blood loss. Then the dura was opened through an arcuate incision with the base facing the anterior fossa (►Fig. 6A). Before crossing the midline, we performed ligation and coagulation of the superior sagittal sinus and cut the falx, and then the dural flap was advanced and fixed anteriorly with the use of Prolene threads.

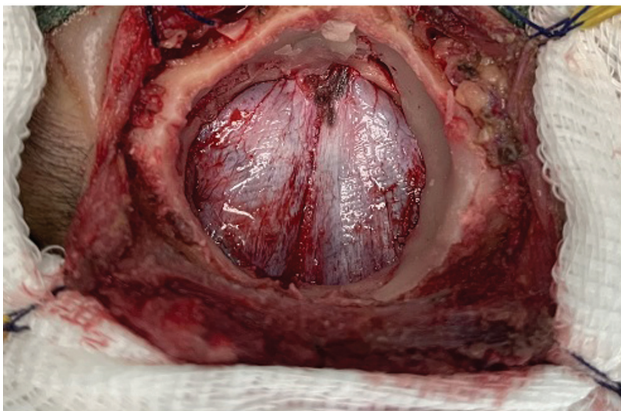


Fig. 5 After removal of the inner table of the frontal sinus. Note the dura mater firmly attached to the floor of the anterior fossa.

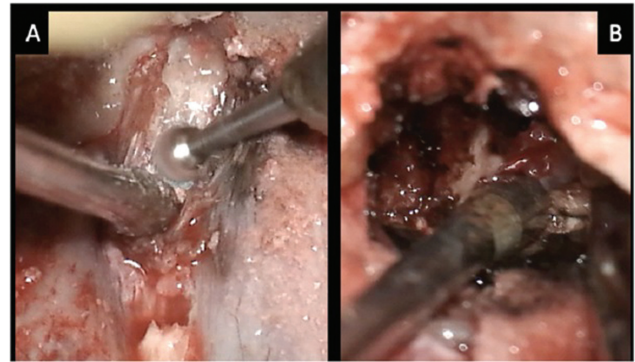


Fig. 6 (A) Drilling the crista galli. (B) Observe the right anterior ethmoid artery before being coagulated.

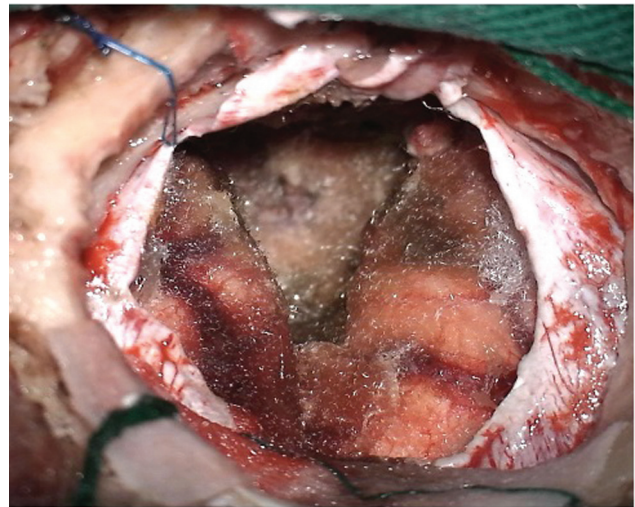


Fig. 7 Final postoperative appearance. Note the space previously filled by the tumor. Note the presence of fibrillar Surgicel covering the tumor bed and frontal lobes. Duroplasty:

- **Microsurgery:** After dural opening, we initially performed debulking of the tumor using a microscope, and then dissection of the arachnoid planes. Removing the lesion en bloc should be avoided (►Fig. 7).

The dura was sutured primarily with 4-0 Prolene thread in continuous stitches as tightly as possible. As the basal dura was coagulated and resected in the initial steps of microscopy, we placed an autologous flap between the dura and the bone of the anterior fossa, and then the space was filled with abdominal fat and biological fibrin glue (►Fig. 8).

- **Cranioplasty:** After dural closure, we removed the bone wax initially used to occlude the frontonasal ducts, and filled it with fat and an autologous patch. The external table was then fixed to the skull using 2-0 nylon threads or small titanium plates (►Fig. 9). We recommend the use of titanium plates for a better cosmetic result.
- **Skin Closure:** After rigorous hemostasis, the subcutaneous tissue was closed, without using a drain, with a 3-0

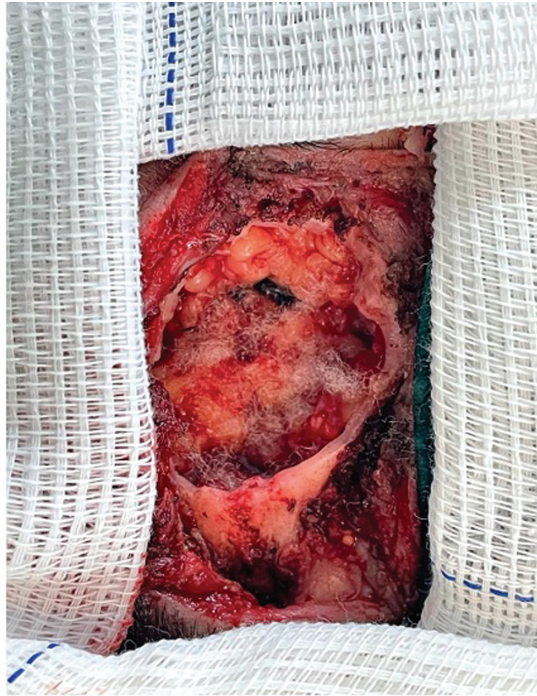

Fig. 8 After hermetic closure of the dura mater, we filled the space occupied by the frontal sinus with abdominal fat.

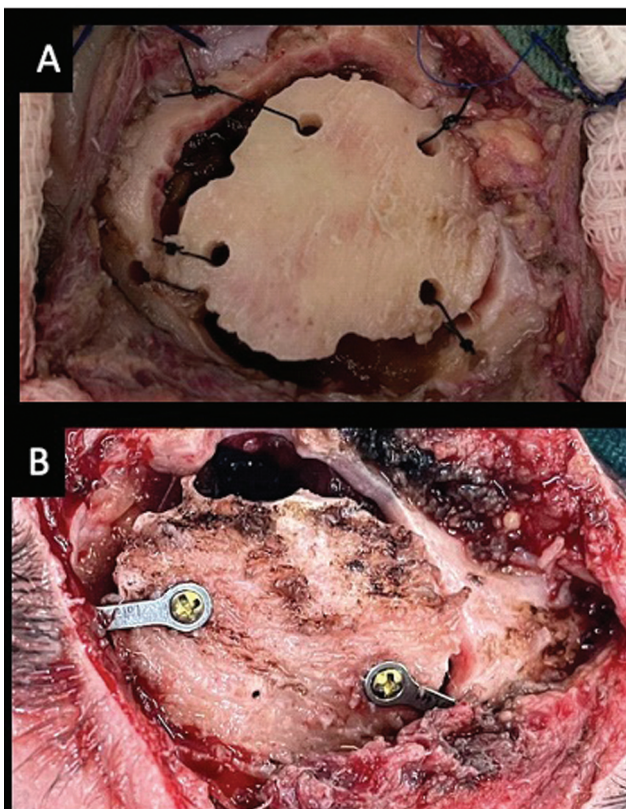


Fig. 9 Two possible forms of bone closure: (A) with nonabsorbable threads or (B) with titanium plates.

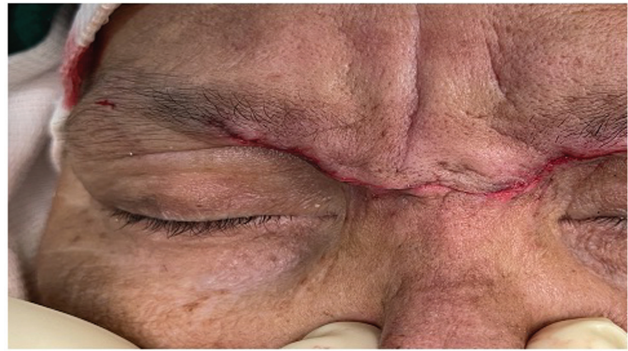

Fig. 10 Final aspect of the skin closure.

absorbable thread, and then the skin is closed using a 4–0 Monocryl thread. Ideally, for better aesthetic results, we recommend performing continuous suture instead of intradermal suture (→ **Fig. 10**).

- *Tips:* The incision must follow the natural folds of the skin to obtain the best aesthetic result.

Closure is a very important part of access, both to avoid CSF leaks that can hinder healing and complicate wound infection and to obtain a better aesthetic result.

Discussion

Kleiber et al were the first to combine the advantages of the trans-sinusal approach through the frontal sinus to the anterior fossa with a minimally invasive incision over the glabella.⁴

The frontal transglabellar trans-sinusal approach has several advantages, some of which are the following: a very short incision and craniotomy, with minimal blood loss, which is particularly useful in older patients. It allows early access to the arterial feeders of the tumors. It provides access to the tumor with minimal frontal lobe retraction. It also allows extradural coagulation of the tumor base, enabling clean surgery.

However, this access is not free of complications. The most common complications are wound infection and CSF fistula. Both can be prevented through cranialization of the frontal sinus through resection of all mucous membranes, obstruction of the frontonasal ducts, isolation of the cranial cavity from the paranasal sinuses, and hermetic dural closure, using an autologous patch.²

When hermetic reconstruction of the dura is not possible, especially the basal dura, the space between the dura and the bone of the anterior fossa must be filled with fat and an autologous patch and reinforced with fibrin glue.

In our work, we describe a step-by-step approach, with images, a variation of this access, being as less invasive as possible. In all cases, we achieved maximum total resection

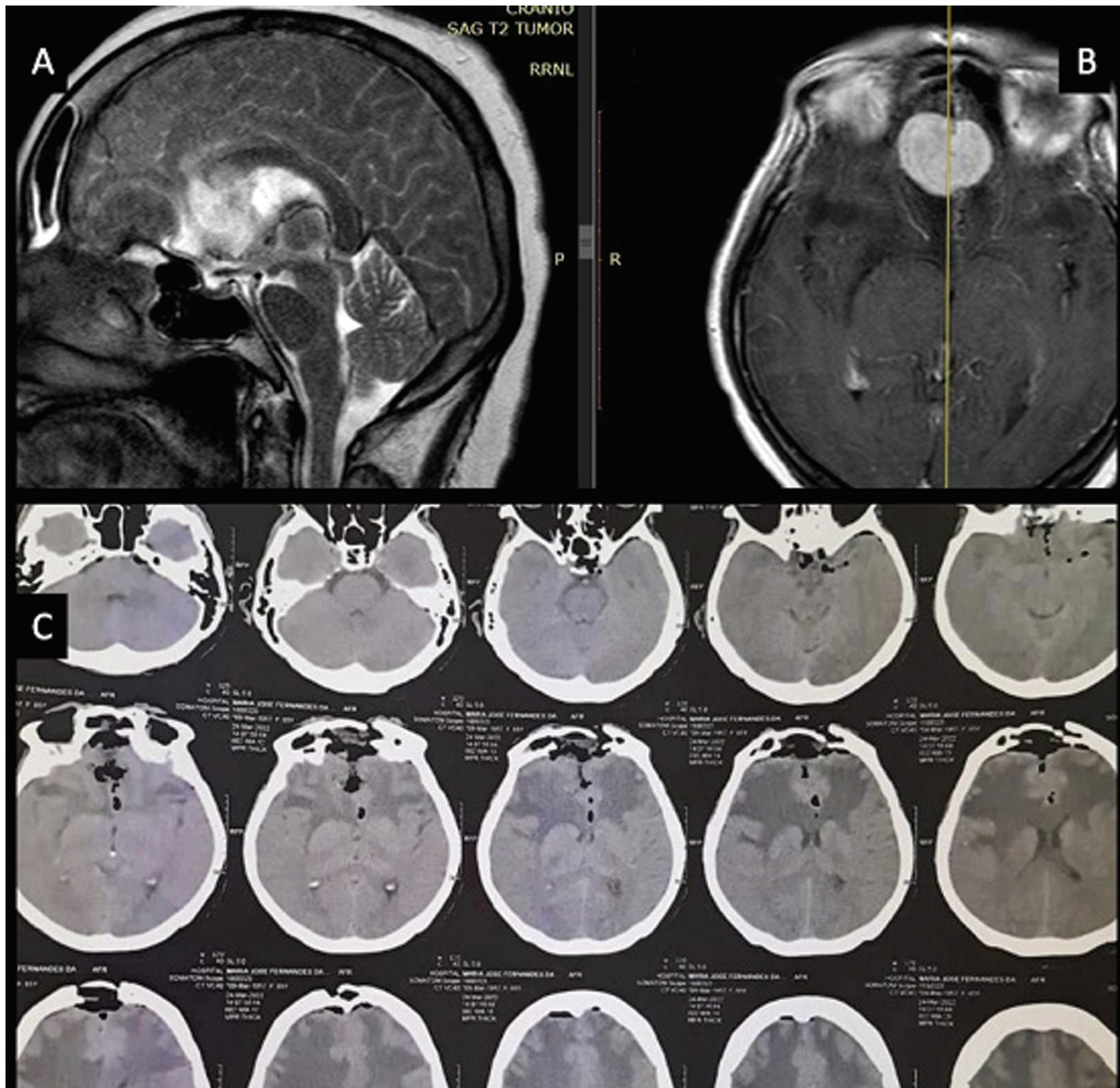

Fig. 11 Preoperative aspect of a magnetic resonance imaging (MRI) in (A) sagittal and (B) axial sections, and (C) immediate postoperative tomography showing total resection of the lesion through the translabellar approach.

of the lesion (► **Fig. 11**). There were no postoperative complications related to the surgery. In one case, we used the access to remove a foreign body in the frontal lobe, allowing for a cleaner and faster surgery.

The aesthetic evolution of all patients was considered satisfactory (► **Figs. 12** and **13**).

Conclusion

The frontal trans-sinusal translabellar access allows direct access to anterior cranial fossa tumors and other frontal lobe

lesions close to the floor of the anterior fossa, without the need for brain retraction, allowing early devascularization of the tumor.

However, this access is not recommended for all types of tumors, being improved for more anteriorly located lesions, such as olfactory groove meningioma or planum, and not recommended for sellar tubercle lesions.

Conflict of Interest

None declared.

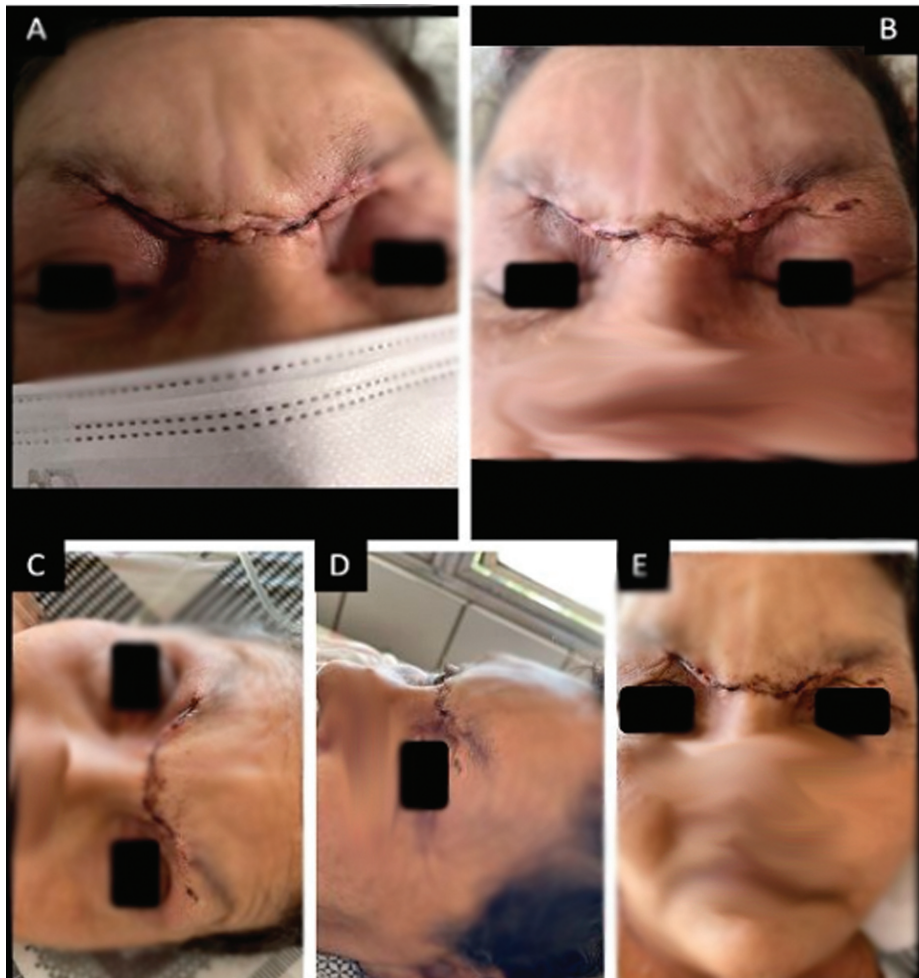


Fig. 12 Case 01. (A) Aspect of the wound on the first postoperative day. (B) Aspect on post-op day 4. (C-E) Aspect on post-op day 10.

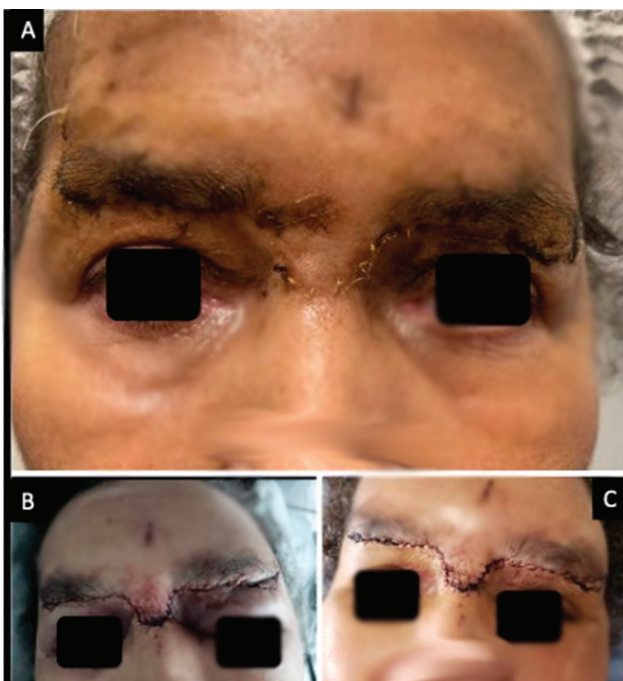


Fig. 13 Case 02. (A) Aspect of the wound on postoperative day 14. (B) Aspect on post-op day 2. (C) Aspect on post-op day 5.

References

- 1 Meningiomas. Their classification, regional behaviour, life history, and surgical end results. *Bull Med Libr Assoc* 1938;27(02):185
- 2 Hallacq P, Moreau JJ, Fischer G, Béziat JL. Trans-sinusal frontal approach for olfactory groove meningiomas. *Skull Base* 2001;11(01):35-46
- 3 Hassler W, Zentner J. Pterional approach for surgical treatment of olfactory groove meningiomas. *Neurosurgery* 1989;25(06):942-945, discussion 945-947
- 4 Kleiber JC, Roemer S, Duntze J, et al. Transglabellar approach for resection of anterior midline skull base meningiomas: technical note. *Acta Neurochir (Wien)* 2014;156(12):2283-2287
- 5 Raveh J, Vuillemin T, Sutter F. Subcranial management of 395 combined frontobasal-midface fractures. *Arch Otolaryngol Head Neck Surg* 1988;114(10):1114-1122