

Endoscopic calcium electroporation for colorectal cancer: a phase I study



Authors

Malene Broholm¹, Rasmus Vogelsang¹, Mustafa Bulut^{1,2}, Trine Stigaard¹, Hanne Falk³, Stine Frandsen⁴, Dorte Levin Pedersen⁵, Trine Perner⁵, Anne-Marie Kanstrup Fiehn^{1,2,6}, Ida Mølholm⁷, Michael Bzorek⁶, Andreas Weinberger Rosen¹, Christina Søs Auður Andersen⁶, Niels Pallisgaard⁶, Ismail Gögenur^{1,2}, Julie Gehl^{2,3,4}

Institutions

- 1 Center for Surgical Science, Department of Surgery, Zealand University Hospital, Denmark
- 2 Department of Clinical Medicine, Faculty of Health and Medical Sciences, University of Copenhagen, Copenhagen, Denmark
- 3 Department of Oncology, Herlev and Gentofte Hospital, University of Copenhagen, Herlev, Denmark
- 4 Center for Experimental Drug and Gene Electrotransfer (C*EDGE), Department of Clinical Oncology and Palliative Care, Zealand University Hospital, Roskilde, Denmark
- 5 Department of Radiology, Zealand University Hospital, Denmark
- 6 Department of Pathology, Zealand University Hospital, Denmark
- 7 Visiopharm, Hoersholm, Denmark

submitted 23.9.2022

accepted after revision 9.2.2023

published online 13.2.2023

Bibliography

Endosc Int Open 2023; 11: E451–E459

DOI 10.1055/a-2033-9831

ISSN 2364-3722

© 2023. The Author(s).

This is an open access article published by Thieme under the terms of the Creative Commons Attribution-NonDerivative-NonCommercial License, permitting copying and reproduction so long as the original work is given appropriate credit. Contents may not be used for commercial purposes, or adapted, remixed, transformed or built upon. (<https://creativecommons.org/licenses/by-nc-nd/4.0/>)

Georg Thieme Verlag KG, Rüdigerstraße 14,
70469 Stuttgart, Germany

Corresponding author

Malene Broholm, Zealand University Hospital Koge –
Department of Surgery, Lykkebaekvej 1, Koge 4600, Denmark
Phone: +45-41272742
malenebroholm87@gmail.com

Supplementary material is available under
<https://doi.org/10.1055/a-2033-9831>

ABSTRACT

Background and study aims Colorectal cancer is one of the most common malignancies, with approximately 20% of patients having metastatic disease. Local symptoms from the tumor remain a common issue and affect quality of life. Electroporation is a method to permeabilize cell membranes with high-voltage pulses, allowing increased passage of otherwise poorly permeating substances such as calcium. The aim of this study was to determine the safety of calcium electroporation for advanced colorectal cancer.

Patients and methods Six patients with inoperable rectal and sigmoid colon cancer were included, all presenting with local symptoms. Patients were offered endoscopic calcium electroporation and were followed up with endoscopy and computed tomography/magnetic resonance scans. Biopsies and blood samples were collected at baseline and at follow-up, 4, 8, and 12 weeks after treatment. Biopsies were examined for histological changes and immunohistochemically with CD3/CD8 and PD-L1. In addition, blood samples were examined for circulating cell-free DNA (cfDNA).

Results A total of 10 procedures were performed and no serious adverse events occurred. Prior to inclusion, patients reported local symptoms, such as bleeding (N = 3), pain (N = 2), and stenosis (N = 5). Five of six patients reported symptom relief. In one patient, also receiving systemic chemotherapy, clinical complete response of primary tumor was seen. Immunohistochemistry found no significant changes in CD3/CD8 levels or cfDNA levels after treatment.

Conclusions This first study of calcium electroporation for colorectal tumors shows that calcium electroporation is a safe and feasible treatment modality for colorectal cancer. It can be performed as an outpatient treatment and may potentially be of great value for fragile patients with limited treatment options.

Introduction

Colorectal cancer is one of the most commonly diagnosed cancers, and metastatic disease continues to be frequent. In a number of patients, symptoms arise from the tumor in the colon or rectum, leading to a complicated clinical course with obstructive symptoms, pain, or bleeding and resulting in reduced quality of life.

Electroporation utilizes brief electric pulses to permeabilize the cell membrane, which facilitates transport of molecules [1] such as calcium (calcium electroporation) [2]. Calcium electroporation is a promising anticancer treatment and has been tested in preclinical [3–10] and clinical studies [11–14]. Studies investigating calcium electroporation for cutaneous metastases have shown that the treatment is safe and feasible with promising results [11, 13]. A recent study in recurrent head and neck cancer showed a clinical response in three of six patients [14]. Interestingly, studies have found an indication that calcium electroporation initiates a favorable immunologic response, which potentially may be used in a multimodal treatment strategy in the future.

However, calcium electroporation for colorectal cancer has not yet been tested in a clinical setting. We here report the first clinical study of calcium electroporation for colorectal cancer. The aim of the trial was to evaluate the safety of the procedure.

Patients and methods

Setting

This was an exploratory phase I study investigating the safety of endoscopic calcium electroporation for colorectal cancer. The study was planned to include six patients with inoperable colorectal cancer. Patients were recruited at Zealand University Hospital, Denmark. The protocol was approved by the Danish Medicines Agency, the Regional Ethics Committee (H-16036390) and the Danish Data Protection Agency (REG-189–2017). Clinicaltrials.gov identifier: NCT03542214.

Patients

Eligible patients had histologically verified inoperable colorectal. Patients were reviewed by a multidisciplinary team before inclusion. Inclusion criteria were: age > 18 years, treatment-free interval of a minimum of 2 weeks, World Health Organization Performance Status ≤ 2 , patients deemed capable of understanding the given information and written informed consent, thrombocytes ≥ 50 billion/L, and estimated glomerular filtration rate (eGFR) > 40 mL/min. Ineligibility criteria were pregnancy, implanted colon stent, implantable cardioverter-defibrillator or pacemaker, non-correctable coagulative disorder, highly inflamed colon tissue with ulceration and bleeding, or any other clinical condition or previous treatment that, in the investigators' opinion, made the patient ineligible.

Screening

After informed consent was signed, patients were examined with an electrocardiogram (EKG) and blood biochemistry. In addition, a nurse who specialized in nurse-administered propo-

fol sedation (NAPS) assessed whether the patients were eligible for NAPS. Exclusion criteria were ASA > II, body mass index > 35, sleep apnea, high risk of respiratory complications, and previous complications associated with anesthesia.

Bowel preparation

Individual recommendations for bowel preparation were given. For patients with a rectal tumor, enema was found to be sufficient as preparation before the procedure.

Anesthesia

The procedure was performed on an outpatient basis under NAPS. The initial bolus of propofol was 100 mg minus patient age (maximum of 60 mg), followed by a bolus (50% of initial dose) after 45 to 60 seconds. A repeated bolus (5 mg) was provided with a 30– to 40-second interval during the procedure according to institutional guidelines.

Injection of calcium chloride

The dosage of calcium chloride was estimated from preclinical studies [3, 4, 9, 15]. Calcium chloride was administered intratumorally with a 4-mm endoscopic injection needle. The investigator prepared calcium chloride in the Operating Room and the preparation was countersigned by an observer, as previously described [14]. Calcium chloride with a concentration of 0.5 mM (SAD, Denmark) was dispensed in a solution with isotonic NaCl: (6.75 mL calcium chloride + 8.25 mL NaCl = 15 mL solution with 9 mg/mL or 0.225 mmol/mL calcium chloride).

The injected dose of calcium chloride was defined by the surgeon based on assessment of tumor volume through visualization with an endoscope. As a safety measure, the maximum dosage was set at 13 mL of calcium chloride. This was calculated from a desired maximum rise in Ca^{2+} of 0.2 mmol/L extracellular volume (approximately 15 L of extracellular volume \times 0.2 mmol/L = 3 mmol calcium chloride: 3 mmol/0.225 mmol/mL \approx 13 mL calcium chloride).

It was expected that a significant amount of calcium chloride would leak out due to the stiffness of tumor tissue.

Endoscopic electroporation

The EndoVE device (Mirai Medical, Cork, Ireland) was used. EndoVE is a single-use device that can be attached to a standard endoscope. The device was connected to a vacuum system to draw tumor tissue into contact with the chamber. The device was connected to a square wave pulse generator (Cliniporator EPS01, Italy). The pulse generator delivered a series of eight pulses of 0.1 ms duration with a frequency of 1 kHz and an amplitude of 1 kV/cm.

Endoscopic procedure

Before injection of calcium chloride, the tumor was inspected and photographed, and biopsies were collected. After biopsies were collected, calcium chloride was injected intratumorally. After injection, the EndoVe device was attached. The device was placed on the tumor, and vacuum suction secured the position. Repositioning of the electrode was performed after each series of electrical pulses until the entire tumor area was cov-

ered or to the extent possible. The treatment was performed by two experienced endoscopic surgeons.

After treatment, patients were observed for at least 20 minutes.

Follow-up

A follow-up visit after 1 week was planned, with clinical examination and blood samples. Furthermore, patients had a follow-up visit with blood samples and endoscopy with biopsies approximately 4, 8, and 12 weeks and 6 months after initial study treatment, if possible. Additional treatment with calcium electroporation could be offered in case of remaining tumor tissue, and if the repeated procedure was deemed suitable. A maximum of three treatments were offered with a minimum interval of 4 weeks.

Primary endpoint

The primary endpoint was safety of the procedure. Safety evaluation was performed using reported adverse events (AEs) according to Common Terminology Criteria for Adverse Events (CTCAE) version 4.0.

Secondary endpoints

Pain

Pain in relation to the procedure and pain from the primary tumor at follow-up were evaluated through the numeric rating scale (NRS) pain score. In NRS, patients are asked to indicate a number between 0 and 10. Zero represents no pain at all whereas the upper limit represents the worst pain ever possible. NRS was recorded at baseline, Day 1, and at each follow-up visit.

Patient-reported symptoms

Patient-reported symptoms, including pain, bleeding, stenosis, and diarrhea were registered at inclusion and at each follow-up.

Manual assessment of major histopathological differences

Unblinded matched biopsies were compared for obvious differences that would not be identified by the quantitative analysis as i. e. ischemic changes or hyperplasia.

Immunohistochemical staining and histopathological analysis

Potential local immunologic response after treatment was evaluated. Analysis of PD-L1 expression was performed to identify potential targets for anticancer treatment. Serial sections of FFPE blocks of 4 μ m were cut. The first slide was stained with hematoxylin and eosin (HE). Immunohistochemical staining was performed using anti-PD-L1 clone 22C3 (Agilent/Dako, Glostrup, Denmark, cat# M3653), anti-CD3 clone LN10 (Leica/Triolab AS, Broendby, Denmark, cat# NCL-L-CD3-565) and anti-CD8 clone C8/144B (Agilent/Dako, cat# GA623). All staining was performed as double-labelling with anti-Cytokeratin clone BS5 (Nordic Biosite Aps, Copenhagen K, Denmark, cat# BSH-7124-1) on the automated instrument Omnis (Agilent/Dako),

and details of protocols are outlined in **Supplementary 1**. For PD-L1, a previously published detailed protocol was followed [16].

Quantitative digital image analysis of CD3- and CD8-positive lymphocytes

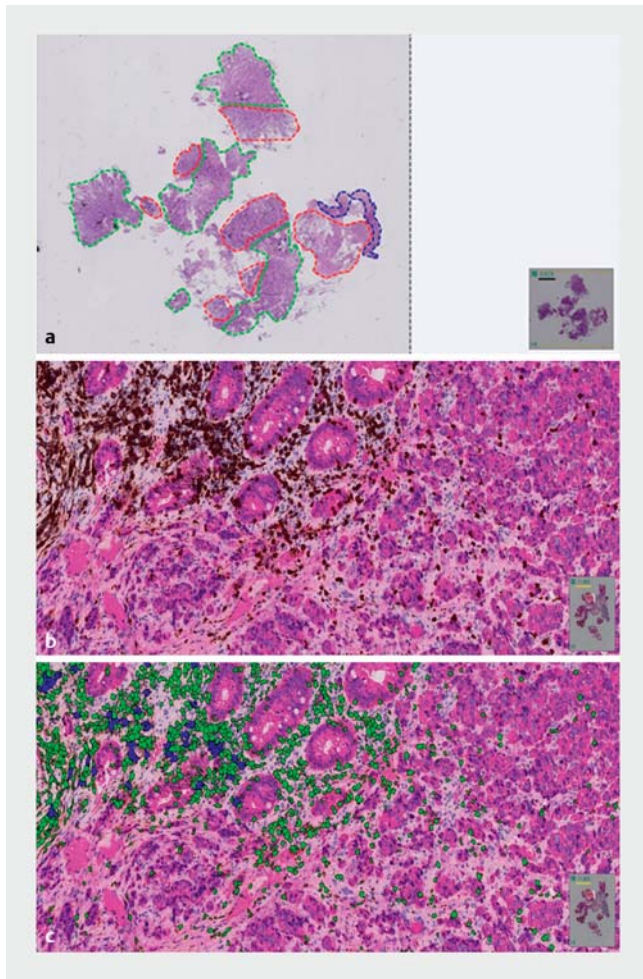
Identification of a potential tumor-specific immune response was performed through analysis of CD3- and CD8-positive lymphocytes. All slides were scanned using a Leica SCN400 slide scanner and subsequently the digital images were uploaded to Visiopharm Quantitative Digital Pathology software, version 2020.09 (Hoersholm, Denmark). For the CD3/cytokeratin- and CD8/cytokeratin-stained slides, an Application Protocol Package (APP) was developed for the quantitative analysis. The APP was built around a process consisting of several sequential steps. At first four separate regions of interest (ROI) was outlined on a HE-stained slide from each tissue block. The tissue was divided into compartments consisting of ulceration; granulation tissue; invasive cancer or areas suspicious of invasive cancer; and non-malignant colon mucosa. Next, the tissue align module was applied on serial sections stained with HE, CD3/cytokeratin and CD8/cytokeratin to ensure analyzing identical ROI. The quantitative analysis was conducted at 20 \times magnification. The defined output variables were area in mm² of each ROI, number of CD3- and CD8-positive cells and density of positive cells per mm² within the ROI, respectively. ► **Fig. 1** illustrates the process of the digital analysis.

Manual assessment of PD-L1 expression

Assessment was performed by a senior pathologist specialized in colorectal cancer. First, the PD-L1 expression was assessed manually on the blinded biopsies. Primary evaluation was performed at $\times 4/\times 10$ magnification to establish an overview, followed by $\times 20$ magnification for evaluation of tumor and immune cells. Convincing partial or complete linear membranous staining was required for classifying a tumor cell as positive. Convincing membranous and/or cytoplasmic staining were required for classifying an immune cell (lymphocytes and macrophages) as positive. Any degree of staining intensity counted as positive. The cellular localization (tumor cells; predominantly tumor cells; immune cells; predominantly immune cells; or an evenly distributed positive reaction between tumor cells and immune cells) and number of positive cells (none, few, moderate or high number of positive cells) was registered. Few positive cells were defined as “scattered positive,” whereas a high number was defined as clustered or bandlike arranged cells. Next, on the matched unblinded material, it was estimated if the number of PD-L1 positive cells had increased, decreased or was identical, before and after treatment.

Quantification of circulating cell-free DNA

Prior to cell-free DNA (cfDNA) purification, a 191-bp DNA spike-in fragment was added to the plasma [17]. Extraction of plasma cfDNA was performed using a Perkin Elmer Chemagic 360 Robot (Waltham, Massachusetts, United States), with a CMG-1304 kit according to the manufacturer’s recommendations. All samples were analyzed using digital droplet PCR (ddPCR)



► **Fig. 1** Illustrating the process of the digital analysis of CD3 and CD8. In this example CD3 is visualized. **a** Visualizing the process of marking different compartments off the tissue. Green marks normal tissue, red marks cancer, blue marks ulcerous tissue. **b** CD3. **c** CD3 labelled.

on a QX-200 system from Bio-Rad (Hercules, California, United States). Levels of spike-in control were measured together with levels of immunoglobulin gene rearrangement that was used as a control for potential contaminating lymphocyte DNA [17]. Further, a fragmentation ratio analysis was performed by measuring levels of 65 base pairs (bp) and 250 bp fragments of the EMC7 housekeeping gene [18]. The EMC7 65 bp assay was also used to quantify the total levels of cfDNA.

Radiological assessment

Evaluation of treatment response also included imaging of primary tumor and distant metastasis. For patients with a rectal tumor, thoraco-abdomino-pelvic computed tomography (CT) scans and rectal magnetic resonance imaging (MRI) were performed at baseline <1 month after initial treatment with calcium electroporation. Follow-up scans were performed at 4, 8, and 12 weeks and after 6 months to the extent possible. For patients with a colonic tumor, only CT scans were performed.

CT scans were performed with 80– to 100-mL IV contrast Iomeron 350 mg Iodine/mL.

The thoraco-abdomino-pelvic CT scans were performed using different CT scan systems; PHILIPS 64-slice Brilliance, PHILIPS iCT 256 slice, SIEMENS Force, SIEMENS Drive, SIEMENS Edge. Images were recorded 70 seconds after intravenous injection of 80 to 100 mL Iomeron 350 mg/mL (Bracco) given at an injection rate of 3 mL/second. No bowel preparation was used. However, oral administration of 1 L of water 15 minutes prior to the scan was used to delineate the small and large bowel. Images were analyzed in the Centricity Radiology Information System and Centricity Picture Archiving and Communications System (PACS–GE Healthcare) and interpreted on an Impax PACS workstation (GE Healthcare).

Scans were evaluated through standard evaluation and tumor T-stage was assessed by radiologists using the 8th version of the TNM classification system. Metastasis were evaluated according to RECIST 1.1 criteria [19]. Response criteria are defined as follows: complete response (CR) with disappearance of all lesions, partial response (PR) $\geq 30\%$ decrease in the sum of diameters of target lesions from baseline, stable disease (SD) neither CR, PR or progressive disease (PD) $\geq 20\%$ increase in the sum of diameters of target lesions from baseline.

MRI scans were primarily performed on a 3 T Siemens MAGNETOM Vida (70 cm). Two other MRI scans were used: 1.5 T Siemens MAGNETOM AvantoFit (60 cm) and 1.5 T Siemens MAGNETOM Aera (70 cm). MRI scans were performed using T2 sequences axial, coronal and sagittal to the tumor, and diffusion axial to the patient. Like CT, the MRI scans were evaluated through standard evaluation and tumor T-stage was assessed by radiologists using the 8th version of the TNM classification system.

Statistical analysis

Due to the small sample size of the study and the variability of time between available blood sample and tissue, no formal statistical tests were performed. The concentration of cfDNA at the various time points was plotted for each study participant. The density of CD3- and CD8-positive cells were calculated for each individual tissue compartment present in the biopsies and plotted at the various time points for each study participant.

Results

The study included six patients, five with rectal cancer and one patient with sigmoid colon cancer, from Zealand University Hospital, Denmark, from April 2018 to January 2020. Five male and one female patient aged 42 to 83 with WHO performance 0 to 2 were included in the study. Of the included patients, three had been undergoing systemic chemotherapy before entering the protocol. Patient characteristics are shown in ► **Table 1**.

A total of 10 procedures with calcium electroporation were performed. Of the six patients, three patients had a second treatment with calcium electroporation and one patient had three treatments. Patients no. 3 and 5 were offered additional treatments with a time interval of 4 weeks and patient no. 6 with a time interval of 3 weeks as requested by the patient. In

► **Table 1** Patient characteristics.

Pa-tient	Gen-der	Age	ASA	Perform-ance (WHO)	Tumor stage	Tumor length	Circumferential extent	Metasta-sis	Local symptoms	Previous treatment
1	M	82	2	1	T2N2M1	5 cm	Not passable with endoscope	Liver	Pain, bleed-ing, stenosis	None
2	M	80	2	1	T3N2M1	6 cm	Not passable with endoscope	Lymph node	Stenosis	Capecitabine + bevacizumab 14 cycles
3	M	83	2	2	T3N1M1	5 cm	>75%	Liver	Pain, bleed-ing, stenosis	None
4	M	49	1	0	T4N2M1	7 cm	100%	Liver	Bleeding, stenosis	FOLFIRI + pani-tuzumab 14 cycles and FOLFOX + bev-acizumab 7 cy-cles
5	F	42	2	0	T3N0M1	6 cm	>60%	Liver and lung	Diarrhea	FOLFIRI 11 cy-cles
6	M	69	2	0	T3N1M1	6 cm	>75%	Liver and lung	Stenosis, diarrhea	None

ASA, American Society of Anesthesiologists; WHO, World Health Organization; FOLFIRI, folinic acid, fluorouracil, irinotecan; FOLFOX, folinic acid, fluorouracil, oxaliplatin.

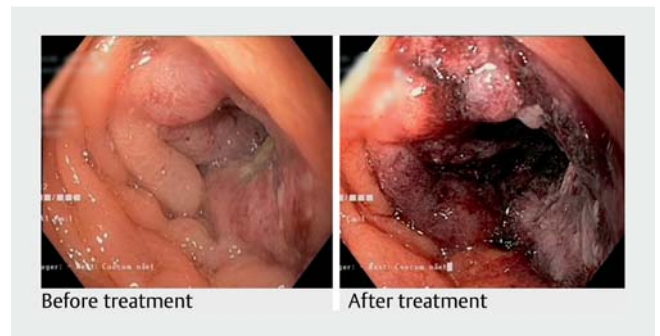
two patients, we were unable to deliver a second treatment due to insufficient bowel preparation.

Patients no. 2 and 5 were offered calcium electroporation as an additive treatment and continued systemic chemotherapy after the procedures. Patient no. 6 was followed with an interval of approximately 3 months from the initial treatment to first follow-up. Systemic chemotherapy was initiated 3 weeks after calcium electroporation and the patient requested a delay of an additional treatment.

Treatment procedure

The procedures were initiated with inspection and biopsies from the tumor area. In two cases (patients no. 1 and 2) the tumor was not passable with the endoscope; however, it was possible to treat the anal part of the tumor. In one case (patient no. 4) the tumor was passable with the endoscope; however, the area was narrow due to a circumferential extent of almost 100% and only approximately 50% of the tumor was accessible to the EndoVe device. In the final three cases, inspection found circumferential extent of >60% in one patient (no. 5) and >75% in two patients (no. 3 and 6). In the initial procedure, 75% of the tumor surface area was treated and at the additional treatment it was possible to cover 100% of the tumor surface area.

After inspection and evaluation of the tumor, calcium chloride was injected intratumorally. A median dose of 11 mL (range 3–13 mL) was administered. After injection of calcium chloride, the EndoVe device was attached to the endoscope and a median of eight series of pulses (range 3–13) were applied to the tumor area, with a median current (A) of 12 in all procedures (range 8–12). Immediately after the pulses were delivered, tumor tissue became pale and ischemic (► **Fig. 2**). Median proce-



► **Fig. 2** Images of a T2 tumor in the sigmoid colon before and immediately after treatment with calcium electroporation. Calcium was injected and thereafter pulses were applied consecutively to cover the tumor volume. After treatment, the tumor tissue became ischemic, whereas normal tissue was less affected by the treatment.

duration time from the patients were sedated to end of the procedure was 35 minutes (range 28–55 minutes). All patients were discharged approximately 1 hour after the treatment. All procedures were successful and no complications have been observed in relation to the procedures. For procedure-related characteristics, see ► **Table 2**.

Adverse events

No procedure-related serious AEs were reported. In two cases (patients no. 1 and 6), patients experienced fever and general malaise within the first 24 to 48 hours after treatment. In both cases, spontaneous recovery was seen after 24 hours.

► **Table 2** Procedure characteristics.

Patient	Endoscopy	Treatment	Calcium chloride (mL)	Series of pulses	Treated tumor surface	Treatment duration	Comments
1	1	1	3	5	>25%	55 min	Tumor not passable with the endoscope
1	2						Insufficient bowel preparation
2	1	1	5	3	>25%	28 min	Tumor not passable with the endoscope
2	2						Insufficient bowel preparation
3	1	1	10	7	>75%	30 min	
3	2	2	11	6	100%	30 min	
4	1	1	11	10	>50%	50 min	
5	1	1	13	8	>75%	28 min	
5	2	2	13	8	100%	25 min	
5	3	3	13	15	100%	50 min	
6	1	1	13	8	>75%	45 min	
6	2	2	13	8	100%	40 min	
6	3						No visible tumor

Pain score

Pain in relation to the study treatment and at follow-up was evaluated. A median NRS score of 0 (range 0–1) was reported at all time points (baseline, Day 1, Day 7, Week 4 and Week 8).

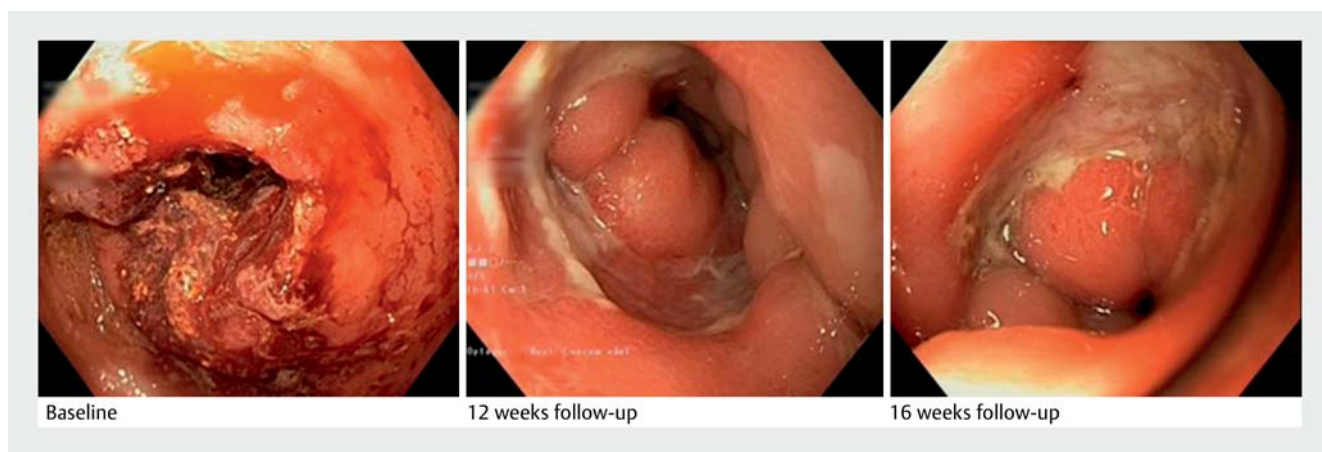
Response to treatment

After the initial treatment, five patients were followed with an endoscopic procedure, and one patient (no.4) was deemed unsuitable for an additional procedure due to comorbidity and tumor progression. At follow-up the tumor was evaluated by inspection. In four cases, PR was seen, with necrotic tumor tissue

and fibrin. Patient no.6 had clinical CR, with fibrin at the previous tumor site with no visible residual tumor tissue (► **Fig. 3**).

Symptom relief

Of the six patients, five reported symptom relief after study treatment. Patient no.1 with sigmoid colon cancer suffered from bleeding, pain, and obstruction prior to treatment and 2 days after treatment, the patient reported reduced pain, bleeding ceased and the obstruction was partially relieved. Five patients with a rectal tumor all suffered from stenosis. Of these, four patients reported partial relief of obstruction a few days after the initial treatment. Of the five patients with a rectal tu-



► **Fig. 3** Endoscopic images from a 62-year-old man with a rectal tumor. **a** Baseline image just before the initial treatment with calcium electroporation. **b** Follow-up 12 weeks after treatment showing fibrin and no visible tumor. **c** Follow-up 4 months after treatment showing normalization of treatment area.

► **Table 3** CT scans with evaluation of metastasis according to RECIST criteria.

Patient	Additional treatment	4 weeks	8 weeks	12 weeks	6 months
1	Capecitabine	SD	SD		
2		SD	PD		
3		SD	SD	SD	
4		PD			
5	FOLFIRI		SD	SD	SD
6	Capecitabine + bevacizumab			PR	PR (liver)/CR (lung)

CT, computed tomography; RECIST, Response Evaluation Criteria in Solid Tumours; FOLFIRI, folinic acid, fluorouracil, irinotecan; SD, stable disease; PD, progressive disease; PR, partial response; CR, complete response.

mor, three suffered from malignant bleeding. Of these, two patients (no. 1 and 3) reported that the bleeding ceased within a few days after treatment. One patient (no. 4) did not report symptom relief after treatment.

Radiologic evaluation

All patients were evaluated with CT scans and metastases were evaluated according to RECIST 1.1 criteria. Patients with rectal cancer were also evaluated with MRI of the primary tumor.

MRI was performed on five patients. In three patients, MRI found reduced tumor size of 1, 1.5 and 2 cm, respectively. In one patient, tumor size increased by 1 cm. Patient no. 6 was unable to cooperate for a baseline MRI; however, an MRI was performed at the final follow-up visit. This patient had macroscopic CR and MRI showed a residual tumor lesion consisting of primarily fibrosis and edema.

RECIST 1.1 evaluation of metastasis found stable disease in three patients and progression of metastasis in two patients (► **Table 3**). Complete regression of lung metastasis and PR of liver metastasis and rectal tumor were found in patient no. 6 (► **Fig. 4**).

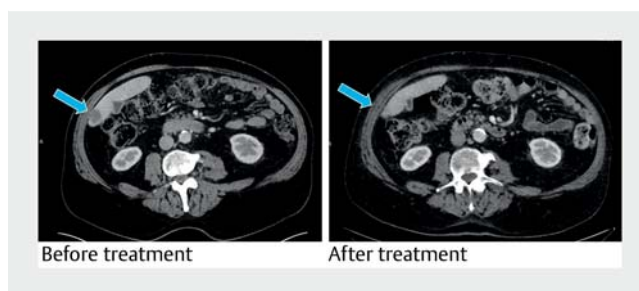
Cell-free DNA

The concentration of cfDNA in alleles per mL is shown in **Supplementary 2**. Based on the visualization, there are no clear patterns of changes in cfDNA concentration over time.

Pathological evaluation

Qualitative pathological evaluation

Baseline biopsies were compared with follow-up biopsies by a gastrointestinal pathologist. In patients no. 1, 2, 3 and 5, no clear changes in tissue morphology were seen. In patient no. 6, baseline samples showed adenocarcinoma, ulcerous tissue and granulation tissue. At follow-up, multiple biopsies were collected. Follow-up biopsies after 12 weeks showed granulation tissue and ulcerous tissue and no residual adenocarcinoma. At 4-month follow-up biopsies, only granulation tissue persisted. Patient no. 4 had no follow-up biopsies collected.



► **Fig. 4** CT scans at baseline and 12-week follow-up in patient no. 6 showing regression of liver metastasis. The patient had complete regression of lung metastasis and partial response of liver metastasis. The patient received systemic chemotherapy during the period from calcium electroporation to follow-up.

Quantitative analysis of CD3- and CD8-positive cells

The densities of CD3 and CD8 in each tissue compartment of the biopsies are shown in **Supplementary 3** and **Supplementary 4**. The visualization of each individual patient shows that CD3 and CD8 density follow the same trend across tissue compartments. Overall, based on the visualization, no clear trend of changes in the density appeared over time.

PD-L1 evaluation

PD-L1-positive cells were seen in all baseline samples and for all patients the expression was primarily located in the immune cells. In patients no. 1 and 3, few positive cells were present, while patients no. 4 and 5 had a moderate number of positive cells and only in patient no. 2 a high number of PD-L1-positive cells were present. Patient no. 4 had no follow-up biopsies collected. Patient no. 6 had no residual tumor cells in the follow-up samples and was excluded from analysis. No clear trend was found when we compared baseline samples with follow-up samples.

Discussion

This study is the first-in-human clinical study to investigate calcium electroporation for colorectal cancer and we found that the treatment is safe and feasible. Furthermore, clinical response and symptom relief are indicated. An endoscopic device

(EndoVE) enabled electroporation-based treatments in the gastrointestinal tract. The EndoVE device has been proven safe in clinical trials investigating electrochemotherapy with bleomycin for esophageal cancer and advanced colorectal cancer [20–23].

Endoscopic calcium electroporation was found to be a safe and feasible outpatient procedure, with limited side effects. A total of six patients were included in the study and a total of 10 procedures with calcium electroporation were performed. The patients reported symptoms including pain, malignant bleeding and stenosis before entering the protocol. After the initial procedure with calcium electroporation, five patients reported symptom relief. In all cases, palliative relief was achieved within a few days.

Treatment response was evaluated through imaging and biopsies. Evaluation found stable disease in three patients and progression in two. The final patient was treated with calcium electroporation followed by systemic chemotherapy, and CT scans showed complete regression of lung metastasis and partial response in liver metastasis. In addition, pathological evaluation of biopsies from follow-up colonoscopies found no residual adenocarcinoma after calcium electroporation.

Of the included patients, three suffered from hemorrhage from their malignant tumors prior to the treatment. All patients reported symptom relief within a few days. These findings correlate with previous evidence showing an anti-vascular effect of calcium electroporation. A previous study found that calcium electroporation suppressed the ability of the endothelial cells to migrate and form capillary-like structures [24]. Interestingly, evidence suggests that calcium electroporation induces ATP loss and necrosis of cancer cells, whereas normal tissue tolerates the treatment [2]. This correlates with the findings of this study, showing pale and ischemic tumor tissue immediately after the electrical pulses were applied, whereas normal tissue was less affected by the treatment.

The study was limited by the small number of patients. Furthermore, the group was heterogenic as these fragile patients could not attend all follow-up visits. Histopathological examination of immune cell infiltration and necrosis was performed, and no statistically significant signal in tumor-related immune infiltration or in tissue morphology was seen. In addition, a number of patients received systemic chemotherapy before or after calcium electroporation, and as such, the isolated effects of calcium electroporation are difficult to determine. The reported tumor responses may, in fact, be due to a multimodal treatment rather than calcium electroporation alone.

This first-in-human clinical trial found calcium electroporation to be an efficient palliative treatment option for this patient group. The treatment was performed as an outpatient procedure, and in most cases, an enema was sufficient as bowel preparation. Calcium electroporation offers an alternative treatment where symptom palliation is needed and can be offered in addition to chemotherapy. The procedure is, however, limited as treatment is dependent on the endoscopic device to reach and cover the entire tumor surface area, which is not always possible.

Previous studies have found endoscopic electrochemotherapy with systemically administered bleomycin to be a safe and feasible procedure with promising results [20–22]. However, the use of bleomycin is limited due to risk of interstitial pulmonary fibrosis. In contrast, calcium chloride is injected locally and may be associated with a lower risk of side effects. Based on the current data, we expect electrochemotherapy and calcium electroporation to have comparable anticancer effects [7, 8, 11, 12, 23]; however, there are currently no studies comparing endoscopic electrochemotherapy with calcium electroporation for colorectal cancer.

Conclusions

In conclusion, endoscopic calcium electroporation is a safe and feasible treatment for colorectal cancer and could be of great value for patients with limited treatment options.

Acknowledgements

This study was funded by the Danish Cancer Society (R110-A6996) and the Enhanced perioperative oncology (EPEONC) consortium, Zealand University Hospital.

Competing interests

The authors declare that they have no conflict of interest.

Funding

Enhanced perioperative oncology (EPEONC) consortium
Kræftens Bekæmpelse <http://dx.doi.org/10.13039/100008363>
R110-A6996

Clinical trial

ClinicalTrials.gov (<http://www.clinicaltrials.gov/>)
NCT03542214
TRIAL REGISTRATION: Prospective trial NCT03542214 at ClinicalTrials.gov (<http://www.clinicaltrials.gov/>)

References

- [1] Gehl J. Electroporation: theory and methods, perspectives for drug delivery, gene therapy and research. *Acta Physiol Scand* 2003; 177: 437–447
- [2] Frandsen SK, Vissing M, Gehl J. A comprehensive review of calcium electroporation - a novel cancer treatment modality. *Cancers* 2020; 12: 290
- [3] Frandsen SK, Gissel H, Hojman P et al. Direct therapeutic applications of calcium electroporation to effectively induce tumor necrosis. *Cancer Res* 2012; 72: 1336–1341
- [4] Frandsen SK, Krüger MB, Mangalanathan UM et al. Normal and malignant cells exhibit differential responses to calcium electroporation. *Cancer Res* 2017; 77: 4389–4401

- [5] Falk H, Forde PF, Bay ML et al. Calcium electroporation induces tumor eradication, long-lasting immunity and cytokine responses in the CT26 colon cancer mouse model. *Oncoimmunology* 2017; 6: e1301332
- [6] Frandsen SK, Gehl J. A Review on differences in effects on normal and malignant cells and tissues to electroporation-based therapies: a focus on calcium electroporation. *Technol Cancer Res Treat* 2018; 17: doi:10.1177/1533033818788077
- [7] Hoejholt KL, Mužić T, Jensen SD et al. Calcium electroporation and electrochemotherapy for cancer treatment: Importance of cell membrane composition investigated by lipidomics, calorimetry and in vitro efficacy. *Sci Rep* 2019; 9: 4758
- [8] Frandsen SK, Gissel H, Hojman P et al. Calcium electroporation in three cell lines: a comparison of bleomycin and calcium, calcium compounds, and pulsing conditions. *Biochim Biophys Acta* 2014; 1840: 1204–1208
- [9] Hansen EL, Sozer EB, Romeo S et al. Dose-Dependent ATP depletion and cancer cell death following calcium electroporation, relative effect of calcium concentration and electric field strength. *PLoS One* 2015; 10: e0122973
- [10] Szweczyk A, Gehl J, Daczewska M et al. Calcium electroporation for treatment of sarcoma in preclinical studies. *Oncotarget* 2018; 9: 11604–11618
- [11] Falk H, Matthiessen LW, Wooler G et al. Calcium electroporation for treatment of cutaneous metastases; a randomized double-blinded phase II study, comparing the effect of calcium electroporation with electrochemotherapy. *Acta Oncol* 2018; 57: 311–319
- [12] Falk H, Lambaa S, Johannesen HH et al. Electrochemotherapy and calcium electroporation inducing a systemic immune response with local and distant remission of tumors in a patient with malignant melanoma – a case report. *Acta Oncol* 2017; 56: 1126–1131
- [13] Ágoston D, Baltás E, Ócsai H et al. Evaluation of calcium electroporation for the treatment of cutaneous metastases: a double blinded randomised controlled phase II trial. *Cancers (Basel)* 2020; 12: 179
- [14] Plaschke CC, Gehl J, Johannesen HH et al. Calcium electroporation for recurrent head and neck cancer: A clinical phase I study. *Laryngoscope Investig Otolaryngol* 2019; 4: 49–56
- [15] Frandsen SK, Gibot L, Madi M et al. Calcium electroporation: evidence for differential effects in normal and malignant cell lines, evaluated in a 3D spheroid model. *PLoS One* 2015; 10: e0144028
- [16] Røge R, Vyberg M, Nielsen S. Accurate PD-L1 protocols for non-small cell lung cancer can be developed for automated staining platforms with clone 22C3. *Appl Immunohistochem Mol Morphol* 2017; 25: 381–385
- [17] Pallisgaard N, Spindler KLG, Andersen RF et al. Controls to validate plasma samples for cell free DNA quantification. *Clin Chim Acta* 2015; 446: 141–146
- [18] Lefèvre AC, Pallisgaard N, Kronborg C et al. The clinical value of measuring circulating HPV DNA during chemo-radiotherapy in squamous cell carcinoma of the anus. *Cancers (Basel)* 2021; 13: 2451
- [19] Lalchandani UR, Sahai V, Hersberger K et al. A Radiologist's Guide to Response Evaluation Criteria in Solid Tumors. *Curr Probl Diagn Radiol* 2019; 48: 576–585
- [20] Falk Hansen H, Bourke M, Stigaard T et al. Electrochemotherapy for colorectal cancer using endoscopic electroporation: a phase 1 clinical study. *Endosc Int Open* 2020; 8: E124–E132
- [21] Egeland C, Baeksgaard L, Johannesen HH et al. Endoscopic electrochemotherapy for esophageal cancer: a phase I clinical study. *Endosc Int Open* 2018; 6: E727–E34
- [22] Schipilliti FM, Onorato M, Arrivi G et al. Electrochemotherapy for solid tumors: literature review and presentation of a novel endoscopic approach. *Radiol Oncol* 2022; 56: 285–291
- [23] Egeland C, Baeksgaard L, Gehl J et al. Palliative treatment of esophageal cancer using calcium electroporation. *Cancers (Basel)* 2022; 14: 5283
- [24] Staresinic B, Jesenko T, Kamensek U et al. Effect of calcium electroporation on tumour vasculature. *Sci Rep* 2018; 8: 9412