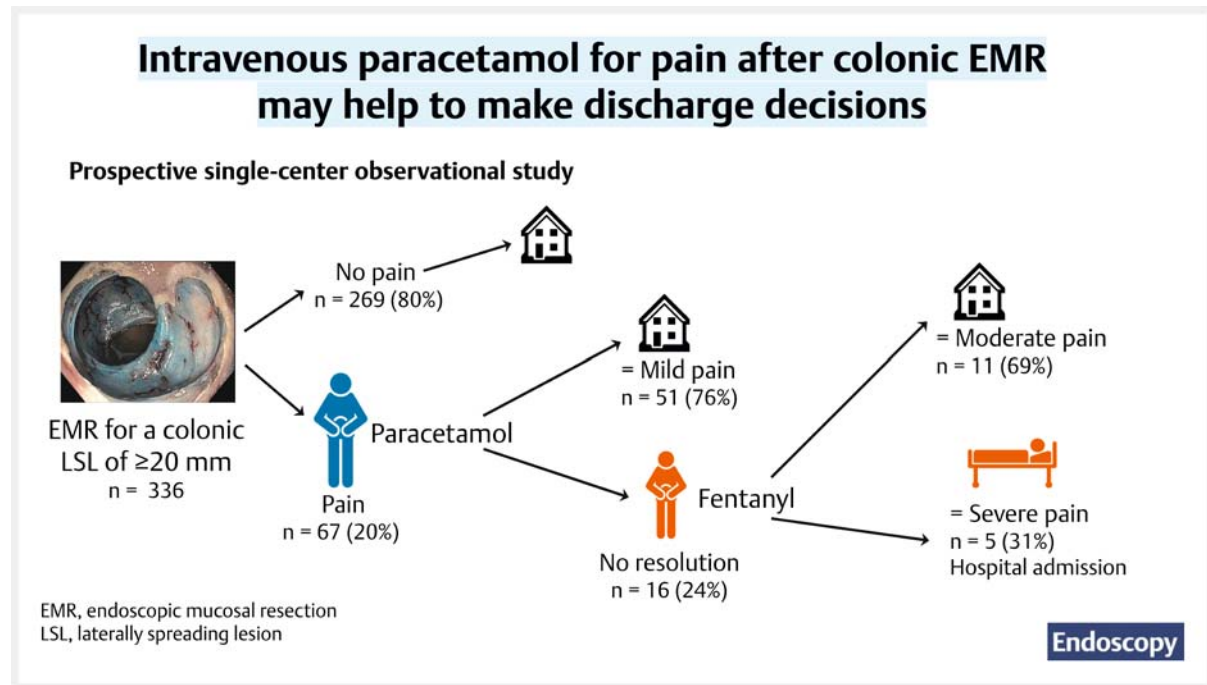





Intravenous paracetamol for persistent pain after endoscopic mucosal resection discriminates patients at risk of adverse events and those who can be safely discharged

GRAPHICAL ABSTRACT



Authors

Lobke Desomer^{1,2,3,‡}, David J. Tate^{1,3,4,‡} , Leshni Pillay¹, Halim Awadie¹ , Mayenaaz Sidhu¹, Golo Ahlenstiel¹ , Michael J. Bourke^{1,4}

Institutions

- 1 Department of Gastroenterology and Hepatology, Westmead Hospital, Sydney, New South Wales, Australia
- 2 Department of Gastroenterology and Hepatology, AZ Delta Hospital, Roeselare, Belgium
- 3 Department of Gastroenterology and Hepatology, University Hospital of Ghent, Ghent, Belgium
- 4 Westmead Clinical School, University of Sydney, Sydney, New South Wales, Australia

submitted 18.8.2020

accepted after revision 30.1.2023

accepted manuscript online 30.1.2023

published online 17.4.2023

Bibliography

Endoscopy 2023; 55: 611–619

DOI 10.1055/a-2022-6530

ISSN 0013-726X

© 2023. Thieme. All rights reserved.

Georg Thieme Verlag KG, Rüdigerstraße 14,
70469 Stuttgart, Germany

 Table 1 s

Supplementary material is available under
<https://doi.org/10.1055/a-2022-6530>

Corresponding author

Michael Bourke, MD, Department of Gastroenterology and Hepatology, Westmead Hospital, Suite 106a, 151–155 Hawkesbury Road, Westmead, NSW 2145, Australia
michael@citywestgastro.com.au

ABSTRACT

Introduction The frequency and severity of abdominal pain after endoscopic mucosal resection (EMR) of colonic laterally spreading lesions (LSLs) of ≥ 20 mm is unknown, as are the risk factors to predict its occurrence. We aimed to

[‡] Joint first authors

prospectively characterize pain after colonic EMR, determine the rapidity and frequency of its resolution after analgesia, and estimate the frequency of needing further intervention.

Methods Procedural and lesion data on consecutive patients with LSLs who underwent EMR at a single tertiary referral center were prospectively collected. If pain after colonic EMR, graded using a visual analogue scale (VAS), lasted >5 minutes, 1 g of paracetamol was administered. Pain lasting >30 minutes lead to clinical review and upgrade to opiate analgesics. Investigations and interventions for pain were recorded.

Results 67/336 patients (19.9%, 95%CI 16.0%–24.5%) experienced pain after colonic EMR (median VAS 5, interquartile range 3–7). Multivariable predictors of pain were: lesion size ≥ 40 mm, odds ratio [OR] 2.15 (95%CI 1.22–3.80); fe-

male sex, OR 1.99 (95%CI 1.14–3.48); and intraprocedural bleeding requiring endoscopic control, OR 1.77 (95%CI 0.99–3.16). Of 67 patients with pain, 51 (76.1%, 95%CI 64.7%–84.7%) had resolution of their “mild pain” after paracetamol and were discharged without sequelae. The remaining 16 (23.9%) required opiate analgesia (fentanyl), after which 11/16 patients (68.8%; “moderate pain”) could be discharged. The 5/67 patients (7.5%) with “severe pain” had no resolution despite fentanyl; all settled during hospital admission (median duration 2 days), intravenous analgesia, and antibiotics.

Conclusion Pain after colonic EMR occurs in approximately 20% of patients and resolves rapidly and completely in the majority with administration of intravenous paracetamol. Pain despite opiates heralds a more serious scenario and further investigation should be considered.

Introduction

Endoscopic mucosal resection (EMR) is accepted as the first-line technique to remove large (≥ 20 mm) laterally spreading lesions (LSLs) of the colorectum [1–4]. Neither the frequency nor severity of pain after EMR is well understood and no risk factors have been identified to predict its occurrence.

In contrast, perioperative analgesia in colonic surgery is well-defined, with a structured evidence-based approach to pain covering the entire perioperative period [5]. The specific goals of perioperative analgesia are to provide sufficient pain relief, allowing early mobilization, bowel function, and feeding, and to be devoid of complications.

Pain after colonic EMR is not infrequent; however, it has yet to be subjected to systemic study. Transmural thermal injury with consequent local peritoneal inflammation is one such cause [6]. Historically, this has been termed post-polypectomy syndrome. Other causes of pain after colonic EMR may include transmural injection during EMR, abdominal distension (nowadays less frequent owing to the widespread use of carbon dioxide [7, 8]), and urinary retention [9]. Pain after colonic EMR may be accompanied by a significant inflammatory response mandating hospital admission. EMR-related perforation is always a possibility, although the risk of this can be mitigated by systematic examination of the EMR defect for deep injury [10]. Clearly the ability to discriminate between these scenarios is clinically important and has financial and resource implications for patients and healthcare systems.

The ideal treatment for pain after colonic EMR should be safe and widely available, with a rapid onset, without clouding the clinical picture or mandating hospital admission owing to side effects. Paracetamol is a vital component of analgesia in post-surgical patients [5]. The peak effect of intravenous (IV) paracetamol is generally reached at the end of a 15-minute infusion. It has been shown to provide a 16% reduction in the requirement for opioid analgesics after abdominal surgery [11]. It is safe, inexpensive, and widely available. It therefore seems to be a logi-

cal drug of choice for the treatment of pain after colonic EMR, given that EMR is commonly performed as a day-case procedure [12].

In this study, we aimed to determine the frequency and characteristics of pain after colonic EMR, the risk factors for its occurrence, and the efficacy of IV paracetamol as a discriminant between benign and more sinister causes of pain after colonic EMR.

Methods

Inclusion criteria

Consecutive patients with an LSL of ≥ 20 mm who were referred for EMR at a single tertiary referral center were eligible for inclusion in this study. All patients gave written informed consent and institutional review board approval was obtained.

Technical aspects

Patients were sedated during the procedure using propofol, after midazolam and fentanyl had been given at the start of the procedure. Paracetamol was not administered intraprocedurally. Antibiotics were not routinely administered, except in specific cases (lesions at the distal rectum and anorectal junction [8]). All colonoscopies were performed using high definition 180 or 190 series CF or PCF colonoscopes (Olympus, Tokyo, Japan). Insufflation with carbon dioxide was used in all cases. The submucosal injectate consisted of a succinylated gelatin (Gelofusin; B. Braun Australia Pty Ltd, Bella Vista, Australia), adrenaline (1:100 000), and indigo carmine blue (80 mg/500 mL) solution in every patient. Resection was predominantly performed with braided snares (Olympus SnareMaster; 15 mm) or, in fewer cases, a monofilament snare (Captivator II; Boston Scientific, Massachusetts, USA). A microprocessor-controlled electrosurgical generator with fractionated current was used (Endocut Q, effect 2, 30 W; ERBE Elektromedizin, Tübingen, Germany).

EMR was performed according to a previously described technique [4, 13]. ► **Fig. 1** illustrates a typical procedure. Patient and lesion characteristics and periprocedural data were prospectively collected. Successful EMR described the complete resection of the LSL in a single session. The “Deep Mural Injury” (DMI) classification [10] was used to assess the post-EMR defect prior to removing the colonoscope, and clips were placed if a DMI score >1 was observed.

Standard protocol post-EMR at this center.

Standard post-EMR care included 2 hours of continuous monitoring of the patients’ vital parameters in first-stage recovery. If their parameters were stable and in the absence of pain or other symptoms, patients were allowed to step-down to second-stage recovery for 1 hour, where clear fluids were given. Patients were discharged thereafter if they were pain-free and had tolerated clear fluids ► **Fig. 2**). Extended recovery meant a duration of more than 2 hours spent in first-stage recovery or transfer back from second-stage to first-stage recovery because of pain or other symptoms.

The degree of pain was graded in first-stage recovery by asking the patient to report their pain from 0 to 10 using a visual analogue scale (VAS) [14, 15]. The VAS is a validated and easily administered tool that requires no reading or other capabilities of the patient. Nurses in first-stage recovery used a standard post-EMR assessment sheet to record their evaluation of all patients and performed observations every 5 minutes. If pain was reported (VAS>0) and lasted for longer than 5 minutes, it was

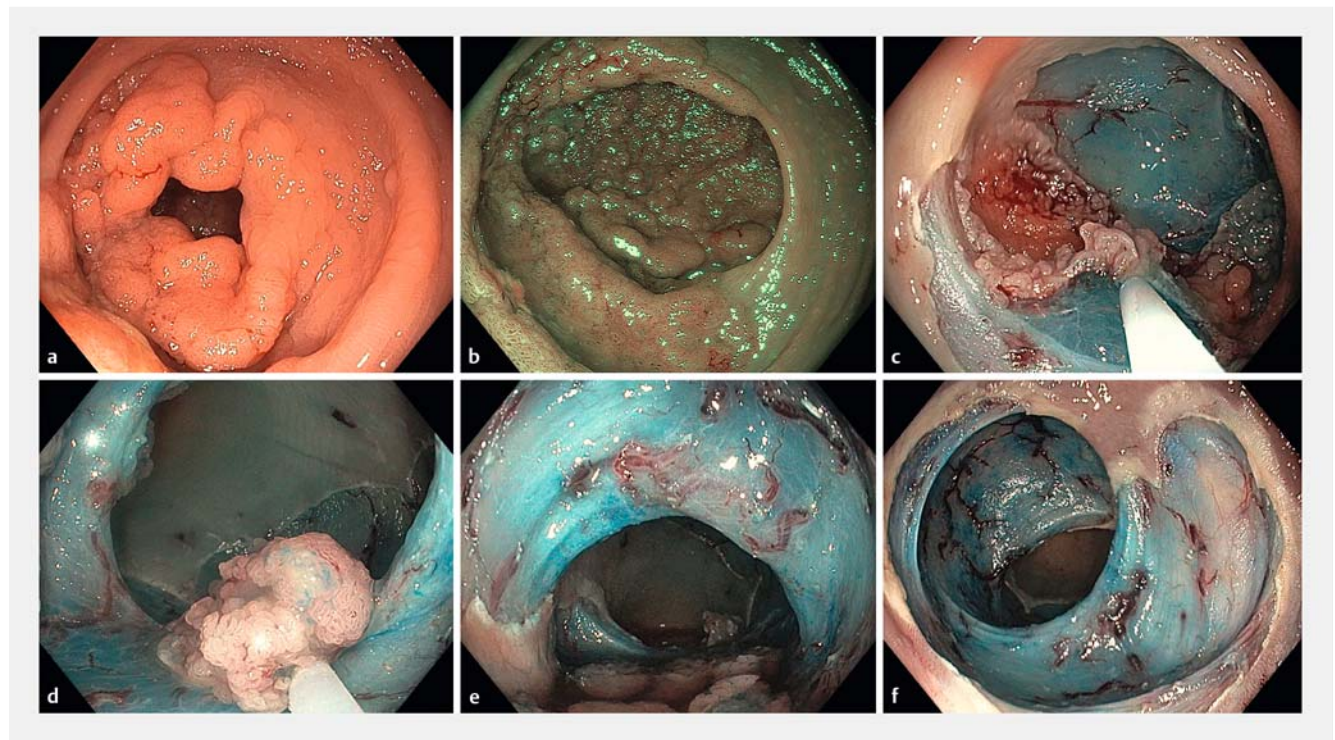
classified as pain after colonic EMR and medical review by the endoscopy team was performed. If no major concerns were identified, 1g of paracetamol was administered parenterally and the patient’s vital signs were monitored every 5 minutes. If the pain settled, with a decrease of the VAS to 0 or 1, this was labelled as “mild pain” and the patient was transferred to second-stage recovery after further medical review and approval. After 4 hours observation and if they were well, patients were subsequently discharged on a clear-fluid diet overnight.

Pain after colonic EMR persisting for >30 minutes despite parenteral paracetamol triggered another medical review and usually an escalation of analgesia, with fentanyl at a starting dose of 25µg, up to a maximum of 100µg. Pain after colonic EMR that settled after the administration of fentanyl was labelled as “moderate”; all other persistent pain after colonic EMR was labelled as “severe.” Investigations, admission, and interventions for pain were recorded prospectively.

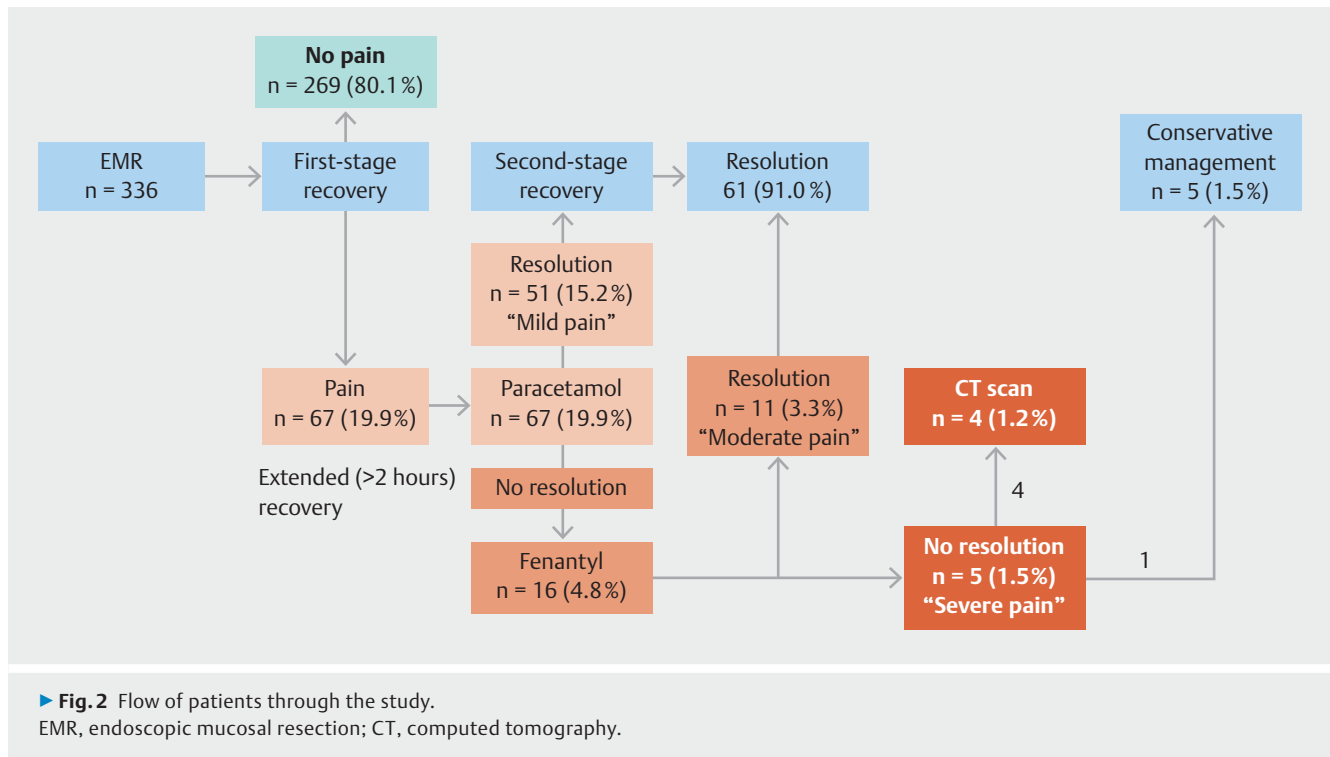
At 2 weeks after the procedure, patients were contacted by a study coordinator and underwent a structured telephone interview to identify periprocedural adverse events, including clinically significant post-EMR bleeding (CSPEB) and delayed perforation. CSPEB is described as bleeding needing re-admission, re-intervention, and/or the transfusion of packed red cells.

Study end points

The primary end point of this observational study was to determine the frequency of pain after colonic EMR.



► **Fig. 1** Endoscopic images of endoscopic mucosal resection (EMR) of a very large, near-circumferential laterally spreading lesion in the rectum, with snare-tip soft coagulation having been applied to the defect margin to prevent adenoma recurrence during surveillance. Larger lesions such as this were found to be associated with persistent pain after EMR in this study.



The secondary end points were: (i) to determine patient, procedural, and lesion factors that were predictive of pain after colonic EMR; (ii) to describe the evolution of pain after the administration of parenteral paracetamol and the frequency of further intervention (analgesic or otherwise) being required.

Statistical analysis

Patients with multiple LSLs resected during a single session were excluded owing to the difficulty attributing the primary end point to a specific lesion and the risk of correlated observations within a single patient.

Categorical variables were compared using the chi-squared test; for those where there were very few individuals in some of the categories, Fisher's exact test was used. Continuous variables were analyzed using either Student's *t* test (two-tailed) or Mann-Whitney *U* test. If categorized, continuous data were described using the median value. Univariable analyses were deemed significant if the *P* value was <0.05. Multivariable analysis was performed using binomial logistic regression of all univariable predictors significant to *P*<0.10, and the outcomes were described using odds ratios (ORs).

The study data were analyzed using SPSS statistics 23 (IBM, Armonk, New York, USA). All authors had access to the study data and reviewed the final manuscript.

Results

From August 2015 until May 2018, 550 patients with 601 LSLs (≥ 20 mm) underwent EMR at a single center. Of these, 509 patients had a single lesion and were eligible for inclusion in the study; 41 patients had multiple lesions (34 had two lesions, 4

had three lesions, and 3 patients had four lesions) and were excluded. There were 173 patients who did not consent to data collection for this specific study. After the above exclusions, 336 patients with 336 lesions were included in the study and their data were analyzed.

Baseline characteristics of included patients and their lesions

The mean age of all patients at the time of the EMR procedure was 68.9 years (SD 10.4) and 176 patients (52.4%) were men (► **Table 1**). The median lesion size was 35 mm (interquartile range [IQR] 20 mm), with 55.4% being located in the right colon (hepatic flexure and proximal), and the majority having Paris 0-IIa (54.2%), granular morphology (65.2%), and being tubulovillous adenomas (64.6%) with low grade dysplasia (71.1%) at final histopathology.

Nature and frequency of persistent pain post-EMR

Of the 336 patients, 67 (19.9%, 95%CI 16.0%–24.5%) experienced pain after colonic EMR and were administered IV paracetamol (► **Table 2**). The median (IQR) VAS score at the onset of pain was 5 (3–7). A median (IQR) decrease in VAS of 4 (3–5) was described after the administration of paracetamol, with a median (IQR) time to resolution (VAS<2) of 25 (10–48) minutes (► **Table 3**). Of the 67 patients with pain, 51 (76.1%, 95% CI 64.7%–84.7%) with "mild pain" experienced complete resolution of their pain with IV paracetamol and were discharged to second-stage recovery, although 4/51 (7.8%) required an extended stay in first-stage recovery. The flow through the study is displayed in ► **Fig. 2**.

► **Table 1** Comparison of patients who did and did not experience persistent post-procedural pain, and factors associated with the development of pain.

	No pain (n=269)	Pain (n=67)	Total (n=336)	P value		Odds ratio (95%CI)
				Uni- variable	Multi- variable ¹	
Baseline characteristics						
▪ Age, mean (SD), years	68.9 (10.6)	68.9 (10.0)	68.9 (10.4)	0.99		
▪ Sex, female, n (%)	120 (44.6)	40 (59.7)	160 (47.6)	0.03	0.02	1.99 (1.14–3.48)
Lesion characteristics						
Size, n (%), mm				0.002	0.008	2.15 (1.22–3.80)
▪ 20–39	160 (59.5)	26 (38.8)	186 (55.4)			
▪ ≥40	109 (40.5)	41 (61.2)	150 (44.6)			
Location, n (%)				0.57	NS	
▪ Right colon ²	151 (56.1)	35 (52.2)	186 (55.4)			
Paris classification, n (%)				0.11		
▪ 0-Is	32 (11.9)	5 (7.5)	37 (11.0)			
▪ 0-IIa	149 (55.4)	33 (49.3)	182 (54.2)			
▪ 0-IIa + Is	70 (26.0)	27 (40.3)	97 (28.9)			
▪ Others	18 (6.7)	2 (3.0)	20 (6.0)			
Morphology, n (%)				0.24		
▪ Granular	167 (62.1)	52 (77.6)	219 (65.2)			
▪ Nongranular	73 (27.1)	11 (16.4)	84 (25.0)			
▪ Mixed	12 (4.5)	2 (3.0)	14 (4.2)			
▪ Serrated	15 (5.6)	2 (3.0)	17 (5.1)			
▪ Unable to classify	2 (0.7)	0 (0)	2 (0.6)			
Kudo classification, n (%)				0.47		
▪ II	19 (7.1)	2 (3.0)	21 (6.3)			
▪ III	59 (21.9)	12 (17.9)	71 (21.1)			
▪ IV	182 (67.7)	52 (77.6)	234 (69.6)			
▪ V	9 (3.3)	1 (1.5)	10 (3.0)			
Successful EMR, n (%)	256 (95.2)	60 (89.6)	316 (94.0)	0.09	NS	
STSC to the margin, n (%)	180 (66.9)	39 (58.2)	219 (65.2)	0.18		
Procedural data						
Submucosal fibrosis, n (%)	88 (32.7)	17 (25.4)	105 (31.3)	0.25	NS	
Procedure duration, mean (SD), minutes	30 (23.0)	35 (28.0)	30 (22.5)	0.16		
Intraprocedural bleeding requiring endoscopic control, n (%)	102 (37.9)	35 (52.2)	137 (40.8)	0.03	0.05	1.77 (0.99–3.16)
Major deep mural injury (type III/IV), n (%)	5 (1.9)	1 (1.5)	6 (1.8)	>0.99	NS	
Clip placement, n (%)	67 (24.9)	13 (19.4)	80 (23.8)	0.34		

► **Table 1** (Continuation)

	No pain (n = 269)	Pain (n = 67)	Total (n = 336)	P value		Odds ratio (95%CI)
				Uni- variable	Multi- variable ¹	
Histopathology data						
Histopathology, n (%)				0.85		
▪ Tubular adenoma	58 (21.6)	15 (22.4)	73 (21.7)			
▪ Tubulovillous adenoma	172 (63.9)	45 (67.2)	217 (64.6)			
▪ Sessile serrated adenoma	35 (13.0)	6 (9.0)	41 (12.2)			
▪ Other	4 (1.5)	1 (1.5)	5 (1.5)			
Highest grade of dysplasia, n (%)				0.65		
▪ None	29 (10.8)	5 (7.5)	34 (10.1)			
▪ Low grade	191 (71.0)	48 (71.6)	239 (71.1)			
▪ Focal high grade	40 (14.9)	10 (14.9)	50 (14.9)			
▪ Diffuse high grade	9 (3.3)	4 (6.0)	13 (3.9)			
Invasive cancer, n (%)	14 (5.2)	5 (7.5)	19 (5.7)	0.55		
Post-procedure data						
CSPEB, n (%)	17 (6.3)	7 (10.4)	24 (7.1)	0.29		
Delayed perforation, n (%)	0 (0)	1 (1.5)	1 (0.3)	0.20		
Surgical referral by 2 weeks, n (%)	13 (4.8)	7 (10.4)	20 (6.0)	0.09		
EMR, endoscopic mucosal resection; STSC, snare-tip soft coagulation; CSPEB, clinically significant post-EMR bleeding						
¹ Multivariable model terms designated as NS (nonsignificant) or given with P value and odds ratio if retained in the model.						
² Hepatic flexure and proximal.						

► **Table 2** Management by degree of pain after colonic endoscopic mucosal resection and associated factors.

	Mild	Moderate	Severe	All
Number of patients (%) [95%CI]	51 (76.1) [64.7–84.7]	11 (16.4) [9.4–27.1]	5 (7.5) [3.2–16.3]	67/336 (19.9) [16.0–24.5]
Administered paracetamol IV, n (%)	51 (100)	11 (100)	5 (100)	67/67 (100)
Administered fentanyl IV, n (%) ¹	0	11 (100)	5 (100)	15/67 (100)
Dose of fentanyl, median (IQR), µg	0	25 (25)	25 (50)	25 (25)
CT scan, n (%)	0	0	4 (80.0)	4/67 (6.0)
Delayed perforation, n (%)	0	0	1 (20.0)	1/67 (1.5)
Associated factors				
LSL size, median (IQR), mm	40 (20)	50 (25)	45 (38)	40 (20)
Sex, female, n (%)	27 (52.9)	9 (81.8)	4 (80.0)	40/67 (59.7)
IPB, n (%)	28 (54.9)	3 (27.3)	4 (80.0)	35/67 (52.2)
IQR, interquartile range; CT, computed tomography; LSL, laterally spreading colonic lesion ≥20 mm; IPB, intraprocedural bleeding requiring endoscopic control.				
¹ Administration after procedure.				

► **Table 3** Further data relating to the 67 patients who experienced pain post-endoscopic mucosal resection.

Prior medication dosing	
Anesthetist managed procedure, n (%)	5 (7.5%)
Received paracetamol (pre-recovery), n (%)	0 (0%)
Use of propofol as sedative, n (%)	67 (100%)
Pain characteristics	
VAS at entry to recovery, median (IQR)	0 (0–2)
Duration of pain, median (IQR), minutes	25 (10–48)
VAS at onset of pain, median (IQR)	5 (3–7)
Decrease in VAS after paracetamol, median (IQR)	4 (3–5)
VAS at exit from first-stage recovery, median (IQR)	0 (0–1)
Extended recovery (longer than 2 hours in first-stage recovery), n (%)	20 (29.9%)
Need for fentanyl, n (%)	16 (23.9%)
Dose of fentanyl, median (IQR), µg	25 (25–50)
Admission due to pain, n (%)	5 (7.5%)
Further investigation with CT scan, n (%)	4 (6.0%)
Need for surgery, n (%)	0 (0%)
Length of stay, median (IQR), days	2 (1–5.5)

Predictors of pain after colonic EMR

Univariable predictors of pain after colonic EMR were: female sex ($P=0.03$), lesion size ≥ 40 mm ($P=0.002$), and presence of intraprocedural bleeding requiring endoscopic control (IPB; $P=0.03$) (► **Table 1**). On multivariable analysis, lesion size ≥ 40 mm, OR 2.15 (95%CI 1.22–3.80; $P=0.008$); female sex, OR 1.99 (95%CI 1.14–3.48; $P=0.02$); and intraprocedural bleeding requiring endoscopic control, OR 1.77 (95%CI 0.99–3.16; $P=0.05$) were independent predictors of pain after colonic EMR.

Patients with non-resolving pain after colonic EMR (“moderate and severe pain” after colonic EMR)

Of the 67 patients, 16 (23.8%, 95%CI 15.3%–35.3%) had pain after colonic EMR that did not resolve after paracetamol and required fentanyl at a median (IQR) dose of 25 (25–50) µg. Of these 16 patients, 11 (68.8%) were discharged to second-stage recovery after resolution of their pain with fentanyl without further sequelae (classified as “moderate pain” after colonic EMR).

Five patients with “severe pain” after colonic EMR were admitted to hospital because of ongoing pain (► **Table 3**). A computed tomography (CT) scan was performed in four of these patients, who received ≥ 25 µg of fentanyl without resolution of their pain (► **Fig. 2**). The CT was normal in two patients, showed serositis in one, and showed small locules of extramural gas without any associated fluid in the fourth. The patient with serositis stayed in hospital for 6 days and was managed with antibiotics and conservative treatment. The patient whose CT scan had indicated a contained perforation was also managed with

antibiotics and conservative treatment. This patient stayed in hospital for 5 days and was discharged thereafter. The outcomes of all patients who experienced non-resolving pain are detailed in **Table 1 s**, see online-only Supplementary material.

Delayed complications

CSPEB needing admission to hospital was observed in 24/336 patients (7.1%), of whom 17 (6.3%) were in the group of patients without pain after colonic EMR and seven (10.4%) in the group with pain ($P=0.29$) (► **Table 1**). Delayed perforation occurred in 1/336 patients (0.3%), with this patient experiencing pain after colonic EMR ($P=0.20$). These results are in line with previously published numbers.

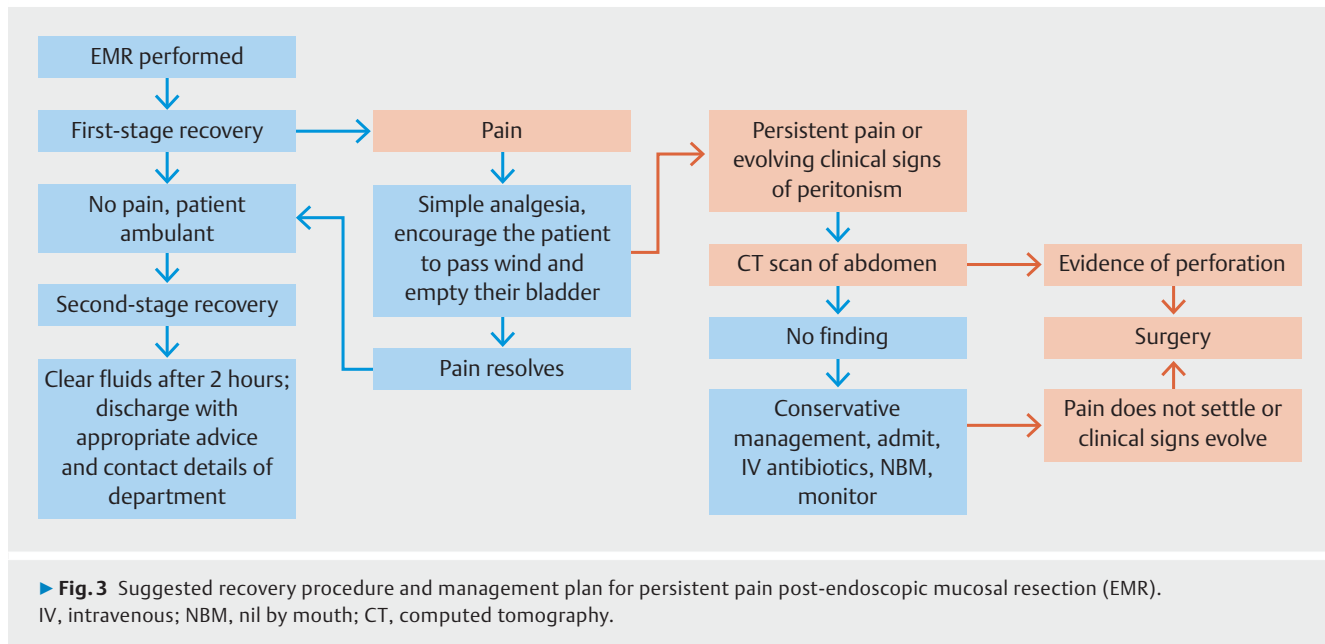
Discussion

Abdominal pain after EMR of colonic LSLs of ≥ 20 mm has not been comprehensively studied, its frequency is unknown and there is no standardized method for its treatment. It is hypothesized to result from transmural thermal injury to the colonic wall or may herald a significant adverse event, such as a missed or delayed perforation. In this study, we have demonstrated that pain after EMR of an LSL occurs in 1/5 patients, is commonly short-lived, and is responsive to IV paracetamol.

The risk factors for developing pain after EMR in the colon are unknown. Some literature exists in relation to gastric endoscopic submucosal dissection (ESD). Here the frequency of any pain after the procedure in one study was up to 94%, with a mean (SD) VAS of 4.7 (2.5) immediately after ESD, falling to 3.8 (2.5) within 6 hours [16]. The investigators tried injecting bupivacaine into the post-ESD defect in this randomized study, without a significant impact on pain post-ESD. A further study of patients undergoing gastric ESD described pain in only 53.8% (but only defined pain as being present if the VAS was >3) and identified female sex, pre-ESD proton pump inhibitor use, distal tumor location, and baseline dyspeptic symptoms as risk factors for its occurrence [17].

In the current study, multiple risk factors for pain after colonic EMR were identified. Women had a greater risk of developing pain after colonic EMR than men; a clear reason for this discrepancy is not immediately obvious to the authors. In addition, we found that pain after colonic EMR was associated with the use of techniques that increase the amount of electrocautery used during the procedure. At multivariable analysis, intraprocedural bleeding, which was generally treated with snare-tip soft coagulation if it persisted for more than 30 seconds, and larger lesion size, clearly requiring more snare resections, were significantly associated with pain. Interestingly the application of thermal ablation to the post-EMR margin, in keeping with a previous randomized trial [18], was not significantly associated with pain. Furthermore, clip placement, which may perhaps cause extra tension on the colonic wall, was also not associated with pain.

No reports could be found in the literature pertaining to the severity or frequency of pain after colonic EMR or ESD. In this study of consecutive patients undergoing EMR at a tertiary endoscopy center, pain after colonic EMR (VAS >0 for longer



than 5 minutes) was reported in 20% of patients. The median (IQR) VAS at the onset of pain was 5 (3–7) and the median (IQR) time to resolution of the pain (after administration of 1 g of parenteral paracetamol) was 25 (10–48) minutes. Of the patients with pain after colonic EMR, 24% (or 5% of all patients in the study) required opiate analgesia (fentanyl in this study). No patient who did not require fentanyl experienced a serious event, such as admission, perforation, or the need for surgery, after EMR. Of patients requiring opiate analgesia, 69% were able to be discharged on the same day having undergone extended recovery time. Only 31% of patients requiring opiate analgesia (1% of all patients in the study) were admitted to hospital, with just one patient undergoing admission for conservative management after a CT scan showed small locules of extramural gas without any associated fluid.

IV paracetamol was chosen as the initial analgesic of choice for patients with pain after colonic EMR in this study. In comparison to those receiving opiates, patients receiving IV paracetamol experience less nausea, vomiting, and sedation. In addition, as the adverse events of opiates may mimic the adverse events after EMR, paracetamol also avoids this confusion. Paracetamol is safe – there is no statistically significant difference in the rates of adverse events in patients receiving IV paracetamol – and efficacious, offering similar pain relief to nonsteroidal anti-inflammatory drugs but with a superior safety profile. It is widely available and, in most healthcare systems, relatively inexpensive.

The findings of this study highlight a discriminatory role for the administration of IV paracetamol at the onset of pain after colonic EMR. If the pain subsides within 30 minutes of administration (median time to resolution of pain in this study was 25 minutes), the patient can safely be discharged home (classified as “mild pain” after colonic EMR). If not, further analgesia is clearly appropriate. We show here, albeit with smaller numbers, that pain after colonic EMR despite fentanyl (classified as “severe

pain” after colonic EMR) may also be discriminatory for patients who need hospital admission and possible further investigation.

This information offers the practicing EMR clinician and their patient an insight into the post-EMR situation as regards pain after colonic EMR, a clear guide for how to treat pain after colonic EMR, and when to be concerned about it. It further informs consent discussions with patients before EMR and may lead to streamlining of patient recovery and discharge from hospital. This in turn may lead to cost-savings for patients (fewer lost workdays, less need for accommodation and travel expenses) and healthcare systems alike.

In this study, we did not collect data on fever and leukocytosis but it may be hypothesized that the patients who experienced pain that did not resolve with opiates were suffering from pain with an associated significant inflammatory response (historically termed the post-polypectomy syndrome), with rates from 9.0%–40.2% having been reported after colorectal endoscopic resection [19–21]. In this study the rate was much lower (1%), perhaps because these reports related predominantly to ESD or owing to differences in technique. Of the five patients in this situation in the current study, all were admitted to hospital and settled with conservative management (IV antibiotics and analgesia); none required surgery. The discriminant investigation in this situation was CT scan of the abdomen. ► **Fig. 3** presents a suggested algorithm for the management of pain after colonic EMR.

The major limitation of this study is its single-center nature using a standardized technique for EMR. As such, the results may not be generalizable outside of this setting. Approximately one-third of patients approached did not consent to participate in this study, perhaps because of the subject; it is not possible to know whether these patients had different characteristics to the consenting study population.

The authors acknowledge that this is an observational study to identify the risk factors for pain after colonic EMR; we did not

set out to develop a prediction model for pain after colonic EMR, nor does the study design support this. Multiple exploratory analyses were carried out and the results should therefore be interpreted with caution. Further multicenter data should be obtained to confirm the assertions made herein.

In all of our study patients, adrenaline was added to the injectate; we acknowledge a recent small (n = 21) single-operator single-center series that demonstrated the use of adrenaline to be a risk factor for pain after colonic EMR [22]. Again, further multicenter data are required prior to generalizing these findings.

One of the primary end points in our study was the frequency and severity of pain after EMR using a subjective measure, namely the VAS score. Although this score is well validated, perceptions of pain can certainly be different among individual patients. Finally, 25 µg of fentanyl is a low dose and resolution of pain could also have been the natural clinical course rather than the effect of the opiates given.

In conclusion, persistent pain after EMR of LSLs occurs in approximately 20% of patients, is commonly mild, and resolves rapidly and completely in the vast majority of patients after administration of IV paracetamol. Such patients may be safely discharged home. Patients with “moderate pain” who require opiate analgesia may also be safely discharged home if their pain resolves with an extended recovery time. Ongoing “severe pain” despite opiate analgesia heralds a more serious scenario and abdominal imaging with hospital admission should be considered.

Conflict of interest

The authors declare that they have no conflict of interest.

Funding

The Cancer Institute New South Wales, Australia

Clinical trial

Trial Registration: ClinicalTrials.gov | Registration number (trial ID): NCT03471156 | Type of study: Prospective

References

- [1] Lee EY, Bourke MJ. EMR should be the first-line treatment for large laterally spreading colorectal lesions. *Gastrointest Endosc* 2016; 84: 326–328
- [2] Bahin FF, Heitman SJ, Bourke MJ et al. Wide-field endoscopic mucosal resection versus endoscopic submucosal dissection for laterally spreading colorectal lesions: a cost-effectiveness analysis. *Gut* 2018; 67: 1965–1973
- [3] Bourke MJ, Neuhaus H, Bergman JJ. Endoscopic submucosal dissection: indications and application in Western endoscopy practice. *Gastroenterology* 2018; 154: 1887–1900.e5
- [4] Jideh B, Bourke MJ. How to perform wide-field endoscopic mucosal resection and follow-up examinations. *Gastrointest Endosc Clin* 2019; 29: 629–646
- [5] Gustafsson UO, Scott MJ, Hubner M et al. Guidelines for perioperative care in elective colorectal surgery: Enhanced Recovery After Surgery (ERAS(R)) Society Recommendations: 2018. *World J Surg* 2019; 43: 659–695
- [6] Hirasawa K, Sato C, Makazu M et al. Coagulation syndrome: delayed perforation after colorectal endoscopic treatments. *World J Gastrointest Endosc* 2015; 7: 1055–1061
- [7] Bassan MS, Holt B, Moss A et al. Carbon dioxide insufflation reduces number of postprocedure admissions after endoscopic resection of large colonic lesions: a prospective cohort study. *Gastrointest Endosc* 2013; 77: 90–95
- [8] Dellon ES, Hawk JS, Grimm IS et al. The use of carbon dioxide for insufflation during GI endoscopy: a systematic review. *Gastrointest Endosc* 2009; 69: 843–849
- [9] Holt BA, Bassan MS, Bourke MJ. Endoscopic management of colonoscopic perforations. *Gastrointest Endosc* 2012; 75: 1291–1292
- [10] Burgess NG, Bassan MS, McLeod D et al. Deep mural injury and perforation after colonic endoscopic mucosal resection: a new classification and analysis of risk factors. *Gut* 2017; 66: 1779–1789
- [11] McNicol ED, Ferguson MC, Haroutounian S et al. Single dose intravenous paracetamol or intravenous propacetamol for postoperative pain. *Cochrane Database Syst Rev* 2016: doi:10.1002/14651858.CD007126.pub3
- [12] Moss A, Bourke MJ, Williams SJ et al. Endoscopic mucosal resection outcomes and prediction of submucosal cancer from advanced colonic mucosal neoplasia. *Gastroenterology* 2011; 140: 1909–1918
- [13] Klein A, Bourke MJ. How to perform high-quality endoscopic mucosal resection during colonoscopy. *Gastroenterology* 2017; 152: 466–471
- [14] Hawker GA, Mian S, Kendzerska T et al. Measures of adult pain: Visual Analog Scale for Pain (VAS Pain), Numeric Rating Scale for Pain (NRS Pain), McGill Pain Questionnaire (MPQ), Short-Form McGill Pain Questionnaire (SF-MPQ), Chronic Pain Grade Scale (CPGS), Short Form-36 Bodily Pain Scale (SF-36 BPS), and Measure of Intermittent and Constant Osteoarthritis Pain (ICOAP). *Arthritis Care Res (Hoboken)* 2011; 63: (Suppl. 01): S240–S252
- [15] Gallagher EJ, Bijur PE, Latimer C et al. Reliability and validity of a visual analog scale for acute abdominal pain in the ED. *Am J Emerg Med* 2002; 20: 287–290
- [16] Jung JH, Jang HJ, Bang CS et al. Efficacy of submucosal bupivacaine injection for pain relief after endoscopic submucosal dissection: A multicenter, prospective, randomized controlled, and double-blind trial. *Medicine (Baltimore)* 2019; 98: e15360
- [17] Jung DH, Youn YH, Kim J-H et al. Factors influencing development of pain after gastric endoscopic submucosal dissection: a randomized controlled trial. *Endoscopy* 2015; 47: 1119–1123
- [18] Klein A, Tate DJ, Jayasekaran V et al. Thermal ablation of mucosal defect margins reduces adenoma recurrence after colonic endoscopic mucosal resection. *Gastroenterology* 2019; 156: 604–613.e3
- [19] Lee SP, Sung I-K, Kim JH et al. A randomized controlled trial of prophylactic antibiotics in the prevention of electrocoagulation syndrome after colorectal endoscopic submucosal dissection. *Gastrointest Endosc* 2017; 86: 349–357.e2
- [20] Jung D, Youn YH, Jahng J et al. Risk of electrocoagulation syndrome after endoscopic submucosal dissection in the colon and rectum. *Endoscopy* 2013; 45: 714–717
- [21] Lee S-YSP, Kim JH, Sung I-K et al. Effect of submucosal fibrosis on endoscopic submucosal dissection of colorectal tumors: pathologic review of 173 cases. *J Gastroenterol Hepatol* 2015; 30: 872–878
- [22] Rex DK, Lahr RE, Peterson MM et al. Impact of including epinephrine in the submucosal injectate for colorectal EMR on postprocedural pain: a randomized controlled trial. *Gastrointest Endosc* 2022; 95: 535–539.e1