

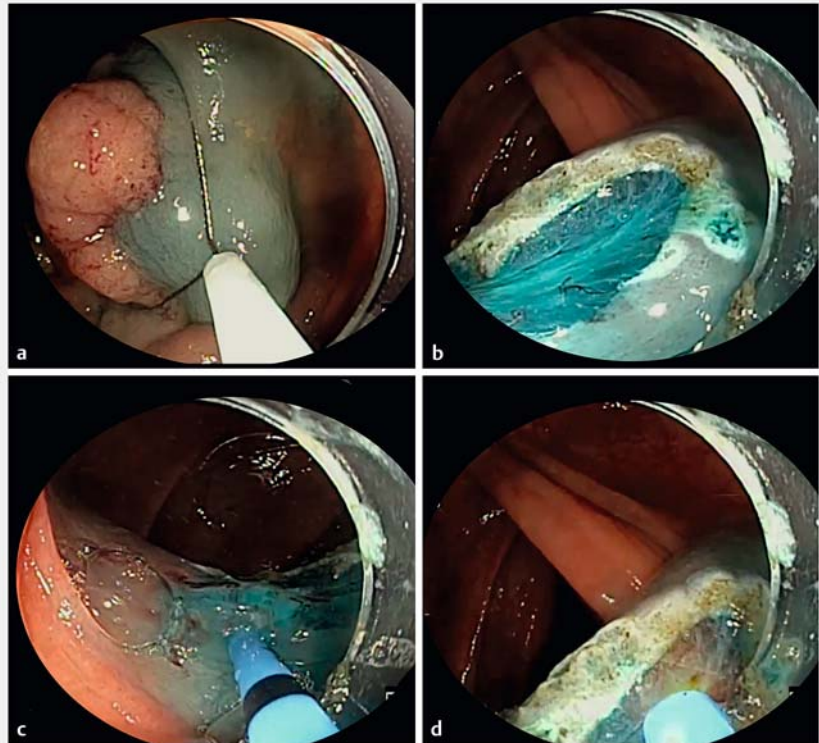


Combining endoscopic mucosal resection with hybrid argon plasma coagulation to reduce local colorectal lesion recurrence: a video tutorial

Endoscopic mucosal resection (EMR) is a safe, effective, and surgery-sparing technique for removing large colorectal lesions [1]. Although piecemeal EMR is recommended for polyps >20mm in size, it remains a suboptimal technique for complete lesion resection, with high rates of residual polyp and recurrence rates reaching 15% [2]. Hybrid argon plasma coagulation (hAPC) is a novel approach allowing ablation of resection margins and surface after EMR. hAPC combines waterjet injection and argon plasma coagulation (APC) in a single device. On-demand, repeatable saline cushioning without instrument exchange reduces thermal ablative insult to deep tissue structures, allowing for effective destruction of micro-remnants with reduced risk of perforation. High technical success and low recurrence rates (0%) were shown in a pilot study using EMR in combination with hAPC [3]. A prospective international multicenter study showed that the local recurrence rate was only 2.2% when using hAPC after EMR [4]. One recent meta-analysis found the local recurrence rate to be 3.3% after hot EMR and margin ablation at 12-month follow-up [5].

We present a step-by-step video tutorial demonstrating how hAPC-assisted EMR is performed while providing technical tips to achieve optimal ablation results (► **Video 1**).

hAPC-assisted EMR is done after standard initial assessment of polyp morphology and submucosal invasion. The polyp is removed in piecemeal fashion using a combination of an electrosurgical snare, cold snare, and forceps avulsion techniques (► **Fig. 1**). Following complete resection of the entire visible polyp, the base and margins of the submucosal defect are then lifted using the waterjet function of the hAPC probe and thermal ablation is performed. EMR margin abla-



► **Fig. 1** The hybrid argon plasma coagulation (hAPC)-assisted endoscopic mucosal resection (EMR) technique for removal of colon polyps. **a** EMR is performed. **b** The resection area post-EMR. **c** Needlesh waterjet injection for margin and base lifting prior to hAPC. **d** Thermal ablation using hAPC.

tion is performed with combinations alternating between 25–40W pulsed-APC and precise-APC Effect 8–10 (11–21W), with both modes using a flow of 0.8L/min. Vessels can be prophylactically ablated; however, the clinical benefit of this is unclear at present.

Endoscopy_UCTN_Code_TTT_1AQ_2AD


Competing interests

D. von Renteln has received research funding and speaker honoraria from Erbe.

The authors

Melissa Zarandi-Nowroozi¹, Daniel von Renteln²

- 1 Division of Internal Medicine, University of Montreal Hospital Center, Montreal, Quebec, Canada
- 2 Division of Gastroenterology, University of Montreal Hospital Center, Montreal, Quebec, Canada



Video 1 Video tutorial demonstrating how to perform hybrid argon plasma coagulation-assisted endoscopic mucosal resection in different clinical examples.

Corresponding author

Daniel von Renteln, MD

Division of Gastroenterology, Department of Medicine, University of Montreal Hospital Center, University of Montreal, 900 St-Denis Street, Montreal, Quebec, H2X 0A9, Canada
danielrenteln@gmail.com

References

- [1] Kaltenbach T, Anderson J, Singh R et al. Endoscopic removal of colorectal lesions: recommendations by the US Multi-Society Task Force on Colorectal Cancer. *Am J Gastroenterol* 2020; 115: 435–464
- [2] Belderbos TD, Leenders M, Moons LM et al. Local recurrence after endoscopic mucosal resection of nonpedunculated colorectal lesions: systematic review and meta-analysis. *Endoscopy* 2014; 46: 388–402
- [3] Motz VL, Lester C, Moyer MT et al. Hybrid argon plasma coagulation-assisted endoscopic mucosal resection for large sessile colon polyps to reduce local recurrence: a prospective pilot study. *Endoscopy* 2022; 54: 580–584
- [4] Motchum L, Levenick JM, Djinbanchian R et al. EMR combined with hybrid argon plasma coagulation to prevent recurrence of large nonpedunculated colorectal polyps (with videos). *Gastrointest Endosc* 2022. doi:10.1016/j.gie.2022.06.018
- [5] Rotermund C, Djinbanchian R, Taghiakbari M et al. Recurrence rates after endoscopic resection of large colorectal polyps: a systematic review and meta-analysis. *World J Gastroenterol* 2022; 28: 4007–4018

Bibliography

Endoscopy 2023; 55: 391–392
DOI 10.1055/a-2009-2196
ISSN 0013-726X

© 2022. The Author(s).

This is an open access article published by Thieme under the terms of the Creative Commons Attribution-NonDerivative-NonCommercial License, permitting copying and reproduction so long as the original work is given appropriate credit. Contents may not be used for commercial purposes, or adapted, remixed, transformed or built upon. (<https://creativecommons.org/licenses/by-nc-nd/4.0/>)

Georg Thieme Verlag KG, Rüdigerstraße 14, 70469 Stuttgart, Germany



Citation Format

Endoscopy 2023; 54 (S01); E229–E230,
DOI: 10.1055/a-1966-0441.

ENDOSCOPY E-VIDEOS

<https://eref.thieme.de/e-videos>



Endoscopy E-Videos is an open access online section, reporting on interesting cases and new techniques in gastroenterological endoscopy. All papers include a high quality video and all contributions are freely accessible online. Processing charges apply, discounts and waivers acc. to HINARI are available.

This section has its own submission website at
<https://mc.manuscriptcentral.com/e-videos>