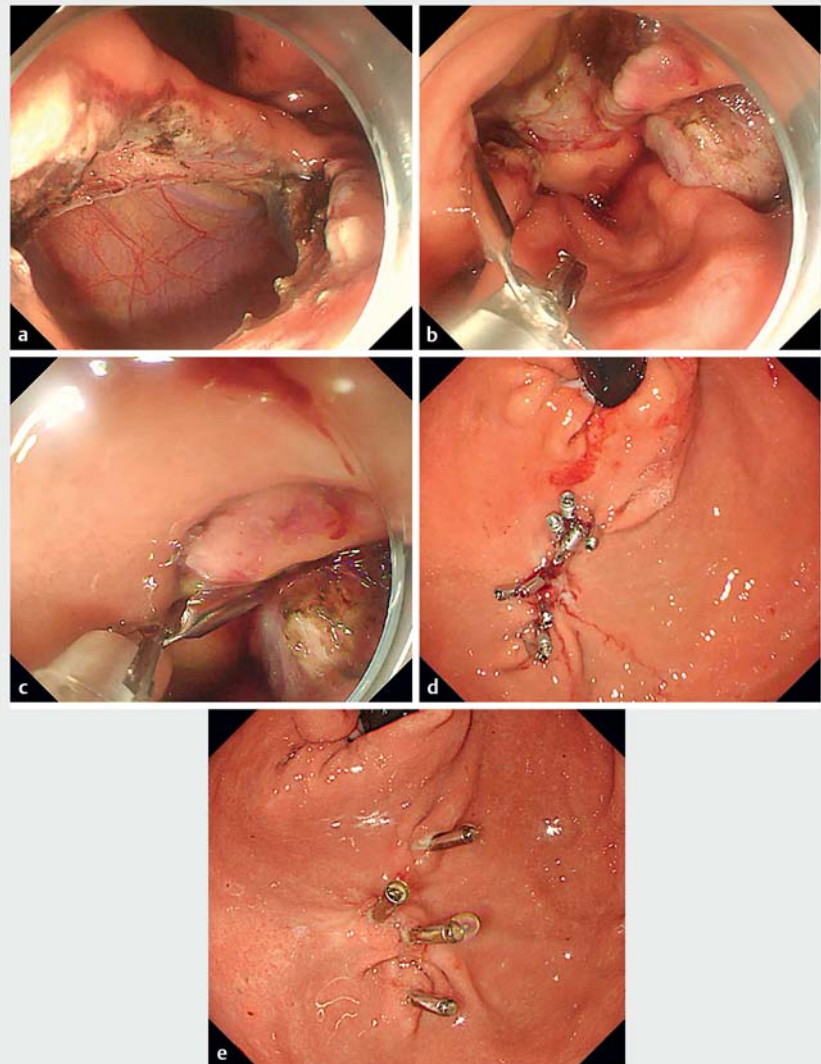


## A novel endoscopic clip for closing a large perforating wound in a patient undergoing endoscopic full-thickness resection



The through-the-scope twin clip (Micro-Tech Co. Ltd., Nanjing, China), also called a dual action tissue clip, was first reported by us [1,2]. The clip can pass directly through the working channel of the endoscope to close the wound and is convenient and quick to use. To our knowledge, this was the first time that through-the-scope twin clips were used to close a large perforation in a patient with a submucosal tumor.

The 2.5-cm tumor, located at the gastric fundus and derived from the muscularis propria, was completely resected by endoscopic full-thickness resection (EFTR). The pathology of the resected tumor was a low-risk stromal tumor. After EFTR, the perforating wound size was about 2.5 cm (► Fig. 1 a). It was closed using through-the-scope twin clips combined with traditional through-the-scope clips (► Video 1, ► Fig. 1) as follows: One side of a twin clip was opened by operating the handle and the mucosa on one side of the wound was tightly clamped (► Fig. 1 b). Then, the clamped mucosa was pulled toward the opposite side to close the mucosa, and the clip on the other side of the twin clip was opened to clamp that side of the mucosa (► Fig. 1 c). After the mucosa on both sides of the wound was firmly clamped together, the twin clip was released. The large perforation closed by four through-the-scope twin clips was gradually turned into a small wound, and then the small wound was closed by five traditional through-the-scope clips (► Fig. 1 d). The total time of wound closure was 15 minutes, and the mean time spent closing the wound with each twin clip was 2.5 minutes. No bleeding or perforation complications occurred. In 2 months after the operation, the wound had healed, all twin clips had detached spontaneously, and four traditional clips remained (► Fig. 1 e). In this case, a large perforating wound was successfully closed by the through-the-scope twin clips.

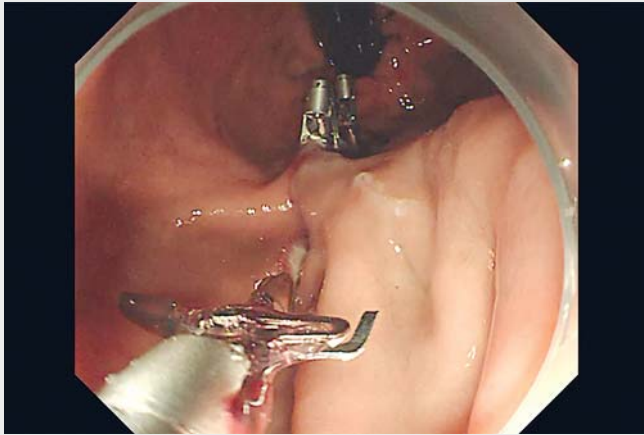


► **Fig. 1** A large perforating wound was successfully closed by through-the-scope twin clips. **a** After a submucosal tumor resected by endoscopic full-thickness resection, a 2.5-cm perforating wound of was produced. **b** The clip on one side of a twin clip was opened by operating the handle to tightly clamp the mucosa on one side of the wound. **c** The clamped mucosa was pulled toward the mucosa on the opposite side and that side clamped with the other clip. **d** The wound was completely closed by use of through-the-scope twin clips combined with traditional through-the-scope clips. **e** In 2 months after operation, the wound had healed, and all the twin clips had detached spontaneously.

Endoscopy\_UCTN\_Code\_CPL\_1AH\_2AG

Competing interests

The authors declare that they have no conflict of interest.



**Video 1** A case of through-the-scope twin clips to close a large perforating wound in a patient undergoing endoscopic full-thickness resection.

## Bibliography

Endoscopy 2022; 54: 199–200

DOI 10.1055/a-1980-1688

ISSN 0013-726X

published online 25.5.2022

© 2022. The Author(s).

This is an open access article published by Thieme under the terms of the Creative Commons Attribution-NonDerivative-NonCommercial License, permitting copying and reproduction so long as the original work is given appropriate credit. Contents may not be used for commercial purposes, or adapted, remixed, transformed or built upon. (<https://creativecommons.org/licenses/by-nc-nd/4.0/>)

Georg Thieme Verlag KG, Rüdigerstraße 14,  
70469 Stuttgart, Germany



## Citation Format

Endoscopy 2022; 54 (S02); E65-E66 DOI:  
10.1055/a-1838-4526.

## The authors

**Qiang Zhang**  **Zhen Wang**

Guangdong Provincial Key Laboratory of  
Gastroenterology, Department of  
Gastroenterology, Nanfang Hospital, Southern  
Medical University, Guangzhou, China

## Corresponding author

**Qiang Zhang, MD**

Guangdong Provincial Key Laboratory of  
Gastroenterology, Department of  
Gastroenterology, Nanfang Hospital,  
Southern Medical University, Guangzhou,  
Guangdong Province 510515, China  
4024313@qq.com

## References

- [1] Zhang Q, Wang Z, Bai Y. A novel through-the-scope twin endoclip for a large mucosal closure in a live pig model. *Endoscopy* 2019; 51: E372–E373
- [2] Zhang Q, Jin H-Y, Shen Z-H al. A novel through-the-scope twin clip for the closure of gastrointestinal wounds: the first experimental survival study in pigs (with videos). *Gastrointest Endosc* 2021; 94: 850–858

## ENDOSCOPY E-VIDEOS

<https://eref.thieme.de/e-videos>



*Endoscopy E-Videos* is an open access online section, reporting on interesting cases and new techniques in gastroenterological endoscopy. All papers include a high quality video and all contributions are freely accessible online. Processing charges apply (currently EUR 375), discounts and waivers acc. to HINARI are available.

This section has its own submission website at  
<https://mc.manuscriptcentral.com/e-videos>