












Small-bowel capsule endoscopy and device-assisted enteroscopy for diagnosis and treatment of small-bowel disorders: European Society of Gastrointestinal Endoscopy (ESGE) Guideline – Update 2022



Authors

Marco Pennazio¹ , Emanuele Rondonotti² , Edward J. Despott³, Xavier Dray⁴, Martin Keuchel⁵, Tom Moreels⁶, David S. Sanders⁷, Cristiano Spada^{8,9}, Cristina Carretero¹⁰, Pablo Cortegoso Valdivia¹¹ , Luca Elli¹² , Lorenzo Fuccio¹³ , Begona Gonzalez Suarez¹⁴, Anastasios Koulaouzidis¹⁵ , Lumir Kunovsky^{16,17,18} , Deirdre McNamara¹⁹, Helmut Neumann²⁰ , Enrique Perez-Cuadrado-Martinez²¹, Enrique Perez-Cuadrado-Robles²² , Stefania Piccirelli⁸, Bruno Rosa^{23,24,25}, Jean-Christophe Saurin²⁶, Reena Sidhu^{27,28}, Ilja Tacheci²⁹ , Erasmia Vlachou³⁰, Konstantinos Triantafyllou³¹ 

Institutions

- 1 University Division of Gastroenterology, City of Health and Science University Hospital, University of Turin, Turin, Italy
- 2 Gastroenterology Unit, Valduce Hospital, Como, Italy
- 3 Royal Free Unit for Endoscopy, The Royal Free Hospital and UCL Institute for Liver and Digestive Health, London, UK
- 4 Sorbonne University, Endoscopy Unit, AP-HP, Hôpital Saint-Antoine, Paris, France
- 5 Clinic for Internal Medicine, Agaplesion Bethesda Krankenhaus Bergedorf, Hamburg, Germany
- 6 Division of Gastroenterology and Hepatology, University Hospital Saint-Luc, Brussels, Belgium
- 7 Sheffield Teaching Hospitals NHS Foundation Trust, Gastroenterology Sheffield, Sheffield, UK
- 8 Digestive Endoscopy Unit and Gastroenterology, Fondazione Poliambulanza, Brescia, Italy
- 9 Università Cattolica del Sacro Cuore, Rome, Italy
- 10 Department of Gastroenterology. University of Navarre Clinic, Healthcare Research Institute of Navarre, Pamplona, Spain
- 11 Gastroenterology and Endoscopy Unit, University Hospital of Parma, University of Parma, Parma, Italy
- 12 Gastroenterology and Endoscopy Unit, Fondazione IRCCS Ca' Granda Ospedale Maggiore Policlinico, Milan, Italy
- 13 IRCCS Azienda Ospedaliero-Universitaria di Bologna, Department of Medical and Surgical Sciences, Gastroenterology Unit, University of Bologna, Bologna, Italy
- 14 Gastroenterology Department – ICMDiM, Hospital Clínic of Barcelona, DIBAPS, CiBERHED, Barcelona, Spain
- 15 Centre for Clinical Implementation of Capsule Endoscopy, Store Adenomer Tidlige Cancer Center, Svendborg, University of Southern Denmark, Denmark
- 16 2nd Department of Internal Medicine – Gastroenterology and Geriatrics, University Hospital Olomouc, Faculty of Medicine and Dentistry, Palacky University Olomouc, Olomouc, Czech Republic
- 17 Department of Surgery, University Hospital Brno, Faculty of Medicine, Masaryk University, Brno, Czech Republic
- 18 Department of Gastroenterology and Digestive Endoscopy, Masaryk Memorial Cancer Institute, Brno, Czech Republic
- 19 TAGG Research Centre, Department of Clinical Medicine, Trinity Centre, Tallaght Hospital, Dublin, Ireland
- 20 Department of Medicine I, University Medical Center Mainz, Mainz, Germany
- 21 Sección de Aparato Digestivo, Area VI, Hospital Morales Meseguer, Murcia, Spain
- 22 Department of Gastroenterology, Georges-Pompidou European Hospital, Paris, France
- 23 Department of Gastroenterology, Hospital da Senhora da Oliveira, Guimarães, Portugal
- 24 Life and Health Sciences Research Institute, School of Medicine, University of Minho, Braga/Guimarães, Portugal
- 25 ICVS/3B's, PT Government Associate Laboratory, Braga/Guimarães, Portugal
- 26 Gastroenterology and Endoscopy Unit, Hospices Civils de Lyon, Hôpital E. Herriot, Lyon, France
- 27 Academic Department of Gastroenterology and Hepatology, Sheffield Teaching Hospitals, Sheffield, United Kingdom

- 28 Department of Infection, Immunity and Cardiovascular Diseases, University of Sheffield, United Kingdom
- 29 2nd Department of Internal Medicine – Gastroenterology, University Hospital Hradec Králové, Charles University, Faculty of Medicine in Hradec Králové, Czech Republic
- 30 Army Share Fund Hospital (NIMTS), Athens, Greece
- 31 Hepatogastroenterology Unit, Second Department of Internal Medicine – Propaedeutic, Research Institute and Diabetes Center, Medical School, National and Kapodistrian University of Athens, Attikon University General Hospital, Athens, Greece

published online 24.11.2022

Bibliography

Endoscopy 2023; 55: 58–95

DOI 10.1055/a-1973-3796

ISSN 0013-726X

© 2022. European Society of Gastrointestinal Endoscopy

All rights reserved.

This article is published by Thieme.

Georg Thieme Verlag KG, Rüdigerstraße 14,
70469 Stuttgart, Germany

Corresponding author

Marco Pennazio, MD, University Division of Gastroenterology,
City of Health and Science University Hospital, 10123 Turin,
Italy

Fax: +39-11-6336752

pennazio.marco@gmail.com

 Supplementary material

Supplementary material is available under

<https://doi.org/10.1055/a-1973-3796>

MAIN RECOMMENDATIONS

MR1 ESGE recommends small-bowel capsule endoscopy as the first-line examination, before consideration of other endoscopic and radiological diagnostic tests for suspected small-bowel bleeding, given the excellent safety profile of capsule endoscopy, its patient tolerability, and its potential to visualize the entire small-bowel mucosa.
Strong recommendation, moderate quality evidence.

MR2 ESGE recommends small-bowel capsule endoscopy in patients with overt suspected small-bowel bleeding as soon as possible after the bleeding episode, ideally within 48 hours, to maximize the diagnostic and subsequent therapeutic yield.
Strong recommendation, high quality evidence.

MR3 ESGE does not recommend routine second-look endoscopy prior to small-bowel capsule endoscopy in patients with suspected small-bowel bleeding or iron-deficiency anemia.
Strong recommendation, low quality evidence.

MR4 ESGE recommends conservative management in those patients with suspected small-bowel bleeding and high quality negative small-bowel capsule endoscopy.
Strong recommendation, moderate quality evidence.

MR5 ESGE recommends device-assisted enteroscopy to confirm and possibly treat lesions identified by small-bowel capsule endoscopy.
Strong recommendation, high quality evidence.

MR6 ESGE recommends the performance of small-bowel capsule endoscopy as a first-line examination in patients with iron-deficiency anemia when small bowel evaluation is indicated.
Strong recommendation, high quality evidence.

MR7 ESGE recommends small-bowel capsule endoscopy in patients with suspected Crohn's disease and negative ileocolonoscopy findings as the initial diagnostic modality for investigating the small bowel, in the absence of obstructive symptoms or known bowel stenosis.
Strong recommendation, high quality evidence.

MR8 ESGE recommends, in patients with unremarkable or nondiagnostic findings from dedicated small-bowel cross-sectional imaging, small-bowel capsule endoscopy as a subsequent investigation if deemed likely to influence patient management.
Strong recommendation, low quality evidence.

MR9 ESGE recommends, in patients with established Crohn's disease, the use of a patency capsule before small-bowel capsule endoscopy to decrease the capsule retention rate.
Strong recommendation, moderate quality evidence.

MR10 ESGE recommends device-assisted enteroscopy (DAE) as an alternative to surgery for foreign bodies retained in the small bowel requiring retrieval in patients without acute intestinal obstruction.
Strong recommendation, moderate quality evidence.

MR11 ESGE recommends DAE-endoscopic retrograde cholangiopancreatography (DAE-ERCP) as a first-line endoscopic approach to treat pancreaticobiliary diseases in patients with surgically altered anatomy (except for Billroth II patients).
Strong recommendation, moderate quality evidence.

ABBREVIATIONS

AI	artificial intelligence	IDA	iron-deficiency anemia
BSG	British Society of Gastroenterology	IRT	iron replacement trial
CD	Crohn's disease	MCV	mean corpuscular volume
CECDAI	Capsule Endoscopy Crohn's Disease Activity Index	MRE	magnetic resonance enterography
CI	confidence interval	MRI	magnetic resonance imaging
CRP	C-reactive protein	NEN	neuroendocrine neoplasm
CTE	computed tomography enterography	NPV	negative predictive value
DAE	device-assisted enteroscopy	NSAID	nonsteroidal anti-inflammatory drug
DBE	double-balloon enteroscopy	OGIB	obscure gastrointestinal bleeding
DPEJ	direct percutaneous endoscopic jejunostomy	OR	odds ratio
EATL	enteropathy-associated T-cell lymphoma	PE	push-enteroscopy
EmA	antiendomysial antibody	PEJ	percutaneous endoscopic jejunostomy
ERCP	endoscopic retrograde cholangio-pancreatography	PJS	Peutz-Jeghers syndrome
ESGE	European Society of Gastrointestinal Endoscopy	PPI	proton pump inhibitor
ESPGHAN	European Society for Paediatric Gastroenterology, Hepatology and Nutrition	PPV	positive predictive value
ESR	erythrocyte sedimentation rate	RCD	refractory celiac disease
EUS	endoscopic ultrasound	RCT	randomized controlled trial
FOBT	fecal occult blood testing	RFIT	radiofrequency identification tag
GI	gastrointestinal	RYGB	Roux-en-Y gastric bypass
GIST	gastrointestinal stromal tumor	SB	small-bowel
GRADE	Grading of Recommendations Assessment, Development and Evaluation	SBCE	small-bowel capsule endoscopy
HR	hazard ratio	SBE	single-balloon enteroscopy
IBD-U	inflammatory bowel disease, unclassified type	SBT	small-bowel tumor
ICCE	International Conference on Capsule Endoscopy	SEMS	self-expanding metal stent
		SSBB	suspected small-bowel bleeding
		tTG	antitransglutaminase antibody
		UC	ulcerative colitis

SCOPE AND PURPOSE

This Guideline is an official statement from the European Society of Gastrointestinal Endoscopy (ESGE). It is an update of the previously published 2015 ESGE Clinical Guideline addressing the role of small-bowel capsule endoscopy (SBCE) and device-assisted enteroscopy (DAE) for diagnosing and treating small-bowel disorders.

Introduction

The introduction of small-bowel capsule endoscopy (SBCE) and device-assisted enteroscopy (DAE) over 20 years ago marked the beginning of a new era for investigating the small intestine. There is now more solid scientific evidence on established indications, and more data on new applications of enteroscopy are available. The aim of this Guideline, commissioned by the European Society of Gastrointestinal Endoscopy (ESGE) as an update of the previous 2015 Guideline [1], is to provide guidance for the clinical application of enteroscopy techniques in the management of adult patients with small-bowel (SB) disorders.

Methods

ESGE commissioned this clinical Guideline (ESGE Guideline Committee Chair, K.T.) and appointed a guideline leader (M.P.) who formed a coordinating team (M.P., E.R., P.C.V.). The guideline leader established six task forces, each with its leader (C.S., E.D., M.K., D.S.S., T.M., X.D.). Key questions were prepared by the coordinating team according to the PICO (patients, interventions, controls, outcomes) format and divided among the six task forces (see **Table 1 s**, Key Questions, available online-only in Supplementary Material). Given that this is an update of the 2015 ESGE Clinical Guideline [1], each task force performed a structured, systematic search, using keywords, for available literature (English-language articles) from December 2014 to November 30 2021 in Ovid MEDLINE, EMBASE, Google Scholar, and the Cochrane Database of Systematic Reviews; the literature search was then updated up to April 1 2022, to look for recently released papers. A dedicated manual search was also performed in the same timeframe by checking references of relevant papers. The hierarchy of studies included in this evidence-based guideline was, in decreasing order of evidence level: published systematic reviews/meta-analyses, randomized controlled trials (RCTs), prospective and retrospective observational studies, and case series.

Evidence on each key question was summarized in tables (**Table 2s**, Evidence tables), using the Grading of Recommendations Assessment, Development and Evaluation (GRADE) system, wherever applicable [2]. The evidence grading depends on the balance between any health intervention's benefits and their risk or burden. Further details on ESGE guideline development are available elsewhere [3].

The literature search results and answers to PICO questions were presented to all guideline group members during an online meeting on October 8 2021. Subsequently, drafts for each topic were prepared by each task force leader and distributed between the task force members for revision and discussion. In June 2022, a draft prepared by the coordinating team, including all the statements, was sent to all guideline group members. All the statements were discussed and modified in real time, if necessary, during an online meeting on June 24 2022. After the agreement of all members was obtained, the manuscript was reviewed by two independent external reviewers. The manuscript was then sent to the 51 ESGE member societies and to individual members for further comments. The final revised manuscript, having been agreed upon by all authors, was submitted for publication to the journal *Endoscopy*.

This ESGE Guideline was issued in 2022 and will be considered for update in 2027. Any interim updates will be noted on the ESGE website: <http://www.esge.com/esge-guidelines.html>.

Evidence statements and Recommendations

Evidence statements and Recommendations are grouped according to the different task force topics: suspected small-bowel bleeding (SSBB) and iron-deficiency anemia (IDA) (task force 1), Crohn's disease (CD) (task force 2), small-bowel tumors (SBTs) and inherited polyposis syndromes (task force 3), celiac disease (task force 4), other indications (task force 5), and innovations (task force 6). Each statement is followed by the assessment of the strength of evidence, based on GRADE. ► **Table 1** summarizes all recommendations in this updated Guideline.

Suspected small-bowel bleeding

RECOMMENDATION

ESGE recommends small-bowel capsule endoscopy as the first-line examination, before consideration of other endoscopic and radiological diagnostic tests, for suspected small-bowel bleeding, given the excellent safety profile of capsule endoscopy, its patient tolerability, and its potential to visualize the entire small-bowel mucosa. Strong recommendation, moderate quality evidence.

Small-bowel (SB) bleeding is defined as bleeding in the gastrointestinal (GI) tract between the ampulla of Vater and the ileocecal valve. SB bleeding is suspected when a patient presents with GI bleeding but has negative upper and lower endoscopy findings; it can present as overt or occult bleeding. The

term "obscure gastrointestinal bleeding" (OGIB) should be reserved for patients not found to have a source of bleeding even after the performance of SB evaluation [4].

The diagnostic yield of small-bowel capsule endoscopy (SBCE) in patients with suspected small-bowel bleeding (SSBB) ranges from 55% to 62% [5–7]. Compared with alternative modalities, SBCE has been consistently shown in prospective studies to be significantly superior to push-enteroscopy [8], computed tomography enterography (CTE) [9], CT angiography and standard angiography [10], and intraoperative enteroscopy [11], and to be as good as DAE [6] in evaluating and finding the lesion(s) causing the bleeding in patients with SSBB.

Careful patient selection may improve the diagnostic yield of SBCE in patients with SSBB. Diagnostic yield is greatest if the interval between SBCE and the last bleeding episode is as short as possible [12] (see following statements and supporting evidence). Other characteristics associated with an increased yield include a history of an overt bleed, use of antithrombotic agents, inpatient status, male sex, older age, and liver and renal comorbidities [13, 14]. From a technical point of view, a careful and focused review, performed by adequately trained readers, using the latest available technological advances (e.g., chromoendoscopy [15], and artificial intelligence [AI]) might contribute to further increasing the diagnostic yield of capsule endoscopy.

In patients with SSBB, SBCE showed an excellent safety profile. The rates of capsule retention range from 1.2% [5] to 2.1% [16]. Thus, routine cross-sectional imaging or the use of a patency capsule is not essential before SBCE in these patients.

It is known that cross-sectional techniques may be helpful in SSBB [4]. This updated Guideline can report only a few further studies that have been published on this subject. A meta-analysis, with 9 mainly high quality studies (396 patients), evaluated the diagnostic accuracy of CTE on SSBB detection [17]. The pooled sensitivity and specificity of CTE were 0.724 (95% CI 0.651–0.789) and 0.752 (95% CI 0.691–0.807), respectively. The area under the curve (AUC) was 0.7916 (95% CI 0.723–0.860). A small retrospective cohort study [18] showed that when CTE and SBCE were used in combination within 30 days, the sensitivity was significantly higher at 30/31 (96.8%) than that of SBCE alone at 24/31 (77.4%; $P=0.0412$).

Although CTE showed only moderate accuracy in the diagnosis of SSBB, it must also be remembered that SBCE can miss solitary protruding lesions in the proximal small bowel, such as small-bowel tumors (SBTs) [19]. CTE may thus be reasonably used as a complementary diagnostic method to SBCE, especially when an SBT is suspected.

DAE is both diagnostic and therapeutic but compared with SBCE, it has a lower rate of complete examination of the small bowel and is more invasive. In addition, the diagnostic yield of double-balloon enteroscopy (DBE) improves from 56% (95% CI 48.9%–62.1%) to 75% (95% CI 60.1%–90.0%) if DBE is preceded by a positive SBCE (odds ratio [OR] for positive DBE 1.79, 95% CI 1.09–2.96%; $P=0.02$) [6]. Although the clinical presentation may indicate the preferential endoscopic insertion route for DAE, SBCE is also an effective tool for guiding the selection of the correct DAE approach (oral vs. anal) [20].

► Table 1 Small-bowel capsule endoscopy and device-assisted enteroscopy for diagnosis and treatment of small-bowel disorders. Summary of all ESGE Guideline 2015 and ESGE Guideline 2022 recommendations. Changes from the 2015 Guideline (new or modified recommendations) are shown in bold.

ESGE Guideline 2015	ESGE Guideline 2022 (in bold if modified)
Suspected small-bowel bleeding	
1. ESGE recommends small-bowel video capsule endoscopy as the first-line investigation in patients with obscure gastrointestinal bleeding (strong recommendation, moderate quality evidence).	<p>1. ESGE recommends small-bowel capsule endoscopy as the first-line examination, before consideration of other endoscopic and radiological diagnostic tests for suspected small-bowel bleeding, given the excellent safety profile of capsule endoscopy, its patient tolerability, and its potential to visualize the entire small-bowel mucosa. Strong recommendation, moderate quality evidence.</p> <p>2. ESGE recommends small-bowel capsule endoscopy in patients with overt suspected small-bowel bleeding as soon as possible after the bleeding episode, ideally within 48 hours, to maximize the diagnostic and subsequent therapeutic yield. Strong recommendation, high quality evidence.</p> <p>3. ESGE suggests that device-assisted enteroscopy be considered as an alternative first-line test in selected cases, given that it allows diagnosis and treatment in the same procedure, depending on the clinical scenario and local availability. Weak recommendation, low quality evidence.</p> <p>4. ESGE recommends, in patients with overt suspected small-bowel bleeding, device-assisted enteroscopy to be performed optimally within 48–72 hours after the bleeding episode. Strong recommendation, high quality evidence.</p> <p>5. ESGE suggests consideration of device-assisted enteroscopy and/or dedicated small-bowel cross-sectional imaging as the first diagnostic test in patients with suspected small-bowel bleeding, depending on availability, expertise, and clinical suspicion, when small-bowel capsule endoscopy is unavailable or contraindicated. Weak recommendation, low quality evidence.</p> <p>6. ESGE does not recommend routine second-look endoscopy prior to small-bowel capsule endoscopy in patients with suspected small-bowel bleeding or iron-deficiency anaemia. Strong recommendation, low quality evidence.</p> <p>7. ESGE recommends conservative management in those patients with suspected small-bowel bleeding and high quality negative small-bowel capsule endoscopy. Strong recommendation, moderate quality evidence.</p>
2. ESGE recommends against push-enteroscopy as the first-line investigation in patients with obscure gastrointestinal bleeding, because of its lower diagnostic yield compared with small-bowel capsule endoscopy (strong recommendation, moderate quality evidence).	
3. ESGE recommends performance of small-bowel capsule endoscopy as the first-line examination, before consideration of small bowel radiographic studies or mesenteric angiography, when small-bowel evaluation is indicated for obscure gastrointestinal bleeding (strong recommendation, high quality evidence). Computed tomography enterography/enteroclysis may be a complementary examination to capsule endoscopy in selected patients (weak recommendation, low quality evidence).	
4. Because of capsule endoscopy's excellent safety profile, patient tolerability, and potential for complete enteroscopy, ESGE recommends performance of small-bowel capsule endoscopy as the first-line examination, before consideration of device-assisted enteroscopy, when small-bowel evaluation is indicated for obscure gastrointestinal bleeding (strong recommendation, moderate quality evidence).	
5. In patients with overt obscure gastrointestinal bleeding ESGE recommends performing small-bowel capsule endoscopy as soon as possible after the bleeding episode, optimally within 14 days, in order to maximize the diagnostic yield (strong recommendation, moderate quality evidence).	
6. ESGE suggests that emergency small-bowel capsule endoscopy should be considered in patients with ongoing overt obscure gastrointestinal bleeding (weak recommendation, moderate quality evidence). In such patients, ESGE suggests that device-assisted enteroscopy should also be considered as a possible first-line test, given that it allows diagnosis and treatment in the same procedure (weak recommendation, low quality evidence).	
7. Given the spectrum of findings usually identified in patients with obscure gastrointestinal bleeding, when small-bowel capsule endoscopy is unavailable or contraindicated, ESGE suggests consideration of device-assisted enteroscopy as the first diagnostic test in these patients (weak recommendation, low quality evidence). ESGE suggests that device-assisted enteroscopy performed with diagnostic intent should be done as soon as possible after the bleeding episode (weak recommendation, low quality evidence).	
8. ESGE does not recommend the routine performance of second-look endoscopy prior to small-bowel capsule endoscopy; however whether to perform second-look endoscopy before capsule endoscopy in patients with obscure gastrointestinal bleeding or iron-deficiency anaemia should be decided on a case-by-case basis (strong recommendation, low quality evidence).	
9. ESGE recommends conservative management in those patients with obscure gastrointestinal bleeding (OGIB) and a negative small-bowel video capsule endoscopy (VCE) who do not have ongoing bleeding shown by overt bleeding or continued need for blood transfusions, since their prognosis is excellent and the risk of re-bleeding is low (strong recommendation, moderate quality evidence).	

► **Table 1** (Continuation)

ESGE Guideline 2015	ESGE Guideline 2022 (in bold if modified)
10. ESGE recommends further investigation using repeat VCE, device-assisted enteroscopy, or computed tomography-enterography/enteroclysis for patients with OGIB and a negative VCE who have ongoing bleeding shown by overt bleeding or continued need for blood transfusions (strong recommendation, moderate quality evidence).	8. ESGE recommends further investigation using repeat small-bowel capsule endoscopy, device-assisted enteroscopy, or dedicated small-bowel cross-sectional imaging for patients with suspected small-bowel bleeding and high quality negative small-bowel capsule endoscopy who have ongoing overt bleeding or continued need for blood transfusions. Strong recommendation, moderate quality evidence.
11. In patients with positive findings at small-bowel capsule endoscopy, ESGE recommends device-assisted enteroscopy to confirm and possibly treat lesions identified by capsule endoscopy (strong recommendation, high quality evidence).	9. ESGE recommends device-assisted enteroscopy to confirm and possibly treat lesions identified by small-bowel capsule endoscopy. Strong recommendation, high quality evidence.
Iron-deficiency anaemia	
12. In patients with iron-deficiency anaemia, ESGE recommends that prior to small-bowel capsule endoscopy, all the following are undertaken: acquisition of a complete medical history (including medication use, comorbidities, and gynaecological history in premenopausal females), oesophagogastroduodenoscopy with duodenal and gastric biopsies, and ileocolonoscopy (strong recommendation, low quality evidence).	10. ESGE recommends that in patients with iron-deficiency anaemia, the following are undertaken prior to small bowel evaluation: acquisition of a complete medical history, esophagogastroduodenoscopy with duodenal and gastric biopsies, and ileocolonoscopy. Strong recommendation, low quality evidence.
13. In patients with iron-deficiency anaemia, ESGE recommends performance of small-bowel capsule endoscopy as a first-line examination, before consideration of other diagnostic modalities, when upper and lower gastrointestinal endoscopies are inconclusive and small-bowel evaluation is indicated (strong recommendation, moderate quality evidence).	11. ESGE recommends the performance of small-bowel capsule endoscopy as a first-line examination in patients with iron-deficiency anaemia when small bowel evaluation is indicated. Strong recommendation, high quality evidence.
Suspected Crohn's disease	
14. ESGE recommends ileocolonoscopy as the first endoscopic examination for investigating patients with suspected Crohn's disease (strong recommendation, high quality evidence).	12. ESGE recommends ileocolonoscopy as the first endoscopic examination for investigating patients with suspected Crohn's disease. Strong recommendation, high quality evidence.
15. In patients with suspected Crohn's disease and negative ileocolonoscopy findings, ESGE recommends small-bowel capsule endoscopy as the initial diagnostic modality for investigating the small bowel, in the absence of obstructive symptoms or known stenosis (strong recommendation, moderate quality evidence).	13. ESGE recommends small-bowel capsule endoscopy in patients with suspected Crohn's disease and negative ileocolonoscopy findings as the initial diagnostic modality for investigating the small bowel, in the absence of obstructive symptoms or known bowel stenosis. Strong recommendation, high quality evidence.
16. ESGE does not recommend routine small-bowel imaging or the use of the PillCam patency capsule prior to capsule endoscopy in these patients (strong recommendation, low quality evidence).	14. ESGE does not recommend routine cross-sectional small-bowel imaging or the use of a patency capsule prior to capsule endoscopy to prevent the retention of the device in patients with suspected Crohn's disease. Strong recommendation, high quality evidence.
17. In the presence of obstructive symptoms or known stenosis, ESGE recommends that dedicated small-bowel cross-sectional imaging modalities such as magnetic resonance enterography/enteroclysis or computed tomography enterography/enteroclysis should be used first (strong recommendation, low quality evidence).	15. ESGE recommends that dedicated small-bowel cross-sectional imaging modalities be used first in patients with suspected Crohn's disease and obstructive symptoms or known bowel stenosis. Strong recommendation, moderate quality evidence.
	16. ESGE recommends the use of a patency capsule prior to small-bowel capsule endoscopy in patients with suspected Crohn's disease and obstructive symptoms. Strong recommendation, low quality evidence.
18. In the setting of suspected Crohn's disease, ESGE recommends careful patient selection (using the clinical history and serological/faecal inflammatory markers) prior to small-bowel capsule endoscopy, in order to improve the diagnostic accuracy of capsule endoscopy for lesions consistent with active small-bowel Crohn's disease (strong recommendation, low quality evidence).	17. ESGE recommends careful patient selection (using clinical history and serological/fecal inflammatory markers) prior to small-bowel capsule endoscopy to improve the diagnostic accuracy for lesions consistent with active small-bowel Crohn's disease. Strong recommendation, moderate quality evidence.

► **Table 1** (Continuation)

ESGE Guideline 2015	ESGE Guideline 2022 (in bold if modified)
19. ESGE recommends discontinuation of nonsteroidal anti-inflammatory drugs (NSAIDs) for at least 1 month before capsule endoscopy since these drugs may induce small-bowel mucosal lesions indistinguishable from those caused by Crohn's disease (strong recommendation, low quality evidence).	18. ESGE recommends discontinuation of both selective and non-selective nonsteroidal anti-inflammatory drugs, including short-term use, as well as of low dose and/or enteric-coated aspirin (if the patient's condition allows), for at least 4 weeks before capsule endoscopy since these drugs may induce small-bowel mucosal lesions that are indistinguishable from those caused by Crohn's disease. Strong recommendation, low quality evidence.
20. ESGE recommends device-assisted enteroscopy with small-bowel biopsy in patients with noncontributory ileocolonoscopy and with suspicion of Crohn's disease on small-bowel cross-sectional imaging modalities or small-bowel capsule endoscopy. Device-assisted enteroscopy with small-bowel biopsy is more likely to provide definitive evidence of Crohn's disease than cross-sectional imaging, although the latter offers a useful less invasive alternative that better defines transmural complication (strong recommendation, high quality evidence).	19. ESGE recommends device-assisted enteroscopy with small-bowel biopsies in patients with noncontributory ileocolonoscopy and suspected Crohn's disease on small-bowel cross-sectional imaging modalities or small-bowel capsule endoscopy. Strong recommendation, high quality evidence.
Established Crohn's disease	
21. In patients with established Crohn's disease, based on ileocolonoscopy findings, ESGE recommends dedicated cross-sectional imaging for small-bowel evaluation since this has the potential to assess extent and location of any Crohn's disease lesions, to identify strictures, and to assess for extraluminal disease (strong recommendation, low quality evidence).	20. ESGE recommends, in patients with established Crohn's disease based on ileocolonoscopy findings, dedicated cross-sectional imaging for small-bowel evaluation since this has the potential to assess the extent and location of any Crohn's disease lesions, to identify strictures, and to assess for extraluminal disease. Strong recommendation, high quality evidence.
22. In patients with unremarkable or nondiagnostic findings from such cross-sectional imaging of the small bowel, ESGE recommends small-bowel capsule endoscopy as a subsequent investigation, if deemed to influence patient management (strong recommendation, low quality evidence).	21. ESGE recommends, in patients with unremarkable or nondiagnostic findings from dedicated small-bowel cross-sectional imaging, small-bowel capsule endoscopy as a subsequent investigation if deemed likely to influence patient management. Strong recommendation, low quality evidence.
<i>Not addressed in the 2015 Guideline</i>	22. ESGE suggests that small-bowel capsule endoscopy may be useful for assessment of Crohn's disease extent and for monitoring and guiding the "treat-to-target" strategy. Weak recommendation, low quality evidence.
23. ESGE suggests the use of activity scores (such as the Lewis score and the Capsule Endoscopy Crohn's Disease Activity Index) to facilitate prospective small-bowel capsule endoscopy follow-up of patients for longitudinal assessment of the course of small-bowel Crohn's disease and its response to medical therapy (using mucosal healing as an end point) (weak recommendation, low quality evidence).	23. ESGE recommends the use of activity scores (such as the Lewis score and the Capsule Endoscopy Crohn's Disease Activity Index [CEDCAI]) to facilitate prospective small-bowel capsule endoscopy follow-up of patients for longitudinal assessment of small-bowel Crohn's disease and its response to medical therapy (using mucosal healing as an endpoint). Strong recommendation, low quality evidence.
24. When capsule endoscopy is indicated, ESGE recommends use of the PillCam patency capsule to confirm functional patency of the small bowel (strong recommendation, low quality evidence).	24. ESGE recommends, in patients with established Crohn's disease, the use of a patency capsule before small-bowel capsule endoscopy to decrease the capsule retention rate. Strong recommendation, moderate quality evidence.
25. ESGE recommends initial conservative treatment in the case of capsule retention. ESGE recommends device-assisted enteroscopy if medical therapy has not led to promote spontaneous passage (strong recommendation, low quality evidence).	25. ESGE recommends initial conservative treatment in the case of capsule retention. Strong recommendation, high quality evidence. 26. ESGE recommends device-assisted enteroscopy if medical therapy has not achieved spontaneous capsule passage. Strong recommendation, high quality evidence.
26. ESGE recommends device-assisted enteroscopy if small-bowel endotherapy is indicated (including dilation of Crohn's disease small-bowel strictures, retrieval of foreign bodies, and treatment of small-bowel bleeding) (strong recommendation, low quality evidence).	27. ESGE recommends device-assisted enteroscopy if small-bowel endotherapy is indicated (including dilation of Crohn's disease small-bowel strictures, retrieval of a retained capsule, and/or treatment of small-bowel bleeding). Strong recommendation, high quality evidence.
27. ESGE recognises small-bowel capsule endoscopy/device-assisted enteroscopy and magnetic resonance or computed tomography enterography/enteroclysis as complementary strategies (weak recommendation, low quality evidence). Cost-effectiveness data regarding optimal investigation strategies for diagnosis of small-bowel Crohn's disease are lacking.	<i>See statements 13, 15, 19, 20, 21, 27</i>

► **Table 1** (Continuation)

ESGE Guideline 2015	ESGE Guideline 2022 (in bold if modified)
Familial adenomatous polyposis	
28. ESGE recommends that surveillance of the proximal small bowel in familial adenomatous polyposis is best performed using conventional forward-viewing and side-viewing endoscopes (strong recommendation, moderate quality evidence).	28. ESGE recommends surveillance of the proximal small bowel in familial adenomatous polyposis using conventional forward-viewing and side-viewing endoscopes. Strong recommendation, moderate quality evidence.
	29. ESGE does not recommend small-bowel capsule endoscopy for surveillance of the proximal small bowel in familial adenomatous polyposis. Strong recommendation, moderate quality evidence.
29. When small-bowel investigation is clinically indicated in familial adenomatous polyposis, ESGE suggests that small-bowel capsule endoscopy and/or cross-sectional imaging techniques may be considered for identifying polyps in the rest of the small bowel, but the clinical relevance of such findings remains to be demonstrated (weak recommendation, moderate quality evidence).	30. ESGE suggests that small-bowel capsule endoscopy and/or cross-sectional imaging techniques may be considered when investigation of the mid-distal small-bowel is clinically indicated in familial adenomatous polyposis. Weak recommendation, moderate quality evidence.
Peutz–Jeghers syndrome	
30. ESGE recommends small-bowel surveillance in patients with Peutz–Jeghers syndrome. Small-bowel capsule endoscopy and/or magnetic resonance enterography/enteroclysis appear adequate methods for this purpose, depending on local availability and expertise, or patient preference (strong recommendation, moderate quality evidence)	31. ESGE recommends, for small bowel surveillance in patients with Peutz–Jeghers syndrome, small-bowel capsule endoscopy and/or magnetic resonance enterography, depending on local availability and expertise and/or patient preference. Strong recommendation, moderate quality evidence.
31. ESGE recommends device-assisted enteroscopy with timely polypectomy when large polyps (> 10–15 mm) are discovered by radiological examination or small-bowel capsule endoscopy in patients with Peutz–Jeghers syndrome (strong recommendation, moderate quality evidence).	32. ESGE recommends device-assisted enteroscopy with polypectomy when large polyps (> 15 mm) or symptomatic polyps are discovered by radiological examination or small-bowel capsule endoscopy in patients with Peutz–Jeghers syndrome. Strong recommendation, moderate quality evidence.
Juvenile polyposis	
<i>Not addressed in the 2015 Guideline</i>	33. ESGE recommends that routine evaluation of the small bowel in juvenile polyposis patients should be limited to the duodenum and based on flexible forward-viewing endoscopy. Strong recommendation, low quality evidence.
Small-bowel tumors	
32. ESGE recommends early use of small-bowel video capsule endoscopy in the search for a small-bowel tumour when obscure gastrointestinal bleeding and iron-deficiency anaemia are not explained otherwise (strong recommendation, moderate quality evidence).	34. ESGE recommends the use of small-bowel capsule endoscopy in patients where there is an increased risk of a small-bowel tumor. Strong recommendation, moderate quality evidence.
33. In the setting of suspicion of a small-bowel tumour, ESGE does not recommend specific investigations before small-bowel capsule endoscopy in patients without evidence for stenosis or previous small-bowel resection (strong recommendation, low quality evidence).	35. ESGE does not recommend, in the setting of suspected small-bowel tumor, specific investigations before small-bowel capsule endoscopy unless patients are considered to be at risk of capsule retention. Strong recommendation, low quality evidence.
34. ESGE recommends consideration of device-assisted enteroscopy in preference to small-bowel capsule endoscopy if imaging tests have already shown suspicion of small-bowel tumour (strong recommendation, low quality evidence).	36. ESGE recommends consideration of device-assisted enteroscopy in preference to small-bowel capsule endoscopy if imaging tests have already demonstrated suspected small-bowel tumor. Strong recommendation, low quality evidence.
35. ESGE recommends cross-sectional imaging to ascertain operability when there is a small-bowel capsule endoscopy finding of small-bowel tumour with a high diagnostic certainty. When there is uncertain diagnosis of small-bowel tumour at capsule endoscopy, biopsy sampling by device-assisted enteroscopy is required (strong recommendation, low quality evidence).	37. ESGE recommends cross-sectional imaging for staging and ascertaining operability when there is a small-bowel capsule endoscopy finding of a small-bowel tumor with high diagnostic certainty. Strong recommendation, low quality evidence.
	38. ESGE recommends, when there is an uncertain diagnosis of small-bowel tumor at capsule endoscopy, biopsy sampling and tattooing of its location by device-assisted enteroscopy. Strong recommendation, low quality evidence.

► **Table 1** (Continuation)

ESGE Guideline 2015	ESGE Guideline 2022 (in bold if modified)
36. When a submucosal mass is detected by small-bowel capsule endoscopy, ESGE recommends confirmation of the diagnosis by device-assisted enteroscopy (strong recommendation, low quality evidence).	39. ESGE recommends, when a subepithelial mass is detected by small-bowel capsule endoscopy, confirmation of the diagnosis by device-assisted enteroscopy and/or cross-sectional imaging, depending on local availability and expertise. Strong recommendation, low quality evidence.
37. When capsule endoscopy shows high suspicion of submucosal mass and there is a negative but incomplete device-assisted enteroscopy, ESGE suggests cross-sectional imaging tests to confirm the diagnosis (weak recommendation, low quality evidence).	
38. ESGE recommends against small-bowel capsule endoscopy in the follow-up of treated small-bowel tumours because of lack of data (strong recommendation, low quality evidence).	40. ESGE does not recommend small-bowel capsule endoscopy in the follow-up of treated small-bowel tumors because of lack of data. Strong recommendation, low quality evidence.
<i>Not addressed in the 2015 Guideline</i>	41. ESGE suggests considering enteroscopic placement of self-expanding metal stents in the palliation of malignant small-bowel strictures as an alternative option to surgery. Weak recommendation, low quality evidence.
Celiac disease	
39. ESGE strongly recommends against the use of small-bowel capsule endoscopy for suspected coeliac disease but suggests that capsule endoscopy could be used in patients unwilling or unable to undergo conventional endoscopy (strong recommendation, low quality evidence).	42. ESGE does not recommend small-bowel capsule endoscopy to diagnose celiac disease. Strong recommendation, low quality evidence.
40. ESGE recommends that there is no role for small-bowel capsule endoscopy in assessing the extent of disease or response to a gluten-free diet (strong recommendation, low quality evidence).	
41. ESGE suggests the use of small-bowel capsule endoscopy in cases of equivocal diagnosis of coeliac disease (weak recommendation, low quality evidence).	43. ESGE recommends using small-bowel capsule endoscopy in cases of equivocal diagnosis of celiac disease since it is essential for final diagnosis and therapy. Strong recommendation, low quality evidence.
42. ESGE recommends initial assessment by small-bowel capsule endoscopy followed by device-assisted enteroscopy in nonresponsive or refractory coeliac disease (strong recommendation, low quality evidence).	44. ESGE recommends in nonresponsive or refractory celiac disease, small-bowel capsule endoscopy followed by device-assisted enteroscopy for diagnosis and disease monitoring. Strong recommendation, high quality evidence.
Chronic abdominal pain	
<i>Not addressed in the 2015 Guideline</i>	45. ESGE does not recommend small-bowel capsule endoscopy as the first-line investigation for patients with isolated chronic abdominal pain. Strong recommendation, low quality evidence.
Foreign-body retrieval	
<i>Not addressed in the 2015 Guideline</i>	46. ESGE recommends device-assisted enteroscopy as an alternative to surgery for foreign bodies retained in the small bowel requiring retrieval in patients without acute intestinal obstruction. Strong recommendation, moderate quality evidence.
DAE-assisted percutaneous endoscopic jejunostomy (PEJ) for enteral feeding	
<i>Not addressed in the 2015 Guideline</i>	47. ESGE suggests that in patients requiring jejunostomy for enteral feeding, DAE-assisted percutaneous endoscopic jejunostomy (PEJ) is a possible alternative to surgical jejunostomy. Weak recommendation, moderate quality evidence.
DAE-ERCP in patients with altered anatomy	
<i>Not addressed in the 2015 Guideline</i>	48. ESGE recommends DAE-ERCP as a first-line endoscopic approach to treat pancreaticobiliary diseases in patients with surgically altered anatomy (except for Billroth II patients). Strong recommendation, moderate quality evidence.
DAE, device-assisted enteroscopy; ERCP, endoscopic retrograde cholangiopancreatography; ESGE, European Society of Gastrointestinal Endoscopy; PEJ, percutaneous endoscopic jejunostomy	

As already stated in previous guidelines [1] and on the basis of all the above scientific evidence, SBCE can be recommended as the first-line investigation in patients with SSBB. This agrees with the recommendations of other scientific societies [4, 21, 22].

► **Fig. 1** presents recommended approaches for diagnosis and treatment of SSBB.

RECOMMENDATION

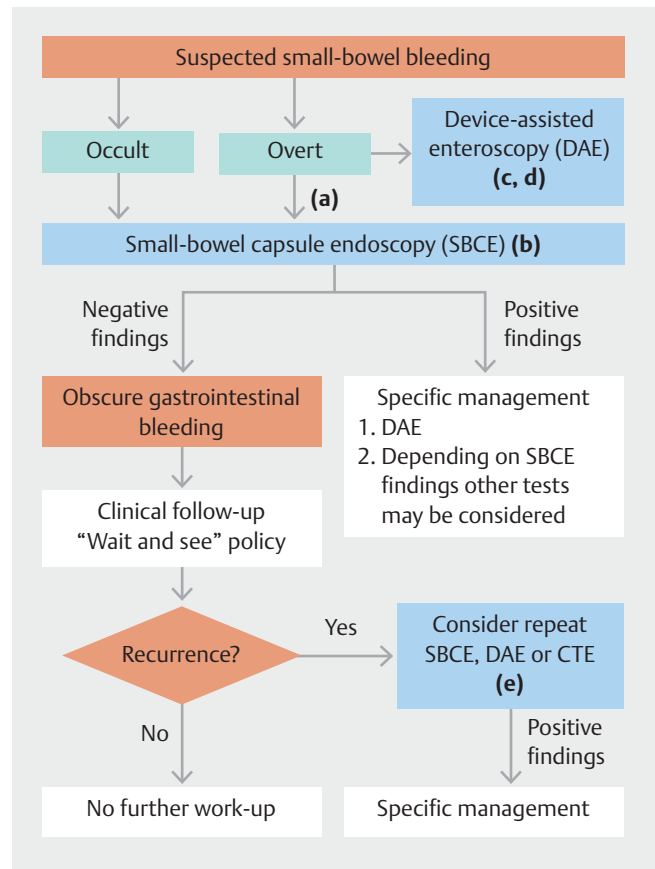
ESGE recommends small-bowel capsule endoscopy in patients with overt suspected small-bowel bleeding as soon as possible after the bleeding episode, ideally within 48 hours, to maximize the diagnostic and subsequent therapeutic yield.

Strong recommendation, high quality evidence.

Despite the unquestionable role of early SB evaluation in patients with SSBB, especially in cases of overt bleeding, the optimal timing is still debated. The 14-day timeframe, suggested in the previous ESGE guideline [1], is somewhat arbitrary and quite broad.

Since the publication of the initial guideline [1], six retrospective studies and two meta-analyses have been published to compare the diagnostic and therapeutic yield of SB endoscopic procedures in the setting of overt SB bleeding according to the timing of SB evaluation (performed with either SBCE or DAE).

Zhao et al. [23] carried out a propensity score-matching study on 997 patients, that supported previous ESGE statements; they found that early SBCE (within 14 days from last bleeding event) was associated with a significantly higher rate of diagnosis (56.4% vs. 45.5%, $P=0.001$), with ORs of 0.648 (95%CI 0.496–0.847, $P=0.001$) and 0.666 (95%CI 0.496–0.894, $P=0.007$) at univariate and multivariate analysis, respectively. In this study, the incidence of rebleeding within 1 year following treatment was significantly lower (24.7% vs. 36.7%, $P=0.041$) for patients who underwent early SBCE. Chao et al. [24] reported a detection rate for the source of bleeding ranging from 70% to 77.6% if SBCE was performed in the first 3 days from the first bleeding episode in patients ($n=60$) with overt bleeding. In contrast, the detection rate decreased to 36.4% if SBCE was performed after the 4th day. Using a 48-hour cut-off, Kim et al. [25] found that among 94 patients, the 30 who underwent SBCE within 2 days from the last bleeding had a greater diagnostic yield (66.7% vs. 40.6%, $P=0.019$), a greater subsequent therapeutic yield (24.7% vs. 9.4%, $P=0.028$) and a shorter hospital stay (5 days, 95%CI 4.8–7.7 vs. 7 days, 95%CI 6.9–10.1, $P=0.039$). A shorter hospital stay, as well as a decrease in resource utilization in the index hospitalization, was also demonstrated by Wood et al. [26] in inpatients receiving an early SBCE. Iio et al. [27] found a lesion detection rate of 80% (12/15) in patients with ongoing overt bleeding who underwent early SBCE (15/127) compared to 47% (53/112) in the “late” group ($P=0.0174$). These data were consistent with the



► **Fig. 1** Recommended approaches for diagnosis and treatment of suspected small-bowel bleeding (SSBB). **a** In patients with overt SSBB, small-bowel capsule endoscopy (SBCE) should be performed as soon as possible after the bleeding episode, ideally within 48 hours. **b** When SBCE is contraindicated or unavailable, device-assisted enteroscopy (DAE) and/or dedicated small-bowel (SB) cross-sectional imaging may be considered for SB evaluation, depending on availability, expertise, and clinical suspicion. **c** DAE can also be considered as alternative first-line examination in selected cases, depending on the clinical scenario and local availability, and should be performed optimally within 48–72 hours after the bleeding episode. **d** In patients with significant active bleeding and unsuitable for flexible endoscopy, computed tomography (CT) angiography or angiography may be considered. **e** Upper and/or lower gastrointestinal endoscopy may also be considered on a case-by-case basis to identify lesions overlooked at baseline endoscopy. CTE, computed tomography enterography.

results of Song et al. [28], who showed that early deployment of SBCE results in a significantly higher diagnostic yield (OR for relevant lesion detection was 4.99 for <24-h group vs. 8-day group). On the other hand, in the study of Gomes et al. [29] ($n=115$), where the timing of SBCE was further divided (≤ 48 h, 48h–14 d, ≥ 14 d), the overall diagnostic yield was high (about 80%) and similar among the three groups irrespective of SBCE timing ($P=0.39$). However, the three timing-based subgroups were small (about 30 patients in each) and when SBCE was performed within 48 hours, a trend toward an increased diagnostic yield was observed ($P=0.06$). In addition, the early group showed the highest therapeutic yield (66.7% vs. 40% vs. 31.7%, $P=0.005$) and the lowest rebleeding rate (15.4% vs.

34.3% vs. 46.3%, $P=0.007$), with a longer time to rebleed when compared with the >48-h groups ($P=0.03$).

Recently, a meta-analysis from Uchida et al. [30], by pooling 19 previous studies (9 prospective, 9 retrospectives, 1 unspecified), confirmed that performing SBCE within 2 days leads to high diagnostic and therapeutic yields (55.9% and 65.2%, respectively). However, the metaregression was based on subgroups with small sample size and heterogeneous data [30]. The largest meta-analysis available so far, involving 39 studies, confirmed higher pooled diagnostic yields for SBCE performed in the first 24, 48, and 72 hours, being 83.4% (95%CI 76.30%–90.46%), 81.3% (95%CI 75.20%–87.43%) and 63.6% (95%CI 45.59%–81.51%), respectively. The pooled therapeutic yields for the same timings were 57.56% (95%CI 36.95%–78.16%), 59.09% (95%CI 43.66%–74.52%) and 18.90% (95%CI 11.26%–26.54%), respectively [31].

RECOMMENDATION

ESGE suggests that device-assisted enteroscopy be considered as an alternative first-line test in selected cases, given that it allows diagnosis and treatment in the same procedure, depending on the clinical scenario and local availability.

Weak recommendation, low quality evidence.

RECOMMENDATION

ESGE recommends, in patients with overt suspected small-bowel bleeding, device-assisted enteroscopy to be performed optimally within 48–72 hours after the bleeding episode.

Strong recommendation, high quality evidence.

Two previously mentioned studies [30,31] not only evaluated the diagnostic yield of SBCE but also dealt with the performance of DAE in the same setting. According to Estevinho et al. [31], the pooled diagnostic and therapeutic yields of early DAE were superior to those of SBCE by 7.97 and 20.89 percentage points, respectively ($P<0.05$). However, it is not possible to exclude that the DAE results may be influenced both by a selection bias, related to patient features (e.g., patients undergoing direct DAE are likely to have more severe bleeding), and by a detection bias, since several patients may have received another diagnostic test, with a positive result, before DAE. In addition, urgent DAE may raise significant organizational issues; it is not readily available in most centers and requires trained personnel.

Therefore, even in overt SSBB, a sequential approach with a diagnostic examination (e.g., SBCE, CT angiography etc.) followed by a potentially therapeutic one (e.g., DAE) should be preferred. Performance of DAE in the first 72 hours is most often dependent on performance of SBCE in the first 48 hours [31]. A recent retrospective study with a large sample size of

patients undergoing both SBCE and DBE [32] also confirmed that a short interval between the two procedures maximizes the effectiveness of the diagnostic/therapeutic process. Although the agreement between SBCE and DBE was generally rated as suboptimal ($k=0.059$), it markedly improved ($k=0.323$) when the procedures were performed within 1–5 days of each other. As demonstrated for SBCE, in the overt SB bleeding setting, recent data confirm the importance of keeping the interval between DAE and the bleeding episode as short as possible. In fact, in the pooled analysis of double-arm studies [31], the odds for a positive diagnosis (OR 3.99; $P<0.01$; $I^2=45\%$) and subsequent therapeutic intervention (OR 3.86; $P<0.01$; $I^2=67\%$) were significantly superior in the early group, for either DAE or SBCE.

RECOMMENDATION

ESGE suggests consideration of device-assisted enteroscopy and/or dedicated small-bowel cross-sectional imaging as the first diagnostic test in patients with suspected small-bowel bleeding, depending on availability, expertise, and clinical suspicion, when small-bowel capsule endoscopy is unavailable or contraindicated.

Weak recommendation, low quality evidence.

SBCE has a very limited number of absolute contraindications [33], such as GI obstruction. However, SBCE may also be unavailable, especially in emergency settings, although lately, there is a trend of increasing use outside the endoscopy suite [34]. Overall, there is not enough evidence-based data to recommend a single specific examination as first-line when SBCE is unavailable. A meta-analysis [9] of a total of 18 studies ($n=660$ patients) reported the pooled diagnostic yield of CTE in evaluating SSBB as 40% (95%CI 33%–49%). Seven studies ($n=279$) compared the yield of CTE with SBCE. The yields for CTE and SBCE for all findings were 34% and 53%, respectively (incremental yield –19%, 95%CI –34% to –4%). Therefore, CTE has been described as an effective modality to show the precise location of bleeding and guide subsequent enteroscopy management, especially in patients with bleeding from tumors and overt bleeding [9]. In an emergency setting, DAE has been described as effective as suggested by a recent systematic review and meta-analysis [31], including retrospective studies in which this procedure was performed as first-line for selected patients.

RECOMMENDATION

ESGE does not recommend routine second-look endoscopy prior to small-bowel capsule endoscopy in patients with suspected small-bowel bleeding or iron-deficiency anemia.

Strong recommendation, low quality evidence.

Good quality upper and lower GI endoscopy is crucial in the investigation of SSBB. Evidence and recent guidelines propose an acceptable minimal examination time to ensure good quality examination and meeting minimum standards [35,36]. In patients where bidirectional endoscopy has been negative, with the persistence of symptoms or suspicion of SB bleeding, SBCE is the preferred next diagnostic test. Several studies had investigated routine second-look endoscopy before capsule endoscopy and highlighted this as not being cost-effective, as stated in the 2015 Guideline [1]. Since the publication of the latter, eight further studies have been published on this subject. A study by Innocenti et al. [37] showed non-SB lesions detected in 30% of cases, of which 43% were bleeding. The study was retrospective and without randomization. Similarly, another retrospective study by Clere-Jehl et al. [38] studied 69 endoscopy-negative patients >65 years, with persistent IDA. Further investigations were performed in 45 patients; 64% of the second-look GI endoscopies led to significant changes in treatment compared with 25% for the capsule endoscopies. Conventional diagnoses of IDA were ultimately established for 19 (27%) patients and included 3 cancer patients suggesting second-look endoscopy is favored for persistent IDA. On the other hand, a prospective study by Riccioni et al. [39] showed that at SBCE, findings in the upper GI tract were found in 21% and the colon in 6.4%. Subsequent studies by Akin et al. [40], Hoedemaker et al. [41], and Juanmartiñena Fernández et al. [42–44] (this last group published three separate studies about esophageal, gastroduodenal, and colonic findings on SBCE), all retrospective in nature, conclude that clinicians should carefully review not just SB images but also those of the esophagus, stomach, and colon.

There have been no further cost-effectiveness studies.

Overall, the current literature is inadequate to support routine repetition of standard endoscopy, and this should be reserved on a case-by-case basis. However it highlights the importance of a good standard of baseline endoscopy performance.

RECOMMENDATION

ESGE recommends conservative management in those patients with suspected small-bowel bleeding and high quality negative small-bowel capsule endoscopy. Strong recommendation, moderate quality evidence.

RECOMMENDATION

ESGE recommends further investigation using repeat small-bowel capsule endoscopy, device-assisted enteroscopy, or dedicated small-bowel cross-sectional imaging for patients with suspected small-bowel bleeding and high quality negative small-bowel capsule endoscopy who have ongoing overt bleeding or continued need for blood transfusions. Strong recommendation, moderate quality evidence.

Analogously to upper and lower GI endoscopy, for SBCE to be considered a reliable diagnostic tool on which subsequent follow-up is based, it must be rated a high quality examination, according to ESGE quality standards [45], and evaluated by a dedicated and properly trained reader, according to ESGE curriculum criteria [46]. Even more than in upper and lower endoscopy, given the passive nature of capsule endoscopy (e.g., lavage and aspiration cannot be done), the characteristics of the luminal contents (e.g., presence of bubbles, fecal material, or turbid fluid) strongly impact the quality of the examination. Therefore, adequate SB visualization is a crucial element in ensuring a reliable assessment of the small intestine. Although the current ESGE technical guidelines specifically address this issue [47], the evidence is rapidly evolving [48] and remains somewhat controversial [49].

A systematic review and meta-analysis [50], including 26 mostly high quality studies with 3657 individuals, showed that a negative SBCE implies adequate assurance of a subsequently low risk of rebleeding. The pooled rate of rebleeding after negative SBCE was 0.19 (95%CI 0.14–0.25; $P<0.0001$). The pooled OR of rebleeding was 0.59 (95%CI 0.37–0.95; $P<0.001$), and moreover, the effect was more pronounced in studies with a short follow-up (OR 0.47, 95%CI 0.24–0.94; $P<0.001$). On top of that, prospective studies showed a lower OR of rebleeding at 0.24 (95%CI 0.08–0.73; $P=0.01$). Lastly, there was no statistically significant difference in rebleeding after SBCE for occult and overt OGIB. Therefore, patients with negative SBCE after an episode of SSBB can be safely managed with watchful waiting, at least in the short term [51, 52].

However, in the long-term, recurrence of bleeding is not uncommon [53–55], and further investigations could be required. In these cases, repeating the diagnostic workup by SBCE appears to have more diagnostic value than DAE; a small study from Japan showed that the rate of positive findings in the repeat SBCE group was significantly higher than in the DBE group [56]. A closer follow-up has been proposed in patients with a higher red blood cell transfusion requirement previous to an SBCE and overt bleeding [55,57,58] or severe anemia [59], as they are associated with higher rebleeding rates. Recently, de Sousa Magalhães et al. developed and validated a score (RHE-MITT) that accurately predicts the individual risk of SB rebleeding after initial SBCE [60,61].

RECOMMENDATION

ESGE recommends device-assisted enteroscopy to confirm and possibly treat lesions identified by small-bowel capsule endoscopy. Strong recommendation, high quality evidence.

It is known that the diagnostic yield of DBE significantly improves if DBE is preceded by a positive SBCE [6] and a recent meta-analysis reported that this sequential approach increased the diagnostic yield for vascular lesions by 7% [62]. Moreover, in patients with negative SBCE, a subsequent DBE can identify the source of the bleeding in about one third [6, 56]. In addition

to its therapeutic possibilities, DBE has been reported to help clarify the origin of bleeding when SBCE shows only blood in the lumen or doubtful findings [63]. The correct management of patients with SSB is involves using both techniques.

Although several studies have assessed the diagnostic and therapeutic yield of SBCE and DAE in SB bleeding, the emphasis should be on meaningful results when we consider outcomes in clinical practice. In this clinical setting, a positive patient outcome should be either bleeding cessation or anemia resolution. In addition, other important clinical outcomes for evaluation may include mortality and hemoglobin levels or the reduction in the numbers of endoscopic procedures, hospitalizations, and blood transfusions.

In this regard, both the older literature [1] and the more recent studies evaluating the impact of SB endoscopy on the clinical outcomes of patients with SB bleeding have produced conflicting results [32, 64–68]. This is probably because considerable heterogeneity exists across studies in the definition, relevance, and clinical management of vascular lesions and follow-up periods. Furthermore, the studies differ in the severity of the bleeding of the enrolled patients, and, above all, a standardized intervention protocol for the identified bleeding lesions had not always been established a priori. Though a recent meta-analysis [31] assessing the impact of early SB endoscopy in patients with overt SSB showed a lower recurrent bleeding rate (OR 0.40; $P < 0.01$; $I^2 = 0\%$) when SBCE/DAE was performed very close to the bleeding episode, further high quality research, including randomized trials, is needed to clarify the open questions and clinical management regarding SB bleeding.

Iron-deficiency anemia

RECOMMENDATION

ESGE recommends that in patients with iron-deficiency anemia, the following are undertaken prior to small-bowel evaluation: acquisition of a complete medical history, esophagogastroduodenoscopy with duodenal and gastric biopsies, and ileocolonoscopy. Strong recommendation, low quality evidence.

RECOMMENDATION

ESGE recommends the performance of small-bowel capsule endoscopy as a first-line examination in patients with iron-deficiency anemia when small bowel evaluation is indicated. Strong recommendation, high quality evidence.

The evidence published since the previous ESGE guideline [1] and the most recent practice guideline on IDA [69] confirm that, before evaluation of the small-bowel, patients with IDA should undergo a thorough anamnestic evaluation and a multi-

step diagnostic–therapeutic workup that includes endoscopic evaluation of the upper and lower digestive tract.

Furthermore, the British Society of Gastroenterology (BSG) guideline for the management of IDA in adults [69] recommends that, before the SB evaluation is planned, an empirical iron replacement trial (IRT), should be performed with appropriate dosage and duration. According to the BSG guideline, endoscopic SB examination should be performed only if the target values are not reached in the initial IRT or if anemia recurs at the end of treatment. However, no clinical trials have compared the clinically relevant outcomes (e. g., diagnostic yield and possible diagnostic delay) in patients referred for SB study according to the IRT outcome. This policy may lead to different results in different subgroups of patients. Therefore, the available evidence appears insufficient to recommend using the IRT as a decision-making tool in deciding to perform an SB study.

Considering multiple clinical issues, a comprehensive overall assessment should always be performed when planning SBCE. Several studies pursued the aim of identifying such predictive factors for SB pathology. Male sex, older age, low mean corpuscular volume (MCV), low hemoglobin values, high transfusion requirement, use of nonsteroidal anti-inflammatory drugs (NSAIDs) in the last 2 weeks before SBCE, and antithrombotic therapy have been demonstrated to correlate with diagnostic yield in IDA patients [70–75]. Hypoalbuminemia has also been shown to increase the proportion of positive findings at SBCE in a subgroup of celiac disease patients presenting with persistent IDA despite a gluten-free diet (GFD) [76].

In recent years, new evidence has also emerged concerning the possible role of fecal occult blood testing (FOBT), either guaiac or immunochemical, as a filter test to select IDA patients for SBCE [77–79]. The meta-analysis by Yung et al. [80] found, for all positive FOBT, sensitivity 0.60 (95%CI 0.50–0.69), specificity 0.72 (95%CI 0.52–0.86), and diagnostic OR 3.96 (95%CI 1.50–10.4) for SB findings. Corresponding values for fecal immunochemical testing alone were sensitivity 0.48 (95%CI 0.36–0.61), specificity 0.60 (95%CI 0.42–0.76), and diagnostic OR 1.41 (95%CI 0.72–2.75). Nevertheless, there is still insufficient evidence to recommend FOBT in routine practice as a screening tool for deciding whether to perform SBCE in IDA patients. Larger studies may better clarify its usefulness and lead to future guidance changes.

In recent years, it has also been shown that, although there are some differences in terms of both diagnostic yield and the spectrum of findings between young and elderly patients, age is not a discriminating factor when SB studies are performed in patients with IDA and negative bidirectional endoscopy [74]. Interestingly, two studies [81, 82] focused on the subgroup of female IDA patients and showed a lower diagnostic yield in premenopausal women compared to post-menopausal women. Moreover, Silva et al. [82] found that in premenopausal women, only 1.8% required therapeutic endoscopy, whereas in 17.3% of post-menopausal women, SBCE findings led to additional endoscopic treatment. Furthermore, the rebleeding rate at 1, 3 and 5 years was 3.6%, 10.2%, and 10.2% in premenopausal women and 22.0%, 32.3%, and 34.2% in post-menopausal women. These figures might suggest a higher threshold for SBCE in pre-

menopausal women. However, this evidence is insufficient to make any firm recommendation.

According to previous ESGE guidelines [1], large studies have confirmed that SBCE is the test of choice for evaluating the small intestine in patients with IDA, both because of its high diagnostic yield and favorable safety profile [70,71,77,83,84]. In contrast, there is conflicting and inconclusive evidence about the role of second-look endoscopy before SBCE in IDA patients [37,38,73]. Therefore, repetition of upper and lower endoscopies should be decided on a case-by-case basis, considering the timing and quality of upper and lower endoscopy performed before SBCE.

Furthermore, recent data confirm that negative SBCE provides adequate evidence of a low risk of rebleeding. Such patients can therefore be safely managed with watchful waiting [50,53,85,86]. Nevertheless, SB neoplasia and diverticula are mural-based lesions that can cause IDA but can be missed at SBCE, and for which CTE has been shown to have higher sensitivity [9,17,87]. Since the 2015 ESGE clinical guideline [1] there have been no recent large studies that have investigated the diagnostic yield of DAE exclusively in IDA patients. However, performance can be similar to that reported for patients in the SSBB setting.

Crohn's disease

Suspected Crohn's disease

RECOMMENDATION

ESGE recommends ileocolonoscopy as the first endoscopic examination for investigating patients with suspected Crohn's disease.

Strong recommendation, high quality evidence.

RECOMMENDATION

ESGE recommends small-bowel capsule endoscopy in patients with suspected Crohn's disease and negative ileocolonoscopy findings as the initial diagnostic modality for investigating the small bowel, in the absence of obstructive symptoms or known bowel stenosis.

Strong recommendation, high quality evidence.

RECOMMENDATION

ESGE does not recommend routine cross-sectional small-bowel imaging or the use of a patency capsule prior to capsule endoscopy to prevent the retention of the device in patients with suspected Crohn's disease.

Strong recommendation, high quality evidence.

Up to 83% of patients with CD have SB involvement at diagnosis [88], and in approximately 90% of patients with SB CD, the disease involves the terminal ileum [89]. Thus, ileocolono-

scopy is considered to be the first-line investigation for CD and is sufficient to establish the diagnosis in most patients [90]. While the addition of capsule assessment may improve specificity, the discriminatory ability of SBCE was shown in a recent study not to be superior to ileocolonoscopy alone as an initial investigation for CD [91].

Skip lesions may result in a false-negative ileocolonoscopy [92], and SBCE should be considered when ileoscopy is not achieved or when proximal SB disease must be excluded.

For patients with suspected CD, two recent meta-analyses have confirmed SBCE has a diagnostic yield for SB disease similar to that of magnetic resonance enterography (MRE), CTE, and abdominal ultrasound, while confirming its superiority to both small-bowel follow-through and enteroclysis [93,94]. Subgroup analysis of the 2017 meta-analysis of Koplov et al. [93] suggests that for patients with established disease, SBCE is more sensitive for proximal (jejunal) disease compared with MRE (OR 2.79, 95%CI 1.2–6.48; $P=0.02$). Similarly, Choi et al.'s meta-analysis [94] found that SBCE detected more ileal disease in patients with established CD than ileocolonoscopy (SBCE 60% vs. ileocolonoscopy 48%; weighted incremental yield [Iyw] 0.11, 95%CI 0.00–0.22; $P=0.004$). Two recent studies have confirmed a diagnostic advantage for SBCE in assessing SB disease in established CD, for the entire small bowel versus MRE [95], and for the proximal and mid-small bowel versus MRE and CTE [96]. These studies support SBCE as the appropriate next investigation in patients with suspected CD after failed ileocolonoscopy and as the most sensitive means of mapping SB disease in patients with established CD [95,96].

SBCE should be seen as complementary to ileocolonoscopy in doubtful cases, to confirm the diagnosis and simultaneously determine disease location, extent, and activity. Even after positive ileocolonoscopy findings, SBCE can add important diagnostic information and support a CD diagnosis.

A retrospective observational study by Freitas et al. [97] investigated 102 patients found to have "isolated terminal ileitis" at ileocolonoscopy, endoscopic abnormalities proximal to the terminal ileum were found in 36.3% of patients; one third (35/102) were finally diagnosed with CD. Similarly, isolated ileitis on SBCE can frequently herald an ultimate diagnosis of CD, even in patients with an initial negative ileocolonoscopy [98,99].

The risk of capsule retention in patients with suspected CD, without obstructive symptoms or known stenosis, and no history of SB resection is low and similar to that of patients who are being investigated for SB bleeding [100]. A careful clinical history may be the most helpful way to determine the risk of capsule retention in this setting.

In 2017, Rezapour et al. [16] published a meta-analysis showing a slightly higher SBCE retention rate even in suspected CD than previously reported. Retention rates were 8.2% (95%CI 6.0%–11.0%) for established CD and 3.6% (95%CI 1.7%–8.6%) for suspected CD (studies of patients with strictures on CTE/MRE or patency capsule retention were excluded). However, there was significant heterogeneity among the studies ($I^2=69\%$).

A more recent meta-analysis by Pasha et al. [100] evaluated SBCE retention in patients with suspected and established CD. The retention rate in patients with established CD was 4.63% (95%CI 3.42%–6.25%; 32 studies) and in patients with suspected CD it was 2.35% (95%CI 1.31%–4.19%; 16 studies). Patients with established CD were 3.5 times more likely to experience retention than those with suspected CD (95%CI 2.12–5.78; 16 studies).

Several additional observational studies have also reported a low risk of capsule retention in patients with suspected CD [91, 101–103]. These studies have also shown that the use of either cross-sectional imaging [101, 102] or patency capsule tests [102] in high risk patients with suspected CD (suspected stricture) can avoid capsule retention.

RECOMMENDATION

ESGE recommends that dedicated small-bowel cross-sectional imaging modalities be used first in patients with suspected Crohn's disease and obstructive symptoms or known bowel stenosis.

Strong recommendation, moderate quality evidence.

RECOMMENDATION

ESGE recommends the use of a patency capsule prior to small-bowel capsule endoscopy in patients with suspected Crohn's disease and obstructive symptoms.

Strong recommendation, low quality evidence.

If patients with suspected CD present with obstructive symptoms or known stenosis, dedicated SB cross-sectional imaging in the form of CTE or MRE (which may also provide an additional evaluation of mural and extramural disease) should be the investigation of choice.

Recent studies have shown a high incidence of SB strictures in patients with newly diagnosed CD, particularly in those with isolated SB rather than ileocolonic disease (OR 3.04, $P=0.02$ [104]; and 20.5% vs. 9.4%, $P=0.002$ [105]). The efficacy of MRE to detect SB stenosis has been confirmed in a meta-analysis [106] and a comparative observational study with enteroscopy [107], reporting sensitivities of 65% and 61% and specificities of 93% and 93%, respectively. Moreover, magnetic resonance imaging (MRI) combined with clinical assessment can accurately predict complications (fistulas in 98% and intra-abdominal abscesses in 99%) [108].

The retrospective study by Al-Bawardy et al. [109] revealed that patients with SBCE retention were more likely to have, as identified on pre-SBCE CTE, strictures (63% vs. 23%), partial SB obstruction (63% vs. 38%), or SB anastomosis (88% vs. 23%), as compared with patients who had passed the capsule. SBCE may still be applied in this setting if the use of a patency capsule confirms the functional patency of the small bowel. Dedicated SB cross-sectional imaging can overestimate or have low specificity and low positive predictive value (PPV) for the presence of

stenosis [110, 111]. Therefore, use of a patency capsule is recommended even in cases of negative findings from cross-sectional modalities in those with suspected CD and obstructive symptoms. A study in 2016 by Rondonotti et al. [110] supports this assertion, with capsule retention occurring in their at-risk cohort with negative CTE findings prior to SBCE. Rozen-dorn et al. [111] evaluated the ability of MRE to predict retention; because of the low specificity (59%) and low PPV (40%) of MRE for prediction of retention, the authors also recommended patency capsule use prior to SBCE in at-risk patients, regardless of MRE findings.

The corollary is also true; in 2008, Herrerias et al. [112] evaluated 106 patients with stenosis seen on small-bowel follow-through or CT, who were subsequently also given a patency capsule. The patency capsule confirmed functional patency in 59 patients (56%). These patients later underwent SBCE safely, with no cases of capsule retention. González-Suárez et al. reported similar overestimation of stenosis for MRE [95].

It is also important to note that a few case series have reported patency capsule retention in patients with suspected CD [113, 114]. In all patients with findings of wall thickening or stenosis, CT was performed before patency capsule use. Patency capsule retention may cause transient obstructive symptoms, which usually resolve spontaneously, albeit resultant SB perforation has been reported [114, 115].

RECOMMENDATION

ESGE recommends careful patient selection (using clinical history and serological/fecal inflammatory markers) prior to small-bowel capsule endoscopy to improve the diagnostic accuracy for lesions consistent with active small-bowel Crohn's disease.

Strong recommendation, moderate quality evidence.

SBCE is indicated for investigating patients with suspected CD, nondiagnostic terminal ileitis, or inflammatory bowel disease, type unclassified (IBD-U) [116]. Symptoms alone are a poor predictor of CD. The International Conference on Capsule Endoscopy (ICCE) [117] recommended a broader definition of suspected CD that includes inflammatory markers, abnormal imaging, and/or extraintestinal manifestations [118, 119]. It has also been demonstrated that ICCE criteria can be used as an effective selection tool for SBCE since patients with fewer than two ICCE criteria are not only unlikely to have inflammatory changes in the small bowel but also to be diagnosed with CD in the follow-up [118].

Recent meta-analyses have consistently demonstrated that fecal calprotectin has significant diagnostic accuracy for detecting SB CD [120–122]. The likelihood of a positive diagnosis is very low in patients with suspected CD with calprotectin $<50\mu\text{g/g}$. A cutoff of $100\mu\text{g/g}$ has demonstrated high sensitivity and specificity and appears to be the optimal cutoff value to be used as a screening tool for SB CD [118, 121]. Moreover, in a prospective validation study, a combined diagnostic strategy

based on clinical presentation with Red Flags index score ≥ 8 and/or fecal calprotectin $>250\text{ ng/g}$ showed average values (ranges) of sensitivity 100% (29%–100%), specificity 72% (55%–85%), PPV 21% (5%–51%), and NPV 100% (88–100%) for the diagnosis of CD [123]. Evidence also shows that a combination of biomarkers can further enhance patient selection.

A diagnostic workflow is proposed for investigation of patients with suspected CD and nondiagnostic ileocolonoscopy (► Fig. 2).

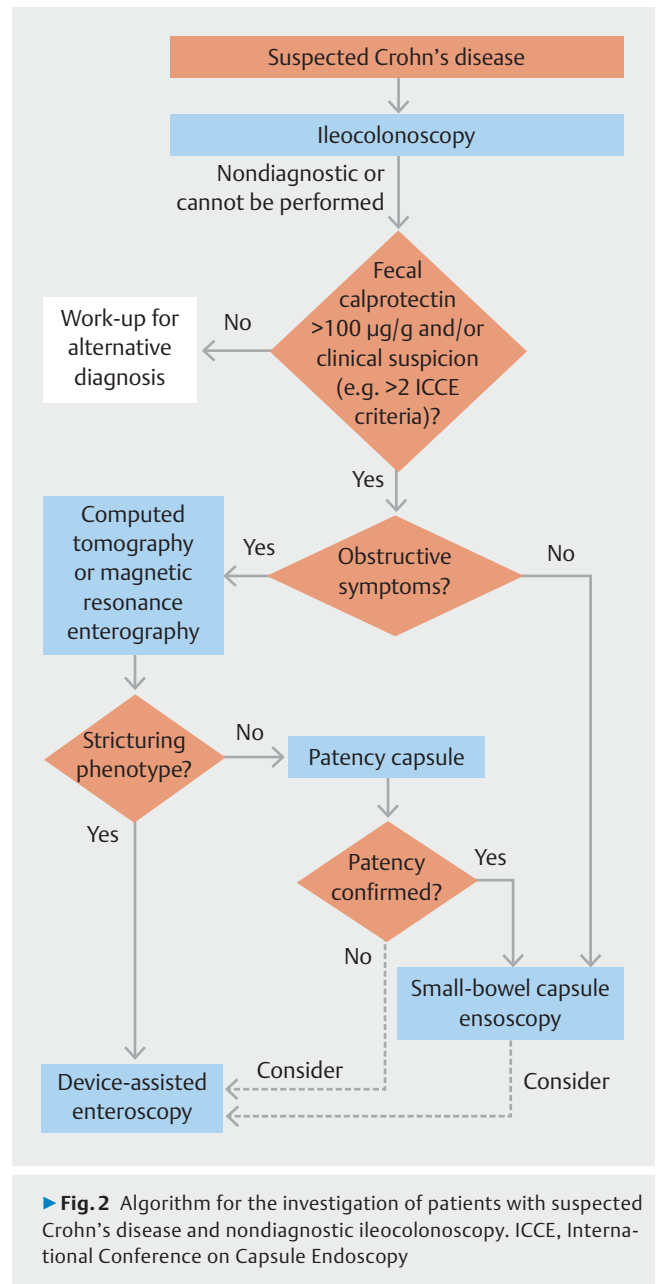
RECOMMENDATION

ESGE recommends discontinuation of both selective and nonselective nonsteroidal anti-inflammatory drugs, including short-term use, as well as of low dose and/or enteric-coated aspirin (if the patient's condition allows), for at least 4 weeks before capsule endoscopy since these drugs may induce small-bowel mucosal lesions that are indistinguishable from those caused by Crohn's disease. Strong recommendation, low quality evidence.

NSAIDs, including enteric-coated or low-dose aspirin, are a common cause of SB erosions and ulcerations because of direct toxicity and systemic effects on prostaglandin metabolism. Cyclo-oxygenase 2 (COX 2)-selective agents have also been shown to cause comparable SB damage; therefore, the current ESGE recommendations apply to both selective and nonselective NSAIDs. Severe enteropathy, such as circumferential ulcers with stricturing (diaphragmatic disease), has been described in approximately 2% of patients on long-term NSAID use [124]. Short-term use results in SB injury in most patients, manifesting as multiple petechiae or red spots, erythematous patches, loss of villi, erosions, and ulcers [125]. After only 2 weeks of treatment, up to 71% of patients have some evidence of drug-induced SB lesions [124, 126, 127], and the reported prevalence in long-term low dose aspirin users is 88.5%–100% [128]. Characteristic features of NSAID-induced injury include: (i) multiple superficial lesions; (ii) similar distribution in the jejunum and ileum; (iii) lesions $<1\text{ cm}$; (iv) uncommon ileocecal valve involvement [129].

The use of proton pump inhibitors (PPIs), histamine H₂-receptor antagonists, or enteric-coated aspirin formulations is associated with a higher risk for NSAID-induced enteropathy [130, 131]. Indeed, a prospective SBCE study found that PPI use (OR 2.04, 95%CI 1.05–3.97) and use of enteric-coated aspirin (OR 4.05, 95%CI 1.49–11.0) were the two most important risk factors for the presence of mucosal breaks [132]. Chronic acid suppression could lead to SB bacterial overgrowth, namely of enterobacteria which contribute to the development of NSAID-induced enteropathy, while enteric-coated aspirin formulations dissolve in the small bowel rather than the stomach or duodenum, resulting in localized direct toxicity.

No data are available regarding the interval required for spontaneous healing of NSAID/low dose aspirin and/or enteric-coated aspirin-induced SB mucosal lesions. However, in the setting of suspected CD, the current recommendation to suspend



NSAIDs for 4 weeks before SBCE to allow for complete mucosal healing remains generally recommended if the patient's clinical condition allows. If discontinuation is clinically contraindicated, interpretation of SBCE findings should consider that any lesion identified may have been caused by the ongoing use of these medications.

RECOMMENDATION

ESGE recommends device-assisted enteroscopy with small-bowel biopsies in patients with noncontributory ileocolonoscopy and suspected Crohn's disease on small-bowel cross-sectional imaging modalities or small-bowel capsule endoscopy. Strong recommendation, high quality evidence.

As stated in the previous guideline [1], despite all the recent advances in endoscopic and dedicated SB cross-sectional imaging, CD may still pose a diagnostic challenge, mainly if it is confined to the small bowel [90, 133]. Furthermore, it may be challenging to differentiate inflammatory SB lesions with other etiologies, such as infection (e.g., mycobacterial disease), drugs (e.g., NSAIDs and olmesartan), and malignancy (e.g., lymphoma), from similar lesions caused by CD. In such circumstances, direct endoscopic evaluation and biopsy of lesions at DAE is helpful in ruling out other causes and/or providing corroborative evidence of a diagnosis of SB CD [1, 47]. Since 2015 [1], there has been further support for the usefulness of DAE in this context [134, 135]. A retrospective series by Tun et al. (n = 100) [134], evaluated the role of DBE in the setting of suspected CD, where a definitive diagnosis through other modalities remained elusive. In this cohort, histopathology of biopsies taken at DBE was helpful to support a diagnosis of CD in 23%. In another similar retrospective series by Holleran et al., which included 13 adult patients, single-balloon enteroscopy (SBE) contributed to the diagnosis of CD in 39% [135].

Established Crohn's disease

RECOMMENDATION

ESGE recommends, in patients with established Crohn's disease based on ileocolonoscopy findings, dedicated cross-sectional imaging for small-bowel evaluation since this has the potential to assess the extent and location of any Crohn's disease lesions, to identify strictures, and to assess for extraluminal disease.
Strong recommendation, high quality evidence.

RECOMMENDATION

ESGE recommends, in patients with unremarkable or nondiagnostic findings from dedicated small-bowel cross-sectional imaging, small-bowel capsule endoscopy as a subsequent investigation if deemed likely to influence patient management.
Strong recommendation, low quality evidence.

RECOMMENDATION

ESGE suggests that small-bowel capsule endoscopy may be useful for assessment of Crohn's disease extent and for monitoring and guiding the "treat-to-target" strategy.
Weak recommendation, low quality evidence.

The present ESGE guideline confirms that, in the setting of established CD, when SB evaluation is indicated, SB cross-sectional imaging with CTE or MRE generally takes precedence over SBCE since these modalities can assess the transmural

and extraluminal nature of the disease and its anatomical distribution [1, 136]. However, as discussed previously, there is growing evidence from published meta-analyses and observational studies to show that SBCE is more sensitive than cross-sectional imaging for mucosal disease throughout the small bowel in patients with established as well as suspected CD [93–96]. SBCE has been shown to be a complementary test, increasing the identification of more diffuse SB disease even in patients with a positive ileocolonoscopy.

Recent studies have evaluated the potential benefit of a panenteric capsule endoscopy for further evaluation of patients with CD. A study by Bruining et al. [137] compared panenteric capsule endoscopy with MRE and ileocolonoscopy. The overall sensitivities for active enteric inflammation (panenteric capsule endoscopy vs. MRE and/or ileocolonoscopy) were 94% vs. 100% ($P=0.125$) and the specificities were 74% vs. 22%, respectively ($P=0.001$). The sensitivity of panenteric capsule endoscopy was superior to that of MRE within the proximal small bowel (97% vs. 71%, $P=0.021$), and similar to that of MRE and/or ileocolonoscopy within the terminal ileum and colon ($P=0.500$ – 0.625). The study by Tai et al. [102] showed that the use of panenteric capsule endoscopy resulted in management change in 46.5% of cases. Overall, the presence of active inflammatory findings resulted in a change in medical management in 64.6% of patients with established CD. Proximal SB findings led to an upstaging of disease in 19.7% and predicted escalation of therapy (OR 40.3). Similarly, in a prospective comparative study of panenteric capsule endoscopy and ileocolonoscopy by Leighton et al. [138] in patients with active CD, panenteric capsule endoscopy was shown to have a higher lesion detection rate in all SB segments including the terminal ileum.

Despite recommendation by new guidelines that all patients newly diagnosed with CD undergo SB assessment by ultrasound, MRE, and/or SBCE [90], it is still not clear whether these techniques are alternative or complementary. Evidence is scarce, but Greener et al. [139] compared the changes in disease extent and localization after performing MRE, SBCE, and both modalities. The investigators demonstrated that previously unrecognized disease locations were detected with SBCE and MRE in 51% and 25%, respectively ($P<0.01$) and by both modalities combined in 44 patients (55%). Using both modalities together may alter the original Montreal classification in 64% of patients [139].

For patients with established CD, the use of SBCE and panenteric capsule endoscopy may lead to changes in management in 50%–60% of patients [102, 140], as they allow assessment of mucosal healing [141]. Indeed, in a meta-analysis by Niv [142], mucosal healing detection by capsule was shown to be a good predictor of long-term clinical remission.

Although the Lewis score and the Capsule Endoscopy Crohn's Disease Activity Index (CECDAI) have shown good correlation with each other [142, 143], there seems to be poor correlation between capsule activity index scores and clinical and laboratory parameters. The study by Kopylov et al. [144] emphasizes that SBCE may detect mucosal inflammation even in patients in clinical and biomarker remission. Furthermore, a Lewis score of ≥ 270 has been identified as a predictor of

disease-related hospitalization [145], and a baseline Lewis score of ≥ 350 predicts long-term disease flare-ups [146].

The 2015 ESGE guideline recommended using SBCE to assess postoperative recurrence if colonoscopy is contraindicated or unsuccessful [1]. Since then, however, new evidence and a meta-analysis have emerged. Recent studies are consistently showing that in this setting, SBCE has a higher sensitivity for lesion detection, when compared with MRE and ultrasound [147, 148], even before symptoms appear [149], and may effectively drive further patient management [147, 149].

Conversely, since the 2015 guideline [1], only scant data regarding the role of SBCE in IBD-U have been published. Monteiro et al. [116] published a multicenter retrospective study of 36 patients with IBD-U, and analyzed inflammatory activity with SBCE using the Lewis score. In this study, 25% of patients were then diagnosed with CD (Lewis score ≥ 135), 44% of patients with ulcerative colitis (UC), and 27% continued to have a diagnosis of IBD-U, supporting the potential role of SBCE in reclassifying some cases of IBD-U.

RECOMMENDATION

ESGE recommends the use of activity scores (such as the Lewis score and the Capsule Endoscopy Crohn's Disease Activity Index (CECDAI)) to facilitate prospective small-bowel capsule endoscopy follow-up of patients for longitudinal assessment of small-bowel Crohn's disease and its response to medical therapy (using mucosal healing as an endpoint).

Strong recommendation, low quality evidence.

The invention of capsule endoscopy introduced the need for quantitative metrics to assess mucosal inflammation. Furthermore, as treatment targets focus on mucosal healing, this has become even more essential. Several quantitative inflammatory scores for capsule endoscopy have been developed over the years [1, 141–143]. Regarding SBCE reporting, along with the Lewis score and CECDAI, a new activity index, the Eliakim score combining evaluation of SB and colonic findings, has been proposed. When panenteric capsule endoscopy is used to allow for an integrated assessment of the small bowel and the colon, the Eliakim score has shown a good correlation with the Lewis score [150].

RECOMMENDATION

ESGE recommends, in patients with established Crohn's disease, the use of a patency capsule before small-bowel capsule endoscopy to decrease the capsule retention rate.

Strong recommendation, moderate quality evidence.

The patency capsule is a noninvasive and safe device developed to confirm functional patency of the intestinal lumen in

patients with suspected stenosis, to avoid SB capsule endoscopy retention. If the patency capsule is egested intact, retention of an actual capsule is unlikely. When the patency capsule is not egested within 30 hours, cross-sectional imaging is favored over abdominal radiography to confirm its exact location [151]. Silva et al. [152] observed that using the radiofrequency identification tag scanner, part of the patency capsule equipment, is also not helpful and may be avoided.

Given the higher risk of capsule retention in established CD, several strategies have been evaluated to identify patients with reduced functional patency. Nemeth et al. [153] evaluated capsule retention in two groups of patients who underwent a previous patency test: (i) a preselected group of patients with obstructive symptoms or previous abdominal surgery; and (ii) a group with nonselective patency capsule administration. No difference in capsule retention rates was observed (1.3% vs. 1.6%, $P=0.9$). However, capsule endoscopy after a positive patency test was associated with a high retention risk (11.1%).

A large ($n=3117$) multicenter, prospective, observational study by Rondonotti et al. [110] evaluated capsule retention rates in low risk and high risk patients. Patients were considered high risk ($n=175$) if they met one of the following criteria: recurrent abdominal pain, previous SB surgery, chronic NSAID use, SB stenosis detected in imaging techniques, prior abdominal radiation therapy, or refractory celiac disease. Of these 175 high risk patients, 24 underwent CTE or MRE before SBCE and the remaining 151 were given a patency capsule instead. In high risk patients, the subsequent capsule retention rate was 0.7% (1/151) for the patency capsule subgroup and 8.3% (2/24) for the cross-sectional imaging subgroup. The authors concluded that in high risk patients, a patency capsule is still required, regardless of radiological findings. Dedicated SB cross-sectional imaging, although helpful, can underestimate or overestimate the presence/degree of any stricturing.

RECOMMENDATION

ESGE recommends initial conservative treatment in the case of capsule retention.

Strong recommendation, high quality evidence.

RECOMMENDATION

ESGE recommends device-assisted enteroscopy if medical therapy has not achieved spontaneous capsule passage.

Strong recommendation, high quality evidence.

Capsule retention is the main adverse event of SBCE. As stated in the previous guideline [1], the recommendation is that asymptomatic patients should be managed conservatively/medically in the first instance, with DAE retrieval reserved for cases of persistent retention. Large series published since 2015 [1] have confirmed the validity of this recommended strategy. A multicenter retrospective study by Fernández-Urién

et al. (n=5428; different indications for SBCE) [154] showed an overall retention rate of 1.8%; >50% of retained capsules passed with conservative management (37% spontaneously; 20% with concomitant medical therapy). Nemeth et al., 2 years later also demonstrated a favorable outcome with this strategy: medical management resulted in the passage of 24% of retained capsules, while endoscopic retrieval was required in 44% [155]. This recommendation was also supported by the findings of another large retrospective series (n=5348; all indications) [156] and a retrospective study focused on patients with established CD, which also reported a high rate (70.5%) of passage of retained capsules with conservative measures [157].

The evidence to support specific medical management regimens remains scant, albeit most series reported on the use of glucocorticoids for capsule retention in the context of CD [154, 155, 157], with immunomodulators also used as an alternative [157]. Published egestion rates with medical management range from 10% to 70% [155–157], being higher in patients with established CD. In a multivariate analysis published by Lee et al. [158], the presence of abdominal symptoms after capsule retention was an independent predictive factor for a surgical outcome (OR 18.56, 95%CI 1.87–183.82; $P=0.013$).

Endoscopic retrieval has been a safe alternative in asymptomatic patients or in those with slight symptoms. Recently, a systematic review of 12 studies (n=150) regarding the use of DBE for retrieval of retained capsules [159], demonstrated a pooled retrieval success rate of 86.5% (95%CI 75.6%–95.1%). Factors associated with higher success were the antegrade approach (74.7% vs. 26.3%; $P<0.001$) and the presence of malignant strictures (100.0% vs. 78.3%; $P=0.043$) [159].

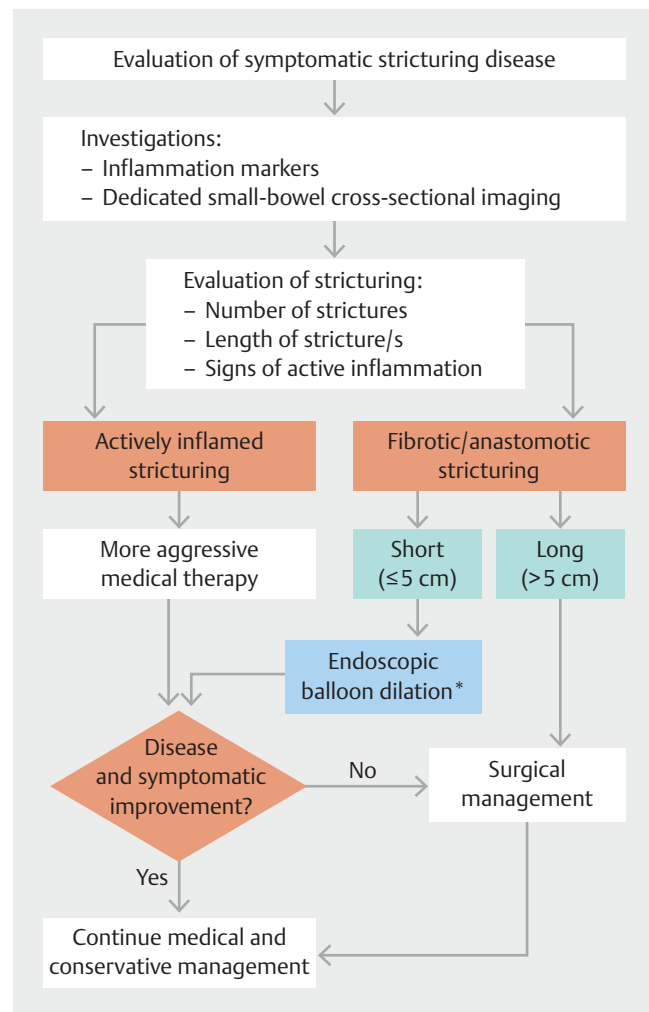
RECOMMENDATION

ESGE recommends device-assisted enteroscopy if small-bowel endotherapy is indicated (including dilation of Crohn's disease small-bowel strictures, retrieval of a retained capsule, and/or treatment of small-bowel bleeding).
Strong recommendation, high quality evidence.

Since the publication of the 2015 ESGE guideline [1] the evidence favoring the effectiveness and safety of DAE-facilitated endoscopic balloon dilation (EBD) of CD SB strictures has strengthened. This is best summarized in a recent meta-analysis by Bettenworth et al. [160], which evaluated 18 studies including a total of 463 patients and 1189 endoscopic balloon dilations. The pooled per-study analysis demonstrated that the technical success of endoscopic balloon dilation was 95% (95% CI 86.7%–98.1%; 13/18 studies), with clinical efficacy in 82.3% of patients (95%CI 68.1%–91%; 9/18 studies) in the short term. The major complication rate (including bleeding, perforation, and emergency surgery) was 5.3% (95%CI 3.5%–8.1%; 14/18 studies). Longer-term outcomes (as reflected by 20.5 months of follow-up) showed that symptomatic recurrence had occurred in 48.3% of patients (95%CI 33.2%–63.7%; 11/18 studies).

Nonetheless, this was managed by repeat endoscopic balloon dilation in 38.8% of patients (95%CI 27%–52%; 16/18 studies); recourse to surgery was required in 27.4% (95%CI 21.9%–33.8%; 15/18 studies). This meta-analysis [160] further interrogated detailed data from four of the included high volume centers (218 patients; 384 dilations) to identify potential risk factors associated with outcomes. On per-patient-based multivariable analysis, active SB disease was associated with reduced short-term clinical efficacy (OR 0.32, 95%CI 0.14–0.73; $P=0.007$). Furthermore, concomitant active disease of the small and/or large bowel increased the risk for surgery (hazard ratio [HR] 1.85, 95%CI 1.09–3.13; $P=0.02$; and HR 1.77, 95%CI 1.34–2.34; $P<0.001$). Conversely, ongoing anti-TNF-alpha treatment at the time of dilation correlated with reduced re-intervention (HR 0.78, 95%CI 0.63–0.96; $P=0.019$).

Based on the current evidence, an algorithm for the endoscopic management of SB strictures is suggested in ► Fig. 3 [161, 162].



► Fig. 3 Algorithm for the endoscopic management of benign small-bowel strictures (modified from [161, 162] with permission). * Consider surgery as a possible alternative to endoscopic balloon dilation, depending on location/presence of prestenotic dilatation/angulation and local set-up.

Inherited polyposis syndromes

Familial adenomatous polyposis

RECOMMENDATION

ESGE recommends surveillance of the proximal small bowel in familial adenomatous polyposis, using conventional forward-viewing and side-viewing endoscopes. Strong recommendation, moderate quality evidence.

RECOMMENDATION

ESGE does not recommend small-bowel capsule endoscopy for surveillance of the proximal small bowel in familial adenomatous polyposis. Strong recommendation, moderate quality evidence.

RECOMMENDATION

ESGE suggests that small-bowel capsule endoscopy and/or cross-sectional imaging techniques may be considered when investigation of the mid–distal small bowel is clinically indicated in familial adenomatous polyposis. Weak recommendation, moderate quality evidence.

The recent literature does not suggest an increased risk of distal (namely, beyond the proximal jejunum that is accessible at standard upper endoscopy) SB cancer in familial adenomatous polyposis [163–165]. This is concordant with the ESGE 2019 [166] and the ASGE 2020 [167] recommendations. Since SBCE may miss polyps in the proximal small bowel, it does not appear suitable for surveillance at this level [168]. If SBCE is justified in selected patients (anemia, major duodenojejunal burden of adenomas), prior patency examination or abdominal imaging is suggested in some studies [165, 167]. In a therapeutic context, the ASGE recommendations consider the use of DAE, bearing in mind that neither SBCE nor DAE studies report the presence of advanced adenomas deeper than the proximal jejunum [163, 165, 167].

In conclusion, endoscopy using a long axial endoscope and a lateral-viewing endoscope remains the gold standard of SB examination in familial adenomatous polyposis patients in 2022.

RECOMMENDATION

ESGE recommends, for small-bowel surveillance in patients with Peutz–Jeghers syndrome, small-bowel capsule endoscopy and/or magnetic resonance enterography, depending on local availability and expertise and/or patient preference. Strong recommendation, moderate quality evidence.

Peutz–Jeghers syndrome

Most polyps are localized within the small bowel in patients with Peutz–Jeghers syndrome (PJS). Patients have a significant risk of non-neoplastic complications (intussusception, bleeding, anemia) as well as an increased risk of malignancies (intestinal and extraintestinal) [169]. SB surveillance in PJS aims to prevent polyp-related complications (by reduction of the polyp burden) and to detect early premalignant or malignant changes with advancing patient age.

Guidelines from ESGE and the European Society for Paediatric Gastroenterology, Hepatology and Nutrition (ESPGHAN) recommend starting SB surveillance no later than 8 years of age (and earlier in patients with symptoms or complications) [166, 170]. Based on the number and size of SB polyps, a 1–3-yearly surveillance interval is recommended [166]. Cancer risk is significantly increased in PJS [171]. However, the potential for malignant transformation of the SB hamartomas remains unknown.

SB surveillance should be a part of the complex multiorgan screening program for patients with PJS [169]. SBCE is superior at detecting SB polyps in comparison with small-bowel follow-through and standard CT scans [168, 172]. The direct comparison of MRE and SBCE shows at least equivalent sensitivity of both methods in detection of SB hamartomas; there is some risk of missing clinically relevant polyps with both techniques [173, 174]. Some data suggest better localization of polyps and more accurate size estimation with MRE [173, 174], but SBCE superiority for detection of small polyps (< 15 mm) [174]. A meta-analysis of 15 comparative studies (821 patients) of DAE and SBCE confirmed high concordance (93%) in the identification of SB polyps and tumors [172]. In a retrospective multicenter study, 25 patients underwent SBCE followed by DBE when treatment was indicated. Authors found a strong agreement for polyp location and size but not for the number of polyps; DAE was more accurate for the latter [175]. Two small studies reported high concordance of MRE with DBE, laparoscopic enteroscopy, or surgery (93%). They also showed comparable diagnostic yields from MRE and DBE for SB polyps > 15 mm [176, 177].

In summary, MRE, SBCE, and DAE are complementary methods with similar diagnostic yields and a similar risk of missed lesions. The limited data do not allow preference for any one of the methods. Thus, both noninvasive techniques (SBCE or MRE) can be recommended for SB surveillance in patients with PJS, based on local availability and experience.

A patient history of SB resection (and therefore a risk of intra-abdominal adhesions) may mean a higher risk of SBCE retention, especially in patients with obstructive symptoms [178]. The routine use of the patency capsule [179] is not recommended in PJS and should be considered only on a case-by-case basis.

RECOMMENDATION

ESGE recommends device-assisted enteroscopy with polypectomy when large polyps (>15 mm) or symptomatic polyps are discovered by radiological examination or small-bowel capsule endoscopy in patients with Peutz–Jeghers syndrome.
Strong recommendation, moderate quality evidence.

An SB polyps size > 15 mm is the most important risk factor for SB intussusception, which can lead to intestinal obstruction and acute abdomen [180, 181]. On the other hand, in children (because of the smaller intestinal diameter), even polyps smaller than 15 mm may represent a risk, and polyps may result in other complications such as chronic bleeding with IDA [181]. Consequently, large (> 15 mm), symptomatic, or rapidly growing polyps should be promptly removed.

Both in adults and children, DAE is clinically useful for diagnosis and relatively safe for therapy of SB polyps [180, 182–184]. In a study of 50 enteroscopies using the antegrade (84%) and retrograde (16%) approach, the therapeutic interventions resulted in complete clearance of polyps >10 mm in 76% of patients [184]. However, considering the safety profile of DAE polypectomy (complication rate in PJS patients: 4%–6% [183–185]), enteroscopy should be used only as a targeted approach after previous noninvasive SB examination (using SBCE or MRE).

Motorized spiral enteroscopy has only recently been used in patients with PJS [186]. The published data on this technique are promising but insufficient for a final recommendation for patients with PJS.

Various technical improvements, including underwater resection [187] and ischemic polypectomy using polyp strangulation with endoclips and/or detachable snare (possibly also with an underwater approach), have been reported [188, 189]. They could represent a safer and faster alternative to conventional polypectomy; however, their benefits need future verification. In some clinical situations (high polyp burden and incomplete polyp clearance during previous DAE), the direct indication for the next DAE (without repeated SBCE or MRE) can be considered in an individualized time frame. A gradual decline in polyp size, numbers, and complication rate can be expected in the course of surveillance and repeated DAE polypectomies [182, 185, 190, 191].

When a polyp is too large for safe removal with DAE or cannot be reached using this modality (because of adhesions), intraoperative enteroscopy as a complementary technique could be considered for SB evaluation and polypectomy [183, 184]. Combined treatment of SB hamartomas with device-assisted and intraoperative enteroscopy significantly increases clearance success by 16% [184]. This approach may reduce the need for future surgery and SB resection in PJS patients.

Juvenile polyposis**RECOMMENDATION**

ESGE recommends that routine evaluation of the small bowel in juvenile polyposis patients should be limited to the duodenum and based on flexible forward-viewing endoscopy.
Strong recommendation, low quality evidence.

Involvement of the small bowel in juvenile polyposis seems infrequent and mainly limited to the duodenum in patients harboring a SMAD4 mutation [192, 193]. No case of SB cancer has been reported at this time in the well-characterized juvenile polyposis family. The ESGE 2019 consensus and the recent pediatric consensus on genetic syndromes do not recommend using SBCE or DAE in juvenile polyposis syndrome [166, 194].

In conclusion, there is no evidence of the usefulness of capsule endoscopy and no published case of histologically proven juvenile polyposis in the distal small bowel in these patients. According to ESGE and ESPGHAN recommendations, duodenoscopy appears sufficient, specifically in SMAD4 mutation carriers, because of the frequency of duodenal polyps.

Small-bowel tumors**RECOMMENDATION**

ESGE recommends the use of small-bowel capsule endoscopy in patients where there is an increased risk of a small-bowel tumor.
Strong recommendation, moderate quality evidence.

Most SBTs are detected during work-up for SSBB or unexplained IDA but are the cause in only about 3.5%–5% of these patients, making these symptoms weak predictors. Some subsets of patients have an increased risk of SBT, such as those with liver metastases of previously undiagnosed primary neuroendocrine tumor, stage IV malignant melanoma, or stage III malignant melanoma with positive FOBT, or with nonresponsive/complicated celiac disease (see **Celiac disease** section) [19]. In contrast, recent data do not suggest a significant yield for SBT or polyps in patients with sporadic duodenal adenomas [195], long-standing SB CD [196], or asymptomatic Lynch syndrome [197, 198]. The risk for underlying SBT does not seem to be higher in patients with recurring or ongoing bleeding than in patients with the first bleeding episode [199].

Because of the rarity of SBTs, prospective studies are lacking, and data are primarily retrospective from SSBB and IDA studies. In this setting, SBCE has exhibited good diagnostic performance for identifying SBTs [74, 200]. Although Johnston et al. have reported more frequent detection of SB malignancy at SBCE in younger patients (<55 years) [201], most studies did

not reveal any significant differences in the incidence of SBTs depending on the age of the patients, albeit there were variations in the definition of the younger versus older age groups [202–204]. The diagnostic yields of double-balloon enteroscopy for SBTs in the SSBB setting were also similar between patients <65 years old and elderly patients (>65 years), except for cases of incomplete SB obstruction where a higher rate of adenocarcinoma was identified in the elderly group (19.4% vs. 7.1%, $P=0.038$) [205].

In an RCT in the setting of SSBB, SBCE had a higher diagnostic yield for SBTs and polyps than push enteroscopy [206]. Compared to DAE in SSBB, SBCE had detection rates similar to single-balloon enteroscopy for SBTs [207,208]. Also double-balloon enteroscopy and SBCE had comparable diagnostic yields for SBTs [209,210], even in a context of SB re-examination, where double-balloon enteroscopy was compared to repeat SBCE for SSBB [56]. Nevertheless, the concordance between SBCE and single-balloon enteroscopy was not significant regarding SB masses [211], and the agreement between SBCE and double-balloon enteroscopy was lower for SBTs than for other SB pathology in the setting of SSBB [212,213]. Suspected SB neoplasia was related to increased diagnostic and therapeutic yield for both single- and double-balloon enteroscopy. Although previous SB investigations, including SBCE and/or imaging studies, improved the diagnostic yield of enteroscopy, this was not statistically significant [214].

On the other hand, the risk of false-negative SBCE results has been documented for SBTs, especially for lesions located in the proximal SB [168] or subepithelial tumors with minimal endoluminal components, such as GI stromal tumors (GISTs) [215] and neuroendocrine neoplasms (NENs) [216]. Therefore, in the case of a negative SBCE, albeit with a strong suspicion of an SBT, further dedicated SB cross-sectional imaging should be performed for confirmation.

Regarding imaging studies, CTE was accurate in raising the suspicion of SBTs [18], primarily when performed for SSBB [217]. CT angiography had a higher diagnostic yield for bleeding SBTs than for SB bleeding of nontumoral origin [218]. In a retrospective comparison of CTE and MRE, all cases of SBTs were accurately diagnosed by both modalities [219]. Conversely, in a prospective study comparing SBCE and CTE in the context of SSBB, the sensitivity of SBCE for SBTs was 66.67% compared to 100% for CTE [87]. In a retrospective study comparing double-balloon enteroscopy with SBCE and imaging modalities (CTE and MRE) for detecting SBTs, double-balloon enteroscopy was superior to all methods in terms of sensitivity, specificity, accuracy, and negative predictive value (NPV). Only CTE exhibited slightly higher PPV than double-balloon enteroscopy (93.5% vs. 90.0%) with comparable specificity, whereas MRE was outperformed in every aspect [220]. In another retrospective study comparing SBCE, double-balloon enteroscopy, and CTE for SSBB, all three approaches were comparable, complementing each other in detecting SBTs [221]. Thus, a combination of SBCE, dedicated cross-sectional SB imaging (e.g., CTE) and DAE may be required in the setting of suspected SBT since all three modalities are complementary to each other and

provide supplementary information to establish the diagnosis of an SBT.

RECOMMENDATION

ESGE does not recommend, in the setting of suspected small-bowel tumor, specific investigations before small-bowel capsule endoscopy unless patients are considered to be at risk of capsule retention.
Strong recommendation, low quality evidence.

RECOMMENDATION

ESGE recommends consideration of device-assisted enteroscopy in preference to small-bowel capsule endoscopy if imaging tests have already demonstrated suspected small-bowel tumor.
Strong recommendation, low quality evidence.

The ESGE Technical Review on SBCE and DAE recommends that no specific investigations be routinely performed on every patient referred for SBCE unless they are considered at risk for capsule retention. Careful assessment of symptoms such as abdominal pain/distension, nausea/vomiting, a history of previous SB resection, abdominal/pelvic radiation, or chronic use of NSAIDs may be used to distinguish patients at a higher risk of capsule retention [47]. Ultrasound could be a noninvasive initial diagnostic option in these patients, as a sensitivity of >90% for SBTs >2 cm has been reported [222].

The capsule retention rate in the case of SBTs varies among studies [201,203]; nevertheless, in a meta-analysis, the capsule retention rate was 2.1% for patients with SSBB, representing the most common indication for SB investigations in patients with SBTs [16]. In the setting of suspected SBT in imaging studies, DAE should be preferred over SBCE to avoid capsule retention and acquire biopsies for histological diagnosis [1]. Furthermore, in the case of capsule retention, surgery remains the mainstay of treatment when neoplastic disease is unequivocally suggested, allowing both capsule retrieval and tumor resection [47]. If the nature of the SB lesion cannot be determined with certainty, then DAE can be an alternative for capsule retrieval and tissue sampling and/or endoscopic resection if deemed feasible in the case of benign tumors [159,223].

RECOMMENDATION

ESGE recommends cross-sectional imaging for staging and ascertaining operability when there is a small-bowel capsule endoscopy finding of a small-bowel tumor with high diagnostic certainty.
Strong recommendation, low quality evidence.

RECOMMENDATION

ESGE recommends, when there is an uncertain diagnosis of small-bowel tumor at capsule endoscopy, biopsy sampling and tattooing of its location by device-assisted enteroscopy.
Strong recommendation, low quality evidence.

RECOMMENDATION

ESGE recommends, when a subepithelial mass is detected by small-bowel capsule endoscopy, confirmation of the diagnosis by device-assisted enteroscopy and/or cross-sectional imaging, depending on local availability and expertise.
Strong recommendation, low quality evidence.

When SBCE findings strongly suggest an SBT (stenotic or protruding, ulcerated, bleeding mass lesion), direct surgical referral without preoperative histological diagnosis would be justifiable. In these cases, preoperative cross-sectional imaging is mandatory to provide further information on disease extent and resectability. If the underlying etiology of the tumor is uncertain (e. g., adenocarcinoma vs. lymphoma), tissue sampling through DAE is indicated to establish a histopathological diagnosis that may guide the course of subsequent management. When subepithelial protrusions or bulges of uncertain nature are identified on SBCE, further investigations (DAE or/and dedicated SB cross-sectional imaging) are warranted to avoid a false-positive diagnosis of subepithelial lesions such as GISTs or NENs. It should be noted that the prominent extraluminal component of GISTs may challenge endoscopic diagnosis, not only with SBCE but with DAE too. The effectiveness of histological confirmation by DAE in this setting has a wide range (46%–88%) [223–225]. Placement of a tattoo during DAE is mandatory to facilitate recognition of an SB mass lesion at subsequent (laparoscopic) surgery [1].

Regarding SB subepithelial lesions, CTE was shown to be superior to abdominopelvic CT for identifying SB GISTs [215] and SB NENs [226]. MRE has exhibited high degrees of sensitivity for the diagnosis of NENs >10 mm (94%), but for lesions <10 mm, sensitivity was only 45% [227]. In a retrospective study assessing imaging techniques and double-balloon enteroscopy for the management of SB NENs, double-balloon enteroscopy was significantly better at identifying the primary tumor than CT, MRI, or somatostatin receptor imaging, as well as for detection of multifocal lesions when compared to CT and somatostatin receptor imaging but not compared to MRI [228]. Double-balloon endoscopy also detected additional lesions in 62.2% of patients who underwent an evaluation to exclude multifocal disease in the setting of SB NENs [216].

RECOMMENDATION

ESGE does not recommend small-bowel capsule endoscopy in the follow-up of treated small-bowel tumors, because of lack of data.
Strong recommendation, low quality evidence.

In patients with treated follicular lymphoma, Nakamura et al. found that SBCE detected lesions at a similar rate to double-balloon endoscopy; however, identifying residual lymphoma required biopsy, and the authors recommend DBE for follow-up [229]. Only 1 of 11 patients with an SBCE diagnosis of malignant SBT who underwent surgery had recurrent bleeding; in this patient, it was caused by metastasis of gastric and papillary cancer in familial adenomatous polyposis [230]. After complete resection of SB GIST in 32 patients, no intraluminal recurrence was seen during a median follow-up of 30 months (range 3–54 months) [225].

There are no studies that support regular follow-up of asymptomatic patients after resection of SBT in the absence of inherited polyposis syndromes.

Similarly, SBCE seems to have a very limited role in staging SBTs diagnosed with other techniques. SBCE and enteroscopy can help define the extent of GI non-Hodgkin's lymphoma, although they do not change the stage of follicular lymphoma [231]. Similarly, the number of detected NENs in the small bowel could be increased without demonstrating an impact of multifocality on outcomes [216].

RECOMMENDATION

ESGE suggests considering enteroscopic placement of self-expanding metal stents in the palliation of malignant small-bowel strictures as an alternative option to surgery.
Weak recommendation, low quality evidence.

A summary of published reports on self-expanding metal stents (SEMSs) placement by endoscopy (n=69) in malignant SB strictures found the method to be safe and effective [232]. Recent small series confirmed this result. Clinical improvement was observed following SEMS placement but not with medical treatment [233]. DAE can also be applied for ink marking of malignant SB strictures for palliative surgery [234].

Celiac disease

RECOMMENDATION

ESGE does not recommend small-bowel capsule endoscopy to diagnose celiac disease.
Strong recommendation, low quality evidence.

In studies assessing the utility/efficacy of SBCE in diagnosing celiac disease (i. e., ability to detect histologically proven villous atrophy), the sensitivity, specificity, PPV, and NPV of SBCE were 70%–100%, 64%–100%, 96%–100% and 71%–93%, respectively [235–239]. All these studies consistently show that, in the presence of antiendomysial antibody (EmA) or significantly elevated antitransglutaminase antibody (tTG), the PPV and specificity for recognizing endoscopic markers of celiac disease are 100%. However, the high pre-test probability of celiac disease in all of these studies may be a potential limitation leading to an overestimation of SBCE performance. A later meta-analysis confirms the previous findings [240], and an RCT has demonstrated that frontal and lateral view capsules are equivalent in detecting villous atrophy [241]. From a clinical point of view, new data suggest that when upper endoscopy is impossible, a diagnostic pathway similar to the pediatric sequence, based upon serology, could also be applied in adults [242], further limiting the potential use of SBCE in this setting.

Consequently, the actual scenario does not support the use of SBCE in this setting (basically, patients with positive serology necessitating a histological confirmation of the diagnosis) and probably, when necessary, the adoption of serological criteria could avoid any endoscopic procedure to diagnose celiac disease. Although currently unproven, the use of computerized image enhancement could modify this situation in future [243].

As with the previous ESGE guideline [1], there is no new evidence supporting the use of SBCE to routinely map the extent of disease. However, two recent studies from Chetcuti Zammit et al. [244,245] reported that the extent of villous atrophy could be efficiently verified by SBCE and atrophy extent could correlate with clinical parameters in some specific subgroups of patients (e. g., those with nonresponsive celiac disease, or severe bone involvement). The first study analyzed SBCE in 300 celiac patients and demonstrated an acceptable agreement among readers to define the severity of celiac disease [244]; the second analyzed a cohort of 80 celiac patients and showed that, in individuals with a relevant percentage of small bowel involved by villous atrophy, bone mineral density decreased significantly [245]; furthermore, bone mineral density did not correlate with histological severity of atrophy, underlining the potential relevance of atrophy extent. In conclusion, more recent studies suggest that atrophy extent could be efficiently quantified using SBCE and that this finding could correlate with some clinical parameters. However, because of the absence of other than gluten-free diet therapies for celiac disease, this factor is merely descriptive, and SBCE cannot be routinely recommended for this purpose. Nevertheless, this scenario could rapidly change in the near future once pharmacological therapies for celiac disease become available.

RECOMMENDATION

ESGE recommends using small-bowel capsule endoscopy in cases of equivocal diagnosis of celiac disease since it is essential for final diagnosis and therapy.
Strong recommendation, low quality evidence.

Equivocal cases of celiac disease represent a clinical challenge and a clear indication for SBCE. Two subgroups of patients can fit within the “equivocal cases” definition: patients with positive celiac serology (i. e., positive IgA tTG and/or EmA) but normal duodenal histology, and patients with histologically detected villous atrophy but negative celiac serology [246]. In the first scenario, previous studies indicated that SBCE usually does not detect relevant findings that change the clinical management of the patients [238, 247, 248].

In the case of seronegative villous atrophy, the diagnostic yield of capsule endoscopy is higher with relevant findings at SBCE. In the study by Kurien et al. [248], based on SBCE appearances and other ancillary tests, several patients were diagnosed with celiac disease and further patients were diagnosed with SB Crohn’s disease as a cause of villous atrophy.

Two recent studies, single-center by Chetcuti-Zammit et al. [249] and multicenter by Luján-Sanchis et al. [250], demonstrated the central role of capsule endoscopy in equivocal cases. In the first study, 177 patients were enrolled; the overall diagnostic yield was 31.6%. Furthermore, a positive correlation between mortality and atrophy extent was found in the 11 patients who died during the study follow-up. This finding underlines the prognostic role of SBCE in these cases and its relevance as a monitoring tool to assess therapeutic response. The multicenter second study evaluated 163 patients who underwent SBCE, with an overall diagnostic yield of 54%; again, the diagnostic yield was higher in the case of seronegative villous atrophy (74%) with relevant SBCE findings and diagnoses such as Crohn’s disease and lymphoproliferative disorders. Notably, in this previous study, SBCE revealed a significant management impact, with 71% of patients changing therapy after undergoing SBCE.

RECOMMENDATION

ESGE recommends in nonresponsive or refractory celiac disease, small-bowel capsule endoscopy followed by device-assisted enteroscopy for diagnosis and disease monitoring.
Strong recommendation, high quality evidence.

Celiac disease frequently presents a benign course with an optimal prognosis; however, up to 20% of patients show persistent or recurrent symptoms despite 6–12 months of following a strict gluten-free diet [246,251]. This “nonresponsive” form of celiac disease requires a careful diagnostic work-up to detect the presence of preneoplastic and neoplastic complications, such as refractory celiac disease (RCD), ulcerative jejunoileitis, enteropathy-associated T-cell lymphoma (EATL), and SB adenocarcinoma. RCD is defined by malabsorption and villous atrophy despite a correct gluten-free diet; RCD can be further subtyped into RCD type 1 (RCD-1) and type 2 (RCD-2) depending on the presence of an aberrant T-cell type in the duodenal mucosa, detected using cytofluorimetry. RCD-2 is less frequent but characterized by a severe prognosis with mortality of up to 50% in 5 years and a higher risk of neoplastic evolution [252].

For these reasons, nonresponsive celiac disease and RCD-1 and RCD-2 warrant surveillance of the small bowel and early detection of neoplastic complications.

Previously, two studies evaluating patients with nonresponsive disease identified a few severe complications with SBCE [248, 253]. Focusing on RCD, Barret et al. [254] used SBCE to investigate disease severity in 29 RCD patients; notably, after tissue sampling with DAE, they diagnosed 3 cases of EATL and 5 cases of ulcerative jejunoileitis requiring specific treatment in the RCD cohort. The sequential approach, SBCE followed by DAE in the case of suspect findings, appears justified by the potentially relevant diagnosis (EATL and ulcerative jejunoileitis) and the importance of the consequent therapies [255, 256].

More recently, different studies have investigated the clinical use of SBCE and DAE in this setting, including a large number of patients in single-center and multicenter patient cohorts [256–261]. Notably, all these studies confirmed a diagnostic yield of SBCE close to 50%, with the detection of SBTs in 3%–10% of cases. SBCE represents the first-line investigation, while DAE is performed to obtain tissue samples that usually reveal an EATL or that can be used in cytofluorimetry to diagnose or monitor RCD.

Furthermore, two studies [257, 259] demonstrated that atrophy extent correlates with mortality more than histology does. In 40% of cases, SBCE findings were beyond the Treitz ligament and thus not accessible at upper endoscopy, underlining the pivotal role of SBCE/DAE in RCD. These findings have been strengthened by a recently published meta-analysis [262] demonstrating a diagnostic yield for malignancies and ulcerative jejunoileitis of 13% in the case of SBCE and 30% for DAE. Given the scenario described above, in the case of nonresponsive celiac disease or RCD, upper endoscopy and SBCE are mandatory; the first to take biopsies to perform routine histology, the second to detect other lesions to be targeted by DAE [263].

Other indications

Chronic abdominal pain

RECOMMENDATION

ESGE does not recommend small-bowel capsule endoscopy as the first-line investigation for patients with isolated chronic abdominal pain.
Strong recommendation, low quality evidence.

Chronic abdominal pain is usually defined as a constant or recurrent pain that lasts 3 months or more. Chronic abdominal pain without pathological findings in upper endoscopy, colonoscopy and/or imaging techniques is a prevalent condition [264].

Interestingly, many case reports and case series have described diagnosis by SBCE of significant pathologies in patients with chronic abdominal pain (e.g., Meckel's diverticulum [265], eosinophilic enteritis [266], and SBTs [220]). However, the

available evidence highlights that the probability of detecting significant findings at SBCE is very low (below 20%) when isolated chronic abdominal pain is the indication for SBCE. At the same time, this rises significantly when associated with signs/symptoms or altered laboratory findings.

Shim et al. [267] retrospectively analyzed 110 patients with unexplained chronic abdominal pain: diagnostic yield was 17.3%, and in multivariate analysis weight loss was a significant risk factor for positive findings at SBCE (OR 18.6, 95%CI 1.6–222.4; $P=0.02$). Katsinelos et al. [268] conducted an open-label prospective nonrandomized multicenter clinical trial. In this study, diagnostic yield was 44.4%, and in multivariate regression analysis positive findings from SBCE were associated with elevated erythrocyte sedimentation rate (ESR) (OR 67.9, 95%CI 9.3–310.6, $P<0.001$) and C-reactive protein (CRP) (OR 41.5, 95%CI 6.2–213.4, $P<0.001$). Huang et al. [269] conducted a retrospective study which included 341 patients with chronic abdominal pain. In this study, the diagnostic yield was 28.15%, and these features were positively associated with SBCE diagnosis: weight loss (OR 2.827, 95%CI 1.938–4.926; $P=0.038$), hypoalbuminemia (OR 6.142, 95%CI 4.129–8.274; $P=0.008$), elevated ESR (OR 4.025, 95%CI 3.178–6.892; $P=0.016$), and increased CRP (OR 7.539, 95%CI 5.365–11.723; $P=0.002$). More recently, Kim et al. [270] performed a meta-analysis showing that the presence of elevated CRP (OR 14.09, 95%CI 2.81–70.60; $P=0.001$) and ESR (OR 14.45, 95%CI 0.92–227.33; $P=0.06$) significantly increased the diagnostic yield of SBCE in patients with unexplained abdominal pain.

These data underscore how, on the one hand, the SB endoscopic evaluation plays a very limited role in cases of isolated abdominal pain and, on the other, how relevant it is in this subset of patients to plan a comprehensive diagnostic workup (including laboratory tests, imaging tests, and accurate collection of clinical history), since when abdominal pain is associated with other clinical features, SBCE may lead to establishing a definite diagnosis.

Foreign body retrieval

RECOMMENDATION

ESGE recommends device-assisted enteroscopy as an alternative to surgery for foreign bodies retained in the small bowel requiring retrieval in patients without acute intestinal obstruction.
Strong recommendation, moderate quality evidence.

SB foreign-body retention that needs intervention is a rare event. Most frequently the foreign bodies involved are endoscopy capsules or other medical devices (e.g., migrated plastic or metallic stents). Capsule retention is defined as a capsule remaining in the digestive tract for at least 2 weeks, and retention rates vary between 2.1% and 8.2% [16]. Previous abdominal surgery or SB disease (e.g., stricturing CD or SBT) may contribute to retention. A systematic review has shown that DAE is a

reliable alternative to surgery, with a retrieval rate of 74.7% when the capsule is retained in the jejunum and can be reached via the antegrade approach [158]. However, when the capsule is retained in the ileum, the retrograde approach often necessitates endoscopic balloon dilation of the stricture before the capsule can be reached and is, therefore, less effective, as illustrated by a retrieval rate of only 26.3%. The serious adverse event rate is low (1.3% SB perforation risk) and associated with balloon dilation or neoplasia. One multicenter study reported that symptoms were the only independent predictor of successful retrieval using DAE (OR 13.40, 95%CI 1.10–162.56; $P=0.042$) [271]. In addition to retrieving the retained capsule, DAE can also facilitate the diagnosis and treatment of the underlying intestinal disease, by endoscopic biopsy, endoscopic balloon dilation, and preoperative tattooing. However, the indication for endoscopic or surgical intervention should be evaluated on a case-by-case basis and depends on local availability and expertise.

DAE-assisted percutaneous endoscopic jejunostomy (PEJ) for enteral feeding

RECOMMENDATION

ESGE suggests that in patients requiring jejunostomy for enteral feeding, DAE-assisted percutaneous endoscopic jejunostomy (PEJ) is a possible alternative to surgical jejunostomy.

Weak recommendation, moderate quality evidence.

Direct percutaneous endoscopic jejunostomy (DPEJ) is an accepted alternative to nasojejunal or surgical jejunal feeding in patients who require long-term post-pyloric feeding [272].

DPEJ using an enteroscope has a technical success rate of up to 90%. Technical failures are reported mostly because of limited enteroscope advancement in patients with a history of abdominal surgery and adhesions. DPEJ by DAE has a significant adverse event rate of 3.5% [273–276]; these include bleeding and SB perforation. DAE-assisted PEJ can represent an alternative to surgical jejunostomy according to local availability and expertise.

DAE-ERCP in patients with altered anatomy

RECOMMENDATION

ESGE recommends DAE-ERCP as a first-line endoscopic approach to treat pancreaticobiliary diseases in patients with surgically altered anatomy (except for Billroth II patients).

Strong recommendation, moderate quality evidence.

Since the advent of DAE, multiple retrospective studies have been published on DAE-endoscopic retrograde cholangiopancreatography (ERCP) in patients with surgically altered

anatomy. Biliary indications are more frequent than pancreatic indications. The most frequently met surgical reconstructions are Billroth II partial gastrectomy, Roux-en-Y total gastrectomy, Roux-en-Y gastric bypass (RYGB), Whipple's pancreaticoduodenectomy (also with Roux-en-Y), and Roux-en-Y hepaticojejunostomy [277]. According to ESGE guidelines [278], use of a side-viewing duodenoscope is the first option for performing ERCP in Billroth II patients. However, DAE-ERCP is equally effective [279].

Several recent meta-analyses on using long and short DBE, SBE, and manual spiral enteroscopy for performing ERCP in patients with altered anatomy, are based on multiple retrospective case series [280–284] (see **Table 3s**). They show that procedural success has seemed to increase over time, reaching >75% in the most recent meta-analysis, and even much higher success rates in individual retrospective series. DBE and SBE are equally effective. Short versions of both DBE and SBE have been developed, allowing the use of conventional ERCP accessories. Studies have shown equal procedural success when using short-type DAE, except in the cases of Roux-en-Y surgery without gastrectomy and long limb Roux-en-Y surgery such as RYGB, where the short-type DAE device may be too short to reach the biliopancreatic system [283, 285, 286]. Except for a single preliminary case report, there are currently no data available on the use of motorized spiral enteroscopy to perform ERCP in patients with surgically altered anatomy [287]. Overall, adverse events show low rates (up to 8% in meta-analysis reviews) and are mild with little indication for surgical intervention (mainly due to intestinal perforation), and mortality related to DAE-ERCP is close to 0%.

DAE-ERCP in patients with surgically altered anatomy can be considered a first-line technique to treat biliopancreatic pathology thanks to the good overall procedural success rate and the low adverse event rate. However, since the overall procedural success rate is good but not excellent, alternative, more invasive techniques have emerged, showing both higher technical success and adverse event rates. Thanks to the excluded stomach in RYGB, multiple alternative approaches currently exist, including laparoscopy-assisted ERCP, endoscopic ultrasound (EUS)-directed transgastric ERCP, EUS-guided intrahepatic puncture with antegrade clearance, and percutaneous transhepatic biliary drainage [288, 289]. Both laparoscopy-assisted ERCP and EUS-directed transgastric ERCP have high (>90%) procedural success rates but also higher adverse event rates (12%–24%) [290]. Also, in patients with Whipple's pancreaticoduodenectomy, transgastric EUS-guided drainage of the pancreatic duct is feasible with a good technical success rate of more than 70%, but with an adverse event rate of 20%–35% [291, 292]. ERCP in patients with surgically altered anatomy is challenging and should be referred to expert centers. The technique of choice depends on local availability and expertise, as previously suggested by ESGE [293].

Innovations

SBCE

Since their inception at the dawn of this millennium, SBCE and DAE have continually evolved. For the former, two main paths lead to further development. First, technological advances are expected to lead to paradigm shifts. Second, patient- and society-related outcomes may drastically change SBCE practice in the coming years.

The latest generation of commercially available SBCE devices and software currently provides high resolution images captured by powerful central processing units, an adaptive frame rate, post-processing chromoendoscopy options, long-life batteries (enabling gastroenteric or enterocolonic examinations) and expert systems (allowing faster reading) [294]. Implementation of AI in software is a significant step [295]. These solutions allow a drastic reduction (of around 90%) in image selection and reading time, while maintaining very high sensitivity (above 98%) for lesion detection [296, 297]. Further high level clinical assessment and discussions with scientific societies and regulatory authorities are required before AI can routinely be used in clinical practice. This allows the triage of normal videos and/or images within videos. Additionally, some AI software also enables characterization of abnormalities [297]. Researchers in AI are working to address the challenges of automated evaluation of anatomical landmarks, of completion, and of cleanliness [295]. In addition, progress in miniaturization and energy-saving may provide more room for batteries within the capsule and thereby longer battery life.

Consequently, it is expected that a genuinely “panenteric” (mouth-to-anus) capsule endoscope will be available in the near future [298]. In addition, magnetically guided capsule endoscopy has been developed and clinically assessed for examination of the stomach or combined stomach and small bowel [299, 300]. However, active capsules with embedded AI, microbiota or tissue sampling, or therapeutic options, are still in the early stages of development [300].

Furthermore, emerging healthcare and societal trends may profoundly modify how we practice SBCE. For example, some capsule endoscopy manufacturers have recently obtained approval from the US Food and Drug Administration for capsule home delivery, provided that a healthcare provider accompanies patients for the procedure [300]. As a result, patients' comfort and reporting times would be significantly improved. In addition, there is growing concern regarding the ecological impact of endoscopy. Capsule endoscopy is expected not to escape the debate around avoiding the yearly release of tens of thousands of batteries and electronic material into the environment [300]. Overall, such developments may widen the indications for capsule endoscopy and how we practice SBCE in the future.

DAE

Motorized spiral enteroscopy

A novel motorized spiral enteroscopy device (Olympus, Tokyo, Japan) has recently been introduced. The activation of an integrated electric motor permits the rotational movement of a spiral overtube, achieving advancement by pleating the SB. Since its introduction, several case reports have been published, showing the potential abilities of this new endoscopy device. The first prospective trial was conducted in 132 patients from two European tertiary referral centers. It showed diagnostic and therapeutic yields for antegrade explorations similar to those from previous studies with balloon enteroscopy. However, longer insertion length (mean 450 cm, range 0–600 cm) in a shorter procedural time (mean 25 min, range 3–122 min) was achieved [301]. Two other clinical studies from Europe and Asia reported similar results; moreover, total enteroscopy rates were 61% and 70% [302, 303]. Nonetheless, some issues regarding this technique are still unclear, such as the need for general anesthesia for antegrade procedures, the learning curve, and the target population. Furthermore, only minimal information exists on the impact of prior major abdominal surgery on the feasibility and the safety of motorized spiral enteroscopy [304, 305].

Water-aided enteroscopy

The water-exchange intubation technique has been proposed to achieve higher total enteroscopy rates. The method is the same as when applied for the exploration of the colon, with warm saline (37 °C) infused into the intestinal lumen to maintain the endoscopic view and mostly suctioned during the insertion phase. During the antegrade procedure, saline is infused once the ligament of Treitz is reached, while during the retrograde procedure, water exchange begins from insertion at the anus [306]. Of note, an adaptor connecting the water pump tube to the accessory channel of the enteroscope is needed.

The two studies available so far have produced conflicting results. One randomized, nonblinded, single-center study compared the total enteroscopy rates between patients undergoing water-exchange-assisted (n=55) and CO₂-insufflated (n=55) SBE [306]. The total enteroscopy rate was significantly higher in the water-exchange group (58.2% vs. 36.4%), as well as the overall and antegrade approach insertion depths, the overall insertion time, and the insertion time for the oral route. Diagnostic yields and adverse event rates were similar between groups. In a prospective, comparative and observational study, 46 patients were randomly allocated to water exchange-assisted (n=23 patients) and CO₂-insufflated (n=23 patients) DBE. The median insertion depth was greater in the CO₂ group, at 260 cm vs. 160 cm ($P=0.048$). Multiple logistic regression showed a statistically significant difference in the insertion depth using CO₂ insufflation (OR 1.009, 95%CI 1.001–1.017; $P=0.034$). Adverse event rates were similar between groups [307]. Other larger RCTs comparing the water-exchange technique with CO₂ are awaited.

Interventional enteroscopy

Snare and ischemic polypectomy, and conventional and underwater mucosectomy by DAE, have become the first-line treatments for SB polyps, especially in the setting of PJS. These techniques are efficient, safe and cost-effective. Complete resection rates are over 60%, with infrequent adverse events (mostly in the form of immediate or delayed bleeding and pancreatitis) [183,184]. The outcomes of DAE dilation of benign SB strictures are mentioned in a previous section.

Disclaimer

The legal disclaimer for ESGE Guidelines [3] applies to this Guideline.

Acknowledgments

ESGE wishes to thank external reviewers Prof. Ian M Gralnek of the Rappaport Faculty of Medicine Technion Israel Institute of Technology, Haifa, Israel, and Prof. Owen Epstein of the Royal Free Hospital, London, UK, for their critical review and appraisal of this Guideline. We would like also to thank the following ESGE members who reviewed the Guideline and made interesting suggestions for improvement: Abdulbaqi Al Toma, Rafael Barreto Zuñiga, Gerardo Blanco Velasco, Rosamaria Bozzi, Alessandro Rimondi, Stylianos Stylianidis, Tony Tham, Olga Bednarska on behalf of the Swedish Society of Gastroenterology (SGF), and Rodica Gincul on behalf of the French Society of Digestive Endoscopy (SFED).

Competing interests

C. Carretero provides consultancy and receives speakers fees from Medtronic (ongoing). X. Dray is a founder of and shareholder in Augmented Endoscopy (May 2019 to present); he is a member of the International Capsule Endoscopy REsearch (iCARE) group (December 2021 to present); he holds four patents (shared with his institutions) related to artificial intelligence in endoscopy. E. J. Despott has received educational grants in support of conference organization, and honoraria, from Fujifilm, Pentax, and Olympus (2017–2021), and honoraria from Ambu (2021). L. Elli has held a lecture/consultancy role for Medtronic (2018–2020) and Capsocam (2016). L. Fuccio is a Co-Editor of *Endoscopy* journal. M. Keuchel has received speaker's fees and travel support from and provided consultancy to Medtronic, and received speaker's fees from Olympus (both from 2021 to present); his department has received study support from AnX Robotics (from 2021 to present). A. Koulaouzidis is a co-founder and shareholder of AJM MED-i-Caps (from 2017, ongoing) and iCERV (from 2022, ongoing), and has received consultancy fees from CHI and Jinshan Science & Technology and lecture honoraria from Medtronic (all from 2020, ongoing), travel assistance fees from Aquilant (2019), material support for clinical research from SynMed and Intramedic (2016–2020), and lecture honoraria and AB meeting fees from Dr Falk Pharma UK (2016–2020), and has participated in an advisory board for Ankon (2019); his department has received a grant from Medtronic (2016–2020); he is a founding and board member of iCARE; he or his department holds a patent related to this Guideline. D. McNamara received an iCloud Capsule Platform introductory fee waiver from Medtronic (2021–2022). T. Moreels received speaker's fees from Olympus (2019–2022). H. Neumann is a consultant to Fujifilm, Medtronic, and Jinsha (from 2020, ongoing); his department re-

ceives study support from Fujifilm (from 2020, ongoing). M. Pennazio received speaker's fees from Medtronic, Olympus, and Alfasigma (2015–2019). E. Perez-Cuadrado-Robles provided consultancy to Boston Scientific (2020–2021). E. Rondonotti has been an expert group member and speaker for Fujifilm (January 2021 to December 2021) and provided consultancy to Medtronic (2021); his department received a research grant from Fujifilm (January 2021 to December 2021). B. Rosa provided consultancy to Medtronic (2020–2021). C. Spada provided consultancy to Medtronic (2017–2022) and AnX Robotics (2020–2022). J. C. Saurin provided consultancy to Intramedic, Capsovision, Medtronic, and Povepharm (2021–2024), and teaching for Medtronic (2021–2024). I. Tachei is Scientific Secretary to the Czech Society of Gastroenterology and responsible for dissemination of guidelines (2022). P. Cortegoso Valdivia, B. Gonzalez Suarez, L. Kuvnovsky, E. Perez-Cuadrado-Martinez, S. Piccirelli, D.S. Sanders, R. Sidhu, K. Triantafyllou, and E. Vlachou have no competing interests.

References

- [1] Pennazio M, Spada C, Eliakim R et al. Small-bowel capsule endoscopy and device-assisted enteroscopy for diagnosis and treatment of small-bowel disorders: European Society of Gastrointestinal Endoscopy (ESGE) Clinical Guideline. *Endoscopy* 2015; 47: 352–386 doi:10.1055/s-0034-1391855
- [2] Guyatt GH, Oxman AD, Vist GE et al. GRADE: an emerging consensus on rating quality of evidence and strength of recommendations. *BMJ* 2008; 336: 924–926 doi:10.1136/bmj.39489.470347.AD
- [3] Hassan C, Ponchon T, Bisschops R et al. European Society of Gastrointestinal Endoscopy (ESGE) Publications Policy – Update 2020. *Endoscopy* 2020; 52: 123–126 doi:10.1055/a-1067-4657
- [4] Gerson LB, Fidler JL, Cave DR et al. ACG Clinical Guideline: Diagnosis and management of small bowel bleeding. *Am J Gastroenterol* 2015; 110: 1265–1287 doi:10.1038/ajg.2015.246
- [5] Liao Z, Gao R, Xu C et al. Indications and detection, completion, and retention rates of small-bowel capsule endoscopy: a systematic review. *Gastrointest Endosc* 2010; 71: 280–286 doi:10.1016/j.gie.2009.09.031
- [6] Teshima CW, Kuipers EJ, van Zanten SV et al. Double balloon enteroscopy and capsule endoscopy for obscure gastrointestinal bleeding: an updated meta-analysis. *J Gastroenterol Hepatol* 2011; 26: 796–801 doi:10.1111/j.1440-1746.2010.06530.x
- [7] Cortegoso Valdivia P, Skonieczna-Żydecka K, Elosua A et al. Indications, detection, completion and retention rates of capsule endoscopy in two decades of use: a systematic review and meta-analysis. *Diagnostics* 2022; 12: 1105 doi:10.3390/diagnostics12051105
- [8] Leusse A, Vahedi K, Edery J et al. Capsule endoscopy or push enteroscopy for first-line exploration of obscure gastrointestinal bleeding? *Gastroenterology* 2007; 132: 855–862 doi:10.1053/j.gastro.2006.12.002
- [9] Wang Z, Chen J, Liu J et al. CT enterography in obscure gastrointestinal bleeding: A systematic review and meta-analysis: CT enterography for OGIB. *J Med Imaging Radiat Oncol* 2013; 57: 263–273 doi:10.1111/1754-9485.12035
- [10] Saperas E, Dot J, Videla S et al. Capsule endoscopy versus computed tomographic or standard angiography for the diagnosis of obscure gastrointestinal bleeding. *Am J Gastroenterol* 2007; 102: 731–737 doi:10.1111/j.1572-0241.2007.01058.x
- [11] Hartmann D, Schmidt H, Bolz G et al. A prospective two-center study comparing wireless capsule endoscopy with intraoperative enteroscopy in patients with obscure GI bleeding. *Gastrointest Endosc* 2005; 61: 826–832 doi:10.1016/S0016-5107(05)00372-X
- [12] Pennazio M, Santucci R, Rondonotti E et al. Outcome of patients with obscure gastrointestinal bleeding after capsule endoscopy: re-

- port of 100 consecutive cases. *Gastroenterology* 2004; 126: 643–653
- [13] Kuo JR, Pasha SF, Leighton JA. The clinician's guide to suspected small bowel bleeding. *Am J Gastroenterol* 2019; 114: 591–598 doi:10.1038/s41395-018-0424-x
- [14] Tziatzios G, Gkolfakis P, Papanikolaou IS et al. Antithrombotic treatment is associated with small-bowel video capsule endoscopy positive findings in obscure gastrointestinal bleeding: a systematic review and meta-analysis. *Dig Dis Sci* 2019; 64: 15–24 doi:10.1007/s10620-018-5292-0
- [15] Toskas A, Laskaratos F-M, Coda S. Virtual chromoendoscopy in capsule endoscopy: a narrative review. *Diagnostics* 2022; 12: 1818 doi:10.3390/diagnostics12081818
- [16] Rezapour M, Amadi C, Gerson LB. Retention associated with video capsule endoscopy: systematic review and meta-analysis. *Gastrointest Endosc* 2017; 85: 1157–1168.e2 doi:10.1016/j.gie.2016.12.024
- [17] He B, Yang J, Xiao J et al. Accuracy of computed tomographic enterography for obscure gastrointestinal bleeding: a diagnostic meta-analysis. *Acad Radiol* 2018; 25: 196–201 doi:10.1016/j.acra.2017.09.001
- [18] Unno M, Hashimoto S, Shimizu K et al. Combined use of computed tomography enterography/enteroclysis and capsule endoscopy improves the accuracy of diagnosis of small bowel bleeding. *Intern Med* 2021; 60: 2545–2555 doi:10.2169/internalmedicine.6785-20
- [19] Rondonotti E, Koulaouzidis A, Georgiou J et al. Small bowel tumours: update in diagnosis and management. *Curr Opin Gastroenterol* 2018; 34: 159–164 doi:10.1097/MOG.0000000000000428
- [20] Cortegoso Valdivia P, Skonieczna-Żydecka K, Pennazio M et al. Capsule endoscopy transit-related indicators in choosing the insertion route for double-balloon enteroscopy: a systematic review. *Endosc Int Open* 2021; 09: E163–E170 doi:10.1055/a-1319-1452
- [21] Gurudu SR, Bruining DH, Acosta RD et al. The role of endoscopy in the management of suspected small-bowel bleeding. *Gastrointest Endosc* 2017; 85: 22–31 doi:10.1016/j.gie.2016.06.013
- [22] Enns RA, Hookey L, Armstrong D et al. Clinical practice guidelines for the use of video capsule endoscopy. *Gastroenterology* 2017; 152: 497–514 doi:10.1053/j.gastro.2016.12.032
- [23] Zhao R, Nakamura M, Wu S et al. The role of early video capsule endoscopy in the diagnosis and prognosis of obscure gastrointestinal bleeding: A multi-center propensity score matching study. *J Gastroenterol Hepatol* 2021; 36: 2540–2548 doi:10.1111/jgh.15491
- [24] Chao C-C, Mo L-R, Hu SC. The optimal timing for using capsule endoscopy for patients with gastrointestinal bleeding. *BioMed Res Int* 2021; 2021: 1–5 doi:10.1155/2021/7605324
- [25] Kim SH, Keum B, Chun HJ et al. Efficacy and implications of a 48-h cutoff for video capsule endoscopy application in overt obscure gastrointestinal bleeding. *Endosc Int Open* 2015; 3: E334–338 doi:10.1055/s-0034-1391852
- [26] Wood AR, Ham SA, Sengupta N et al. Impact of early video capsule endoscopy on hospitalization and post-hospitalization outcomes: a propensity score-matching analysis. *Dig Dis Sci* 2021; doi:10.1007/s10620-021-07239-0
- [27] Iio S, Oka S, Tanaka S et al. Clinical utility of emergency capsule endoscopy for diagnosing the source and nature of ongoing overt obscure gastrointestinal bleeding. *Gastroenterol Res Pract* 2019; 2019: 5496242 doi:10.1155/2019/5496242
- [28] Song JH, Kim JE, Chung HH et al. Video capsule endoscopy optimal timing in overt obscure gastrointestinal bleeding. *Diagnostics* 2022; 12: 154 doi:10.3390/diagnostics12010154
- [29] Gomes C, Pinho R, Rodrigues A et al. Impact of the timing of capsule endoscopy in overt obscure gastrointestinal bleeding on yield and rebleeding rate – is sooner than 14 d advisable? *World J Gastrointest Endosc* 2018; 10: 74–82 doi:10.4253/wjge.v10.i4.74
- [30] Uchida G, Nakamura M, Yamamura T et al. Systematic review and meta-analysis of the diagnostic and therapeutic yield of small bowel endoscopy in patients with overt small bowel bleeding. *Dig Endosc* 2021; 33: 66–82 doi:10.1111/den.13669
- [31] Estevinho MM, Pinho R, Fernandes C et al. Diagnostic and therapeutic yields of early capsule endoscopy and device-assisted enteroscopy in the setting of overt GI bleeding: a systematic review with meta-analysis. *Gastrointest Endosc* 2022; 95: 610–625.e9 doi:10.1016/j.gie.2021.12.009
- [32] Elli L, Scaramella L, Tontini GE et al. Clinical impact of videocapsule and double balloon enteroscopy on small bowel bleeding: Results from a large monocentric cohort in the last 19 years. *Dig Liver Dis* 2022; 54: 251–257 doi:10.1016/j.dld.2021.07.014
- [33] Riccioni ME, Tortora A, Costamagna G. Editorial – Video-capsule endoscopy: a test with no contraindications? *Eur Rev Med Pharmacol Sci* 2020; 24: 13105–13106 doi:10.26355/eur-rev_202012_24220
- [34] Lange J, Shah A, Meltzer AC. Video capsule endoscopy beyond the gastrointestinal suite. *Gastrointest Endosc Clin N Am* 2021; 31: 377–385 doi:10.1016/j.giec.2020.12.005
- [35] Bisschops R, Areia M, Coron E et al. Performance measures for upper gastrointestinal endoscopy: a European Society of Gastrointestinal Endoscopy (ESGE) Quality Improvement Initiative. *Endoscopy* 2016; 48: 843–864 doi:10.1055/s-0042-113128
- [36] Kaminski M, Thomas-Gibson S, Bugajski M et al. Performance measures for lower gastrointestinal endoscopy: a European Society of Gastrointestinal Endoscopy (ESGE) Quality Improvement Initiative. *Endoscopy* 2017; 49: 378–397 doi:10.1055/s-0043-103411
- [37] Innocenti T, Dragoni G, Roselli J et al. Non-small-bowel lesions identification by capsule endoscopy: A single centre retrospective study. *Clin Res Hepatol Gastroenterol* 2021; 45: 101409 doi:10.1016/j.clinre.2020.03.011
- [38] Clere-Jehl R, Sauleau E, Ciuca S et al. Outcome of endoscopy-negative iron deficiency anemia in patients above 65: A longitudinal multicenter cohort. *Medicine (Baltimore)* 2016; 95: e5339 doi:10.1097/MD.00000000000005339
- [39] Riccioni ME, Urgesi R, Cianci R et al. Obscure recurrent gastrointestinal bleeding: a revealed mystery? *Scand J Gastroenterol* 2014; 49: 1020–1026 doi:10.3109/00365521.2014.898327
- [40] Akin FE, Yurekli OT, Demirezer Bolat A et al. Analysis of non-small bowel lesions detected by capsule endoscopy in patients with potential small bowel bleeding. *Diagn Ther Endosc* 2016; 2016: 1–5 doi:10.1155/2016/9063293
- [41] Hoedemaker RA, Westerhof J, Weersma RK et al. Non-small-bowel abnormalities identified during small bowel capsule endoscopy. *World J Gastroenterol* 2014; 20: 4025–4029 doi:10.3748/wjg.v20.i14.4025
- [42] Juanmartiñena Fernández JF, Fernández-Urién Sainz I, Saldaña Dueñas C et al. Esophageal lesions detected during small bowel capsule endoscopy: incidence, diagnostic and therapeutic impact. *Acta Gastro-Enterol Belg* 2017; 80: 499–504
- [43] Juanmartiñena Fernández JF, Fernández-Urién Sainz I, Zabalza Ollo B et al. Gastroduodenal lesions detected during small bowel capsule endoscopy: incidence, diagnostic and therapeutic impact. *Rev Esp Enferm Dig* 2018; 110: 102–108 doi:10.17235/reed.2017.5114/2017
- [44] Juanmartiñena Fernández JF, Fernández-Urién Sainz I, Zabalza Ollo B et al. Colonic lesions in patients undergoing small bowel capsule endoscopy: incidence, diagnostic and therapeutic impact. *Rev Esp Enferm Dig* 2017; 109: 498–502 doi:10.17235/reed.2017.4604/2016
- [45] Spada C, McNamara D, Despott EJ et al. Performance measures for small-bowel endoscopy: a European Society of Gastrointestinal

- Endoscopy (ESGE) Quality Improvement Initiative. *Endoscopy* 2019; 51: 574–598 doi:10.1055/a-0889-9586
- [46] Sidhu R, Chetcuti Zammit S, Baltés P et al. Curriculum for small-bowel capsule endoscopy and device-assisted enteroscopy training in Europe: European Society of Gastrointestinal Endoscopy (ESGE) Position Statement. *Endoscopy* 2020; 52: 669–686 doi:10.1055/a-1185-1289
- [47] Rondonotti E, Spada C, Adler S et al. Small-bowel capsule endoscopy and device-assisted enteroscopy for diagnosis and treatment of small-bowel disorders: European Society of Gastrointestinal Endoscopy (ESGE) Technical Review. *Endoscopy* 2018; 50: 423–446 doi:10.1055/a-0576-0566
- [48] Marmo C, Riccioni ME, Pennazio M et al. Small bowel cleansing for capsule endoscopy, systematic review and meta-analysis: Timing is the real issue. *Dig Liver Dis* 2022; S1590865822005849: doi:10.1016/j.dld.2022.07.002
- [49] Lamba M, Ryan K, Hwang J et al. Clinical utility of purgative bowel preparation prior to capsule endoscopy: A multicenter, blinded, randomized controlled trial. *Gastrointest Endosc* 2022; S0016510722018272: doi:10.1016/j.gie.2022.07.010
- [50] Yung DE, Koulaouzidis A, Avni T et al. Clinical outcomes of negative small-bowel capsule endoscopy for small-bowel bleeding: a systematic review and meta-analysis. *Gastrointest Endosc* 2017; 85: 305–317.e2 doi:10.1016/j.gie.2016.08.027
- [51] Alsahafi M, Cramer P, Chatur N et al. The impact of inpatient capsule endoscopy on the need for therapeutic interventions in patients with obscure gastrointestinal bleeding. *Saudi J Gastroenterol* 2020; 26: 53–60 doi:10.4103/sjg.SJG_415_19
- [52] Ormeci A, Akyuz F, Baran B et al. What is the impact of capsule endoscopy in the long term period? *World J Gastrointest Endosc* 2016; 8: 344–348 doi:10.4253/wjge.v8.i7.344
- [53] Van de Bruaene C, Hindryckx P, Snauwaert C et al. The predictive value of negative capsule endoscopy for the indication of obscure gastrointestinal bleeding: no reassurance in the long term. *Acta Gastro-Enterol Belg* 2016; 79: 405–413
- [54] Cho YK, Park H, Moon JR et al. Clinical outcomes between P1 and P0 lesions for obscure gastrointestinal bleeding with negative computed tomography and capsule endoscopy. *Diagn Basel Switz* 2021; 11: 657 doi:10.3390/diagnostics11040657
- [55] Magalhães-Costa P, Bispo M, Santos S et al. Re-bleeding events in patients with obscure gastrointestinal bleeding after negative capsule endoscopy. *World J Gastrointest Endosc* 2015; 7: 403–410 doi:10.4253/wjge.v7.i4.403
- [56] Otani K, Watanabe T, Shimada S et al. Usefulness of small bowel re-examination in obscure gastrointestinal bleeding patients with negative capsule endoscopy findings: Comparison of repeat capsule endoscopy and double-balloon enteroscopy. *United Eur Gastroenterol J* 2018; 6: 879–887 doi:10.1177/2050640618767600
- [57] Ribeiro I, Pinho R, Rodrigues A et al. What is the long-term outcome of a negative capsule endoscopy in patients with obscure gastrointestinal bleeding? *Rev Espanola Enferm Dig* 2015; 107: 753–758
- [58] Khamplod S, Limsrivilai J, Kaosombattawattana U et al. Negative video capsule endoscopy had a high negative predictive value for small bowel lesions, but diagnostic capability may be lower in young patients with overt bleeding. *Can J Gastroenterol Hepatol* 2021; 2021: 8825123 doi:10.1155/2021/8825123
- [59] Harada A, Torisu T, Okamoto Y et al. Predictive factors for rebleeding after negative capsule endoscopy among patients with overt obscure gastrointestinal bleeding. *Digestion* 2020; 101: 129–136 doi:10.1159/000496826
- [60] de Sousa Magalhães R, Cúrdia Gonçalves T, Rosa B et al. RHEMITT score: predicting the risk of rebleeding for patients with mid-gastrointestinal bleeding submitted to small bowel capsule endoscopy. *Dig Dis Basel Switz* 2020; 38: 299–309 doi:10.1159/000504385
- [61] de Sousa Magalhães R, Sousa-Pinto B, Boal Carvalho P et al. RHEMITT score: Predicting the risk of mid gastrointestinal rebleeding after small bowel capsule endoscopy: A prospective validation. *J Gastroenterol Hepatol* 2022; 37: 310–318 doi:10.1111/jgh.15695
- [62] Brito HP, Ribeiro IB, de Moura DTH et al. Video capsule endoscopy vs double-balloon enteroscopy in the diagnosis of small bowel bleeding: A systematic review and meta-analysis. *World J Gastrointest Endosc* 2018; 10: 400–421 doi:10.4253/wjge.v10.i12.400
- [63] Marmo R, Rotondano G, Casetti T et al. Degree of concordance between double-balloon enteroscopy and capsule endoscopy in obscure gastrointestinal bleeding: a multicenter study. *Endoscopy* 2009; 41: 587–592 doi:10.1055/s-0029-1214896
- [64] Tziatzios G, Gkolfakis P, Dimitriadis GD et al. Long-term effects of video capsule endoscopy in the management of obscure gastrointestinal bleeding. *Ann Transl Med* 2017; 5: 196 doi:10.21037/atm.2017.03.80
- [65] Rahmi G, Samaha E, Vahedi K et al. Long-term follow-up of patients undergoing capsule and double-balloon enteroscopy for identification and treatment of small-bowel vascular lesions: a prospective, multicenter study. *Endoscopy* 2014; 46: 591–597 doi:10.1055/s-0034-1365514
- [66] Jeon SR, Byeon J-S, Jang HJ et al. Clinical outcome after enteroscopy for small bowel angioectasia bleeding: A Korean Association for the Study of Intestinal Disease (KASID) multicenter study. *J Gastroenterol Hepatol* 2017; 32: 388–394 doi:10.1111/jgh.13479
- [67] Aniwani S, Viriyautsahakul V, Luangsukrerk T et al. Low rate of recurrent bleeding after double-balloon endoscopy-guided therapy in patients with overt obscure gastrointestinal bleeding. *Surg Endosc* 2021; 35: 2119–2125 doi:10.1007/s00464-020-07615-3
- [68] Kim Y, Kim J-H, Kang E-A et al. Rebleeding rate and risk factors for rebleeding after device-assisted enteroscopy in patients with obscure gastrointestinal bleeding: A KASID multicenter study. *Diagn Basel Switz* 2022; 12: 954 doi:10.3390/diagnostics12040954
- [69] Snook J, Bhala N, Beales ILP et al. British Society of Gastroenterology guidelines for the management of iron deficiency anaemia in adults. *Gut* 2021; 70: 2030–2051 doi:10.1136/gutjnl-2021-325210
- [70] Stone J, Grover K, Bernstein CN. The use of capsule endoscopy for diagnosis of iron deficiency anemia: a retrospective analysis. *J Clin Gastroenterol* 2020; 54: 452–458 doi:10.1097/MCG.0000000000001255
- [71] Contaldo A, Losurdo G, Albano F et al. The spectrum of small intestinal lesions in patients with unexplained iron deficiency anemia detected by video capsule endoscopy. *Med Kaunas Lith* 2019; 55: E59 doi:10.3390/medicina55030059
- [72] Singeap A-M, Cojocariu C, Girleanu I et al. Clinical impact of small bowel capsule endoscopy in obscure gastrointestinal bleeding. *Med Kaunas Lith* 2020; 56: E548 doi:10.3390/medicina56100548
- [73] Olano C, Pazos X, Avendaño K et al. Diagnostic yield and predictive factors of findings in small-bowel capsule endoscopy in the setting of iron-deficiency anemia. *Endosc Int Open* 2018; 6: E688–E693 doi:10.1055/a-0593-5915
- [74] Yung DE, Rondonotti E, Giannakou A et al. Capsule endoscopy in young patients with iron deficiency anaemia and negative bidirectional gastrointestinal endoscopy. *United Eur Gastroenterol J* 2017; 5: 974–981 doi:10.1177/2050640617692501
- [75] Almlaji O, Smith C, Surgenor S et al. Refinement and validation of the IDIOM score for predicting the risk of gastrointestinal cancer in iron deficiency anaemia. *BMJ Open Gastroenterol* 2020; 7: e000403 doi:10.1136/bmjgast-2020-000403
- [76] Efthymakis K, Milano A, Laterza F et al. Iron deficiency anemia despite effective gluten-free diet in celiac disease: Diagnostic role of small bowel capsule endoscopy. *Dig Liver Dis* 2017; 49: 412–416 doi:10.1016/j.dld.2016.12.007

- [77] Chang JY, Moon CM, Shim K-N et al. Positive fecal occult blood test is a predictive factor for gastrointestinal bleeding after capsule endoscopy in patients with unexplained iron deficiency anemia: A Korean multicenter CAPENTRY study. *Clin Endosc* 2020; 53: 719–726 doi:10.5946/ce.2019.149
- [78] Judge C, Tighe D, Barry L et al. Predicting pathology on small bowel capsule endoscopy: a good FIT. *Endosc Int Open* 2019; 07: E1379–E1385 doi:10.1055/a-0990-9225
- [79] Endo H, Kato T, Sakai E et al. Is a fecal occult blood test a useful tool for judging whether to perform capsule endoscopy in low-dose aspirin users with negative colonoscopy and esophagogastroduodenoscopy? *J Gastroenterol* 2017; 52: 194–202 doi:10.1007/s00535-016-1212-2
- [80] Yung DE, Vijayan S, Avni T et al. Fecal occult blood testing for the prediction of small-bowel pathology detected by capsule endoscopy: a systematic review and meta-analysis. *Ann Gastroenterol* 2017; 30: 186–191 doi:10.20524/aog.2017.0122
- [81] Garrido Durán C, Iyo Miyashiro E, Páez Cumpa C et al. Diagnostic yield of video capsule endoscopy in premenopausal women with iron-deficiency anemia. Article in Spanish. *Gastroenterol Hepatol* 2015; 38: 373–378 doi:10.1016/j.gastrohep.2015.01.001
- [82] Silva JC, Pinho R, Rodrigues A et al. Yield of capsule endoscopy in obscure gastrointestinal bleeding: A comparative study between premenopausal and menopausal women. *World J Gastrointest Endosc* 2018; 10: 301–307 doi:10.4253/wjge.v10.i10.301
- [83] Romeo S, Neri B, Mossa M et al. Diagnostic yield of small bowel capsule endoscopy in obscure gastrointestinal bleeding: a real-world prospective study. *Intern Emerg Med* 2022; 17: 349–358 doi:10.1007/s11739-021-02791-z
- [84] Xavier S, Magalhães J, Rosa B et al. Impact of small bowel capsule endoscopy in iron deficiency anemia: influence of patients' age on diagnostic yield. *Arq Gastroenterol* 2018; 55: 242–246 doi:10.1590/S0004-2803.201800000-61
- [85] Sealock RJ, Thrift AP, El-Serag HB et al. Long-term follow up of patients with obscure gastrointestinal bleeding examined with video capsule endoscopy. *Medicine (Baltimore)* 2018; 97: e11429 doi:10.1097/MD.00000000000011429
- [86] Cúrdia Gonçalves T, Barbosa M, Rosa B et al. Uncovering the uncertainty: Risk factors and clinical relevance of P1 lesions on small bowel capsule endoscopy of anemic patients. *World J Gastroenterol* 2016; 22: 8568–8575 doi:10.3748/wjg.v22.i38.8568
- [87] Limsrivilai J, Srisajjakul S, Pongprasobchai S et al. A prospective blinded comparison of video capsule endoscopy versus computed tomography enterography in potential small bowel bleeding: Clinical utility of computed tomography enterography. *J Clin Gastroenterol* 2017; 51: 611–618 doi:10.1097/MCG.0000000000000639
- [88] Taylor SA, Mallett S, Bhatnagar G et al. Diagnostic accuracy of magnetic resonance enterography and small bowel ultrasound for the extent and activity of newly diagnosed and relapsed Crohn's disease (METRIC): a multicentre trial. *Lancet Gastroenterol Hepatol* 2018; 3: 548–558 doi:10.1016/S2468-1253(18)30161-4
- [89] Jensen MD, Nathan T, Rafaelsen SR et al. Ileoscopy reduces the need for small bowel imaging in suspected Crohn's disease. *Dan Med J* 2012; 59: A4491
- [90] Maaser C, Sturm A, Vavricka SR et al. ECCO-ESGAR Guideline for Diagnostic Assessment in IBD Part 1: Initial diagnosis, monitoring of known IBD, detection of complications. *J Crohns Colitis* 2019; 13: 144–164 doi:10.1093/ecco-jcc/jjy113
- [91] Mitselos IV, Christodoulou DK, Katsanos KH et al. The role of small bowel capsule endoscopy and ileocolonoscopy in patients with non-specific but suggestive symptoms of Crohn's disease. *Eur J Gastroenterol Hepatol* 2016; 28: 882–889 doi:10.1097/MEG.0000000000000644
- [92] Samuel S, Bruining DH, Loftus EV et al. Endoscopic skipping of the distal terminal ileum in Crohn's disease can lead to negative results from ileocolonoscopy. *Clin Gastroenterol Hepatol* 2012; 10: 1253–1259 doi:10.1016/j.cgh.2012.03.026
- [93] Kopylov U, Yung DE, Engel T et al. Diagnostic yield of capsule endoscopy versus magnetic resonance enterography and small bowel contrast ultrasound in the evaluation of small bowel Crohn's disease: Systematic review and meta-analysis. *Dig Liver Dis* 2017; 49: 854–863 doi:10.1016/j.dld.2017.04.013
- [94] Choi M, Lim S, Choi M-G et al. Effectiveness of capsule endoscopy compared with other diagnostic modalities in patients with small bowel Crohn's disease: a meta-analysis. *Gut Liver* 2017; 11: 62–72 doi:10.5009/gnl16015
- [95] González-Suárez B, Rodríguez S, Ricart E et al. Comparison of capsule endoscopy and magnetic resonance enterography for the assessment of small bowel lesions in Crohn's disease. *Inflamm Bowel Dis* 2018; 24: 775–780 doi:10.1093/ibd/izx107
- [96] Calabrese C, Diegoli M, Dussias N et al. Performance of capsule endoscopy and cross-sectional techniques in detecting small bowel lesions in patients with Crohn's disease. *Crohns Colitis* 2020; 2: otaa046 doi:10.1093/crocol/otaa046
- [97] Freitas M, Cúrdia Gonçalves T, Boal Carvalho P et al. From terminal ileitis to Crohn's disease: how capsule endoscopy is crucial to diagnosis. *Eur J Gastroenterol Hepatol* 2021; 33: 631–638 doi:10.1097/MEG.0000000000001937
- [98] Sihag S, Tan B, Semenov S et al. Development of significant disease in a cohort of patients with non-specific enteritis on capsule endoscopy: clinical suspicion and a high base line Lewis score are predictive of Crohn's disease. *BMC Gastroenterol* 2020; 20: 341 doi:10.1186/s12876-020-01486-7
- [99] Chateau T, Damico F, Zallot C et al. Crohn's disease only visible on small bowel capsule endoscopy: a new entity. *Dig Dis Sci* 2021; 66: 2712–2716 doi:10.1007/s10620-020-06553-3
- [100] Pasha SF, Pennazio M, Rondonotti E et al. Capsule retention in Crohn's disease: a meta-analysis. *Inflamm Bowel Dis* 2020; 26: 33–42 doi:10.1093/ibd/izz083
- [101] Tontini GE, Rizzello F, Cavallaro F et al. Usefulness of panoramic 344°-viewing in Crohn's disease capsule endoscopy: a proof of concept pilot study with the novel PillCamTM Crohn's system. *BMC Gastroenterol* 2020; 20: 97 doi:10.1186/s12876-020-01231-0
- [102] Tai FWD, Ellul P, Elosua A et al. Panenteric capsule endoscopy identifies proximal small bowel disease guiding upstaging and treatment intensification in Crohn's disease: A European multicentre observational cohort study. *United Eur Gastroenterol J* 2021; 9: 248–255 doi:10.1177/2050640620948664
- [103] Eliakim R, Spada C, Lapidus A et al. Evaluation of a new pan-enteric video capsule endoscopy system in patients with suspected or established inflammatory bowel disease - feasibility study. *Endosc Int Open* 2018; 6: E1235–E1246 doi:10.1055/a-0677-170
- [104] Du J, Du H, Chen H et al. Characteristics and prognosis of isolated small-bowel Crohn's disease. *Int J Colorectal Dis* 2020; 35: 69–75 doi:10.1007/s00384-019-03432-w
- [105] Wu S-Y, Yang C-H, Sun W-L et al. Use of advanced modalities does not guarantee early detection of small-bowel Crohn's disease in the absence of complications. *Med Sci Monit* 2019; 25: 8704–8711 doi:10.12659/MSM.918413
- [106] Ahmed O, Rodrigues DM, Nguyen GC. Magnetic resonance imaging of the small bowel in Crohn's disease: a systematic review and meta-analysis. *Can J Gastroenterol Hepatol* 2016; 2016: 7857352 doi:10.1155/2016/7857352
- [107] Takenaka K, Ohtsuka K, Kitazume Y et al. Magnetic resonance evaluation for small bowel strictures in Crohn's disease: comparison with balloon enteroscopy. *J Gastroenterol* 2017; 52: 879–888 doi:10.1007/s00535-016-1284-z

- [108] García-Bosch O, Ordás I, Aceituno M et al. Comparison of diagnostic accuracy and impact of magnetic resonance imaging and colonoscopy for the management of Crohn's disease. *J Crohns Colitis* 2016; 10: 663–669 doi:10.1093/ecco-jcc/jjw015
- [109] Al-Bawardy B, Locke G, Huprich JE et al. Retained capsule endoscopy in a large tertiary care academic practice and radiologic predictors of retention. *Inflamm Bowel Dis* 2015; 21: 2158–2164 doi:10.1097/MIB.0000000000000482
- [110] Rondonotti E, Soncini M, Girelli CM et al. Short article: Negative small-bowel cross-sectional imaging does not exclude capsule retention in high-risk patients. *Eur J Gastroenterol Hepatol* 2016; 28: 871–875 doi:10.1097/MEG.0000000000000628
- [111] Rozendorn N, Klang E, Lahat A et al. Prediction of patency capsule retention in known Crohn's disease patients by using magnetic resonance imaging. *Gastrointest Endosc* 2016; 83: 182–187 doi:10.1016/j.gie.2015.05.048
- [112] Herrerias JM, Leighton JA, Costamagna G et al. Agile patency system eliminates risk of capsule retention in patients with known intestinal strictures who undergo capsule endoscopy. *Gastrointest Endosc* 2008; 67: 902–909 doi:10.1016/j.gie.2007.10.063
- [113] Rasmussen B, Nathan T, Jensen MD. Symptomatic patency capsule retention in suspected Crohn's disease. *J Crohns Colitis* 2016; 10: 1445–1447 doi:10.1093/ecco-jcc/jjw105
- [114] Sawai K, Goi T, Takegawa Y et al. Acute small bowel perforation caused by obstruction of a novel tag-less Agile™ patency capsule. *Case Rep Gastroenterol* 2018; 12: 337–343 doi:10.1159/000490097
- [115] Tanabe H, Ando K, Ohdaira H et al. Successful medical treatment for a Crohn's disease patient with a perforation by a second-generation patency capsule. *Endosc Int Open* 2018; 6: E1436–E1438 doi:10.1055/a-0752-9903
- [116] Monteiro S, Dias de Castro F, Boal Carvalho P et al. Essential role of small bowel capsule endoscopy in reclassification of colonic inflammatory bowel disease type unclassified. *World J Gastrointest Endosc* 2017; 9: 34–40 doi:10.4253/wjge.v9.i1.34
- [117] Mergener K, Ponchon T, Gralnek I et al. Literature review and recommendations for clinical application of small-bowel capsule endoscopy, based on a panel discussion by international experts. Consensus statements for small-bowel capsule endoscopy, 2006/2007. *Endoscopy* 2007; 39: 895–909 doi:10.1055/s-2007-966930
- [118] Monteiro S, Barbosa M, Cúrdia Gonçalves T et al. Fecal calprotectin as a selection tool for small bowel capsule endoscopy in suspected Crohn's disease. *Inflamm Bowel Dis* 2018; 24: 2033–2038 doi:10.1093/ibd/izy098
- [119] Egea-Valenzuela J, González Suárez B, Sierra Bernal C et al. Development and validation of a scoring index to predict the presence of lesions in capsule endoscopy in patients with suspected Crohn's disease of the small bowel: a Spanish multicenter study. *Eur J Gastroenterol Hepatol* 2018; 30: 499–505 doi:10.1097/MEG.0000000000001083
- [120] Xiang B, Dong Z, Dai C. The diagnostic and predictive value of fecal calprotectin and capsule endoscopy for small-bowel Crohn's disease: a systematic review and meta-analysis. *Rev Esp Enferm Dig* 2021; 113: 193–201 doi:10.17235/reed.2020.6996/2020
- [121] Jung ES, Lee SP, Kae SH et al. Diagnostic accuracy of fecal calprotectin for the detection of small bowel Crohn's disease through capsule endoscopy: an updated meta-analysis and systematic review. *Gut Liver* 2021; 15: 732–741 doi:10.5009/gnl20249
- [122] Kopylov U, Yung DE, Engel T et al. Fecal calprotectin for the prediction of small-bowel Crohn's disease by capsule endoscopy: a systematic review and meta-analysis. *Eur J Gastroenterol Hepatol* 2016; 28: 1137–1144 doi:10.1097/MEG.0000000000000692
- [123] Fiorino G, Bonovas S, Gilardi D et al. Validation of the red flags index for early diagnosis of Crohn's disease: a prospective observational IG-IBD study among general practitioners. *J Crohns Colitis* 2020; 14: 1777–1779 doi:10.1093/ecco-jcc/jjaa111
- [124] Ishihara M, Ohmiya N, Nakamura M et al. Risk factors of symptomatic NSAID-induced small intestinal injury and diaphragm disease. *Aliment Pharmacol Ther* 2014; 40: 538–547 doi:10.1111/apt.12858
- [125] Endo H, Sakai E, Kato T et al. Small bowel injury in low-dose aspirin users. *J Gastroenterol* 2015; 50: 378–386 doi:10.1007/s00535-014-1028-x
- [126] Niikura R, Yamada A, Maki K et al. Associations between drugs and small-bowel mucosal bleeding: Multicenter capsule-endoscopy study. *Dig Endosc* 2018; 30: 79–89 doi:10.1111/den.12922
- [127] Teutsch B, Boros E, Vánca S et al. Mucoprotective drugs can prevent and treat nonsteroidal anti-inflammatory drug-induced small bowel enteropathy: a systematic review and meta-analysis of randomized controlled trials. *Ther Adv Gastroenterol* 2021; 14: 17562848211038772 doi:10.1177/17562848211038772
- [128] Gao F, Chen X, Zhang J. Prevalence of gastric and small-intestinal mucosal injury in elderly patients taking enteric-coated aspirin by magnetically controlled capsule endoscopy. *Gastroenterol Res Pract* 2019; 2019: 1582590 doi:10.1155/2019/1582590
- [129] Xu N, Yu Z, Cao X et al. Characteristics of nonsteroidal anti-inflammatory drugs (NSAIDs)-induced small bowel injury identified by single-balloon endoscopy or capsule endoscopy. *Med Sci Monit* 2017; 23: 5237–5245 doi:10.12659/msm.907326
- [130] Washio E, Esaki M, Maehata Y et al. Proton pump inhibitors increase incidence of nonsteroidal anti-inflammatory drug-induced small bowel injury: a randomized, placebo-controlled trial. *Clin Gastroenterol Hepatol* 2016; 14: 809–815.e1 doi:10.1016/j.cgh.2015.10.022
- [131] Kedir HM, Sisay EA, Abiye AA. Enteric-coated aspirin and the risk of gastrointestinal side effects: a systematic review. *Int J Gen Med* 2021; 14: 4757–4763 doi:10.2147/IJGM.S326929
- [132] Endo H, Sakai E, Taniguchi L et al. Risk factors for small-bowel mucosal breaks in chronic low-dose aspirin users: data from a prospective multicenter capsule endoscopy registry. *Gastrointest Endosc* 2014; 80: 826–834 doi:10.1016/j.gie.2014.03.024
- [133] Hall B, Holleran G, McNamara D. Small bowel Crohn's disease: an emerging disease phenotype? *Dig Dis Basel Switz* 2015; 33: 42–51 doi:10.1159/000366047
- [134] Tun GSZ, Rattehalli D, Sanders DS et al. Clinical utility of double-balloon enteroscopy in suspected Crohn's disease: a single-centre experience. *Eur J Gastroenterol Hepatol* 2016; 28: 820–825 doi:10.1097/MEG.0000000000000629
- [135] Holleran G, Valerii G, Tortora A et al. The use of single balloon enteroscopy in Crohn's disease and its impact on clinical outcome. *Scand J Gastroenterol* 2018; 53: 925–929 doi:10.1080/00365521.2018.1476914
- [136] Bourreille A, Ignjatovic A, Aabakken L et al. Role of small-bowel endoscopy in the management of patients with inflammatory bowel disease: an international OMED–ECCO consensus. *Endoscopy* 2009; 41: 618–637 doi:10.1055/s-0029-1214790
- [137] Bruining DH, Oliva S, Fleisher MR et al. Panenteric capsule endoscopy versus ileocolonoscopy plus magnetic resonance enterography in Crohn's disease: a multicentre, prospective study. *BMJ Open Gastroenterol* 2020; 7: e000365 doi:10.1136/bmjgast-2019-000365
- [138] Leighton JA, Helper DJ, Gralnek IM et al. Comparing diagnostic yield of a novel pan-enteric video capsule endoscope with ileocolonoscopy in patients with active Crohn's disease: a feasibility study. *Gastrointest Endosc* 2017; 85: 196–205.e1 doi:10.1016/j.gie.2016.09.009
- [139] Greener T, Klang E, Yablecovitch D et al. The impact of magnetic resonance enterography and capsule endoscopy on the re-classification of disease in patients with known Crohn's disease: a prospective Israeli IBD Research Nucleus (IIRN) study. *J Crohns Colitis* 2016; 10: 525–531 doi:10.1093/ecco-jcc/jjw006

- [140] Elosua A, Rullan M, Rubio S et al. Does capsule endoscopy impact clinical management in established Crohn's disease? *Dig Liver Dis* 2022; 54: 118–124 doi:10.1016/j.dld.2021.08.014
- [141] Le Berre C, Trang-Poisson C, Bourreille A. Small bowel capsule endoscopy and treat-to-target in Crohn's disease: A systematic review. *World J Gastroenterol* 2019; 25: 4534–4554 doi:10.3748/wjg.v25.i31.4534
- [142] Niv Y. Small-bowel mucosal healing assessment by capsule endoscopy as a predictor of long-term clinical remission in patients with Crohn's disease: a systematic review and meta-analysis. *Eur J Gastroenterol Hepatol* 2017; 29: 844–848 doi:10.1097/MEG.0000000000000881
- [143] Yablecovitch D, Lahat A, Neuman S et al. The Lewis score or the capsule endoscopy Crohn's disease activity index: which one is better for the assessment of small bowel inflammation in established Crohn's disease? *Ther Adv Gastroenterol* 2018; 11: 1756283X17747780 doi:10.1177/1756283X17747780
- [144] Kopylov U, Yablecovitch D, Lahat A et al. Detection of small bowel mucosal healing and deep remission in patients with known small bowel Crohn's disease using biomarkers, capsule endoscopy, and imaging. *Am J Gastroenterol* 2015; 110: 1316–1323 doi:10.1038/ajg.2015.221
- [145] Nishikawa T, Nakamura M, Yamamura T et al. Lewis score on capsule endoscopy can predict the prognosis in patients with small bowel lesions of Crohn's disease. *J Gastroenterol Hepatol* 2021; 36: 1851–1858 doi:10.1111/jgh.15366
- [146] Ben-Horin S, Lahat A, Amitai MM et al. Assessment of small bowel mucosal healing by video capsule endoscopy for the prediction of short-term and long-term risk of Crohn's disease flare: a prospective cohort study. *Lancet Gastroenterol Hepatol* 2019; 4: 519–528 doi:10.1016/S2468-1253(19)30088-3
- [147] Han Z-M, Qiao W-G, Ai X-Y et al. Impact of capsule endoscopy on prevention of postoperative recurrence of Crohn's disease. *Gastrointest Endosc* 2018; 87: 1489–1498 doi:10.1016/j.gie.2018.01.017
- [148] Yung DE, Har-Noy O, Tham YS et al. Capsule endoscopy, magnetic resonance enterography, and small bowel ultrasound for evaluation of postoperative recurrence in Crohn's disease: systematic review and meta-analysis. *Inflamm Bowel Dis* 2017; 24: 93–100 doi:10.1093/ibd/izx027
- [149] Shiga H, Abe I, Kusaka J et al. Capsule endoscopy is useful for postoperative tight control management in patients with Crohn's disease. *Dig Dis Sci* 2022; 67: 263–272 doi:10.1007/s10620-021-06841-6
- [150] Eliakim R, Yablecovitch D, Lahat A et al. A novel PillCam Crohn's capsule score (Eliakim score) for quantification of mucosal inflammation in Crohn's disease. *United Eur Gastroenterol J* 2020; 8: 544–551 doi:10.1177/2050640620913368
- [151] Kopylov U, Nemeth A, Cebrian A et al. Symptomatic retention of the patency capsule: a multicenter real life case series. *Endosc Int Open* 2016; 4: E964–969 doi:10.1055/s-0042-112588
- [152] Silva M, Cardoso H, Cunha R et al. Evaluation of small-bowel patency in Crohn's disease: prospective study with a patency capsule and computed tomography. *GE Port J Gastroenterol* 2019; 26: 396–403 doi:10.1159/000499722
- [153] Nemeth A, Kopylov U, Koulaouzidis A et al. Use of patency capsule in patients with established Crohn's disease. *Endoscopy* 2016; 48: 373–379 doi:10.1055/s-0034-1393560
- [154] Fernández-Urién I, Carretero C, González B et al. Incidence, clinical outcomes, and therapeutic approaches of capsule endoscopy-related adverse events in a large study population. *Rev Esp Enferm Dig* 2015; 107: 745–752 doi:10.17235/reed.2015.3820/2015
- [155] Nemeth A, Wurm Johansson G, Nielsen J et al. Capsule retention related to small bowel capsule endoscopy: a large European single-center 10-year clinical experience. *United Eur Gastroenterol J* 2017; 5: 677–686 doi:10.1177/2050640616675219
- [156] Han Z, Qiao W, Ai X et al. Risk factors for surgery in patients with retention of endoscopic capsule. *Scand J Gastroenterol* 2018; 53: 107–113 doi:10.1080/00365521.2017.1390603
- [157] Du J, Pan D, Ma P et al. The clinical characteristic and risk of capsule incomplete and retention in Crohn's disease. *Int J Clin Exp Med* 2015; 8: 13482–13490
- [158] Lee HS, Lim YJ, Kim KO et al. Outcomes and management strategies for capsule retention: A Korean capsule endoscopy nationwide database registry study. *Dig Dis Sci* 2019; 64: 3240–3246 doi:10.1007/s10620-019-05659-7
- [159] Gao Y, Xin L, Wang Y-X et al. Double-balloon enteroscopy for retrieving retained small-bowel video capsule endoscopes: a systematic review. *Scand J Gastroenterol* 2020; 55: 105–113 doi:10.1080/00365521.2019.1703036
- [160] Bettenworth D, Bokemeyer A, Kou L et al. Systematic review with meta-analysis: efficacy of balloon-assisted enteroscopy for dilation of small bowel Crohn's disease strictures. *Aliment Pharmacol Ther* 2020; 52: 1104–1116 doi:10.1111/apt.16049
- [161] Skamnelos A, Lazaridis N, Vlachou E et al. The role of small-bowel endoscopy in inflammatory bowel disease: an updated review on the state-of-the-art in 2021. *Ann Gastroenterol* 2021; 34: 599–611 doi:10.20524/aog.2021.0652
- [162] Despott EJ, Fraser C. Small bowel endoscopy in inflammatory bowel disease. *Best Pract Res Clin Gastroenterol* 2012; 26: 279–291 doi:10.1016/j.bpg.2012.01.019
- [163] Alderlieste YA, Rauws EA, Mathus-Vliegen EM et al. Prospective enteroscopic evaluation of jejunal polyposis in patients with familial adenomatous polyposis and advanced duodenal polyposis. *Fam Cancer* 2013; 12: 51–56 doi:10.1007/s10689-012-9571-1
- [164] Sekiya M, Sakamoto H, Yano T et al. Double-balloon endoscopy facilitates efficient endoscopic resection of duodenal and jejunal polyps in patients with familial adenomatous polyposis. *Endoscopy* 2021; 53: 517–521 doi:10.1055/a-1189-9550
- [165] Matsumoto M, Nakajima T, Kakugawa Y et al. Surveillance using capsule endoscopy is safe in post-colectomy patients with familial adenomatous polyposis: a prospective Japanese study. *Fam Cancer* 2016; 15: 75–83 doi:10.1007/s10689-015-9844-6
- [166] van Leerdam ME, Roos VH, van Hooft JE et al. Endoscopic management of polyposis syndromes: European Society of Gastrointestinal Endoscopy (ESGE) Guideline. *Endoscopy* 2019; 51: 877–895 doi:10.1055/a-0965-0605
- [167] Yang J, Gurudu SR, Koptiuch C et al. American Society for Gastrointestinal Endoscopy guideline on the role of endoscopy in familial adenomatous polyposis syndromes. *Gastrointest Endosc* 2020; 91: 963–982.e2 doi:10.1016/j.gie.2020.01.028
- [168] Han JW, Hong SN, Jang HJ et al. Clinical efficacy of various diagnostic tests for small bowel tumors and clinical features of tumors missed by capsule endoscopy. *Gastroenterol Res Pract* 2015; 2015: 623208 doi:10.1155/2015/623208
- [169] Tacheci I, Kopacova M, Bures J. Peutz-Jeghers syndrome. *Curr Opin Gastroenterol* 2021; 37: 245–254 doi:10.1097/MOG.0000000000000718
- [170] Latchford A, Cohen S, Auth M et al. Management of Peutz-Jeghers syndrome in children and adolescents: A position paper from the ESPGHAN Polyposis Working Group. *J Pediatr Gastroenterol Nutr* 2019; 68: 442–452 doi:10.1097/MPG.0000000000002248
- [171] van Lier MGF, Westerman AM, Wagner A et al. High cancer risk and increased mortality in patients with Peutz-Jeghers syndrome. *Gut* 2011; 60: 141–147 doi:10.1136/gut.2010.223750
- [172] Sulbaran M, de Moura E, Bernardo W et al. Overtube-assisted enteroscopy and capsule endoscopy for the diagnosis of small-bowel

- polyps and tumors: a systematic review and meta-analysis. *Endosc Int Open* 2016; 4: E151–E163 doi:10.1055/s-0041-108261
- [173] Gupta A, Postgate AJ, Burling D et al. A prospective study of MR enterography versus capsule endoscopy for the surveillance of adult patients with Peutz-Jeghers syndrome. *AJR Am J Roentgenol* 2010; 195: 108–116 doi:10.2214/AJR.09.3174
- [174] Caspari R, von Falkenhausen M, Krautmacher C et al. Comparison of capsule endoscopy and magnetic resonance imaging for the detection of polyps of the small intestine in patients with familial adenomatous polyposis or with Peutz-Jeghers syndrome. *Endoscopy* 2004; 36: 1054–1059 doi:10.1055/s-2004-826041
- [175] Rahmi G, Samaha E, Lorenceau-Savale C et al. Small bowel polypectomy by double balloon enteroscopy: Correlation with prior capsule endoscopy. *World J Gastrointest Endosc* 2013; 5: 219–225 doi:10.4253/wjge.v5.i5.219
- [176] Maccioni F, Al Ansari N, Mazzamuro F et al. Surveillance of patients affected by Peutz-Jeghers syndrome: diagnostic value of MR enterography in prone and supine position. *Abdom Imaging* 2012; 37: 279–287 doi:10.1007/s00261-011-9739-4
- [177] Goverde A, Korsche SE, Wagner A et al. Small-bowel surveillance in patients with Peutz-Jeghers syndrome: Comparing magnetic resonance enteroclysis and double balloon enteroscopy. *J Clin Gastroenterol* 2017; 51: e27–e33 doi:10.1097/MCG.0000000000000592
- [178] Nakamura M, Watanabe K, Ohmiya N et al. Tag-less patency capsule for suspected small bowel stenosis: Nationwide multicenter prospective study in Japan. *Dig Endosc* 2021; 33: 151–161 doi:10.1111/den.13673
- [179] Nakamura M, Hirooka Y, Yamamura T et al. Clinical usefulness of novel tag-less Agile patency capsule prior to capsule endoscopy for patients with suspected small bowel stenosis. *Dig Endosc* 2015; 27: 61–66 doi:10.1111/den.12306
- [180] van Lier MGF, Mathus-Vliegen EMH, Wagner A et al. High cumulative risk of intussusception in patients with Peutz-Jeghers syndrome: time to update surveillance guidelines? *Am J Gastroenterol* 2011; 106: 940–945 doi:10.1038/ajg.2010.473
- [181] Gilad O, Rosner G, Fliss-Isakov N et al. Clinical and histologic overlap and distinction among various hamartomatous polyposis syndromes. *Clin Transl Gastroenterol* 2019; 10: 1–9 doi:10.14309/ctg.0000000000000035
- [182] Gao H, van Lier MG, Poley JW et al. Endoscopic therapy of small-bowel polyps by double-balloon enteroscopy in patients with Peutz-Jeghers syndrome. *Gastrointest Endosc* 2010; 71: 768–773 doi:10.1016/j.gie.2009.11.005
- [183] Cortegoso Valdivia P, Rondonotti E, Pennazio M. Safety and efficacy of an enteroscopy-based approach in reducing the polyp burden in patients with Peutz-Jeghers syndrome: Experience from a tertiary referral center. *Ther Adv Gastrointest Endosc* 2020; 13: 2631774520919369 doi:10.1177/2631774520919369
- [184] Perrod G, Samaha E, Perez-Cuadrado-Robles E et al. Small bowel polyp resection using device-assisted enteroscopy in Peutz-Jeghers syndrome: Results of a specialised tertiary care centre. *United Eur Gastroenterol J* 2020; 8: 204–210 doi:10.1177/2050640619874525
- [185] Wang YX, Bian DJ, Zhu HY et al. The role of double-balloon enteroscopy in reducing the maximum size of polyps in patients with Peutz-Jeghers syndrome: 12-year experience. *J Dig Dis* 2019; 20: 415–420 doi:10.1111/1751-2980.12784
- [186] Lafeuille P, Calavas L, Ragi O et al. Ileoileal intussusception treated by polypectomy with spiral enteroscopy in Peutz-Jeghers syndrome. *Endoscopy* 2022; 54: E57–E58 doi:10.1055/a-1382-8060
- [187] Pennazio M, Venezia L, Gambella A et al. Underwater endoscopic mucosal resection of a large jejunal polyp by single-balloon enteroscopy in a patient with Peutz-Jeghers syndrome. *Dig Liver Dis* 2019; 51: 170–172 doi:10.1016/j.dld.2018.08.017
- [188] Khurelbaatar T, Sakamoto H, Yano T et al. Endoscopic ischemic polypectomy for small-bowel polyps in patients with Peutz-Jeghers syndrome. *Endoscopy* 2021; 53: 744–748 doi:10.1055/a-1276-6452
- [189] Limpas Kamiya KJL, Hosoe N, Takabayashi K et al. Feasibility and safety of endoscopic ischemic polypectomy and clinical outcomes in patients with Peutz-Jeghers syndrome (with Video). *Dig Dis Sci* 2022: doi:10.1007/s10620-022-07477-w
- [190] Sakamoto H, Yamamoto H, Hayashi Y et al. Nonsurgical management of small-bowel polyps in Peutz-Jeghers syndrome with extensive polypectomy by using double-balloon endoscopy. *Gastrointest Endosc* 2011; 74: 328–333 doi:10.1016/j.gie.2011.04.001
- [191] Ohmiya N, Nakamura M, Takenaka H et al. Management of small-bowel polyps in Peutz-Jeghers syndrome by using enteroclysis, double-balloon enteroscopy, and videocapsule endoscopy. *Gastrointest Endosc* 2010; 72: 1209–1216 doi:10.1016/j.gie.2010.08.018
- [192] Wain KE, Ellingson MS, McDonald J et al. Appreciating the broad clinical features of SMAD4 mutation carriers: a multicenter chart review. *Genet Med* 2014; 16: 588–593 doi:10.1038/gim.2014.5
- [193] Postgate AJ, Will OC, Fraser CH et al. Capsule endoscopy for the small bowel in juvenile polyposis syndrome: a case series. *Endoscopy* 2009; 41: 1001–1004 doi:10.1055/s-0029-1215175
- [194] Cohen S, Hyer W, Mas E et al. Management of juvenile polyposis syndrome in children and adolescents: A position paper from the ESPGHAN Polyposis Working Group. *J Pediatr Gastroenterol Nutr* 2019; 68: 453–462 doi:10.1097/MPG.0000000000002246
- [195] Awadie H, Klein A, Tate D et al. The prevalence of small-bowel polyps on video capsule endoscopy in patients with sporadic duodenal or ampullary adenomas. *Gastrointest Endosc* 2021; 93: 630–636 doi:10.1016/j.gie.2020.07.029
- [196] Simon M, Cosnes J, Gornet JM et al. Endoscopic detection of small bowel dysplasia and adenocarcinoma in Crohn's disease: a prospective cohort-study in high-risk patients. *J Crohns Colitis* 2017; 11: 47–52 doi:10.1093/ecco-jcc/jjw123
- [197] Saurin J-C, Pilleul F, Soussan E et al. Small-bowel capsule endoscopy diagnoses early and advanced neoplasms in asymptomatic patients with Lynch syndrome. *Endoscopy* 2010; 42: 1057–1062 doi:10.1055/s-0030-1255742
- [198] Haanstra JF, Al-Toma A, Dekker E et al. Incidence of small bowel neoplasia in Lynch syndrome assessed by video capsule endoscopy. *Endosc Int Open* 2017; 5: E622–E626 doi:10.1055/s-0043-111723
- [199] Baba Y, Kawano S, Kono Y et al. Clinical characteristics and risk factors for rebleeding in patients with obscure gastrointestinal bleeding. *Intern Med Tokyo Jpn* 2020; 59: 1345–1350 doi:10.2169/internalmedicine.3628-19
- [200] Calabrese C, Gionchetti P, Calafiore A et al. Sporadic small bowel tumors detected by capsule endoscopy in patients with occult gastrointestinal bleeding. *Intern Emerg Med* 2015; 10: 781–785 doi:10.1007/s11739-015-1314-5
- [201] Johnston CA, Yung DE, Joshi A et al. Small bowel malignancy in patients undergoing capsule endoscopy at a tertiary care academic center: Case series and review of the literature. *Endosc Int Open* 2017; 5: E463–E470 doi:10.1055/s-0043-106186
- [202] Pérez-Cuadrado-Robles E, Zamora-Nava LE, Jiménez-García VA et al. Indications for and diagnostic yield of capsule endoscopy in the elderly. *Rev Gastroenterol Mex Engl* 2018; 83: 238–244 doi:10.1016/j.rgmx.2017.08.004
- [203] Li L, Chen C, Li Y et al. The role of capsule endoscopy in the diagnosis and treatment of obscure gastrointestinal bleeding in older individuals. *Eur J Gastroenterol Hepatol* 2016; 28: 1425–1430 doi:10.1097/MEG.0000000000000737
- [204] Sidhu PS, McAlindon ME, Drew K et al. The utility of capsule endoscopy in patients under 50 years of age with recurrent iron deficiency

- anaemia: is the juice worth the squeeze? *Gastroenterol Res Pract* 2015; 2015: 1–5 doi:10.1155/2015/948574
- [205] Wang L, Xie M, Hong L et al. The diagnostic yields and safety of double-balloon enteroscopy in obscure gastrointestinal bleeding and incomplete small bowel obstruction: comparison between the adults and elderly. *Gastroenterol Res Pract* 2020; 2020: 8121625 doi:10.1155/2020/8121625
- [206] Segarajasingam DS, Hanley SC, Barkun AN et al. Randomized controlled trial comparing outcomes of video capsule endoscopy with push enteroscopy in obscure gastrointestinal bleeding. *Can J Gastroenterol Hepatol* 2015; 29: 85–90 doi:10.1155/2015/897567
- [207] Ma J-J, Wang Y, Xu X-M et al. Capsule endoscopy and single-balloon enteroscopy in small bowel diseases: Competing or complementary? *World J Gastroenterol* 2016; 22: 10625–10630 doi:10.3748/wjg.v22.i48.10625
- [208] Ooka S, Kobayashi K, Kawagishi K et al. Roles of capsule endoscopy and single-balloon enteroscopy in diagnosing unexplained gastrointestinal bleeding. *Clin Endosc* 2016; 49: 56–60 doi:10.5946/ce.2016.49.1.56
- [209] Kakiya Y, Shiba M, Okamoto J et al. A comparison between capsule endoscopy and double balloon enteroscopy using propensity score-matching analysis in patients with previous obscure gastrointestinal bleeding. *Scand J Gastroenterol* 2017; 52: 306–311 doi:10.1080/00365521.2016.1253766
- [210] Pérez-Cuadrado-Robles E, Esteban-Delgado P, Martínez-Andrés B et al. Diagnosis agreement between capsule endoscopy and double-balloon enteroscopy in obscure gastrointestinal bleeding at a referral center. *Rev Esp Enferm Dig* 2015; 107: 495–500 doi:10.17235/reed.2015.3665/2015
- [211] Shiani A, Nieves J, Lipka S et al. Degree of concordance between single balloon enteroscopy and capsule endoscopy for obscure gastrointestinal bleeding after an initial positive capsule endoscopy finding. *Ther Adv Gastroenterol* 2016; 9: 13–18 doi:10.1177/1756283X15610042
- [212] Kalra AS, Walker AJ, Benson ME et al. Comparison of capsule endoscopy findings to subsequent double balloon enteroscopy: a dual center experience. *Diagn Ther Endosc* 2015; 2015: 438757 doi:10.1155/2015/438757
- [213] Zhang Z-H, Qiu C-H, Li Y. Different roles of capsule endoscopy and double-balloon enteroscopy in obscure small intestinal diseases. *World J Gastroenterol* 2015; 21: 7297–7304 doi:10.3748/wjg.v21.i23.7297
- [214] Benmassaoud A, Sasson MS, Pamphile JC et al. The use of balloon-assisted enteroscopy at a large volume centre: a retrospective analysis. *J Can Assoc Gastroenterol* 2018; 1: 33–39 doi:10.1093/jcag/gwy007
- [215] Vasconcelos RN, Dolan SG, Barlow JM et al. Impact of CT enterography on the diagnosis of small bowel gastrointestinal stromal tumors. *Abdom Radiol N Y* 2017; 42: 1365–1373 doi:10.1007/s00261-016-1033-z
- [216] Gangi A, Siegel E, Barmparas G et al. Multifocality in small bowel neuroendocrine tumors. *J Gastrointest Surg* 2018; 22: 303–309 doi:10.1007/s11605-017-3586-8
- [217] Deepak P, Pundi KN, Bruining DH et al. Multiphase computed tomographic enterography: diagnostic yield and efficacy in patients with suspected small bowel bleeding. *Mayo Clin Proc Innov Qual Outcomes* 2019; 3: 438–447 doi:10.1016/j.mayocpiqo.2019.09.001
- [218] Tseng C-M, Lin I-C, Chang C-Y et al. Role of computed tomography angiography on the management of overt obscure gastrointestinal bleeding. *PLoS One* 2017; 12: e0172754 doi:10.1371/journal.pone.0172754
- [219] Pei-You G, Jun-Xia L, Feng-Li L et al. Retrospective comparison of computed tomography enterography and magnetic resonance enterography in diagnosing small intestine disease. *JPM J Pak Med Assoc* 2015; 65: 710–714
- [220] Zhang C, Hong L, Zhang T et al. Clinical characteristics of small bowel tumors diagnosed by double-balloon endoscopy: Experience from a Chinese tertiary hospital. *Turk J Gastroenterol* 2020; 31: 30–35 doi:10.5152/tjg.2020.19115
- [221] Chu Y, Wu S, Qian Y et al. Complimentary imaging modalities for investigating obscure gastrointestinal bleeding: capsule endoscopy, double-balloon enteroscopy, and computed tomographic enterography. *Gastroenterol Res Pract* 2016; 2016: 8367519 doi:10.1155/2016/8367519
- [222] Fujita M, Manabe N, Honda K et al. Usefulness of ultrasonography for diagnosis of small bowel tumors: a comparison between ultrasonography and endoscopic modalities. *Medicine (Baltimore)* 2015; 94: e1464 doi:10.1097/MD.0000000000001464
- [223] Robles EP-C, Delgado PE, Conesa PB et al. Role of double-balloon enteroscopy in malignant small bowel tumors. *World J Gastrointest Endosc* 2015; 7: 652–658 doi:10.4253/wjge.v7.i6.652
- [224] Nakano A, Nakamura M, Watanabe O et al. Endoscopic characteristics, risk grade, and prognostic prediction in gastrointestinal stromal tumors of the small bowel. *Digestion* 2017; 95: 122–131 doi:10.1159/000454728
- [225] Zhou L, Liao Y, Wu J et al. Small bowel gastrointestinal stromal tumor: a retrospective study of 32 cases at a single center and review of the literature. *Ther Clin Risk Manag* 2018; 14: 1467–1481 doi:10.2147/TCRM.S167248
- [226] Kim S, Marcus R, Wells ML et al. The evolving role of imaging for small bowel neuroendocrine neoplasms: estimated impact of imaging and disease-free survival in a retrospective observational study. *Abdom Radiol N Y* 2020; 45: 623–631 doi:10.1007/s00261-020-02410-z
- [227] Dohan A, El Fattach H, Barat M et al. Neuroendocrine tumors of the small bowel: evaluation with MR-enterography. *Clin Imaging* 2016; 40: 541–547 doi:10.1016/j.clinimag.2015.12.016
- [228] Manguso N, Gangi A, Johnson J et al. The role of pre-operative imaging and double balloon enteroscopy in the surgical management of small bowel neuroendocrine tumors: Is it necessary? *J Surg Oncol* 2018; 117: 207–212 doi:10.1002/jso.24825
- [229] Nakamura M, Ohmiya N, Hirooka Y et al. Endoscopic diagnosis of follicular lymphoma with small-bowel involvement using video capsule endoscopy and double-balloon enteroscopy: a case series. *Endoscopy* 2012; 45: 67–70 doi:10.1055/s-0032-1325867
- [230] Albert JG, Schülbe R, Hahn L et al. Impact of capsule endoscopy on outcome in mid-intestinal bleeding: a multicentre cohort study in 285 patients. *Eur J Gastroenterol Hepatol* 2008; 20: 971–977 doi:10.1097/MEG.0b013e3282fb2a53
- [231] Iwamuro M, Okada H, Kawano S et al. A multicenter survey of enteroscopy for the diagnosis of intestinal follicular lymphoma. *Oncol Lett* 2015; 10: 131–136 doi:10.3892/ol.2015.3251
- [232] Zhang F, Amateau SK, Khashab MA et al. Mid-gut stents. *Curr Opin Gastroenterol* 2012; 28: 451–460 doi:10.1097/MOG.0-b013e3283561f3b
- [233] Zhang Y-F, Ning S-B, Li B-R et al. Combined use of single-balloon enteroscope and colonoscope for self-expandable metal stent placement in patients with malignant small intestinal obstruction: a single-center comparative clinical observation. *J Huazhong Univ Sci Technol Med Sci* 2017; 37: 357–361 doi:10.1007/s11596-017-1740-x
- [234] Nishimura N, Mizuno M, Shimodate Y et al. The role of double-balloon enteroscopy in the diagnosis and surgical treatment of metastatic small bowel tumors. *Intern Med Tokyo Jpn* 2018; 57: 1209–1212 doi:10.2169/internalmedicine.9877-17
- [235] Murray JA, Rubio-Tapia A, Van Dyke CT et al. Mucosal atrophy in celiac disease: extent of involvement, correlation with clinical presen-

- tation, and response to treatment. *Clin Gastroenterol Hepatol* 2008; 6: 186–193 quiz 125 doi:10.1016/j.cgh.2007.10.012
- [236] Petroni R, Dubcenco E, Baker JP et al. Given® capsule endoscopy in celiac disease: evaluation of diagnostic accuracy and interobserver agreement. *Am J Gastroenterol* 2005; 100: 685–694 doi:10.1111/j.1572-0241.2005.41069.x
- [237] Hopper AD, Sidhu R, Hurlstone DP et al. Capsule endoscopy: an alternative to duodenal biopsy for the recognition of villous atrophy in coeliac disease? *Dig Liver Dis* 2007; 39: 140–145 doi:10.1016/j.dld.2006.07.017
- [238] Lidums I, Cummins AG, Teo E. The role of capsule endoscopy in suspected celiac disease patients with positive celiac serology. *Dig Dis Sci* 2011; 56: 499–505 doi:10.1007/s10620-010-1290-6
- [239] Rondonotti E, Spada C, Cave D et al. Video capsule enteroscopy in the diagnosis of celiac disease: a multicenter study. *Am J Gastroenterol* 2007; 102: 1624–1631 doi:10.1111/j.1572-0241.2007.01238.x
- [240] Rokkas T, Niv Y. The role of video capsule endoscopy in the diagnosis of celiac disease: a meta-analysis. *Eur J Gastroenterol Hepatol* 2012; 24: 303–308 doi:10.1097/MEG.0b013e32834fa914
- [241] Branchi F, Ferretti F, Orlando S et al. Small-bowel capsule endoscopy in patients with celiac disease, axial versus lateral/panoramic view: Results from a prospective randomized trial. *Dig Endosc* 2020; 32: 778–784 doi:10.1111/den.13575
- [242] Penny HA, Raju SA, Lau MS et al. Accuracy of a no-biopsy approach for the diagnosis of coeliac disease across different adult cohorts. *Gut* 2021; 70: 876–883 doi:10.1136/gutjnl-2020-320913
- [243] Wang X, Qian H, Ciaccio EJ et al. Celiac disease diagnosis from videocapsule endoscopy images with residual learning and deep feature extraction. *Comput Methods Programs Biomed* 2020; 187: 105236 doi:10.1016/j.cmpb.2019.105236
- [244] Chetcuti Zammit S, McAlindon ME, Sanders DS et al. Assessment of disease severity on capsule endoscopy in patients with small bowel villous atrophy. *J Gastroenterol Hepatol* 2021; 36: 1015–1021 doi:10.1111/jgh.15217
- [245] Chetcuti Zammit S, Sanders DS, Sidhu R. Bone mineral density in patients with celiac disease: a further association with extent of disease on capsule endoscopy. *J Clin Gastroenterol* 2020; 54: 294–295 doi:10.1097/MCG.0000000000001294
- [246] Elli L, Ferretti F, Orlando S et al. Management of celiac disease in daily clinical practice. *Eur J Intern Med* 2019; 61: 15–24 doi:10.1016/j.ejim.2018.11.012
- [247] Adler SN, Jacob H, Lijovetzky G et al. Positive coeliac serology in irritable bowel syndrome patients with normal duodenal biopsies: Video capsule endoscopy findings and HLA-DQ typing may affect clinical management. *J Gastrointest Liver Dis JGLD* 2006; 15: 221–225
- [248] Kurien M, Evans KE, Aziz I et al. Capsule endoscopy in adult celiac disease: a potential role in equivocal cases of celiac disease? *Gastrointest Endosc* 2013; 77: 227–232 doi:10.1016/j.gie.2012.09.031
- [249] Chetcuti Zammit S, Schiepati A, Aziz I et al. Use of small-bowel capsule endoscopy in cases of equivocal celiac disease. *Gastrointest Endosc* 2020; 91: 1312–1321.e2 doi:10.1016/j.gie.2019.12.044
- [250] Luján-Sanchis M, Pérez-Cuadrado-Robles E, García-Lledó J et al. Role of capsule endoscopy in suspected celiac disease: A European multicenter study. *World J Gastroenterol* 2017; 23: 703 doi:10.3748/wjg.v23.i4.703
- [251] Ludvigsson JF, Leffler DA, Bai JC et al. The Oslo definitions for coeliac disease and related terms. *Gut* 2013; 62: 43–52 doi:10.1136/gutjnl-2011-301346
- [252] Al-Toma A, Volta U, Auricchio R et al. European Society for the Study of Coeliac Disease (ESsCD) guideline for coeliac disease and other gluten-related disorders. *United Eur Gastroenterol J* 2019; 7: 583–613 doi:10.1177/2050640619844125
- [253] Atlas DS, Rubio-Tapia A, Van Dyke CT et al. Capsule endoscopy in nonresponsive celiac disease. *Gastrointest Endosc* 2011; 74: 1315–1322 doi:10.1016/j.gie.2011.05.049
- [254] Barret M, Malamut G, Rahmi G et al. Diagnostic yield of capsule endoscopy in refractory celiac disease. *Am J Gastroenterol* 2012; 107: 1546–1553 doi:10.1038/ajg.2012.199
- [255] Hadithi M, Al-toma A, Oudejans J et al. The value of double-balloon enteroscopy in patients with refractory celiac disease. *Am J Gastroenterol* 2007; 102: 987–996 doi:10.1111/j.1572-0241.2007.01122.x
- [256] Tomba C, Elli L, Bardella MT et al. Enteroscopy for the early detection of small bowel tumours in at-risk celiac patients. *Dig Liver Dis* 2014; 46: 400–404 doi:10.1016/j.dld.2013.12.009
- [257] Zammit SC, Elli L, Scaramella L et al. Small bowel capsule endoscopy in refractory celiac disease: a luxury or a necessity? *Ann Gastroenterol* 2021; 34: 188–195 doi:10.20524/aog.2021.0586
- [258] Chetcuti Zammit S, Sanders DS, Cross SS et al. Capsule endoscopy in the management of refractory coeliac disease. *J Gastrointest Liver Dis* 2019; 28: 15–22 doi:10.15403/jgld.2014.1121.281.cel
- [259] Ferretti F, Branchi F, Orlando S et al. Effectiveness of capsule endoscopy and double-balloon enteroscopy in suspected complicated celiac disease. *Clin Gastroenterol Hepatol* 2020; doi:10.1016/j.cgh.2020.11.010
- [260] Perez-Cuadrado-Robles E, Lujan-Sanchis M, Elli L et al. Role of capsule endoscopy in alarm features and non-responsive celiac disease: A European multicenter study. *Dig Endosc* 2018; 30: 461–466 doi:10.1111/den.13002
- [261] Tomba C, Sidhu R, Sanders DS et al. Celiac disease and double-balloon enteroscopy: what can we achieve? the experience of 2 European tertiary referral centers *J Clin Gastroenterol* 2016; 50: 313–317 doi:10.1097/MCG.0000000000000424
- [262] Elli L, Casazza G, Locatelli M et al. Use of enteroscopy for the detection of malignant and premalignant lesions of the small bowel in complicated celiac disease: a meta-analysis. *Gastrointest Endosc* 2017; 86: 264–273.e1 doi:10.1016/j.gie.2017.04.006
- [263] Branchi F, Locatelli M, Tomba C et al. Enteroscopy and radiology for the management of celiac disease complications: Time for a pragmatic roadmap. *Dig Liver Dis* 2016; 48: 578–586 doi:10.1016/j.dld.2016.02.015
- [264] Mearin F, Lacy BE, Chang L et al. Bowel disorders. *Gastroenterology* 2016; doi:10.1053/j.gastro.2016.02.031
- [265] Chou J-W, Chung C-S, Huang T-Y et al. Meckel's diverticulum diagnosed by balloon-assisted enteroscopy: a multicenter report from the Taiwan Association for the Study of Small Intestinal Diseases (TASSID). *Gastroenterol Res Pract* 2021; 2021: 1–10 doi:10.1155/2021/9574737
- [266] Herrera Quiñones G, Scharrer SI, Jiménez Rodríguez AR et al. Diagnosis of eosinophilic enteritis with video capsule endoscopy and double balloon enteroscopy with favorable response to corticosteroids. *ACG Case Rep J* 2019; 6: e00127 doi:10.14309/crj.0000000000000127
- [267] Shim K-N, Kim Y-S, Kim K-J et al. Abdominal pain accompanied by weight loss may increase the diagnostic yield of capsule endoscopy: a Korean multicenter study. *Scand J Gastroenterol* 2006; 41: 983–988 doi:10.1080/00365520600548974
- [268] Katsinelos P, Fasoulas K, Beltsis A et al. Diagnostic yield and clinical impact of wireless capsule endoscopy in patients with chronic abdominal pain with or without diarrhea: a Greek multicenter study. *Eur J Intern Med* 2011; 22: e63–66 doi:10.1016/j.ejim.2011.06.012
- [269] Huang L, Huang Z, Tai Y et al. The small bowel diseases detected by capsule endoscopy in patients with chronic abdominal pain: A retrospective study. *Medicine (Baltimore)* 2018; 97: e0025 doi:10.1097/MD.00000000000010025

- [270] Kim W, Lee B, Yoo A et al. Predictors of positive video capsule endoscopy findings for chronic unexplained abdominal pain: single-center retrospective study and meta-analysis. *Diagnostics* 2021; 11: 2123 doi:10.3390/diagnostics11112123
- [271] Kim J, Lee BJ, Ham NS et al. Balloon-assisted enteroscopy for retrieval of small intestinal foreign bodies: a KASID multicenter study. *Gastroenterol Res Pract* 2020; 2020: 1–9 doi:10.1155/2020/3814267
- [272] Gkolfakis P, Arvanitakis M, Despott EJ et al. Endoscopic management of enteral tubes in adult patients – Part 2: Peri- and post-procedural management. *European Society of Gastrointestinal Endoscopy (ESGE) Guideline. Endoscopy* 2021; 53: 178–195 doi:10.1055/a-1331-8080
- [273] Al-Bawardy B, Gorospe EC, Alexander JA et al. Outcomes of double-balloon enteroscopy-assisted direct percutaneous endoscopic jejunostomy tube placement. *Endoscopy* 2016; 48: 552–556 doi:10.1055/s-0042-101853
- [274] Nishiwaki S, Kurobe T, Baba A et al. Prognostic outcomes after direct percutaneous endoscopic jejunostomy in elderly patients: comparison with percutaneous endoscopic gastrostomy. *Gastrointest Endosc* 2021; 94: 48–56 doi:10.1016/j.gie.2020.12.036
- [275] Simoes PK, Woo KM, Shike M et al. Direct percutaneous endoscopic jejunostomy: procedural and nutrition outcomes in a large patient cohort. *JPEN J Parenter Enteral Nutr* 2018; 42: 898–906 doi:10.1002/jpen.1023
- [276] Deliwala SS, Chandan S, Kumar A et al. Direct percutaneous endoscopic jejunostomy (DPEJ) and percutaneous endoscopic gastrostomy with jejunal extension (PEG-J) technical success and outcomes: Systematic review and meta-analysis. *Endosc Int Open* 2022; 10: E488–E520 doi:10.1055/a-1774-4736
- [277] Moreels TG. Techniques for endoscopic retrograde cholangiopancreatography in altered gastrointestinal anatomy. *Curr Opin Gastroenterol* 2017; 33: 339–345 doi:10.1097/MOG.0000000000000381
- [278] Testoni PA, Mariani A, Aabakken L et al. Papillary cannulation and sphincterotomy techniques at ERCP: European Society of Gastrointestinal Endoscopy (ESGE) Clinical Guideline. *Endoscopy* 2016; 48: 657–683 doi:10.1055/s-0042-108641
- [279] Mbatshi G, Macken EJ, De Schepper HU et al. Comparison of side-viewing duodenoscope and single-balloon enteroscope to perform ERCP in patients with Billroth II gastrectomy. *Acta Gastro-Enterol Belg* 2017; 80: 493–497
- [280] Inamdar S, Slattery E, Sejal DV et al. Systematic review and meta-analysis of single-balloon enteroscopy-assisted ERCP in patients with surgically altered GI anatomy. *Gastrointest Endosc* 2015; 82: 9–19 doi:10.1016/j.gie.2015.02.013
- [281] Shao X-D, Qi X-S, Guo X-Z. Endoscopic retrograde cholangiopancreatography with double balloon enteroscope in patients with altered gastrointestinal anatomy: A meta-analysis. *Saudi J Gastroenterol* 2017; 23: 150–160 doi:10.4103/1319-3767.207713
- [282] Klair JS, Jayaraj M, Chandrasekar VT et al. ERCP with overtube-assisted enteroscopy in patients with Roux-en-Y gastric bypass anatomy: a systematic review and meta-analysis. *Endoscopy* 2020; 52: 824–832 doi:10.1055/a-1178-9741
- [283] Anvari S, Lee Y, Patro N et al. Double-balloon enteroscopy for diagnostic and therapeutic ERCP in patients with surgically altered gastrointestinal anatomy: a systematic review and meta-analysis. *Surg Endosc* 2021; 35: 18–36 doi:10.1007/s00464-020-07893-x
- [284] Tanisaka Y, Ryozaawa S, Mizuide M et al. Status of single-balloon enteroscopy-assisted endoscopic retrograde cholangiopancreatography in patients with surgically altered anatomy: Systematic review and meta-analysis on biliary interventions. *Dig Endosc* 2021; 33: 1034–1044 doi:10.1111/den.13878
- [285] Kawaguchi Y, Yamauchi H, Kida M et al. Failure factors to reach the blind end using a short-type single-balloon enteroscope for ERCP with Roux-en-Y reconstruction: a multicenter retrospective study. *Gastroenterol Res Pract* 2019; 2019: 1–8 doi:10.1155/2019/3536487
- [286] Tanisaka Y, Ryozaawa S, Itoi T et al. Efficacy and factors affecting procedure results of short-type single-balloon enteroscopy-assisted ERCP for altered anatomy: a multicenter cohort in Japan. *Gastrointest Endosc* 2022; 95: 310–318.e1 doi:10.1016/j.gie.2021.09.008
- [287] Beyna T, Schneider M, Höllerich J et al. Motorized spiral enteroscopy-assisted ERCP after Roux-en-Y reconstructive surgery and bilioenteric anastomosis: first clinical case. *VideoGIE* 2020; 5: 311–313 doi:10.1016/j.vgie.2020.03.016
- [288] Moreels TG. Endoscopic retrograde cholangiopancreatography in Roux-en-Y gastric bypass patients. *Minerva Chir* 2019; 74: 326–333 doi:10.23736/S0026-4733.18.07929-4
- [289] Khara HS, Parvataneni S, Park S et al. Review of ERCP techniques in Roux-en-Y gastric bypass patients: highlight on the novel EUS-directed transgastric ERCP (EGDE) technique. *Curr Gastroenterol Rep* 2021; 23: 10 doi:10.1007/s11894-021-00808-3
- [290] Connell M, Sun WYL, Mocanu V et al. Management of choledocholithiasis after Roux-en-Y gastric bypass: a systematic review and pooled proportion meta-analysis. *Surg Endosc* 2022; doi:10.1007/s00464-022-09018-y
- [291] Chen Y-I, Levy MJ, Moreels TG et al. An international multicenter study comparing EUS-guided pancreatic duct drainage with enteroscopy-assisted endoscopic retrograde pancreatography after Whipple surgery. *Gastrointest Endosc* 2017; 85: 170–177 doi:10.1016/j.gie.2016.07.031
- [292] Khan Z, Hayat U, Moraveji S et al. EUS-guided pancreatic ductal intervention: A comprehensive literature review. *Endosc Ultrasound* 2021; 10: 98–102 doi:10.4103/eus.eus_67_20
- [293] van der Merwe SW, van Wanrooij RLJ, Bronswijk M et al. Therapeutic endoscopic ultrasound: European Society of Gastrointestinal Endoscopy (ESGE) Guideline. *Endoscopy* 2022; 54: 185–205 doi:10.1055/a-1717-1391
- [294] Vasilakakis M, Koulaouzidis A, Yung DE et al. Follow-up on: optimizing lesion detection in small bowel capsule endoscopy and beyond: from present problems to future solutions. *Expert Rev Gastroenterol Hepatol* 2019; 13: 129–141 doi:10.1080/17474124.2019.1553616
- [295] Dray X, Iakovidis D, Houdeville C et al. Artificial intelligence in small bowel capsule endoscopy - current status, challenges and future promise. *J Gastroenterol Hepatol* 2021; 36: 12–19 doi:10.1111/jgh.15341
- [296] Ding Z, Shi H, Zhang H et al. Gastroenterologist-level identification of small-bowel diseases and normal variants by capsule endoscopy using a deep-learning model. *Gastroenterology* 2019; 157: 1044–1054.e5 doi:10.1053/j.gastro.2019.06.025
- [297] Xie X, Xiao Y-F, Li J-J et al. Development and validation of an artificial intelligence model for small bowel capsule endoscopy video review. *JAMA Netw Open* 2022; 5: e2221992 doi:10.1001/jamanetworkopen.2022.21992
- [298] Cortegoso Valdivia P, Elosua A, Houdeville C et al. Clinical feasibility of panintestinal (or panenteric) capsule endoscopy: a systematic review. *Eur J Gastroenterol Hepatol* 2021; 33: 949–955 doi:10.1097/MEG.0000000000002200
- [299] Xiao Y-F, Wu Z-X, He S et al. Fully automated magnetically controlled capsule endoscopy for examination of the stomach and small bowel: a prospective, feasibility, two-centre study. *Lancet Gastroenterol Hepatol* 2021; 6: 914–921 doi:10.1016/S2468-1253(21)00274-0
- [300] Nowak T. A global perspective on capsule endoscopy. *Ann Transl Med* 2017; 5: 422 doi:10.21037/atm.2017.10.20
- [301] Beyna T, Arvanitakis M, Schneider M et al. Motorised spiral enteroscopy: first prospective clinical feasibility study. *Gut* 2020; doi:10.1136/gutjnl-2019-319908

- [302] Beyna T, Arvanitakis M, Schneider M et al. Total motorized spiral enteroscopy: first prospective clinical feasibility trial. *Gastrointest Endosc* 2021; 93: 1362–1370 doi:10.1016/j.gie.2020.10.028
- [303] Ramchandani M, Rughwani H, Inavolu P et al. Diagnostic yield and therapeutic impact of novel motorized spiral enteroscopy in small-bowel disorders: a single-center, real-world experience from a tertiary care hospital (with video). *Gastrointest Endosc* 2021; 93: 616–626 doi:10.1016/j.gie.2020.07.001
- [304] Beyna T, Moreels T, Arvanitakis M et al. Motorized spiral enteroscopy: Results of an international, multicenter, prospective observational clinical study on patients with normal and altered gastrointestinal anatomy. *Endoscopy* 2022: doi:10.1055/a-1831-6215
- [305] Al-Toma A, Beaumont H, Koornstra JJ et al. The performance and safety of motorized spiral enteroscopy, including in patients with surgically altered gastrointestinal anatomy: a multicenter prospective study. *Endoscopy* 2022: doi:10.1055/a-1783-4802
- [306] Liu S, Dong T, Shi Y et al. Water exchange-assisted versus carbon dioxide-insufflated single-balloon enteroscopy: a randomized controlled trial. *Endoscopy* 2021: doi:10.1055/a-1459-4571
- [307] Blanco Velasco G, Zamarripa-Mottú RA, Soria-Rodríguez R et al. Efficacy and safety of water-exchange enteroscopy compared to carbon dioxide insufflation during enteroscopy. *Rev Esp Enferm Dig* 2020; 112: doi:10.17235/reed.2020.6788/2019