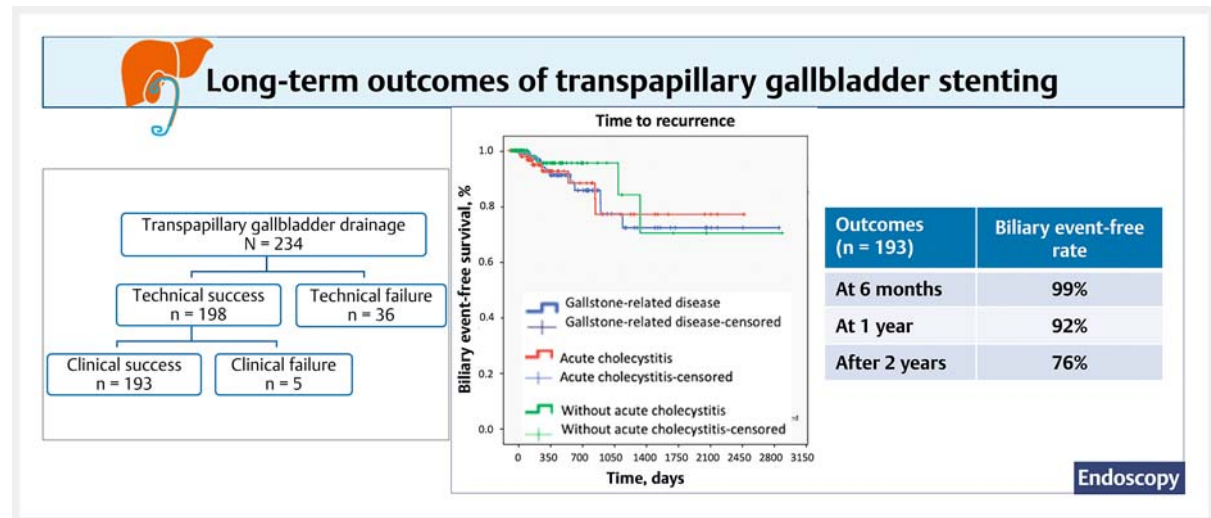






# Intermediate- to long-term outcomes of endoscopic transpapillary gallbladder stenting in patients with gallstone-related disease: a 10-year single-center experience

## GRAPHICAL ABSTRACT



### Authors

Wiriyaporn Ridditid<sup>1,2</sup> , Natee Faknak<sup>1,2</sup>, Panida Piyachaturawat<sup>1,2</sup>, Nicha Teeratorn<sup>1,2</sup>, Yingluk Sritunyarat<sup>1,2</sup>, Phonthep Angsuwatharakon<sup>2,3</sup> , Parit Mekaroonkamol<sup>1,2</sup>, Pradermchai Kongkam<sup>1,2</sup> , Rungsun Rerknimitr<sup>1,2</sup> 

### Institutions

- 1 Division of Gastroenterology, Department of Medicine, Faculty of Medicine, Chulalongkorn University, Bangkok, Thailand
- 2 Excellence Center for Gastrointestinal Endoscopy, King Chulalongkorn Memorial Hospital, Bangkok, Thailand
- 3 Division of Anatomy, Faculty of Medicine, Chulalongkorn University, Bangkok, Thailand

submitted 20.6.2022

accepted after revision 18.10.2022

published online 18.10.2022

### Bibliography

Endoscopy 2023; 55: 469–475

DOI 10.1055/a-1962-7305

ISSN 0013-726X

© 2022, Thieme. All rights reserved.

Georg Thieme Verlag KG, Rüdigerstraße 14, 70469 Stuttgart, Germany

 Supplementary material

Supplementary material is available under <https://doi.org/10.1055/a-1962-7305>

 Scan this QR-Code for the author commentary.



### Corresponding author

Rungsun Rerknimitr, MD, Division of Gastroenterology, Department of Medicine, Faculty of Medicine, Chulalongkorn University and King Chulalongkorn Memorial Hospital, Rama 4 Road, Patumwan, Bangkok, Thailand 10330  
ercp@live.com

### ABSTRACT

**Background** Endoscopic transpapillary gallbladder stenting (ETGS) can be a bridging therapy to elective cholecystectomy or a permanent gallbladder drainage method in patients with symptomatic gallbladder disease who are awaiting cholecystectomy or are unfit for surgery, respectively. We evaluated the intermediate- to long-term outcomes of ETGS in these groups.

**Methods** We retrospectively reviewed 234 patients (acute cholecystitis = 147), who were unfit for surgery (n = 50) or had deferred cholecystectomy (n = 184) and who underwent ETGS between 2012 and 2021. A 7-Fr, 15-cm, double-pigtail plastic stent was placed for ETGS without scheduled stent exchange. Biliary event-free rates (i.e. cholecystitis and cholangitis) were determined at 6 months, 1 year, and  $\geq 2$  years.

**Results** Technical and clinical success rates were 84.6% (198/234) and 97.4% (193/198), respectively. Kaplan–Meier analysis (n = 193) showed a biliary event-free rate of 99%

(95%CI 0.95–1.00) at 6 months, 92% (95%CI 0.87–0.97) at 1 year, and 76% (95%CI 0.65–0.93) at  $\geq 2$  years, during a median follow-up period of 564 days (range 200–3001 days).

**Conclusions** ETGS is an effective biliary drainage method that should be considered in selected cases with common bile duct stone where cholecystectomy could not be performed or was deferred. The biliary event-free rates of  $\geq 76\%$  up to  $\geq 2$  years further support the use of ETGS in these patient groups.

## Introduction

Endoscopic gallbladder drainage has been recently proposed as an alternative treatment strategy to percutaneous cholecystostomy in patients with symptomatic gallbladder disease who are at high surgical risk or whose cholecystectomy is deferred, thus avoiding the adverse events associated with percutaneous cholecystostomy, such as tube dislodgement and leakage, which occur in up to 20% of cases [1–3]. Endoscopic drainage includes endoscopic transpapillary gallbladder stenting (ETGS) and endoscopic ultrasound-guided transmural gallbladder stenting (EUGS). ETGS provides an effective bridging therapy to elective cholecystectomy in patients who are scheduled for future cholecystectomy, owing to its ability to preserve gallbladder anatomy [4–6], and can also serve as an appropriate treatment option in patients at high surgical risk who require permanent gallbladder drainage but have contraindications to percutaneous cholecystostomy and EUGS [6–12]. Our retrospective study aimed to investigate the biliary event-free rates at 6-month follow-up (intermediate term) and  $>6$  months' follow-up (long term) after ETGS in patients with gallstone-related disease who were at high surgical risk or whose cholecystectomy was deferred.

## Methods

### Study population

Data on all patients with gallstone-related disease who underwent endoscopic gallbladder drainage due to high surgical risk (Charlson Comorbidity Index  $\geq 6$ ) [13] or deferred cholecystectomy at our institute between 2012 and 2021 were reviewed retrospectively. Patients receiving EUGS were excluded. All patients who underwent ETGS throughout the study period were analyzed. We also included patients who received ETGS between 2015 and 2019 (n = 104) and had their short-term results included in a previous publication [8].

All patients underwent endoscopic retrograde cholangiopancreatography (ERCP) for common bile duct (CBD) stone(s) removal as the main indication. The presence of CBD stone(s) was confirmed by one method of diagnostic imaging, including transabdominal ultrasound, computed tomography of the abdomen, and magnetic resonance cholangiopancreatography

prior to ERCP. In those with suspected CBD stone(s) not confirmed by pre-procedural imaging, endoscopic ultrasound was performed to confirm the presence of CBD stone(s) before commencing ERCP.

ETGS was performed in patients with concomitant cholecystitis who were at high risk for surgery or were scheduled for future surgery. During the Covid-19 pandemic with surgical lockdown, we also offered ETGS to those patients who were awaiting surgery and had confirmed CBD stone(s) with and without cholecystitis, in order to prevent additional stone migration from the gallbladder to the cystic duct and CBD. Since 2016, our facility has offered EUGS as a treatment option for patients with acute cholecystitis who are at high surgical risk. The diagnosis of acute cholecystitis was based on the patient's clinical presentation (fever and/or right upper quadrant pain or tenderness) with elevated white blood cell count and was confirmed by imaging findings of acute cholecystitis.

Contraindications to ETGS included septic cholangitis, hemodynamic instability, gallbladder perforation, and uncontrollable coagulopathy.

After ETGS, patients were followed until 30 April 2022. All patient data were censored at the date of last visit or by death or when a cholecystectomy was performed. The study protocol was approved by the Institutional Review Board, Chulalongkorn University (IRB No.322/65).

### Endoscopic transpapillary gallbladder drainage technique

More than 700 ERCPs are performed each year at our center. ETGS was performed within 72 hours after the index time of diagnostic confirmation. All procedures were performed by one of five experienced endoscopists (R.R., P.P., P.A., P.K., W.R.), each of whom had performed 100–200 ERCPs/year. CBD stone removal was performed prior to the ETGS procedure.

ETGS was completed in three steps, including cystic duct cannulation, gallbladder guidewire placement, and gallbladder stent placement, as described in our previous study [8]. Following identification of the cystic duct take-off by balloon-occluded cholangiogram, either a 0.035-inch guidewire (Jagwire; Boston Scientific, Marlborough, Massachusetts, USA) or a 0.025-inch guidewire (angled VisiGlide; Olympus, Tokyo, Japan) was used for cystic duct cannulation under fluoroscopic guidance

with an occlusion balloon located just below the cystic duct take-off. In cases with an unsuccessful attempt, cystic duct cannulation was subsequently performed using a bendable-tip catheter such as Ultratome XL (Boston Scientific) or a Swing Tip cannula (Olympus) with a 0.025-inch guidewire (angled Visi-Glide). Since 2015, direct single-operator peroral cholangioscopy (SOC; SpyGlass DS Direct Visualization System; Boston Scientific) has been available at our institute and was subsequently performed to facilitate cystic duct cannulation in cases of unsuccessful cystic duct cannulation within 10 minutes under fluoroscopy, as previously described [8]. After successful gallbladder guidewire placement, a 7-Fr, 15-cm, double-pigtail plastic stent was inserted over the guidewire into the gallbladder.

Technical success was defined as successful stent placement in the desired location as determined endoscopically and radiographically. Clinical success was defined as the resolution of symptoms and laboratory findings within 72 hours after ETGS. Biliary event-free rate was defined as having no cholecystitis and cholangitis related to gallstones or gallbladder stents occurring after ETGS. Procedure-related adverse events were reviewed according to the American Society for Gastrointestinal Endoscopy lexicon [14].

### Post-procedure management and follow-up

Elective cholecystectomy was ultimately performed if patients' clinical status improved. Among patients at high surgical risk, the stent was left in place permanently without scheduled stent exchange, and patients attended outpatient follow-up every 3–6 months. When patients developed recurrent cholecystitis or cholangitis, further management was undertaken at the discretion of the attending physicians, surgeons, and endoscopists.

### Statistical analysis

Categorical variables were described by numbers and percentages. Continuous variables were reported by mean and SD or median and range. We calculated time to event using the Kaplan–Meier product limit method and used this to derive event-free probabilities and 95%CI at 6, 12, and 24 months after the procedure. Statistical analyses were performed using Stata 17.0 (Statacorp LLC, College Station, Texas, USA).

## Results

A total of 234 patients with high surgical risk (n = 50) or cholecystectomy deferral (n = 184) underwent ETGS (► **Table 1**, ► **Fig. 1**). The overall technical success rate of ETGS was 84.6%

► **Table 1** Baseline characteristics and post-procedure outcomes of patients undergoing endoscopic transpapillary gallbladder stenting (n = 234).

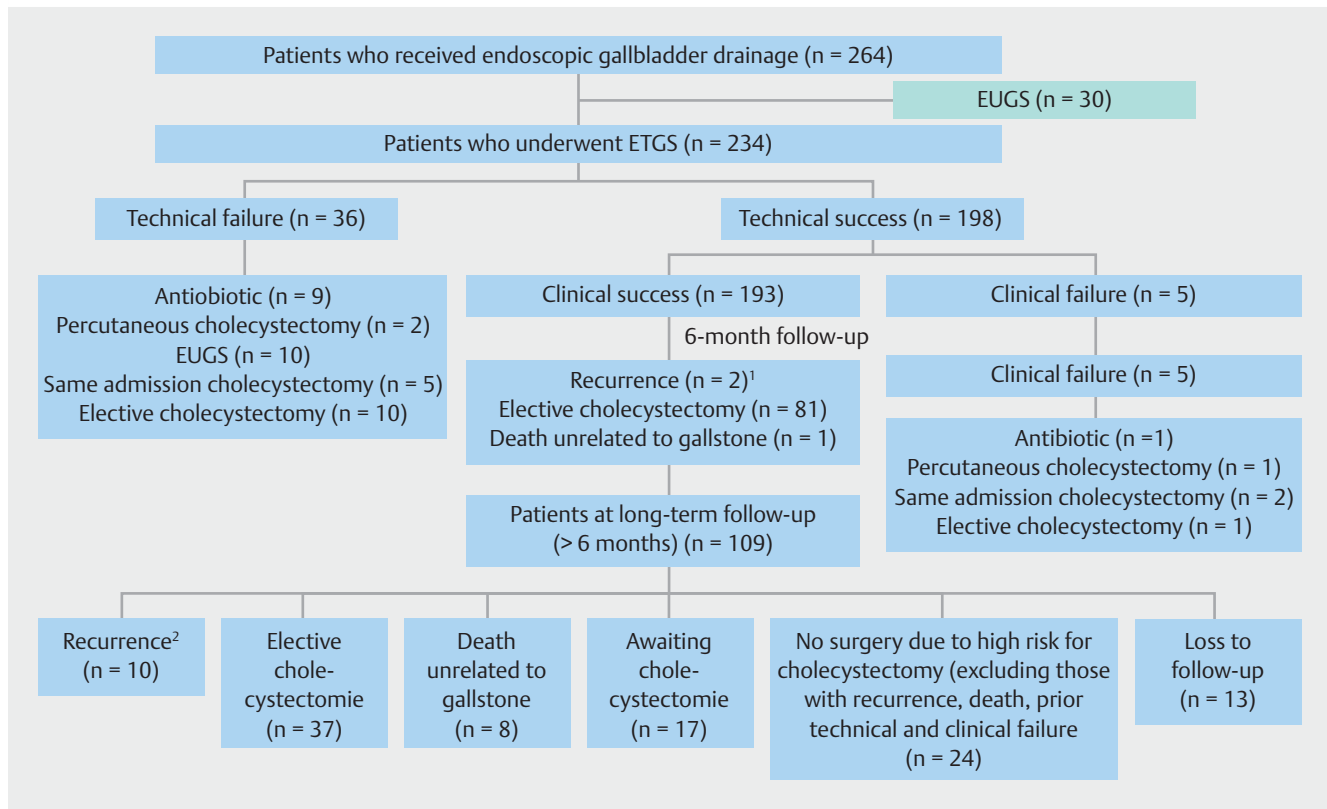
Characters	Patients (n)
Age, mean (SD), years	66.6 (17.4)
Male, n (%)	126 (53.8)
Charlson Comorbidity Index, mean (range)	3 (1–11)

► **Table 1** (Continuation)

Characters	Patients (n)
Reasons for ERCP, n (%)	
<ul style="list-style-type: none"> <li>Common bile duct stone on diagnostic imaging with acute cholecystitis</li> </ul>	147 (62.8)*
<ul style="list-style-type: none"> <li>Common bile duct stone on diagnostic imaging with multiple gallbladder stones</li> </ul>	87 (37.2)*
Endoscopic findings, n (%)	
<ul style="list-style-type: none"> <li>Native papilla</li> </ul>	221 (94.4)
<ul style="list-style-type: none"> <li>Common bile duct stone</li> </ul>	144 (61.5)
Technical success rate, n (%)	
<ul style="list-style-type: none"> <li>Fluoroscopy guidance, n (%)</li> </ul>	148 (64.2)
<ul style="list-style-type: none"> <li>Additional cholangioscopic guidance, n (%)</li> </ul>	198 (84.6)
ETGS failure, n (%)	
Reasons for ETGS failure, n (%)	
<ul style="list-style-type: none"> <li>Failed cystic duct cannulation</li> </ul>	16 (6.8)
<ul style="list-style-type: none"> <li>– Small cystic duct orifice</li> </ul>	6
<ul style="list-style-type: none"> <li>– Edematous cystic duct orifice</li> </ul>	2
<ul style="list-style-type: none"> <li>– Posterior cystic duct take-off</li> </ul>	5
<ul style="list-style-type: none"> <li>– Failure to identified cystic duct</li> </ul>	2
<ul style="list-style-type: none"> <li>– Aberrant cystic duct take-off at right intrahepatic duct</li> </ul>	1
<ul style="list-style-type: none"> <li>Failed guidewire placement in the gallbladder</li> </ul>	14 (6.0)
<ul style="list-style-type: none"> <li>– Blocking cystic duct stone</li> </ul>	5
<ul style="list-style-type: none"> <li>– Acute angle of cystic duct</li> </ul>	3
<ul style="list-style-type: none"> <li>– Tortuous cystic duct</li> </ul>	6
<ul style="list-style-type: none"> <li>Failed stent placement into the gallbladder</li> </ul>	6 (2.6)
<ul style="list-style-type: none"> <li>– Very small cystic duct diameter relative to stent diameter</li> </ul>	6
Clinical success rate, n/N (%)	
193/198 (97.4)	
Procedural time, mean (SD), minutes	
42.8 (26.7)	
Procedure-related adverse events, n (%)	
36 (15.4)	
<ul style="list-style-type: none"> <li>Transient hypoxemia (oxygen saturation &lt;95%)</li> </ul>	12 (5.1)
<ul style="list-style-type: none"> <li>Mild pancreatitis</li> </ul>	12 (5.1)
<ul style="list-style-type: none"> <li>Fever</li> </ul>	4 (1.7)
<ul style="list-style-type: none"> <li>Post-sphincterotomy bleeding</li> </ul>	4 (1.7)
<ul style="list-style-type: none"> <li>Guidewire-related-duct perforation</li> </ul>	4 (1.7)

ERCP, endoscopic retrograde cholangiopancreatography; ETGS, endoscopic transpapillary gallbladder stenting.

\* Diagnostic imaging included transabdominal ultrasound, computed tomography, magnetic resonance cholangiopancreatography or endoscopic ultrasound before the ERCP procedure.



**Fig. 1** Flowchart of patients who received endoscopic transpapillary gallbladder stenting during the study period (n = 234). EUGS, EUS-guided transmural gallbladder stenting; EUS, endoscopic ultrasound; ETGS, endoscopic transpapillary gallbladder stenting. <sup>1</sup>One patient underwent repeat ETGS and the other subsequently received EUGS. <sup>2</sup>Six patients underwent repeat ETGS and four patients received subsequent EUGS.

(198/234). The technical success rate of ETGS was 148/234 (64.1%) under fluoroscopy and increased to 84.6% (198/234) after additional SOC guidance. ETGS was unsuccessful in 15.4% (36/234) (► **Table 1**, **Fig. 1 s** in the online-only Supplementary material). Procedure-related adverse events were noted in 36/234 (15.4%) but none required additional interventions or patient admission to intensive care.

**Intermediate-term outcomes**

At the 6-month follow-up (n = 193), the overall biliary event-free rate was 99% (95%CI 0.95–1.00) (► **Table 2**, ► **Fig. 2**). In the 6-month subgroup analysis of patients with and without acute cholecystitis (n = 193), the biliary event-free rate was 98.3% (95%CI 0.90–0.99) and 100%, respectively (► **Fig. 2**, **Table 1 s**). In patients with acute cholecystitis, recurrent cholangitis occurred in two patients and was due to stent occlusion (n = 1) and stent migration (n = 1), respectively.

**Long-term outcomes**

Based on Kaplan–Meier analysis (n = 193), the overall biliary event-free rate was 92% (95%CI 0.87–0.97) at 1-year follow-up and 76% (95%CI 0.65–0.93) at ≥2-year follow-up, during a median follow-up of 564 days (range 200–3001 days) (► **Table 2**, ► **Fig. 2**).

In a subgroup analysis of patients with and without acute cholecystitis (n = 193), the biliary event-free rate was 91.2% (95

%CI 0.79–0.96) and 94.7% (95%CI 0.80–0.99), respectively, at 1-year follow-up, and 86.2% (95%CI 0.68–0.94) and 94.7% (95%CI 0.80–0.99), respectively, at ≥2-year follow-up (► **Fig. 2**, **Table 1 s**). In those with acute cholecystitis, recurrent cholangitis occurred in three patients due to stent occlusion and recurrent cholecystitis occurred in three patients due to stent migration. In those without acute cholecystitis, recurrent cholangitis occurred in four patients due to stent occlusion (n = 2) and stent migration (n = 2).

**Discussion**

We demonstrated overall biliary event-free rates of 99%, 92%, and 76% in patients with gallstone-related disease after ETGS (n = 193) at 6 months, 1 year, and ≥2 years, respectively, with the overall recurrence rate due to stent migration (n = 5) and stent occlusion (n = 5) being 9.2%. Stent occlusion may be explained by food residue or biliary sludge within a 7-Fr, double-pigtail, plastic stent whereas stent migration could be due to duodenal peristalsis when gallbladder inflammation improves and peristalsis moves food from the duodenum to the jejunum. When subgroup analysis was performed in patients with and without acute cholecystitis (n = 193), their intermediate- and long-term results were comparable. These data indicate that ETGS may be a highly effective treatment for the prevention of recurrent biliary events in the intermediate-to-long term for

► **Table 2** Intermediate- and long-term outcomes of patients undergoing successful endoscopic transpapillary gallbladder stenting (n = 193).

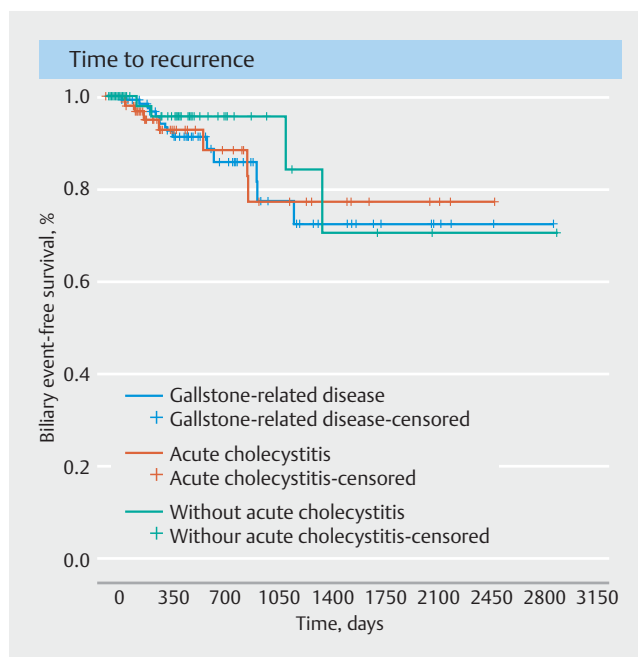
Outcomes	Patients
Intermediate term (at 6-month follow-up)	N = 193
▪ Biliary event-free rate, n (%)	191 (99)
▪ Recurrence, n (%)	2 (1)
– Cholangitis, n	2 <sup>1</sup>
▪ Time to recurrence, median (range), days	118.5 (118–119)
▪ Ultimate cholecystectomy, n (%)	81 (42.0)
▪ Time to cholecystectomy, median (range), days	86 (61–179)
▪ Death unrelated to gallstone	1
Long term (at >6 months' follow-up)	N = 109
▪ Biliary event-free rate, n (%)	99 (90.8)
▪ Recurrence, n (%)	10 (9.2)
– Cholangitis, n	7 <sup>2</sup>
– Cholecystitis, n	3 <sup>3</sup>
▪ Time to recurrence, median (range), days	569 (190–1369)
▪ Time to recurrent cholangitis	569 (190–1369)
▪ Time to recurrent cholecystitis	337 (237–615)
▪ Ultimate cholecystectomy, n (%)	37 (33.9)
▪ Time to cholecystectomy, median (range), days	344 (200–1165)
▪ Death unrelated to gallstone	8
▪ Loss follow-up	13
▪ Follow-up time, median (range), days	564 (200–3001)

<sup>1</sup> One patient required double-pigtail plastic stent exchange and the other received endoscopic retrograde cholangiopancreatography (ERCP) with common bile duct (CBD) stone removal with subsequent successful EUGS.

<sup>2</sup> Of 7 patients with recurrent cholangitis, 1 patient underwent ERCP with successful CBD stone removal with additional EUGS in the same session, 4 patients achieved ERCP with CBD stone removal and received elective cholecystectomy, and 2 patients underwent repeat endoscopic transpapillary gallbladder stenting (ETGS) for stent exchange.

<sup>3</sup> All 3 patients with recurrent cholecystitis underwent successful EUGS.

patients with gallstone-related disease. In previous studies, adverse events, which usually develop within 3 months of the procedure, are highest for percutaneous cholecystostomy compared with ETGS and EUGS (10.8%–17.1% vs. 3.2%–4.6% vs. 1%–4.5%, respectively) [1, 15–17]. Therefore, ETGS should be considered as a viable option for temporary gallbladder drainage in patients with acute cholecystitis and confirmed CBD stone(s) whose surgery cannot be performed in the same admission but who are nonetheless candidates for future cholecystec-



► **Fig. 2** Kaplan–Meier analysis of biliary event-free periods in patients with gallstone-related disease who underwent successful endoscopic transpapillary gallbladder stenting (n = 193) and subgroup analysis in patients with (n = 120) and without (n = 73) acute cholecystitis.

omy. This is because ETGS can preserve gallbladder anatomy without hampering anatomical orientation during the operation. This indication may also include patients with severe cholecystitis and evidence of CBD stone(s) who have previously been considered at high risk for surgery but subsequently improve and become fit for surgery after temporary gallbladder drainage. In patients with CBD and gallbladder stones without acute cholecystitis who may have a long wait for cholecystectomy, especially during Covid-19 surgical lockdown, ETGS during ERCP for CBD stone removal is an interesting option to consider.

In a retrospective US study by Storm et al., recurrent cholecystitis occurred in 2 of 18 patients with a single stent placement [12]; no recurrence was noted in patients with double stent placement (n = 31). However, recurrence was reported in 4.8% with acute cholecystitis with double gallbladder stents (6–7 Fr) in a retrospective study by Sobani et al. (n = 21) [18]. Based on these findings, ETGS with placement of a 7-Fr, double-pigtail, plastic stent is effective at preventing recurrent biliary events in the intermediate-to-long term for these patients. Double stenting may be considered only when the cystic duct diameter is large enough for stent placement. We found that in six patients in our study, even one 7 Fr stent could not traverse the cystic duct owing to a very small cystic duct diameter, although a guidewire had already been placed in the gallbladder.

Data from our recent publication and the current study demonstrated that the technical success rate of ETGS increased from 53% and 64.1% under fluoroscopy to 75% and 84.6% after additional SOC guidance, respectively [8]. The use of SOC was

helpful in cystic duct cannulation during ETGS, particularly in patients with posteromedial cystic duct take-off that could not be identified under fluoroscopy and in those patients who had no contrast in the cystic duct on balloon-occluded cholangiogram [8]. Our data showed a relatively lower technical success rate of ETGS under fluoroscopy compared with other studies [6, 19], as we adopted a lower threshold for the use of SOC to identify the cystic duct, and bypassed the use of additional devices (apart from occlusion balloon and bendable catheter) for cholangiography-guided cystic duct access described elsewhere [6, 19].

We observed a lower rate of guidewire-related duct perforation ( $n = 4$ ; 1.7%) compared with the Nakahara et al. study (9.2%) [20]. Fortunately, all were treated conservatively. Tortuosity and an acute angle of the cystic duct in all four patients may have precluded passage of the sharp tip of a 0.025-inch guidewire (angled VisiGlide; Olympus), resulting in cystic duct injury. Therefore, in cases of difficult cystic duct anatomy, gentle manipulation and using only a soft-tip hydrophilic guidewire should be preferred.

The main limitation of our study was the design, which was retrospective and lacked a control group. Second, the number of patients who underwent a cholecystectomy influenced the length of the follow-up. However, after excluding 81 patients who underwent cholecystectomy, 109 patients remained and were followed for more than 6 months. Third, as each patient was not regularly scheduled for a routine plain X-ray during long-term follow-up, asymptomatic patients with stent migration could have been missed. Finally, our study used retrospective data from a single center and included a large number of patients and a high success rate for gallbladder stent placement. However, we used a cholangioscope to facilitate cystic duct cannulation after failed cholangiographic guidance and this protocol may not be generalizable due to the limited availability of this device. Furthermore, our research fund supported the use of the SOC guidance protocol, and therefore we considered SOC as an alternative approach in patients who had undergone failed ETGS under fluoroscopy. However, the cost-effectiveness of this protocol is debatable, and thus, a cost-effectiveness analysis of ETGS with additional SOC within a multicenter study is required to demonstrate the economic utility of SOC for ETGS.

In conclusion, ETGS should be considered as a possible option in selected patients with symptomatic gallbladder disease who have CBD stone(s). Our study demonstrated a biliary event-free rate of 99% at 6 months, 92% at 1 year, and 76% at  $\geq 2$  years. Further evaluations are needed to determine the proper strategies of ETGS such as intermediate-term drainage in patients with long waiting times for cholecystectomy ( $> 3$  months) and long-term drainage in patients who are unsuitable for surgery indefinitely.

## Acknowledgments

An earlier version of these data was accepted for oral presentation at the annual meeting of Digestive Diseases Week, 21–24 May 2022, San Diego, California, USA.

## Competing interests

The authors declare that they have no conflict of interest.

## References

- [1] Ridditid W, Luangsukrer T, Piyachaturawat P et al. Ultimate outcomes of three modalities for non-surgical gallbladder drainage in acute cholecystitis with or without concomitant common bile duct stones. *Ann Hepatobiliary Pancreat Surg* 2022; 26: 104–112
- [2] Irani S, Ngamruengphong S, Teoh A et al. Similar efficacies of endoscopic ultrasound gallbladder drainage with a lumen-apposing metal stent versus percutaneous transhepatic gallbladder drainage for acute cholecystitis. *Clin Gastroenterol Hepatol* 2017; 15: 738–745
- [3] Teoh AYB, Kitano M, Itoi T et al. Endosonography-guided gallbladder drainage versus percutaneous cholecystostomy in very high-risk surgical patients with acute cholecystitis: an international randomised multicentre controlled superiority trial (DRAC 1). *Gut* 2020; 69: 1085–1091
- [4] Schlenker C, Trotter JF, Shah RJ et al. Endoscopic gallbladder stent placement for treatment of symptomatic cholelithiasis in patients with end-stage liver disease. *Am J Gastroenterol* 2006; 101: 278–283
- [5] Conway JD, Russo MW, Shrestha R. Endoscopic stent insertion into the gallbladder for symptomatic gallbladder disease in patients with end-stage liver disease. *Gastrointest Endosc* 2005; 61: 32–36
- [6] Lee TH, Park DH, Lee SS et al. Outcomes of endoscopic transpapillary gallbladder stenting for symptomatic gallbladder diseases: a multicenter prospective follow-up study. *Endoscopy* 2011; 43: 702–708
- [7] McCarthy ST, Tujios S, Fontana RJ et al. Endoscopic transpapillary gallbladder stent placement is safe and effective in high-risk patients without cirrhosis. *Dig Dis Sci* 2015; 60: 2516–2522
- [8] Ridditid W, Piyachaturawat P, Teeratorn N et al. Single-operator peroral cholangioscopy cystic duct cannulation for transpapillary gallbladder stent placement in patients with acute cholecystitis at moderate to high surgical risk (with videos). *Gastrointest Endosc* 2020; 92: 634–644
- [9] Inoue T, Okumura F, Kachi K et al. Long-term outcomes of endoscopic gallbladder stenting in high-risk surgical patients with calculous cholecystitis (with videos). *Gastrointest Endosc* 2016; 83: 905–913
- [10] Kaura K, Bazerbachi F, Sawas T et al. Surgical outcomes of ERCP-guided transpapillary gallbladder drainage versus percutaneous cholecystostomy as bridging therapies for acute cholecystitis followed by interval cholecystectomy. *HPB (Oxford)* 2020; 22: 996–1003
- [11] Yoshida M, Naitoh I, Hayashi K et al. Four-step classification of endoscopic transpapillary gallbladder drainage and the practical efficacy of cholangioscopic assistance. *Gut Liver* 2021; 15: 476–485
- [12] Storm AC, Vargas EJ, Chin JY et al. Transpapillary gallbladder stent placement for long-term therapy of acute cholecystitis. *Gastrointest Endosc* 2021; 94: 742–748
- [13] Charlson ME, Pompei P, Ales KL et al. A new method of classifying prognostic comorbidity in longitudinal studies: development and validation. *J Chronic Dis* 1987; 40: 373–383
- [14] Cotton PB, Eisen GM, Aabakken L et al. A lexicon for endoscopic adverse events: report of an ASGE workshop. *Gastrointest Endosc* 2010; 71: 446–454
- [15] Mohan BP, Khan SR, Trakroo S et al. Endoscopic ultrasound-guided gallbladder drainage, transpapillary drainage, or percutaneous drainage in high risk acute cholecystitis patients: a systematic review and comparative meta-analysis. *Endoscopy* 2020; 52: 96–106

- [16] Siddiqui A, Kunda R, Tyberg A et al. Three-way comparative study of endoscopic ultrasound-guided transmural gallbladder drainage using lumen-apposing metal stents versus endoscopic transpapillary drainage versus percutaneous cholecystostomy for gallbladder drainage in high-risk surgical patients with acute cholecystitis: clinical outcomes and success in an international, multicenter study. *Surg Endosc* 2019; 33: 1260–1270
- [17] Podboy A, Yuan J, Stave CD et al. Comparison of EUS-guided endoscopic transpapillary and percutaneous gallbladder drainage for acute cholecystitis: a systematic review with network meta-analysis. *Gastrointest Endosc* 2021; 93: 797–804
- [18] Sobani ZA, Sanchez-Luna SA, Rustagi T. Endoscopic transpapillary gallbladder drainage for acute cholecystitis using two gallbladder stents (dual gallbladder stenting). *Clin Endosc* 2021; 54: 899–902
- [19] Maekawa S, Nomura R, Murase T et al. Endoscopic gallbladder stenting for acute cholecystitis: a retrospective study of 46 elderly patients aged 65 years or older. *BMC Gastroenterol* 2013; 13: 65
- [20] Nakahara K, Sato J, Morita R et al. Incidence and management of cystic duct perforation during endoscopic transpapillary gallbladder drainage for acute cholecystitis. *Dig Endosc* 2022; 34: 207–214