

# Outcomes of patients with hepaticojejunostomy anastomotic strictures undergoing endoscopic and percutaneous treatment



## Authors

Kevin Kyung Ho Choi<sup>1,2</sup>, Mark Bonnicksen<sup>1</sup>, Ken Liu<sup>1,2</sup>, Saniya Massey<sup>2</sup>, Dominic Staudenmann<sup>1</sup>, Payal Saxena<sup>1,2</sup>, Arthur John Kaffes<sup>1,2</sup>

## Institutions

- 1 AW Morrow Gastroenterology and Liver Centre, Royal Prince Alfred Hospital, Sydney, Australia
- 2 Sydney Medical School, University of Sydney, Sydney, Australia

submitted 7.6.2022

accepted after revision 20.9.2022

published online 28.9.2022

## Bibliography

Endosc Int Open 2023; 11: E24–E31

DOI 10.1055/a-1952-2135

ISSN 2364-3722

© 2022. The Author(s).

This is an open access article published by Thieme under the terms of the Creative Commons Attribution-NonDerivative-NonCommercial License, permitting copying and reproduction so long as the original work is given appropriate credit. Contents may not be used for commercial purposes, or adapted, remixed, transformed or built upon. (<https://creativecommons.org/licenses/by-nc-nd/4.0/>)

Georg Thieme Verlag KG, Rüdigerstraße 14,  
70469 Stuttgart, Germany

## Corresponding author

Professor Arthur John Kaffes, AW Morrow Gastroenterology and Liver Centre, Royal Prince Alfred Hospital, Missenden Road, Camperdown, NSW, 2050, Australia  
Fax: +95160778  
[arthur@kaffes.com](mailto:arthur@kaffes.com)

## ABSTRACT

**Background and study aims** The increase in hepaticojejunostomies has led to an increase in benign strictures of the anastomosis. Double balloon enteroscopy-assisted ERCP (DBE-ERCP) and percutaneous transhepatic biliary drainage (PTBD) are treatment options; however, there is lack of long-term outcomes, with no consensus on management. We performed a retrospective study assessing the outcomes of patients referred for endoscopic management of hepaticojejunostomy anastomotic strictures (HJAS).

**Patients and methods** All consecutive patients at a tertiary institution underwent endoscopic intervention for suspected HJAS between 2009 and 2021 were enrolled.

**Results** Eighty-two subjects underwent DBE-ERCP for suspected HJAS. The technical success rate was 77% (63/82). HJAS was confirmed in 41 patients. The clinical success rate for DBE-ERCP ± PTBD was 71% (29/41). DBE-ERCP alone achieved clinical success in 49% of patients (20/41). PTBD was required in 49% (20/41). Dual therapy was required in 22% (9/41). Those with liver transplant had less technical success compared to other surgeries (72.1% vs 82.1%  $P=0.29$ ), less clinical success with DBE-ERCP alone (40% vs 62.5%  $P=0.16$ ) and required more PTBD (56% vs 37.5%  $P=0.25$ ). All those with ischemic biliopathy ( $n=9$ ) required PTBD for clinical success, required more DBE-ERCP (4.4 vs 2.0,  $P=0.004$ ), more PTBD (4.7 vs 0.3,  $P<0.0001$ ), longer treatment duration (181.6 vs 99.5 days  $P=0.12$ ), and had higher rates of recurrence (55.6% vs 30.3%  $P=0.18$ ) compared to those with HJAS alone. Liver transplant was the leading cause of ischemic biliopathy (89%). The overall adverse event rate was 7%.

**Conclusions** DBE-ERCP is an effective diagnostic and therapeutic tool in those with altered gastrointestinal anatomy and is associated with low complication rates.

## Introduction

Hepaticojejunostomy is a surgical technique used to preserve the anatomical tract after surgical resection of the hepatobiliary system. As the procedure has become more common, bili-

ary stricture management in patients with hepaticojejunostomy anastomotic stricture (HJAS) has presented a complex management issue. HJAS is a long-term complication that is estimated to occur in 3% to 13% of patients developing at a

median of 2 to 4 years post-procedure and can lead to recurrent cholangitis, jaundice, and stone formation [1, 2].

Percutaneous transhepatic cholangiogram-guided biliary drainage (PTBD) and surgical intervention reportedly have a high success rate; however, the technique requires an external drain, which reduces patient mobility. It is also associated with rates of adverse events (AEs) ranging from 11 % to 35 %, including hepatic artery injury, hemorrhage, post-procedure sepsis, liver abscess, and pneumothorax [3–6]. Traditional endoscopic retrograde cholangiopancreatography (ERCP) is limited by lack of access to the anastomosis, given the length of the afferent limb, with low cannulation success rates of 33 % [7].

Double balloon enteroscopy-assisted ERCP (DBE-ERCP) has shown success in visualization of the bile ducts in those with surgically altered anatomy [8–11]. Recent studies [12–17] have shown good efficacy and safety of this technique as a strategy, with clinical success rates reported to be between 50 % and 100 %. DBE-ERCP presents a reasonable alternative to PTBD to address HJAS but the long-term outcomes and optimal management strategy are not well elucidated. The aim of this retrospective study in a high-volume referral center was to assess the outcomes of HJAS management.

## Patients and methods

### Patients

We performed a retrospective single-center study of consecutive patients who underwent DBE-ERCP for management of HJAS between February 2009 and August 2021 at Royal Prince Alfred Hospital, a quaternary referral liver transplant university hospital. Ethics approval was granted via the Sydney Local Health District ethics committee (X19–0423 & 2019/ETH12850). All patients aged >18 who underwent DBE-ERCP for suspected HJAS were included. Patients referred with a suspected HJAS had deranged liver function tests (LFTs) (bilirubin, alkaline phosphatase, gamma glutamyltransferase at least 1.5 x above upper limit of normal in at least 2 markers) and one or more of the following: fever (temperature >37.5 °C), imaging (computed tomography [CT] cholangiogram or magnetic resonance cholangiopancreatography) consistent with a HJAS, and abdominal pain. Patients were excluded if there was no hepaticojejunostomy (i.e Roux-en-Y bypass), no definitive diagnosis of a HJAS was made or ischemic biliopathy was present without HJAS.

### Endoscopic procedure

DBE-ERCP was performed with the Fujinon therapeutic long double balloon enteroscope (Fujinon Corp., Saitama, Japan) with the following components: EN-450T5/20 video enteroscope (3.2-mm channel, 200-cm working length, and 8.5-mm external diameter), 400 (VP- 402, XL 402) processor and a TS-12140 overtube (140-cm length and 12-mm external diameter), two latex balloons (one each at the distal end of the enteroscope and the overtube), and a PB-10 balloon controller (pressure-controlled pump) with the method described previously [8, 12].

Once the hepaticojejunostomy anastomosis was reached, a cannulation catheter (4.5F or 5.5F tapered 320-cm cannula, Cook Medical, Bloomington, Indiana, United States) with a 480-cm or 600-cm 0.35 tracer wire was used to cannulate the bile duct. This was followed by the insertion of a balloon dilatation catheter (4 to 6 mm, 6 to 8 mm, Boston Scientific, Natick, Massachusetts, United States) across the stricture and a dilatation was performed with the size of balloon corresponding to the bile duct width above the anastomosis. The balloon was inflated for 30 to 60 seconds to ensure complete dilatation. Upon endoscopic assessment of successful dilatation of the HJAS and confirmation of adequate contrast material flow into the jejunum, the procedure was determined to be complete. The benign HJAS was endoscopically treated with a single balloon dilatation alone or in combination with deployment of a single plastic stent (3F, 5F, 7F), depending on the severity of the stricture at endoscopist discretion. All patients received prophylactic intra-procedural antibiotics. All procedures were performed by two experienced endoscopists (AJK, PS) with more than 10 years of DBE-ERCP experience. Patients in whom dilation was successful were monitored for symptoms and blood tests in an outpatient clinic between 1 to 6 months for the first year, then annually thereafter. If stents were placed, repeat DBE-ERCP was performed every 2 to 4 months until resolution of stricture.

PTBD was performed in the Interventional Radiology department. After achieving biliary access, the HJAS and intrahepatic strictures (referred to as ischemic biliopathy) were treated with a combination of plastic stents, balloon dilatation and drain upsizing.

### Study definitions

HJAS was defined endoscopically by a stenosis at the anastomotic site without surrounding irregular mucosa and/or narrowing at the hepaticojejunostomy on cholangiogram with relative upstream dilatation of the bile duct. Ischemic biliopathy was defined as intrahepatic biliary strictures seen on cholangiogram or imaging (CT or magnetic resonance imaging [MRI]).

Treatment duration was defined from the first attempted DBE-ERCP to the final procedure (DBE-ERCP or PTBD) with stent/drain removal or dilatation. Technical success was defined as reaching the HJ anastomosis. Clinical success was defined as complete resolution of stricture determined by improvement of clinical symptoms and laboratory results at follow-up visits (normalization of cholestatic LFTs or >50 % reduction). Treatment failure was defined as patients needing to undergo surgery to resolve cholestasis. Follow-up was defined as time from the day of first procedure to the last follow-up date. This was confirmed by electronic medical records or calling the patient if there was no recorded follow-up within the past 6 months. Recurrence was defined as elevated liver enzymes with or without cholangitis, with imaging showing bile duct dilatation leading to intervention.

AEs were classified in relation to scope insertion or ERCP (early ≤7 days or late >7 days) and recorded in accordance with the American Society of Gastrointestinal Lexicon for endoscopic AEs [18].

## Statistical analysis

Continuous variables were expressed in median (interquartile range [IQR]) or mean (range) as appropriate. Differences between subgroups were analyzed using chi square test for categorical parameters and t test and Kruskal-Wallis test or ANOVA for parametric and non-parametric data. Statistical analysis was performed by Statistical Package for Social Science (SPSS version 22.0, Armonk, New York, United States). A result was considered statistically significant if  $P < 0.05$ . Kaplan-Meier curves were used to estimate the probability of recurrence.

## Results

### Demographics

A total of 82 patients were referred to our center with suspected HJAS. Forty-one patients were confirmed to have a HJAS, of which 65.9% were male. The mean age was 49 years (range 20 to 80). Liver transplant was the most common cause of hepaticojejunostomy (61%), followed by bile duct injury (22%), Whipple surgery (7%), choledochal cyst (5%), and recurrent pyogenic cholangitis (5%). Mean follow-up duration was 3.2 years (► **Table 1**).

### Interventions

DBE-ERCP alone achieved clinical success in 20 patients, 13 of whom had stents with or without dilatation and seven of whom had dilatation alone. Dual therapy with DBE-ERCP and PTBD were required in nine patients. Due to failure with DBE-ERCP, PTBD alone achieved clinical success in 11 patients. Across all patients there was a mean of 3.3 (range 1 to 9) DBE-ERCPs and 2.9 PTBDs (range 0 to 14).

### Patient flow and stricture management

A total of 82 subjects were referred for treatment of a suspected HJAS (► **Fig. 1**). Failure to reach the hepaticojejunostomy occurred in 23% (19/82). The hepaticojejunostomy was reached in 77% (63/82) and HJAS was confirmed in 56% (35/63) with DBE-ERCP (► **Fig. 2**). An additional five cases of HJAS were managed with PTBD after DBE failed (► **Fig. 3**) and one patient was managed conservatively, making a total of 41 patients with HJAS studied. In the 28 cases in which the hepaticojejunostomy was reached but did not reveal a HJAS, the pathology patent hepaticojejunostomy with reflux cholangitis 64% (18/28), ischemic biliopathy 14% (4/28), choledocholithiasis 11% (3/28), and suture material 11% (3/28).

Of the 41 patients with confirmed HJAS, DBE-ERCP alone had an overall clinical success rate of 49% (20/41). Overall, PTBD was required in 49% of patients (20/41) and conservative management was pursued in one patient. Dual therapy was required in 22% (9/41). The clinical success rate in those who had DBE-ERCP with or without PTBD was 71% (29/41). There was no treatment failure in those with a confirmed HJAS.

There were two groups of patients identified within our cohort. HJAS alone was present in 32 patients and nine patients had combined HJAS and ischemic biliopathy strictures. The overall recurrence rate in all those with HJAS was 36.6% (15/41).

► **Table 1** DBE-ERCP ± PTBD patient characteristics.

Total number of patients	41
Sex	
▪ Male	27
▪ Female	14
Mean Age (Range)	49 (20–80)
Indication for hepaticojejunostomy surgery	
▪ Liver transplant	25 (61%)
▪ Bile duct injury	9 (22%)
▪ Whipple's procedure	3 (7%)
▪ Choledochal cyst	2 (5%)
▪ Recurrent pyogenic cholangitis	2 (5%)
Mean time (range) to stricture formation (years)	3.6 (0.1–20.1)
Mean number of DBE-ERCP (range)	3.3 (1–9)
Mean number of PTBD (range)	2.9 (0–14)
Mean follow-up in years (range)	3.2 (0.1–11.6)
Complications related to DBE-ERCP	3
DBE-ERCP, double balloon enteroscopy assisted endoscopic retrograde cholangiopancreatography; HJAS, hepaticojejunostomy anastomotic stricture; PTBD, percutaneous transhepatic biliary drainage.	

### Results according to liver transplant or non-liver transplant

#### Liver transplant (n = 43) vs. other surgery (n = 39) in those with suspected HJAS

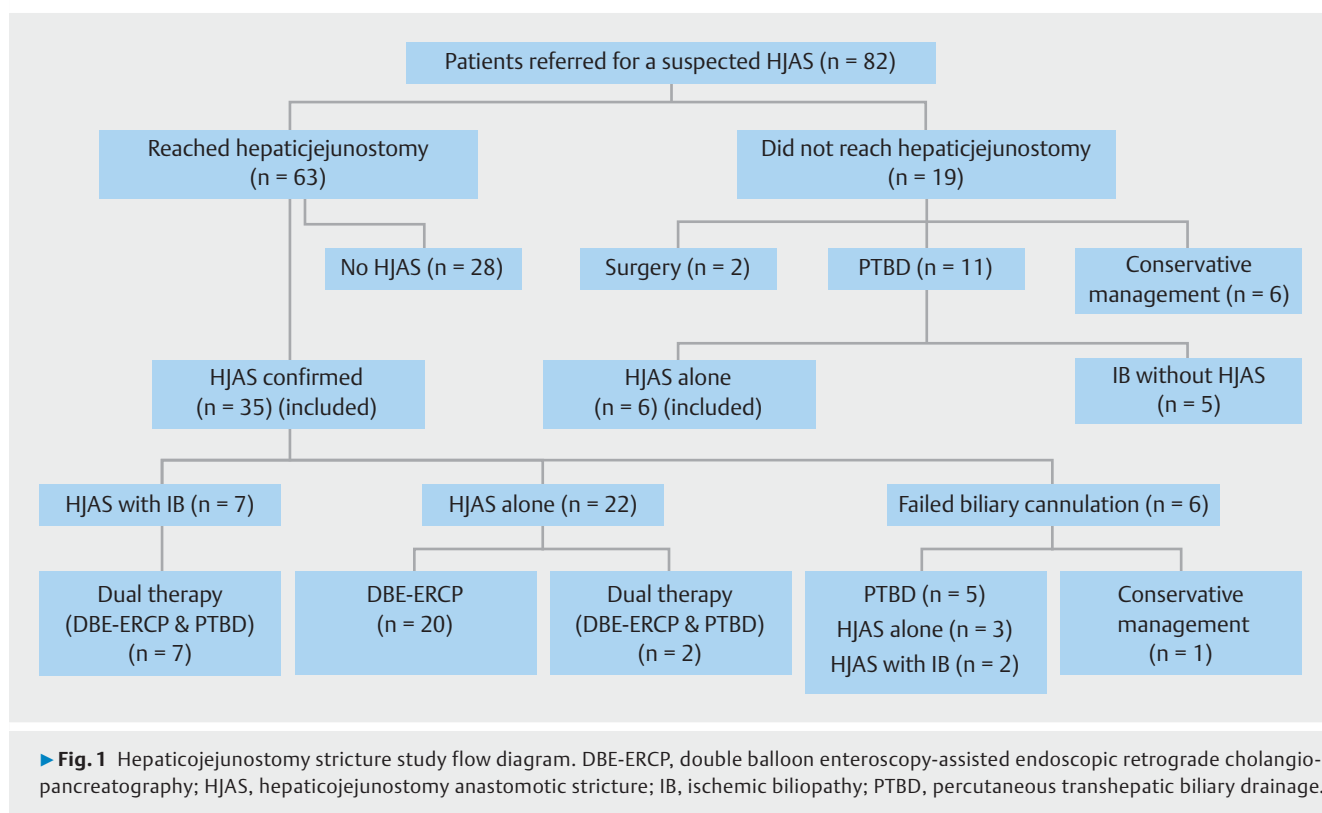
Those with liver transplants had a lower technical success rate (72.1% vs. 82.1%,  $P = 0.29$ ), required more PTBD (56% vs. 37.5%,  $P = 0.25$ ), and had less clinical success with DBE-ERCP alone (40% vs. 62.5%,  $P = 0.16$ ) (► **Table 2**). Recurrence rates were similar across both groups in those with confirmed HJAS (39.1% vs. 37.5%,  $P = 0.40$ ) (► **Table 3**).

#### Liver transplant group with confirmed HJAS (n = 25)

Of the 41 patients who had a confirmed HJAS, liver transplant was the most common indication for hepaticojejunostomy, occurring in 61% (25/41). PTBD was required in 56% (14/25) of those with liver transplant-related hepaticojejunostomy. Furthermore, 88.9% (8/9) of those with combined pathology of HJAS and ischemic biliopathy had a prior liver transplant (► **Fig. 4**).

### Results according to presence or absence of ischemic biliopathy

**HJAS alone** In those with a simple HJAS alone without ischemic biliopathy, DBE-ERCP alone achieved clinical success in 69% (20/29). If the hepaticojejunostomy was reached and endoscopic therapy with DBE-ERCP was successfully performed at time of reaching, the rate of clinical success with DBE-ERCP alone was 90.5% (20/22). In those who were initially treated



with DBE-ERCP, seven patients were successfully treated with dilatation alone, 13 required stenting (mean of 2 stents per patients, range 1 to 8) with or without dilatation, and two required PTBD in this group. There was a mean of 2.1 (range 3 to 7) DBE-ERCPs and 0.1 PTBDs (range 0 to 1) per patient.

### Combined HJAS and ischemic biliopathy

There were nine patients with combined HJAS and ischemic biliopathy. DBE-ERCP was initially successful in seven subjects, whereas two underwent rescue PTBD because DBE-ERCP therapy was unsuccessful. All nine patients with ischemic biliopathy required PTBD for clinical success. There was a mean of 4.4 DBE-ERCPs and 4.7 PTBDs per patient.

### HJAS alone (n = 30) vs. combined HJAS and Ischemic biliopathy (n = 9)

Those with combined HJAS and ischemic biliopathy required more DBE-ERCP (mean 4.4 vs 2.1,  $P=0.004$ ), PTBD (4.7 vs 0.1,  $P<0.0001$ ) and longer treatment duration (181.6 vs 99.5,  $P=0.12$ ). Ischemic biliopathy was seen more commonly in those with liver transplants, 89% vs 53% ( $P=0.05$ ). Recurrence rates in those with ischemic biliopathy were higher (55.6% vs 33.3%,  $P=0.23$ ) (► **Table 2**). Kaplan-Meier curves showed an increased cumulative incidence of recurrence (Log rank  $P=0.002$ ) in those with HJAS with ischemic biliopathy (► **Fig. 5**).

### Adverse events

In those with confirmed HJAS who had DBE-ERCP, the overall AE rate was 7% (3/41), which led to procedural intervention or resulted in death. There was a perforation that required operative

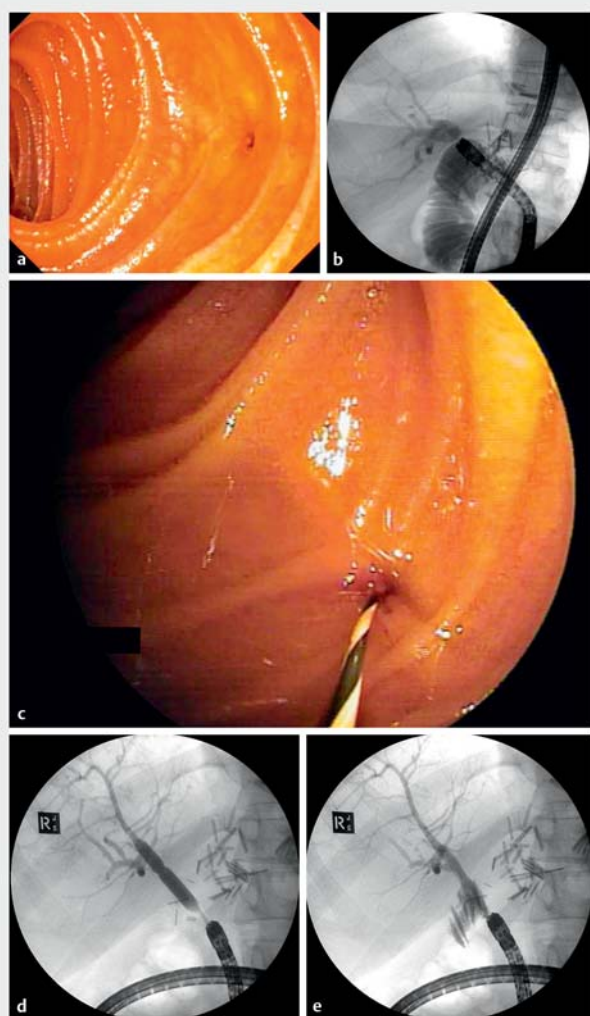
management in a child in the dilatation group who had undergone initial surgery another country. Explant revealed the hepaticojejunostomy site had not been adequately sutured. There was a single unrelated death secondary to sepsis in a patient with acute rejection of a second liver transplant with ischemic biliary strictures that did not respond to DBE-ERCP and PTBD. In one patient, cholangitis developed despite intra-procedure antibiotics and was managed conservatively with oral antibiotics on an outpatient basis.

## Discussion

HJAS development is an increasingly common and complex clinical problem [19, 20]. PTBD is thought to be the gold standard for biliary drainage when conventional ERCP is unable to reach the biliary anastomosis [21–24]. Recent data have shown that DBE-ERCP is a reasonable alternative to PTBD, with clinical success rates reported between 50% to 100% [12, 13, 15–17].

There is only one small case series of predominantly liver transplant patients from Japan, which reported a technical success rate of 85%, clinical success rates of DBE-ERCP in combination with PTBD of 70%, and clinical success with DBE-ERCP alone of 55% [14]. Our study reports the use of DBE-ERCP in those with suspected HJAS in a larger Western population and shows a technical success rate of 77%. All patients who achieved technical success received a diagnosis and/or therapy. Importantly, DBE-ERCP ruled out HJAS and negated the need for PTBD in one-third of the cohort. Thus, DBE-ERCP is a powerful therapeutic and minimally invasive diagnostic tool. DBE-ERCP failed to achieve diagnosis or therapy in 23% and subsequently



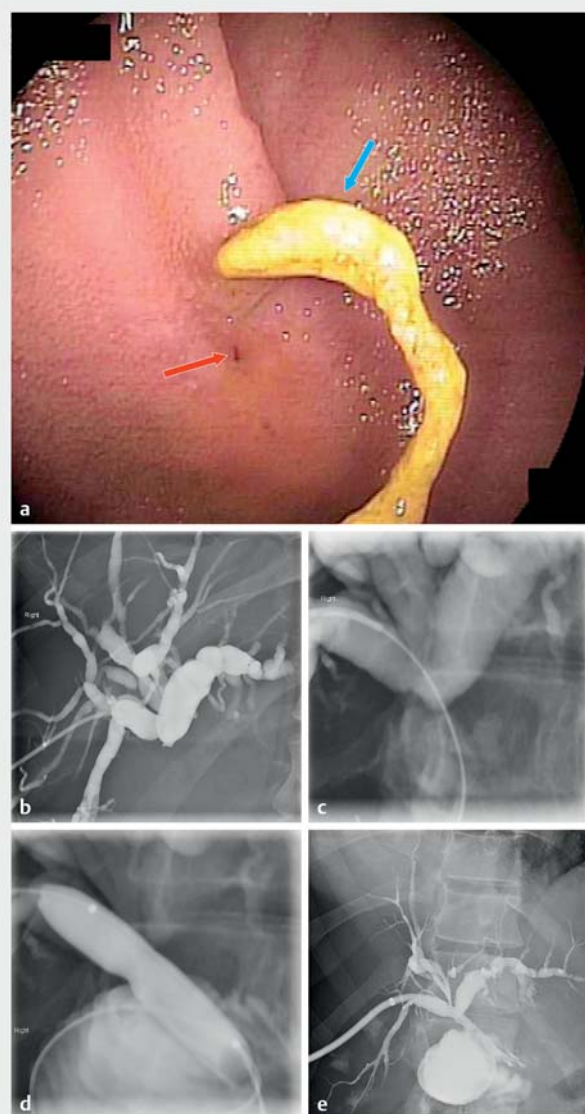


► **Fig. 2** Endoscopic and radiographic images of endoscopic treatment of Patient A during a single session. **a** Endoscopic view of the hepaticojejunostomy anastomotic stricture (HJAS). **b** Double balloon enteroscope-assisted cholangiogram showing dilated intrahepatic ducts with contrast hold up. **c** Wire-guided cannulation through HJAS. **d** DBE-ERCP balloon dilatation across HJAS with visible waisting. **e** Successful drainage of contrast post-dilatation.

required PTBD (58%, 11/19), conservative management (32%, 6/19) or surgery (10%, 2/19). This is in keeping with data from our previous DBE-ERCP experience, which showed that those with re-do Roux-en-Y surgery and liver transplants have failure rates of 54% and 36%, respectively [8].

DBE-ERCP alone led to clinical success in 49% of all those with confirmed HJAS, and DBE-ERCP and PTBD combined had a clinical success rate of 71%. Clinical success rates are reported between 55% and 100%. However, all the data were retrospective, involved heterogeneous populations, and were from a predominantly Southeast Asian cohort [12 to 17].

The highest clinical success rate of 95.7%, which was reported by a large retrospective study in Japan of 139 subjects, involved a small liver transplant cohort of 7% compared to our



► **Fig. 3** Endoscopic and radiographic images of Patient B requiring percutaneous transhepatic biliary drainage (PTBD). **a** Endoscopic view of hepaticojejunostomy anastomotic stricture (red arrow) with adjacent remnant suture string covered with debris/sludge (blue arrow). The wire could not be advanced through the HJAS endoscopically and the patient was referred for PTBD. **b** Percutaneous transhepatic cholangiogram (PTC) showing dilated intrahepatic ducts with no flow of contrast into the small bowel. **c** Wire traversed through HJAS into small bowel shown on PTC. **d** Percutaneous transhepatic balloon dilatation with waisting visible across the HJAS. **e** Successful biliary drainage with contrast flowing through the hepaticojejunostomy into the small bowel.

61%. In addition, a more maneuverable short-DBE was utilized, and the cohort consisted of a Southeast Asian population [15]. Thus, our lower clinical success rates are explained by our predominant liver transplant cohort, a Western population, and the technically challenging use of a long DBE system.

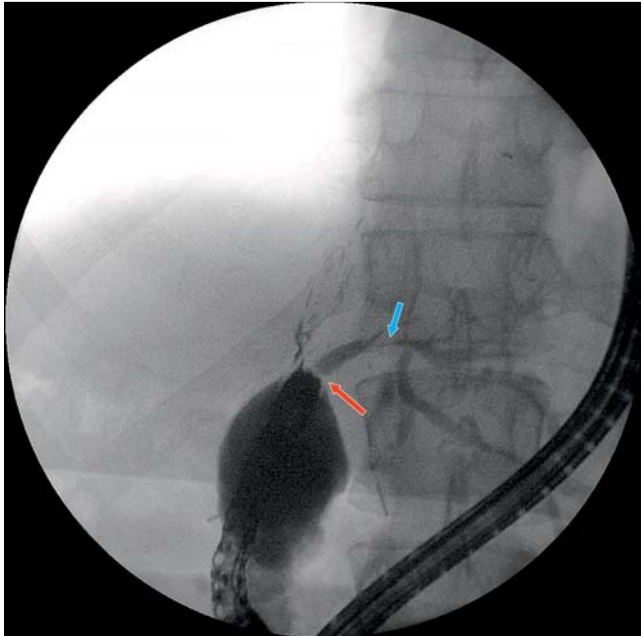
From our experience, the liver transplant population is more challenging to treat. There was a trend toward lower rates of

► **Table 2** Technical success, need for PTBD and ability to achieve clinical success with DBE-ERCP in those with liver transplant vs. other surgeries.

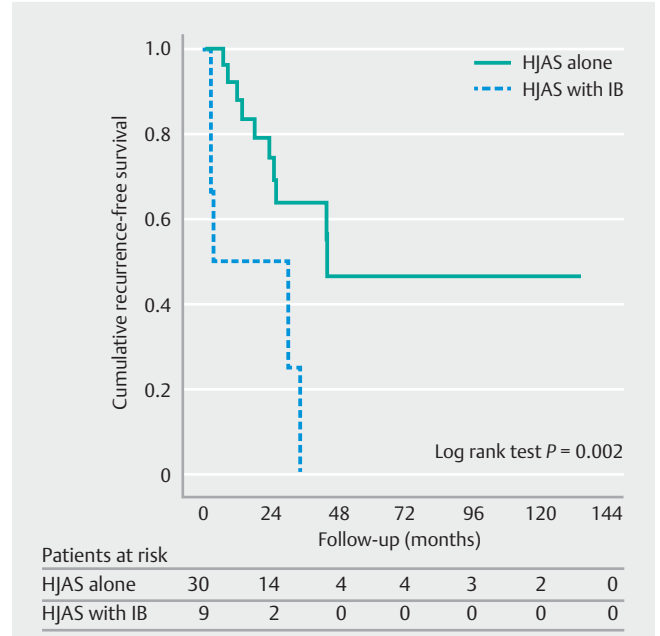
	Liver transplant	Other surgery
Overall technical success (all patients referred for suspected HJAS)	72.1 % (31/43)	82.1 % (32/39) <i>P</i> = 0.29
Need for PTBD in confirmed HJAS with or without ischemic biliopathy	56 % (14/25)	37.5 % (6/16) <i>P</i> = 0.25
Clinical success with DBE-ERCP alone in confirmed HJAS with or without ischemic biliopathy	40 % (10/25)	62.5 % (10/16) <i>P</i> = 0.16
DBE-ERCP, double balloon enteroscopy assisted endoscopic retrograde cholangiopancreatography; HJAS, hepaticojejunostomy anastomotic stricture; PTBD, percutaneous transhepatic biliary drainage.		

► **Table 3** HJAS recurrence by liver transplant vs other surgery and presence/absence of ischemic biliopathy.

	Liver transplant	Other surgery	HJAS alone	Combined HJAS and ischemic biliopathy
n	23*	16*	30*	9
Recurrence n	9	6	10	5
Percentage	39.1 % vs <i>P</i> = 0.40	37.5 %	33.3 % <i>P</i> = 0.23	55.6 %
Overall recurrence rate: 38.4 %				
HJAS, hepaticojejunostomy anastomotic stricture. * One subject who had a perforation and one patient who had perforation were excluded from the recurrence analysis.				



► **Fig. 4** A cholangiogram during DBE-ERCP showing a HJAS (red arrow) in combination with ischemic biliopathy (blue arrow).



► **Fig. 5** Kaplan-Meier curves comparing the recurrence rate in those with HJAS alone compared against HJAS with ischemic biliopathy.

technical and clinical success in those with liver transplants compared to other surgeries (72.1 % vs. 82.1 % *P* = 0.29 and 56 % vs. 37.5 % *P* = 0.25, respectively). There was no difference in recurrence rates between the two groups (*P* = 0.40). This is perhaps

due to the nature of orthotopic liver transplants causing adhesions, acute angulations, and fixed looping leading to a challenging procedure. Although *P* values did not reach statistical

significance, we attribute this to the small case numbers. Furthermore, liver transplant is a key risk factor in developing ischemic biliopathy. Of the nine patients with combined HJAS and ischemic biliopathy, 89% were due to a liver transplant. All those with confirmed combined HJAS and ischemic biliopathy required PTBD for clinical success due to difficulty in treating strictures in peripheral ducts. Our results also demonstrated that those with combined HJAS and ischemic biliopathy required more DBE-ERCP, more PTBD, longer treatment duration, and had higher recurrence rates. Thus, patients with combined HJAS and ischemic biliopathy should be referred for PTBD for management of their HJAS and intrahepatic strictures. During PTBD, if the decision is made to proceed with stent placement, only biodegradable stents should be deployed because of poor accessibility of the hepaticojejunostomy anastomotic site with balloon-assisted enteroscopy.

The major complication rate in the cohort was 7%. This is in keeping with a meta-analysis that showed that double balloon enteroscopy-assisted ERCP had a complication rate of approximately 6.27% [25]. PTBD has the advantage of ease of access for subsequent procedures if required; however, the requirement for drain care has negative impacts on patient mobility and quality of life and has been associated with poorer outcomes compared to endoscopic biliary drainage [4, 14]. Also, a retrospective analysis showed that nearly one-quarter of patients who had PTBD had a drain in situ at 4 years [26]. Moreover, PTBD is associated with a high rate of AEs of 30%, with recurrence rates at 1 year of up to 48% to 60% [27–29]. One study showed that clinical success and AE rates were comparable in the enteroscopy-assisted ERCP and PTBD groups [16].

EUS-guided biliary drainage has been gaining momentum and shows comparable clinical efficacy when compared to standard ERCP [30]. A multicenter retrospective trial of 98 patients comparing EUS-guided biliary drainage and enteroscopy-assisted ERCP revealed higher clinical success rates (88% vs 59.1%,  $P=0.03$ ) using EUS-guided methods, but they were accompanied by a significantly higher AE rate of 20% vs 4% ( $P=0.01$ ) [31]. There are scant high-quality data on EUS-guided biliary drainage in surgically altered anatomy, especially in liver transplant patients. Stents placed via EUS-guided biliary drainage have the disadvantage of being permanent in the event of stent blockage or dysfunction, limiting future therapeutic options.

The main strength of this study is that it shows real-world outcomes in a high-volume liver transplant center with experienced interventional endoscopists. Limitations of the study are related to its retrospective nature and susceptibility to selection bias. The most notable is that patients were subject to treatment bias because treatment was individualized to endoscopic and radiographic findings as well as the expert endoscopists' discretion. Simpler strictures may have been subject to dilatation alone and more complex treatments to those with combined HJAS and ischemic biliopathy. In addition, our center is a primary DBE-ERCP referral center for a large population in Australia. Thus, our results and decision-making may not be generalizable to other smaller centers without balloon-assisted enteroscopy services.

## Conclusions

In conclusion, technical success and clinical success rates reached over 70% in our study, showing that DBE-ERCP in combination with PTBD is an effective diagnostic and therapeutic tool in patients with altered gastrointestinal anatomy with low complication rates. Ischemic biliopathy should be assessed radiologically (CT or MRI) in liver transplant patients with suspected HJAS and they should be referred for primary PTBD therapy if HJAS is detected. Those with severe HJAS requiring stents should have biodegradable stents placed during PTBD because reaching the hepaticojejunostomy may not be feasible. EUS-guided biliary drainage for HJAS should be considered in expert centers and further studies are required to assess its safety and efficacy in liver transplant subjects with HJAS. Future research should focus on prospective trials comparing liver transplant outcomes with other surgical outcomes in the formation of hepaticojejunostomies. In addition, studies using biodegradable stents should be pursued in HJAS to assess safety and efficacy.

## Competing interests

The authors declare that they have no conflict of interest.

## References

- [1] Reid-Lombardo KM, Ramos-De La Medina A, Thomsen K et al. Long-term anastomotic complications after pancreaticoduodenectomy for benign diseases. *J Gastrointest Surg* 2007; 11: 1704–1711
- [2] House MG, Cameron JL, Schulick RD et al. Incidence and outcome of biliary strictures after pancreaticoduodenectomy. *Ann Surg* 2006; 243: 576–578
- [3] Morita S, Kitanosono T, Lee D et al. Comparison of technical success and complications of percutaneous transhepatic cholangiography and biliary drainage between patients with and without transplanted liver. *AJR Am J Roentgenol* 2012; 199: 1149–1152
- [4] Lee AY, Gregorius J, Kerlan RK et al. Percutaneous transhepatic balloon dilation of biliary-enteric anastomotic strictures after surgical repair of iatrogenic bile duct injuries. *PLoS One* 2012; 7: e46478
- [5] Mukund A, Rajesh S, Agrawal N et al. Percutaneous management of resistant biliary-enteric anastomotic strictures with the use of a combined cutting and conventional balloon cholangioplasty protocol: A single-center experience. *J Vasc Interv Radiol* 2015; 26: 560–565
- [6] Bonnel DH, Fingerhut AL. Percutaneous transhepatic balloon dilatation of benign bilioenteric strictures: Long-Term results in 110 patients. *Am J Surg* 2012; 203: 675–683
- [7] Fontein DBY, Gibson RN, Collier NA et al. Two decades of percutaneous transjejunal biliary intervention for benign biliary disease: a review of the intervention nature and complications. *Insights Imaging* 2011; 2: 557–565
- [8] Liu K, Joshi V, Saxena P et al. Predictors of success for double balloon-assisted endoscopic retrograde cholangiopancreatography in patients with Roux-en-Y anastomosis. *Dig Endosc* 2017; 29: 190–197
- [9] Tee HP, How SH, Kaffes AJ. Learning curve for double-balloon enteroscopy: Findings from an analysis of 282 procedures. *World J Gastrointest Endosc* 2012; 4: 368–372

- [10] Wright BE, Cass OW, Freeman ML. ERCP in patients with long-limb Roux-en-Y gastrojejunostomy and intact papilla. *Gastrointest Endosc* 2002; 56: 225–232
- [11] Chua TJ, Kaffes AJ. Tu1594 The utility of balloon assisted enteroscopy in post liver transplant patients with surgically altered anatomy: a single center experience. *Gastrointest Endosc* 2011; 73: 887–891
- [12] Mizukawa S, Tsutsumi K, Kato H et al. Endoscopic balloon dilatation for benign hepaticojejunostomy anastomotic stricture using short double-balloon enteroscopy in patients with a prior Whipple's procedure: A retrospective study. *BMC Gastroenterol* 2018; 18: 14
- [13] Sato T, Kogure H, Nakai Y et al. Double-balloon endoscopy-assisted treatment of hepaticojejunostomy anastomotic strictures and predictive factors for treatment success. *Surg Endosc* 2020; 34: 1612–1620
- [14] Tomoda T, Tsutsumi K, Kato H et al. Outcomes of management for biliary stricture after living donor liver transplantation with hepaticojejunostomy using short-type double-balloon enteroscopy. *Surg Endosc* 2016; 30: 5338–5344
- [15] Tomoda T, Kato H, Miyamoto K et al. Comparison between endoscopic biliary stenting combined with balloon dilation and balloon dilation alone for the treatment of benign hepaticojejunostomy anastomotic stricture. *J Gastrointest Surg* 2020; 24: 1352–1358
- [16] Hammad H, Brauer BC, Smolkin M et al. Treating biliary-enteric anastomotic strictures with enteroscopy-ercp requires fewer procedures than percutaneous transhepatic biliary drains. *Dig Dis Sci* 2019; 64: 2638–2644
- [17] Sato T, Kogure H, Nakai Y et al. Endoscopic treatment of hepaticojejunostomy anastomotic strictures using fully-covered metal stents. *Dig Endosc* 2021; 33: 451–457
- [18] Cotton PB, Eisen GM, Aabakken L et al. A lexicon for endoscopic adverse events: report of an ASGE workshop. *Gastrointest Endosc* 2010; 71: 446–454
- [19] Yamamoto H, Sekine Y, Sato Y et al. Total enteroscopy with a nonsurgical steerable double-balloon method. *Gastrointest Endosc* 2001; 53: 216–220
- [20] Kaffes AJ. Management of benign biliary strictures: current status and perspective. *J Hepatobiliary Pancreat Sci* 2015; 22: 657–663
- [21] Zajko AB, Bron KM, Campbell WL et al. Percutaneous transhepatic cholangiography and biliary drainage after liver transplantation: A five-year experience. *Gastrointest Radiol* 1987; 12: 137–143
- [22] Kühn JP, Busemann A, Lerch MM et al. Percutaneous biliary drainage in patients with nondilated intrahepatic bile ducts compared with patients with dilated intrahepatic bile ducts. *AJR Am J Roentgenol* 2010; 195: 851–857
- [23] Rees J, Mytton J, Evison F et al. The outcomes of biliary drainage by percutaneous transhepatic cholangiography for the palliation of malignant biliary obstruction in England between 2001 and 2014: A retrospective cohort study. *BMJ Open* 2020; 10: e033576
- [24] Matsunaga Y, Higuchi R, Yazawa T et al. Correction to: Negative prognostic outcomes of percutaneous transhepatic biliary drainage in distal cholangiocarcinoma: a retrospective analysis using propensity score matching. *Int J Clin Oncol* 2021; 26: 1775
- [25] Shao XD, Qi XS, Guo XZ. Endoscopic retrograde cholangiopancreatography with double balloon enteroscope in patients with altered gastrointestinal anatomy: A meta-analysis. *Saudi J Gastroenterol* 2017; 23: 150–160
- [26] Weber A, Rosca B, Neu B et al. Long-term follow-up of percutaneous transhepatic biliary drainage (PTBD) in patients with benign bilioenterostomy stricture. *Endoscopy* 2009; 41: 323–328
- [27] Tapping CR, Byass OR, Cast JEI. Percutaneous transhepatic biliary drainage (PTBD) with or without stenting-complications, re-stent rate and a new risk stratification score. *Eur Radiol* 2011; 21: 1948–1955
- [28] Azeemuddin M, Turab N, Chaudhry MBH et al. Percutaneous management of biliary enteric anastomotic strictures: an institutional review. *Cureus* 2018; 10: e2228
- [29] Delden OM, Laméris JS. Percutaneous drainage and stenting for palliation of malignant bile duct obstruction. *Eur Radiol* 2008; 18: 448–456
- [30] Kakked G, Salameh H, Cheesman A et al. Primary EUS-guided biliary drainage versus ERCP drainage for the management of malignant biliary obstruction: A systematic review and meta-analysis. *Endosc Ultrasound* 2020; 9: 298–307
- [31] Khashab M, el Zein M, Sharzei K et al. EUS-guided biliary drainage or enteroscopy-assisted ERCP in patients with surgical anatomy and biliary obstruction: an international comparative study. *Endosc Int Open* 2016; 4: E1322–E1327